



NOTE

Surgery

Bilateral anterior segment dysgenesis with the presumed Peters' anomaly in a cat

Sangwan PARK^{1,2}, Kiwoong KIM², Youngbeum KIM² and Kangmoon SEO¹*¹Department of Veterinary Clinical Sciences, College of Veterinary Medicine and Research Institute for Veterinary Science, Seoul National University, 1 Gwanak-ro, Gwanak-gu, Seoul, 08826, Korea²Bon Animal Medical Center, 114 Songjeong-ro, Jangan-gu, Suwon-si, Gyeonggi-do, Korea*J. Vet. Med. Sci.*

80(2): 297–301, 2018

doi: 10.1292/jvms.17-0532

Received: 29 September 2017

Accepted: 3 December 2017

Published online in J-STAGE:
15 December 2017

ABSTRACT. A seven-month-old female domestic shorthaired cat was presented for buphthalmos in the right eye and corneal cloudiness in the left eye. Full ophthalmic examinations were performed for both eyes and enucleation was done for the right nonvisual eye. Congenital glaucoma caused by anterior segment dysgenesis was confirmed for the right eye. In the left eye, slit-lamp examination revealed focal corneal edema with several iris strands from iris collarette to the affected posterior corneal surfaces. Circular posterior corneal defect was suggested to be the cause of edema. Goniodysgenesis, additionally, was identified. Taken together, the diagnosis of Peters' anomaly which is a subtype of anterior segment dysgenesis was suggested in the left eye.

KEY WORDS: anterior segment dysgenesis, congenital glaucoma, feline, Peters' anomaly

Anterior segment dysgenesis (ASD) has been reported sporadically in different species of animals, including dogs, cats, cattle, horses, mice and wild animals, etc [1, 3, 6, 11, 14, 15]. The ASD is a general term to describe a heterogenous spectrum of developmental disorders affecting the cornea, iris, lens, and iridocorneal angle structure [2, 13]. It is well established in humans and encompasses a broad range of anomalies including the Peters' anomaly, Axenfeld-Rieger syndrome, and sclerocornea [13]. Peters' anomaly is characterized by central corneal leukoma associated with adherent iris and/or lens, the lack of underlying Descemet's membrane and endothelium, and edematous corneal stroma [2, 3, 13–15]. Axenfeld-Rieger syndrome refers to abnormalities including posterior embryotoxon (anteriorly displaced Schwalbe's line), iris strands adherent to the prominent Schwalbe's line, and iris hypoplasia [3, 13]. We reported here a case of bilateral ASD with the presumed Peters' anomaly of one eye in a cat.

A seven-month-old female domestic shorthaired cat was presented with severe buphthalmos of the right eye (Fig. 1). The owner first noticed cloudiness of both eyes (OU) at 4 months of age and the right eye (OD) became progressively enlarged during the last month.

Full ophthalmic examinations including neuro-ophthalmic examinations, fluorescein staining, rebound tonometry (TonoVet®; icare, Tiolat, Helsinki, Finland), slit-lamp biomicroscopy (HS-7000; Huvitz Co., Ltd., Anyang-si, Gyeonggi-do, Korea), and indirect ophthalmoscopy were performed. Although the menace response was negative OD, the normal-sized left eye (OS) was visual. The dazzle reflexes were positive OU and the pupillary light reflexes were negative OD and positive OS. The intraocular pressure OD was elevated at 31 mmHg and was 13 mmHg OS.

The right eye had an axially located, corneal ulceration with extensive fibrosis and neovascularization possibly due to severe buphthalmos. The depth of anterior chamber was increased but the intraocular structures could not be clearly investigated by slit lamp biomicroscopy due to severe corneal opacity. Ultrasound examination revealed posterior polar cataract OD.

The left cornea had focal symblepharon dorsally and medio-central focal corneal edema. The iris exhibited two distinct, solidly pigmented patches dorsotemporally, indicating heterochromic iridis (Fig. 2). No synechia was identified following pharmacological mydriasis. Slit-lamp examination revealed that several pigmented spots were present in the posterior corneal surfaces of edematous area. Some of pigmented spots were connected to iris collarette region and located to the level of anterior corneal stroma, indicating reduced corneal thickness at these points. The thickness of the rest, affected cornea was mildly increased due to stromal edema. Overall posterior surfaces of affected cornea were not clearly investigated because light was scattered by corneal edema. However, the edematous area was delineated in the posterior corneal surfaces by a 360° circular line, which was identified only when retroilluminated. Additionally, iridocorneal angle examination revealed that several iris strands arising from the iris collarette attached to the posterior corneal surfaces, corresponding to the previously described pigmented spots (Fig. 3). Goniodysgenesis characterized by absence of pectinate ligament fibers in some regions was also identified. The vitreous and

*Correspondence to: Seo, K.: kmseo@snu.ac.kr

©2018 The Japanese Society of Veterinary Science

This is an open-access article distributed under the terms of the Creative Commons Attribution Non-Commercial No Derivatives (by-nc-nd) License. (CC-BY-NC-ND 4.0: <https://creativecommons.org/licenses/by-nc-nd/4.0/>)

retina OS had a normal appearance on ultrasound and indirect ophthalmoscopic examinations (Fig. 4).

The cat was in good general condition except for ocular pain by chronic corneal ulceration. Physical examination, blood analyses including CBC and serum chemistry profile and thoracic radiographs were within normal limits. Since enucleation is generally the most appropriate treatment for cats with irreversibly blind and painful eyes [7], the patient underwent enucleation of the right eye and histopathological analysis was performed.

Histologically, there was marked exposure keratopathy with multiple breaks and focal detachment of Descemet's membrane (Fig. 5). Ciliary clefts were collapsed and replaced by an iris-like tissue. The corneal endothelium crosses over the iridocorneal angle, carpeting the anterior surface of the iris and produces a thick PAS-positive Descemet's membrane-like material, called iridocorneal angle descemetization. The trabecular meshwork and aqueous venous plexus were completely absent. Marked lymphoplasmacytic infiltration was identified in the iris and ciliary body. Posterior cortical cataract, optic nerve cupping and atrophy and multifocal retinal detachment were also found.

The lesions affecting the cornea, iris, iridocorneal angle, lens and optic nerve were congenital in nature and fell under the spectrum of ASD. Therefore, congenital glaucoma of the right eye

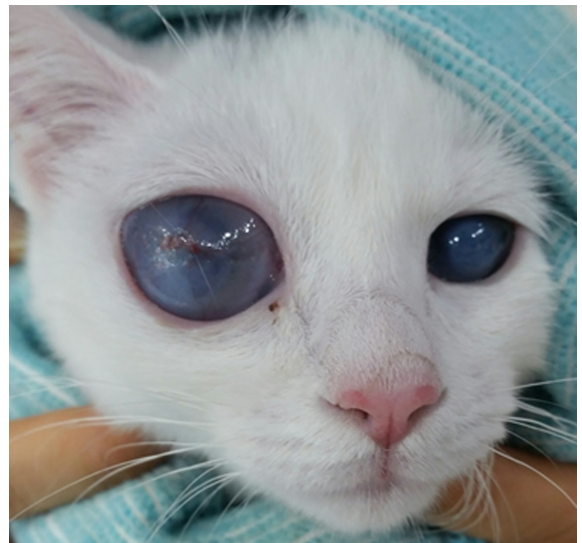

Fig. 1. Clinical photograph of both eyes of 7-month-old domestic shorthaired kitten. Severe buphthalmos of the right eye and cloudy cornea of the left eye were identified.

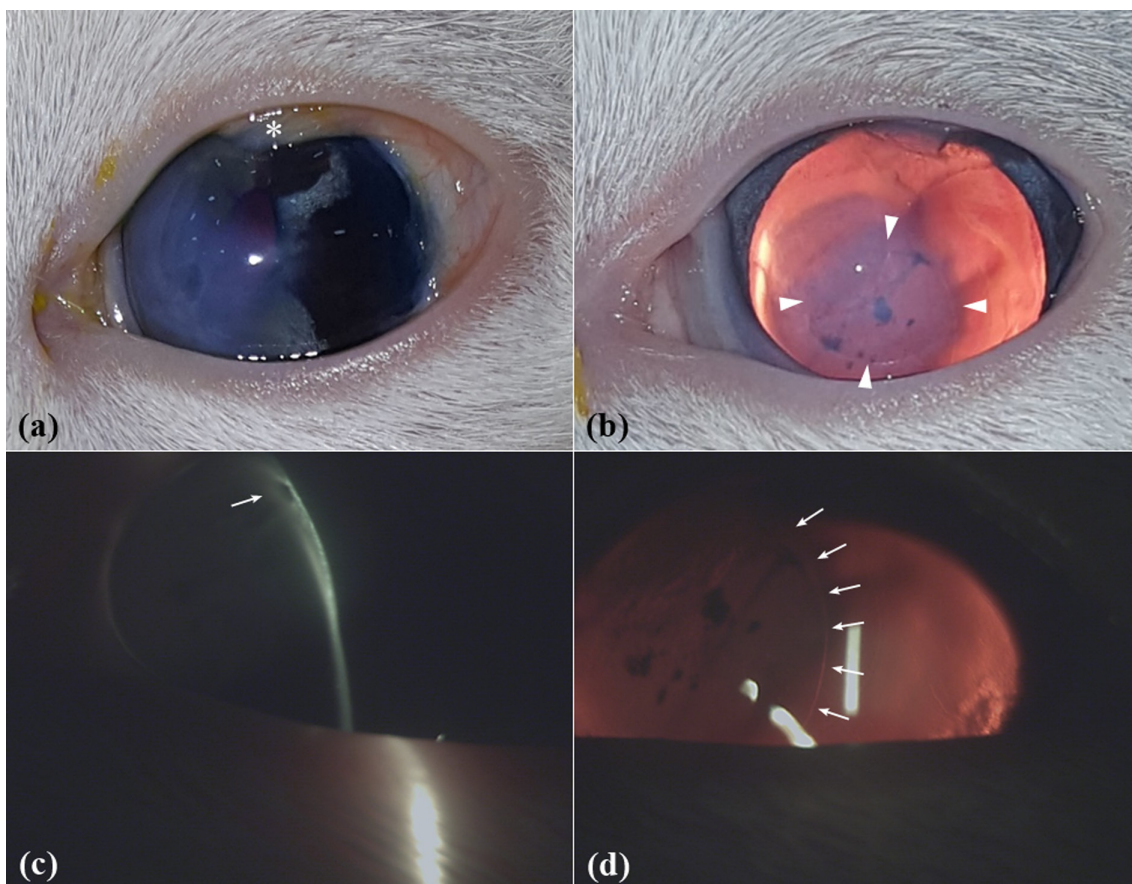


Fig. 2. Clinical photograph of the left eye. (a) Before mydriasis. Note the symblepharon (star), heterochromic iridis and focal corneal edema. (b) After mydriasis. Note the circular corneal edema (arrowheads) and posteriorly pigmented spots. (c) Pigmented iris strand attached to the level of anterior stroma (arrow), indicating reduced corneal thickness and posterior corneal defects. (d) Affected edematous area was delineated in circular fashion (arrows) in the posterior corneal surfaces.

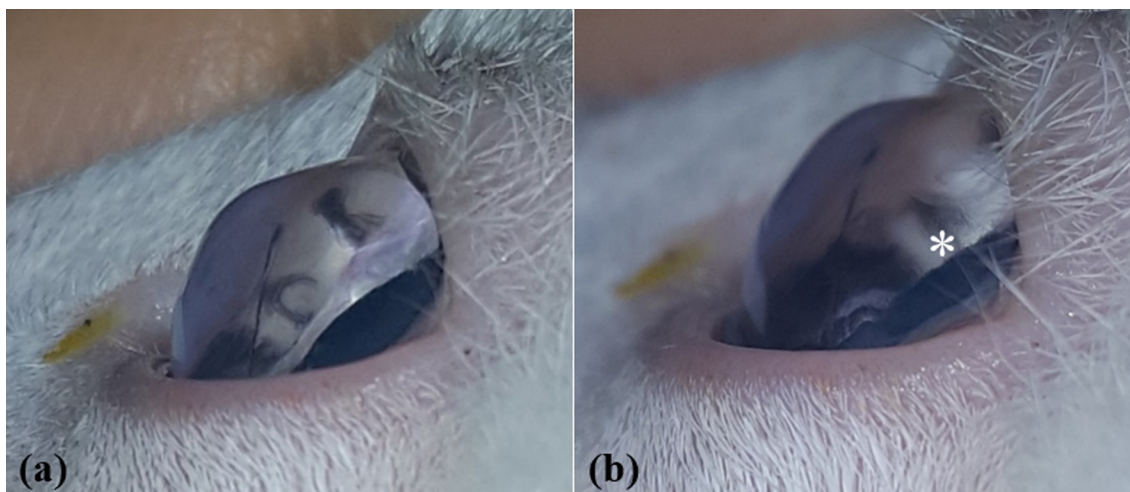


Fig. 3. Clinical goniophotograph of the left eye. (a) Pigmented iris strands originating from iris collarette attached to the affected posterior corneal surfaces. (b) Pectinate ligament fibers were absent in some regions (star).

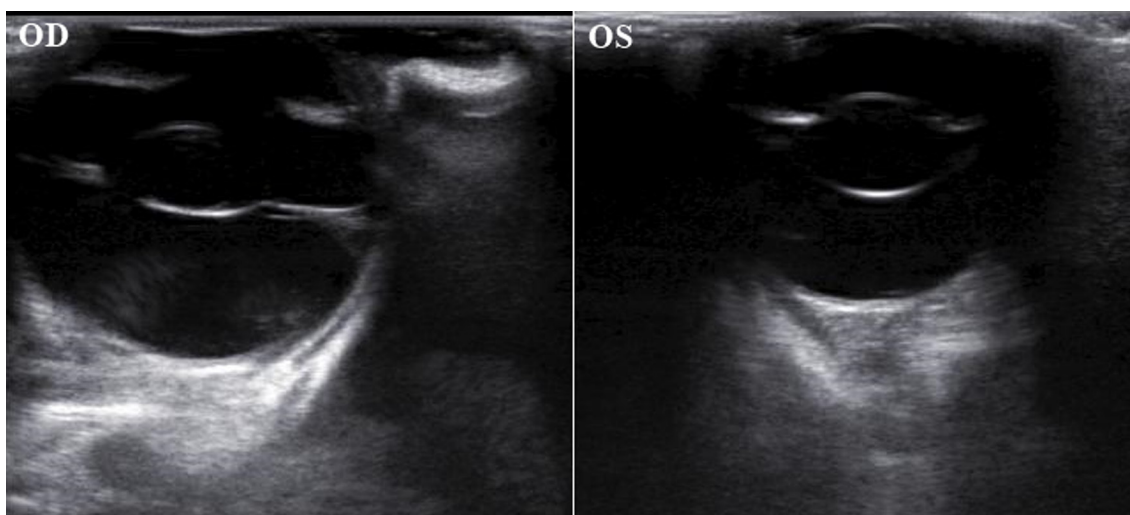


Fig. 4. Ultrasound images of both eyes.

was suggested to be caused by malformation of the anterior ocular segment.

Since most structures of the ocular anterior segment are derived from neural crest and neuroectoderm, ASD is usually attributed to abnormalities during embryogenesis and neural crest cell differentiations [1, 2, 12, 13]. Among the various developmental stages, the period that separation of lens vesicle and surface ectoderm occurs is critical for the development of ASD. As the lens vesicle detaches from the surface ectoderm which will become corneal epithelium, mesenchymal neural crest cells migrate between the surface ectoderm and lens vesicle and fills the future anterior chamber [1, 2]. This mesenchyme sequentially gives rise to the corneal endothelium and trabecular meshwork, corneal keratocytes and stroma, and finally the iris [12, 13]. Although the lens vesicle detachment is known to occur at approximately day 25 of gestation in dogs, the specific timepoint for the cat is yet to be reported. However, a general timeline from lens placode to optic cup formation of cats was investigated to be similar to that of dogs in a previous study [5].

As for the left eye, clinical findings such as iris strands adherent to the cornea and regional absence of pectinate ligament fibers suggested the clinical diagnosis of ASD as well. In addition, although the light reflection of corneal opacity hindered evaluating the continuity of Descemet's membrane at the affected region, the point that pigmented iridal strands adhered was identified to be anteriorly located in the cornea, suggesting the possibility of posterior corneal defects. Furthermore, a 360° circular line delineated the margin of the affected posterior corneal surfaces. Taken together, it is presumed that focal edema was caused by circular defects in the posterior corneal surfaces and iridal strands were attaching to the defected area. These clinical findings are identical with those previously described in snow leopard cubs and humans with Peters' anomaly [3, 8, 12, 13]. Peters' anomaly is primarily characterized by congenital central corneal opacity associated with an absence or defect of underlying Descemet's membrane and

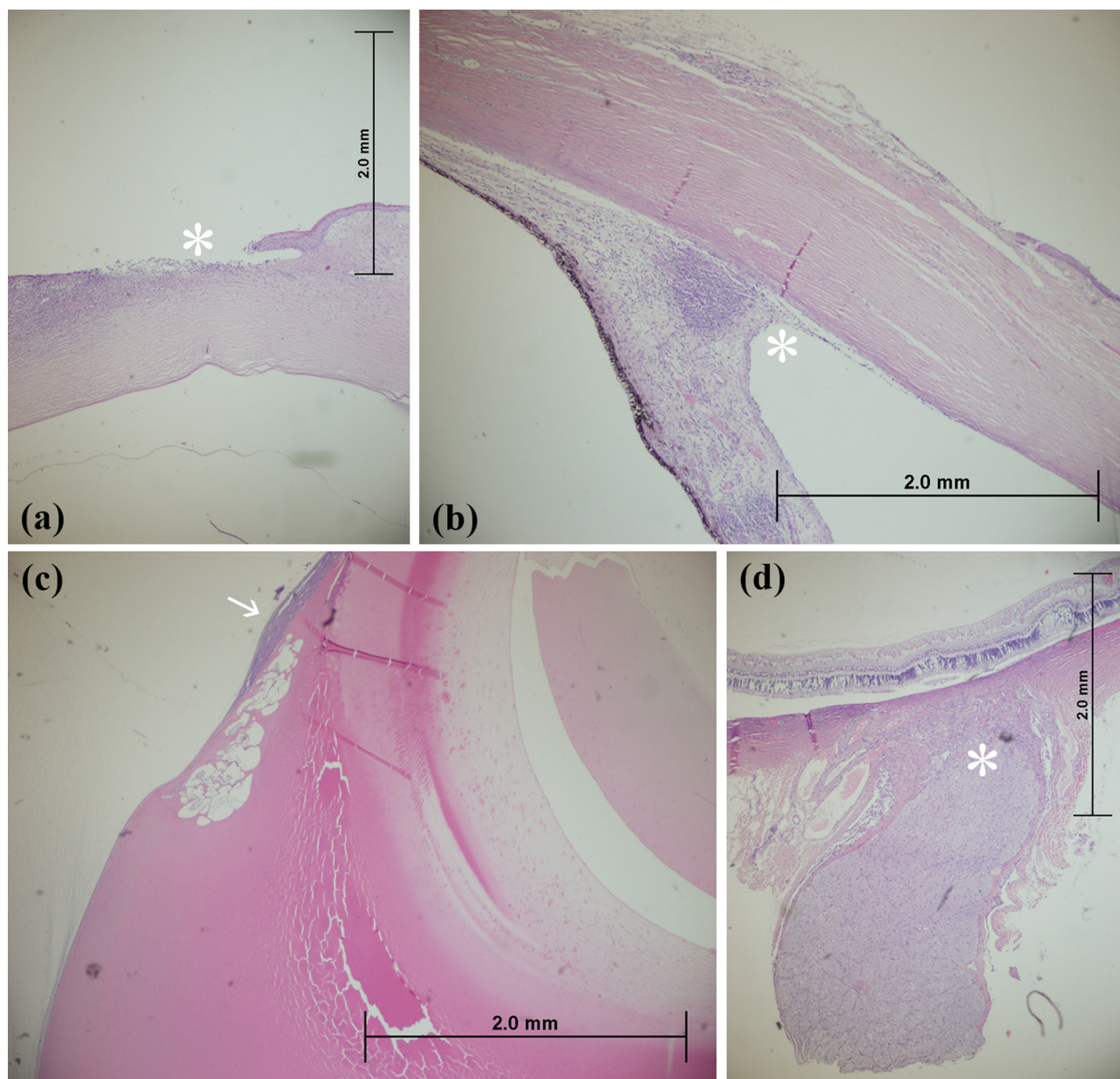


Fig. 5. (a) Corneal erosion (star) with keratinization, stromal fibrosis and vascularization was noted. (b) Ciliary clefts were collapsed (star) and trabecular meshwork and aqueous venous plexus were completely absent. The iris and ciliary body were markedly infiltrated by lymphocytes and plasma cells. (c) The lens presented moderate liquefaction of the posterior cortex with posterior lens epithelial migration and fibrous metaplasia, indicating posterior cortical cataract (arrow). (d) Optic nerve was cupped, atrophied and markedly gliotic (star).

corneal endothelium [3, 9, 13].

Since the light of visible wavelengths of slit lamp biomicroscope is scattered by the corneal edema as in this case, an infrared anterior segment camera employing light of longer wavelengths could be used instead to clearly observe the corneal lesion and to reveal the spatial relation between the cornea and the iris [8]. To confirm the posterior corneal defects which is the essential feature of Peters' anomaly, however, high-resolution and noninvasive imaging techniques such as ultrasound biomicroscopy (UBM) and optical coherence tomography (OCT) would be of greater value to clinicians [4, 9, 12]. Although both techniques were demonstrated to be effective in diagnosis of Peters' anomaly, OCT was suggested to produce more accurate and clear images of the anterior segment compared with UBM [12].

Recently, Peters' anomaly has been subdivided into three types: 1) type 1 characterized with central corneal opacity with iridocorneal adhesions, 2) type 2 central corneal opacity with cataract or keratolenticular adhesions, and 3) Peters' plus syndrome with Peters' anomaly in association with systemic malformations including cleft lip/palate, ear abnormalities, and growth retardation [9, 13]. According to this category, the present case with iridocorneal adhesion only corresponds to the type 1 Peters'

anomaly. Meanwhile, there have been two feline case reports describing central corneal opacity with keratolenticular adhesion, which correspond to the type 2 [6, 10]. One of those cats underwent phacoemulsification for lens removal and a corneal graft surgery using a porcine small intestinal submucosa biomaterial to repair the cornea [6]. In humans, it was demonstrated that anatomical information gained from OCT could support surgical decision making in patients ahead of penetrating keratoplasty, for example finding a safe corneal penetration site and hence avoiding possible iris injury and preventing unnecessary cataract/glaucoma surgery [4].

Since the lesions noted in this kitten are non-progressive and astigmatism induced by focal corneal edema is usually not considered debilitating for the living of a house cat, surgical correction was not recommended. Considering the presence of goniodysgenesis of the remaining eye and the development of glaucoma in the opposite, enucleated eye, however, intraocular pressure should be closely monitored for the rest of the cat's life. In humans, the most common ocular abnormalities associated with Peters' anomaly were glaucoma (20%), microphthalmia (18%), and colobomas (6%) [9]. Furthermore, it was reported that fifty percent of patients with ASD develop glaucoma in another human study [4].

In summary, the diagnosis of ASD in the right eye was confirmed by histopathological analysis. Although the right eye showed no evidence of Peters' anomaly which is a subtype of ASD, clinical findings identified in the left eye closely resembles Peters' anomaly. Peters' anomaly, although rare, should be considered in differential diagnosis of congenital corneal opacity in cats. Meticulous slit lamp examination could reveal the evidence of posterior corneal defects such as reduced corneal thickness at the affected region and posterior circular delineation of the defected area on retroillumination.

ACKNOWLEDGMENT. This study was supported through BK21 PLUS Program for Creative Veterinary Science Research.

REFERENCES

1. Bauer, B. S., Sandmeyer, L. S. and Grahn, B. H. 2015. Diagnostic ophthalmology. *Can. Vet. J.* **56**: 519–520. [Medline]
2. Cook, C. S. 2013. Ocular embryology and congenital malformations. pp. 3–28. In: *Veterinary Ophthalmology*, 15th ed. (Gelatt, K. N., Brian C., G. and Thomas, J., K. eds.) John Wiley & Sons, Iowa.
3. Hamoudi, H., Rudnick, J. C., Prause, J. U., Tauscher, K., Breithaupt, A., Teifke, J. P. and Heegaard, S. 2013. Anterior segment dysgenesis (Peters' anomaly) in two snow leopard (*Panthera uncia*) cubs. *Vet. Ophthalmol.* **16** Suppl 1: 130–134. [Medline] [CrossRef]
4. Hong, J., Yang, Y., Cursiefen, C., Mashaghi, A., Wu, D., Liu, Z., Sun, X., Dana, R. and Xu, J. 2017. Optimising keratoplasty for Peters' anomaly in infants using spectral-domain optical coherence tomography. *Br. J. Ophthalmol.* **101**: 820–827. [Medline] [CrossRef]
5. Knospe, C. 2002. Periods and stages of the prenatal development of the domestic cat. *Anat. Histol. Embryol.* **31**: 37–51. [Medline] [CrossRef]
6. Lazard, P. and Peiffer, R. L. 2010. An uncommon case of anterior segment dysgenesis in a domestic shorthair cat. *Rev. Med. Vet.* **161**: 173–177.
7. McLellan, G. J. and Miller, P. E. 2011. Feline glaucoma--a comprehensive review. *Vet. Ophthalmol.* **14** Suppl 1: 15–29. [Medline] [CrossRef]
8. Morishige, N., Yamada, N., Morita, Y. and Sonoda, K. H. 2014. Peters' anomaly imaged with an infrared anterior segment camera. *Clin. Experiment. Ophthalmol.* **42**: 391–392. [Medline] [CrossRef]
9. Ni, W., Wang, W., Hong, J., Zhang, P. and Liu, C. 2015. A novel histopathologic finding in the Descemet's membrane of a patient with Peters Anomaly: a case-report and literature review. *BMC Ophthalmol.* **15**: 139–144. [Medline] [CrossRef]
10. Peiffer, R. L. Jr. and Belkin, P. V. 1983. Keratolenticular dysgenesis in a kitten. *J. Am. Vet. Med. Assoc.* **182**: 1242–1243. [Medline]
11. Sato, R., Onda, K., Murakami, M., Ito, D. and Madarame, H. 2017. Congenital anterior staphyloma associated with Peters' anomaly and aphakia in a Holstein calf. *J. Vet. Med. Sci.* **79**: 1151–1154. [Medline] [CrossRef]
12. Shigeyasu, C., Yamada, M., Mizuno, Y., Yokoi, T., Nishina, S. and Azuma, N. 2012. Clinical features of anterior segment dysgenesis associated with congenital corneal opacities. *Cornea* **31**: 293–298. [Medline] [CrossRef]
13. Stahl, E. D. 2014. Anterior segment dysgenesis. *Int. Ophthalmol. Clin.* **54**: 95–104. [Medline] [CrossRef]
14. Suedmeyer, W. K., Pearce, J., Persky, M. and Houck, M. L. 2014. Peters anomaly in a red kangaroo (*Macropus rufus*). *J. Zoo Wildl. Med.* **45**: 715–718. [Medline] [CrossRef]
15. Swanson, H. L., Dubielzig, R. R., Bentley, E. and Murphy, C. J. 2001. A case of Peters' anomaly in a springer spaniel. *J. Comp. Pathol.* **125**: 326–330. [Medline] [CrossRef]