

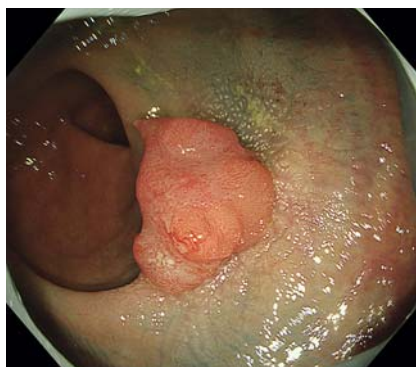
## Cutting into the black sea: endoscopic submucosal dissection using a clip with line for a rectal polyp with severe fibrosis after tattooing



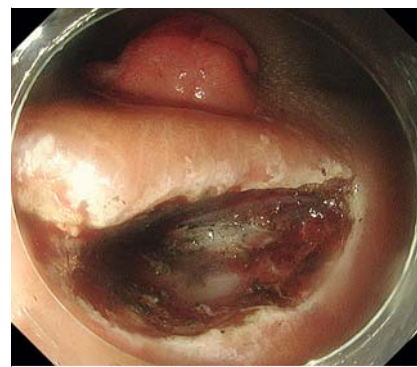
A 75-year-old woman underwent a follow-up colonoscopy after polypectomy of colorectal adenomas. A 20-mm polyp with submucosal invasion was diagnosed endoscopically in the lower rectum, marked with tattoo, and the patient was then referred to our institute for surgery. Colonoscopy revealed a 20-mm reddish protruding lesion with tattooing laterally on both sides of the lesion (► **Fig. 1**). The macroscopic type was 0-Is, the Japanese Narrow-Band Imaging Expert Team classification was type 3, and the pit pattern was VN, suggesting submucosal invasion. As the patient did not wish a stoma to be made, endoscopic submucosal dissection (ESD) was attempted, and she was enrolled in a clinical trial (JCOG1612) investigating the efficacy of chemoradiation after local resection of rectal cancer [1].

After injecting the anal side, where the effect of the prior tattooing was minimal, we made a mucosal incision and a flap (► **Fig. 2**), revealing black submucosa together with severe fibrosis (► **Video 1**). A clip with line (► **Fig. 3**) [2] enabled good visibility of the cutting layer. We finally managed to complete resection in 62 minutes. Black tissue was spread almost all over the submucosa (► **Fig. 4**) on the vertical side. The pathological diagnosis was 16×15 mm, tub1>tub2, pT1b (SM: 4000 μm), INFb, Ly0 (D2–40), V1 (EVG) (SM), BD1, Pn0, HM0, VM0. Severe fibrosis with black staining was identified pathologically (► **Fig. 5**).

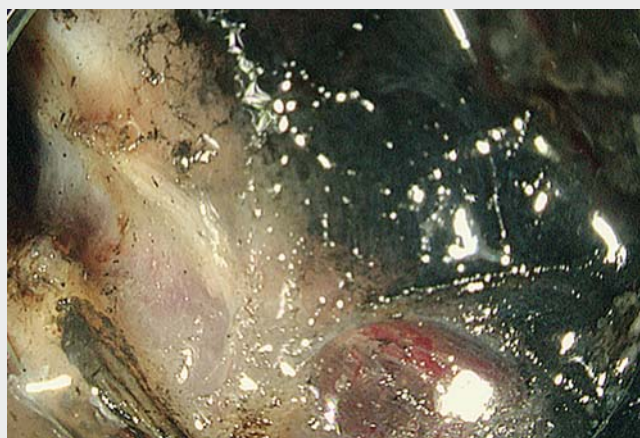
Endoscopic resection is sometimes performed after tattooing, because the preoperative diagnosis of the invasion depth is different from that at the previous hospital, or for submucosal invasive cancer together with subsequent chemoradiotherapy [1]. Although severe fibrosis and black submucosa have led to difficulty in finding the appropriate cutting plane and achieving en bloc resection [3], successful ESD by conventional [4] or tissue retractor system-assisted methods [5]



► **Fig. 1** A 20-mm reddish protruding lesion in the lower rectum with tattooing on both lateral sides of the lesion.



► **Fig. 2** A flap made from the anal side, where the effect of prior tattooing was minimal.



► **Video 1** Cutting into the black sea: endoscopic submucosal dissection using a clip with line for a rectal polyp with severe fibrosis after tattooing.



have been reported. By using the clip with line, which is an easy and inexpensive method, successful ESD was achieved in the present case.

Endoscopy\_UCTN\_Code\_TTT\_1AQ\_2AD

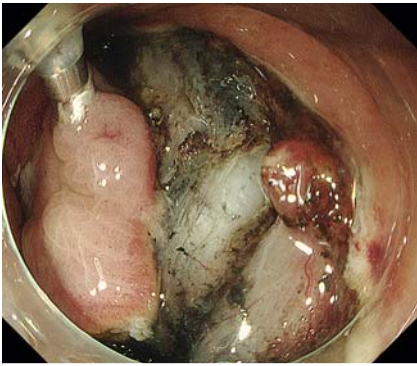
### Competing interests

The authors declare that they have no conflict of interest.

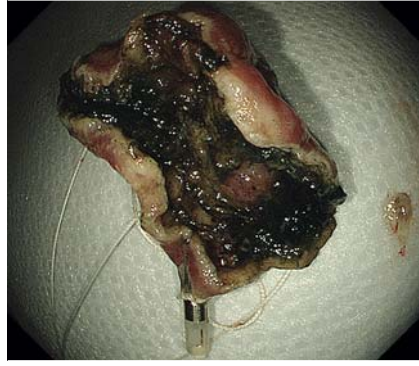
### The authors

Satoki Shichijo<sup>1</sup>, Takehiro Ninomiya<sup>1</sup>, Tomoki Michida<sup>1</sup>, Masayoshi Yasui<sup>2</sup>, Yoji Takeuchi<sup>1</sup>

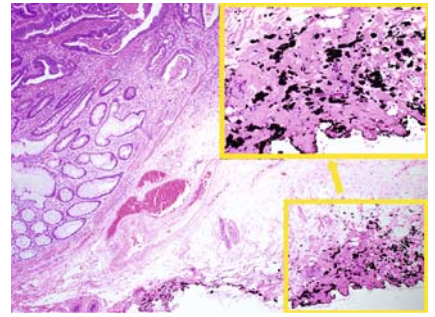
- 1 Department of Gastrointestinal Oncology, Osaka International Cancer Institute, Osaka, Japan
- 2 Department of Gastroenterological Surgery, Osaka International Cancer Institute, Osaka, Japan



► **Fig. 3** A clip with line attached to get adequate tension for good visibility of the submucosal layer.



► **Fig. 4** Vertical view of the resected specimen showing black tissue spread over almost all of the submucosa after en bloc resection.



► **Fig. 5** Severe fibrosis with black staining was identified pathologically.

## Corresponding author

### Satoki Shichijo, MD, PhD

Department of Gastrointestinal Oncology,  
Osaka International Cancer Institute, 3-1-69,  
Otemae, Chuo-ku, Osaka, 541-8567, Japan  
7satoki@oici.jp

## References

- [1] Kadota T, Ikematsu H, Sasaki T et al. Protocol for a single-arm confirmatory trial of adjuvant chemoradiation for patients with high-risk rectal submucosal invasive cancer after local resection: Japan Clinical Oncology Group Study JCOG1612 (RESCUE study). *BMJ Open* 2020; 10: e034947
- [2] Yamasaki Y, Takeuchi Y, Hanaoka N et al. A novel traction method using an endoclip attached to a nylon string during colonic endoscopic submucosal dissection. *Endoscopy* 2015; 47: E238–E239
- [3] Ono S, Fujishiro M, Goto O et al. Endoscopic submucosal dissection for colonic laterally spreading tumors is difficult after target tattooing. *Gastrointest Endosc* 2009; 69: 763–766

- [4] Chiba H, Tachikawa J, Kurihara D et al. Successful endoscopic submucosal dissection of colon cancer with severe fibrosis after tattooing. *Clin J Gastroenterol* 2017; 10: 426–430
- [5] Jawaid S, Yang D, Draganov PV. Tissue retractor system-assisted endoscopic submucosal dissection of a large rectal tumor with significant fibrosis from direct tattooing. *VideoGIE* 2019; 4: 84–86

## Bibliography

*Endoscopy* 2023; 55: E364–E365

DOI 10.1055/a-1996-0502

ISSN 0013-726X

© 2023. The Author(s).

This is an open access article published by Thieme under the terms of the Creative Commons Attribution-NonDerivative-NonCommercial License, permitting copying and reproduction so long as the original work is given appropriate credit. Contents may not be used for commercial purposes, or adapted, remixed, transformed or built upon. (<https://creativecommons.org/licenses/by-nc-nd/4.0/>)

Georg Thieme Verlag KG, Rüdigerstraße 14,  
70469 Stuttgart, Germany



## ENDOSCOPY E-VIDEOS

<https://eref.thieme.de/e-videos>



*Endoscopy E-Videos* is an open access online section, reporting on interesting cases

and new techniques in gastroenterological endoscopy. All papers include a high quality video and all contributions are freely accessible online. Processing charges apply (currently EUR 375), discounts and waivers acc. to HINARI are available.

This section has its own submission website at

<https://mc.manuscriptcentral.com/e-videos>