

IMI—The Dynamic Choroid: New Insights, Challenges, and Potential Significance for Human Myopia

Lisa A. Ostrin,¹ Elise Harb,² Debora L. Nickla,³ Scott A. Read,⁴ David Alonso-Caneiro,⁴ Falk Schroedl,⁵ Alexandra Kaser-Eichberger,⁵ Xiangtian Zhou,⁶ and Christine F. Wildsoet^{2,7}

¹University of Houston College of Optometry, Houston, Texas, United States

²Herbert Wertheim School of Optometry and Vision Science, University of California Berkeley, Berkeley, California, United States

³Department of Biomedical Sciences and Disease, New England College of Optometry, Boston, Massachusetts, United States

⁴Contact Lens and Visual Optics Laboratory, Centre for Vision and Eye Research, School of Optometry and Vision Science, Queensland University of Technology, Brisbane, Queensland, Australia

⁵Center for Anatomy and Cell Biology, Institute of Anatomy and Cell Biology–Salzburg, Paracelsus Medical University, Salzburg, Austria

⁶Eye Hospital and School of Optometry and Ophthalmology, National Clinical Research Center for Ocular Diseases, Wenzhou Medical University, Wenzhou, Zhejiang, China

⁷Centre for Vision and Eye Research, School of Optometry and Vision Science, Queensland University of Technology, Brisbane, Queensland, Australia

Correspondence: Lisa Ostrin, University of Houston College of Optometry, 4401 Martin Luther King Boulevard, Houston, TX 77004, USA; lostrin@central.uh.edu.

Received: January 28, 2023

Accepted: February 7, 2023

Published: May 1, 2023

Citation: Ostrin LA, Harb E, Nickla DL, et al. IMI—The dynamic choroid: New insights, challenges, and potential significance for human myopia. *Invest Ophthalmol Vis Sci*. 2023;64(6):4. <https://doi.org/10.1167/iov.64.6.4>

The choroid is the richly vascular layer of the eye located between the sclera and Bruch's membrane. Early studies in animals, as well as more recent studies in humans, have demonstrated that the choroid is a dynamic, multifunctional structure, with its thickness directly and indirectly subject to modulation by a variety of physiologic and visual stimuli. In this review, the anatomy and function of the choroid are summarized and links between the choroid, eye growth regulation, and myopia, as demonstrated in animal models, discussed. Methods for quantifying choroidal thickness in the human eye and associated challenges are described, the literature examining choroidal changes in response to various visual stimuli and refractive error-related differences are summarized, and the potential implications of the latter for myopia are considered. This review also allowed for the reexamination of the hypothesis that short-term changes in choroidal thickness induced by pharmacologic, optical, or environmental stimuli are predictive of future long-term changes in axial elongation, and the speculation that short-term choroidal thickening can be used as a biomarker of treatment efficacy for myopia control therapies, with the general conclusion that current evidence is not sufficient.

Keywords: myopia control, myopia progression, myopia management, choroid

The choroid is the vascular layer of the eye located between the sclera and Bruch's membrane. Accumulating evidence suggests that the choroid is involved in the regulation of eye growth, with potential implications for both the development of myopia and its treatment. The past few decades have seen an upsurge of interest in the choroid and its potential role in myopia, largely initiated by a 1995 study by Wallman et al.¹ in chicks, showing that the choroid's thickness is modulated in response to retinal defocus to compensate for imposed refractive errors and that these changes are correlated with changes in eye growth. Follow-up studies involving animal models of myopia have provided more convincing evidence for a key role of the choroid in eye growth regulation,² with the demonstration that bidirectional changes in choroidal thickness precede and predict the direction of eye growth.¹ To wit, a literature search of "myopia and choroid" yields 2060 publications since 1995, compared to a mere 234 in the preceding 75 years. It is now apparent that the choroid is a complex multifunctional tissue² whose functions go well beyond those related to supplying nutrients and oxygen to the outer retina.

Studies in humans, mostly involving young adults, have also shown the choroid to be a dynamic structure whose thickness is modulated by numerous physiologic stimuli and visual cues. For example, short-term changes in choroidal thickness have been observed in response to time of day,³ physical activity,⁴ caffeine intake,⁵ light intensity and wavelength,⁶ and defocus.^{7,8} Ocular biometry and optical coherence tomography imaging are techniques utilized to quantify choroidal thickness and, in some cases, choroidal volume, with some studies also using as a surrogate for changes in choroidal thickness equivalent changes in axial length, when defined as the distance from the cornea to retinal pigment epithelium. Thus, for example, a decrease in axial length suggests an increase in choroidal thickness and vice versa. Speculation also continues as to whether short-term modulation of choroidal thickness can be used as a biomarker to determine whether a particular stimulus is myopiagenic or protective against myopia, based on observed choroidal thinning and thickening, respectively. While the choroid of the chick has the capacity to thicken by over 100%, short-term changes in choroidal thickness reported in humans

are much smaller, on the order of 5 to 30 μm , or approximately 2% to 3% of the average thickness of the human choroid, making precise measurement of such changes challenging. In this review, we will first summarize the anatomy and function of the choroid and consider links between the choroid and myopia, as demonstrated in animal models. Then we will describe the most commonly used methods for quantifying choroidal thickness in the human eye, summarize the literature describing choroidal changes in response to various stimuli, and discuss potential implications for myopia.

CHOROID ANATOMY, INNERVATION, AND PHYSIOLOGY

The choroid represents the most posterior and largest portion of the uveal layer of the eye. Located between the sclera and Bruch's membrane, the choroid serves a variety of classical functions, including the provision of nutrients to nearby tissues, removal of waste, regulation of ocular temperature, and absorption of stray light. It also serves as a conduit for vessels and nerves entering and leaving the eye. That aqueous humor can exit the eye via the so-called uveoscleral outflow pathway, in addition to the conventional, more anterior pathway involving Schlemm's canal, also suggests a role of the choroid in regulating intraocular pressure.⁹

The outermost layer of the choroid, the suprachoroid, is composed of loose connective tissue and represents a choroid-to-sclera transition layer.¹⁰ The bulk of the choroid is otherwise dominated by blood vessels, organized loosely into three layers of progressively smaller-diameter blood vessels, Haller's layer being the outermost layer, with the largest vessels, the middle Sattler's layer containing medium diameter blood vessels, and the inner choriocapillaris comprised of fenestrated capillaries, adjacent to Bruch's membrane.¹¹ The arterial vessels of the choroid originate from the long and short posterior ciliary arteries, which are branches of the ophthalmic artery, with a minor contribution to its most anterior portion from the anterior ciliary arteries. Venous drainage of the choroid is via the vortex veins. The choroid has one of the highest rates of blood flow in the body, reflecting its important role as a source of nutrients for the outer retina, which is one of the most metabolically demanding tissues of the body.¹² The choroid is thinnest at its anterior margin (i.e., at the ora serrata), where it transitions into the supraciliary and vascular layer of the ciliary body. The choroid is thickest at the posterior pole, reflecting the high metabolic demands of the overlying macular region. The thickness of the human young adult choroid averages approximately 250 to 350 μm in the subfoveal region, although there are significant individual differences tied to axial length and refractive error, as well as numerous other factors, as discussed below.

The choroidal vasculature is supported by fibroblasts that form a collagen-rich scaffold with elastic elements.^{13,14} Interspersed within this scaffold in many, but not all, species are nonvascular smooth muscle cells,^{15–17} which are predominantly found in the posterior (central) choroid and at entrance sites of blood vessels into the choroid, where they likely also serve to anchor the choroid to the sclera. Melanocytes represent a frequent¹⁸ and, perhaps, inhomogeneous¹⁹ cell population in the choroid. In addition, the choroid is rich in mast cells, macrophages, and lympho-

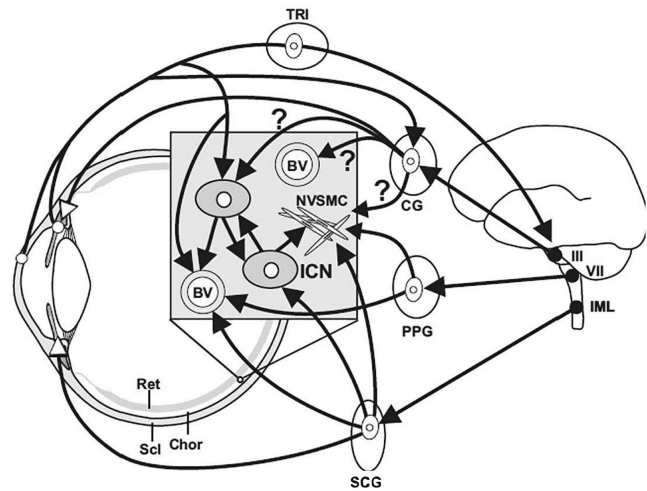


FIGURE 1. Schematic overview of innervation to the choroid in the human eye. BV, blood vessel; CG, ciliary ganglion; Chor, choroid; ICN, intrinsic choroidal neuron; III/VII, brainstem nuclei of cranial nerves III and VII; IML, intermediolateral nucleus; NVSMC, nonvascular smooth muscle cell; PPG, pterygopalatine ganglion; Ret, retina; SCG, superior cervical ganglion; Scl, sclera; TRI, trigeminal ganglion. Adapted with permission from Rucker F, Taylor C, Kaser-Eichberger A, Schroedl F. Parasympathetic innervation of emmetropization. *Exp Eye Res.* 2022;217:108964. © 2022 Elsevier Ltd.

cytes¹⁹ that may contribute to the immune privilege of the inner eye.²⁰ The presence of lymphatic vessels in the human choroid is yet to be established with generally accepted markers,²⁰ and it is still under debate how such a drainage system might contribute to choroidal homeostasis.²⁰ Nonetheless, the presence of choroidal lymphatic lacunae has been confirmed in bird species,²¹ and similar “spaces” have been described in humans, with currently unknown function.^{22–25} There is also a report of lymphatic markers in the choroid of human fetal eyes.²⁶ That the choroid may have an important role in modulating scleral remodeling during eye growth, with implications for emmetropization and myopia,²⁷ could also offer explanations for the recently discovered cell populations displaying retinaldehyde dehydrogenase 2 activity²⁸ and the report of telocyte-like cells in the suprachoroid.²⁸ Apart from synthesizing all-*trans*-retinoic acid,²⁹ the choroid is also known to produce several other growth factors, including vascular endothelial growth factor³⁰ and basic fibroblast growth factor.³¹ Still, it is unknown how these factors are regulated and whether they are transformed into scleral growth signals, what the responsible “start-stop” mechanisms are, and how they interplay with other choroidal functions.

The choroid displays a rich innervation, which includes sympathetic nerve fibers originating from the superior cervical ganglion, as well as parasympathetic nerve fibers originating from the pterygopalatine ganglion (Fig. 1).³² While some species of birds also show a well-established input from the ciliary ganglion, such an input in humans is still under debate.³³ The choroid also contains primary afferent (sensory) nerve fibers, which project to the trigeminal ganglion and then to the trigeminal sensory complex in the brainstem. Additionally, a local network of neurons within the choroid, known as intrinsic choroidal neurons, exists in humans, some nonhuman primates, and some bird species, albeit apparently absent in common laboratory

animals, such as the rat, mouse, and rabbit.^{34,35} Due to their position and nerve fiber contacts—they are contacted by sympathetic, parasympathetic, and primary afferent nerve fibers—they have been termed local integrators for choroidal control,³⁶ although their function remains enigmatic. Established targets of autonomic primary efferent nerve fibers and intrinsic choroidal neurons are choroidal blood vessels and nonvascular smooth muscle cells,^{36,37} consistent with roles in blood flow control³³ and/or changes in choroidal thickness. However, the interplay with the various neural networks and their targets is not well understood. While choroidal melanocytes^{38,39} and pericytes⁴⁰ also receive autonomic innervation,⁴¹ the significance of the latter is equally unknown.

It is generally accepted that the choroid serves an important role in supplying retinal photoreceptors with their required nutrition.³³ Choroidal blood flow regulation seems also essential for retinal thermoregulation,⁴² although the underlying mechanism is not well described.³³ Also not yet well established is the function of the nonvascular smooth muscle cells and their possible involvement in changes in choroidal thickness and/or changes in blood vessel diameters. Finally, it is unknown how accommodative forces generated in the ciliary body are transformed by the choroid, in the interest of preserving vision during accommodation and disaccommodation,^{43,44} although buffering by the preequatorial choroid is suggested by *in vitro* observations made from human eyes denuded of their sclera.⁴⁵

ROLE OF THE CHOROID IN EYE GROWTH REGULATION: WHAT HAS BEEN LEARNED FROM ANIMAL MODELS

Three key findings from animal models with respect to the choroid that have relevance to human myopia are as follows: (1) compensatory optical defocus modulated thickness changes, (2) diurnal thickness changes, and (3) pharmacologic effects (see reviews: Troilo et al.²⁷; Summers⁴⁶). Each is discussed below.

Compensatory changes in the choroid in response to imposed optical defocus were first reported in chicks, in which the choroid showed an approximately linear change in choroidal thickness over a range of spectacle lens defocus from approximately -15 diopters (D) to $+15$ D^{1,47}; these choroidal thickness changes were always closely followed by changes in scleral matrix synthesis that altered the overall growth of the eye to eventually attain emmetropia with the spectacle lenses in place.⁴⁸ This finding suggested that the state of the choroid (i.e., its thickness) is predictive of ocular growth rate, which was subsequently investigated by two different groups, again using the chick model. One group found no predictive value.⁴⁹ However, the other group found a significant association between initial choroidal thickness and subsequent growth rate, such that eyes with thinner choroids grew faster than those with thicker ones. Nonetheless, the latter observation was limited to untreated eyes and not seen in experimentally manipulated eyes.⁵⁰ In any case, the development of myopia in animal models, whether induced by form deprivation or negative spectacle lenses, is always associated with a thinner choroid and vice versa (see review: Nickla and Wallman²). While it remains to be determined whether the changes in choroidal thickness are primary or secondary events, this association has spurred

much research into the role of the choroid in human myopia development.

Diurnal oscillations in choroidal thickness were first reported in the chick. The choroid thickens during the evening, with a peak around midnight, and thins in the morning, with a trough around noon.^{51,52} This rhythm is in approximate antiphase to the rhythm in axial length. These findings have since been replicated in marmosets⁵³ and humans (see below),^{54–57} with similar phase relationships between the two components. Notably, in chick eyes that were responding to myopic defocus imposed by positive lenses that slowed their overall growth, the rhythms shifted into phase, suggesting a causal relationship between phase and ocular growth.^{51,58} In humans too, exposing eyes to brief myopic defocus results in shifts in phase of the two rhythms,⁷ corroborating the work in animal models and suggesting shared underlying circadian and defocus-driven mechanisms in the regulation of eye growth. Hyperopic defocus results in changes in amplitude but not phase.⁸ The recent finding of clock gene expression in chick choroid is intriguing, as it suggests a locally mediated (as opposed to distal or central) modulation of these diurnal rhythms in choroidal thickness and possibly also in scleral matrix synthesis.⁵⁹

As noted above, the choroid has long been known to secrete growth factors, such as vascular endothelial growth factor and hepatocyte growth factor, that have roles in angiogenesis and matrix metalloproteinases and tissue inhibitors of metalloproteinases that have roles in matrix turnover. Such trophic molecules as retinoic acid, transforming growth factor β , and fibroblast growth factor have also been shown to be synthesized in the choroid.²⁷ Three of the most extensively studied neurotransmitter molecules having strong evidence for playing a role in emmetropization are nitric oxide, dopamine, and acetylcholine. Nitric oxide, which is synthesized in both the retina and choroid, is a potent vasodilator, and inhibitors of nitric oxide synthases have been shown to prevent the myopic defocus-evoked choroidal thickening and disinhibited ocular growth,⁶⁰ making nitric oxide a candidate molecule for growth inhibition. Dopaminergic agonists also simultaneously inhibit ocular growth⁶¹ and induce choroidal thickening.⁶² Finally, the cholinergic antagonist, atropine, as well as some other antagonists known to inhibit ocular growth also result in choroidal thickening in animals.⁶³ Atropine (and analogues) results in choroidal thickening in humans as well.⁶⁴ Collectively, these data support the hypothesis linking choroidal thickening to ocular growth inhibition. The potential translational relevance of these observations for human myopia and therapeutic interventions is considered again below in the “Implications of Choroidal Thickness Modulation for Efficacy of Myopia Control” section. However, it should be noted that the sites of action, and hence the underlying mechanisms for the growth inhibition by these three molecules, remain a mystery.

Considering that the choroid is a highly vascularized structure that undergoes rapid changes in blood flow, it is possible that changes in choroidal thickness reflect changes in choroidal blood flow. In an early study making use of laser doppler flowmetry and high-frequency A-scan ultrasonography in young chicks, increases in blood flow were found to represent an early, transient response to myopic defocus, with the choroidal thickening being more enduring.⁶⁵ Myopia was initially induced by form deprivation, which itself led to choroidal thinning and a decrease in

blood flow. More recent studies involving young guinea pigs made use of optical coherence tomography angiography, which enables noninvasive quantification of choroidal perfusion,^{66,67} with simultaneous measurement of thickness. Using this technology with three myopia guinea pig models (spontaneous, form deprivation, and lens-induced myopia),⁶⁸ both choroidal thickness and perfusion were found to be significantly reduced in spontaneous myopia compared to nonmyopic controls, with similar findings in both form deprivation myopia and negative lens-induced myopia. Changes in choroidal thickness and perfusion were also found to be positively correlated in the latter case, with both choroidal parameters observed to subsequently increase after 4 days of recovery from form deprivation myopia.

Inference about causal relationships between altered choroidal perfusion and myopia requires further investigation. In a previous study, single-cell RNA sequencing technology of scleral cells showed that the hypoxia-inducible factor 1 α signaling pathway is activated during myopia.⁶⁹ Furthermore, antihypoxic treatments suppressed the progression of experimental myopia, suggesting that scleral hypoxia is a key modulator of scleral remodeling during myopia development.⁶⁹ In guinea pigs, intraocular injection of prazosin (an α -adrenergic antagonist) increased choroidal perfusion and also inhibited axial elongation and form deprivation myopia, as well as scleral hypoxia.⁷⁰ Antimyopia treatments such as atropine, apomorphine, and intense light, in addition to suppressing myopia progression, were also shown to increase choroidal perfusion and decrease scleral hypoxia labelled adducts.⁷⁰ In guinea pigs, both surgical and pharmacologic reductions in choroidal perfusion via temporal ciliary artery transection and phenylephrine, respectively, induced relative myopia compared to untreated eyes, with both interventions rendering the sclera hypoxic and increasing the expression of α smooth muscle actin.⁷¹ Additionally, quinpirole injections, which promoted the development of myopia, exaggerated the form deprivation myopia-associated reductions in choroidal thickness and perfusion and increased the levels of scleral hypoxia, observed via pimonidazole labeling, and α smooth muscle actin protein.⁷¹ Together, these observations suggest a plausible link between reduced choroidal blood flow, scleral hypoxia, and myopia, although the former along with typical choroidal thickness changes (i.e., thinning) can also be expected to influence the strength of any scleral-directed, retina-derived, growth-modulating signals.

In summary, there is compelling evidence in the animal literature linking the choroid to ocular growth regulation and hence to growth dysregulation and subsequent development of myopia. Further research targeting the choroid is warranted to explore the feasibility of its pharmacologic manipulation to prevent the development of myopia and to translate the findings from animal models to children.

MEASURING THE CHOROID IN HUMANS

Given the accumulating evidence from animal models regarding the involvement of the choroid in eye growth and myopia, there has been increasing interest in investigating the human choroid. Below we discuss various techniques used to quantify choroidal thickness in humans. With the choroid now attracting the attention of both researchers and clinicians, it is important to standardize methods for quantifying choroidal biometrics. To date, this has not been done

in a consistent and deliberate manner. Here, we discuss various methods used to measure choroidal thickness, speaking to the challenges and limitations of each.

Optical Biometry

Optical biometers are noncontact optical instruments based on the principle of partial coherence interferometry; some newer optical biometers utilize swept source optical coherence tomography (OCT) technology. These devices are generally used to measure axial length, defined by the axial distance from the anterior cornea to the retinal pigment epithelium (Fig. 2), and many provide several other ocular axial parameters, including corneal thickness, anterior chamber depth, and lens thickness. The axial resolution offered by optical biometers is typically on the order of 10 μ m, although averaging of multiple measures can be used to further improve performance.^{72,73} A number of studies have used changes in axial length as a surrogate for changes in choroidal thickness, based on the assumption that the axial length, defined as the distance from the cornea to the retinal pigment epithelium, will be sensitive to changes in choroidal thickness, decreasing with an increase in choroidal thickness and vice versa.^{74,75} A limitation of this approach is that changes in any other ocular component could also potentially contribute to observed axial length changes.

Access to an A-scan profile, as possible with some of the optical interferometry-based optical biometers, allows differentiation of some of the posterior ocular structures that are identified as peaks in the interferometric profile. Previous investigators⁵⁵ using this approach have also identified in some participants, in addition to the retinal pigment epithelium peak (P3) referenced in determining axial lengths, a fourth, more posterior peak (P4) that is assumed to originate from the choroid/sclera interface, thereby allowing a direct estimate of the subfoveal choroidal thickness as the distance between P3 and P4 (Fig. 2). It is important to note that this method requires conversion of the optical path length to a geometric length⁷⁶; patient alignment and the ability to identify the peaks, in particular P4, which become less visible with thicker choroids, are also limitations to be considered. Nonetheless, significant correlations between choroidal thickness measures derived from analysis of the A-scan peaks and choroidal thickness obtained using OCT-based methods have been noted.⁷⁷ However, measurement repeatability is generally superior with the latter approaches, and there are relatively wide (95%) limits of agreement between the two methods (+51 to -43 μ m), which most likely reflects the variability in locating the P4 peak in A-scan profiles.⁷⁶ Indeed, Guo et al.⁷⁸ concluded that any changes of <80 μ m in subfoveal choroidal thickness, measured with the posterior peaks derived from Lenstar biometry, may not represent real changes due to the relatively poor reliability of such choroidal thickness measurements.

Optical Coherence Tomography

The advent of OCT has transformed imaging of the posterior ocular tissue, allowing the capture of in vivo high-resolution cross-sectional images. The axial resolution of current commercially available OCT devices for measures of posterior eye tissues thickness ranges from 3.9 to 7 μ m. Advances over more recent years, including the introduction of Fourier domain architectures, eye tracking during image

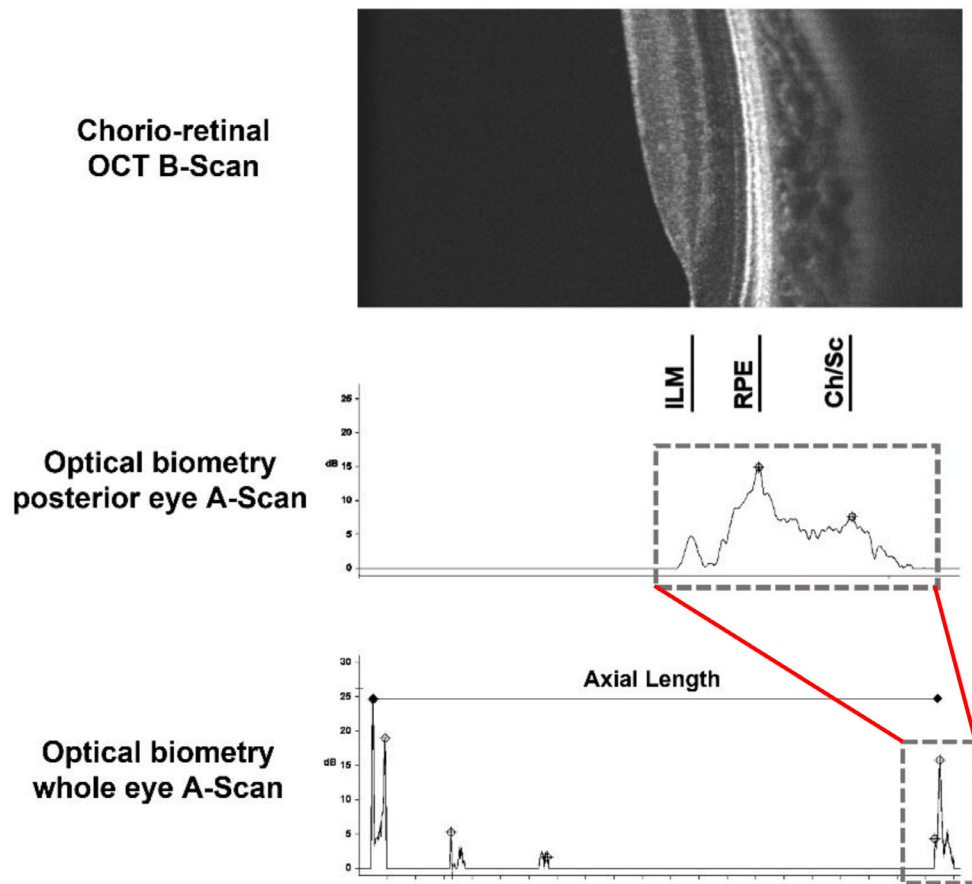


FIGURE 2. Example of an OCT B-scan (Spectralis; Heidelberg Engineering, Heidelberg, Germany; *top*) and corresponding optical biometry A-scan (Lenstar; Haag-Streit, Köniz, Switzerland for the whole eye, from which axial length is defined (*bottom*) and a closeup of the A-scan from the posterior eye (*middle*). The OCT B-scan from the same participant demonstrates concordance between the posterior peaks (RPE: P3, Ch/Sc: P4) identified in the optical biometry A-scan and the retinal and choroidal features in the OCT B-scan.

capture, and higher acquisition speeds, have allowed the capture of highly detailed images of the human choroid, with the deployment of enhanced depth imaging leading to yet further improvements (Fig. 3).⁷⁹ The latter technique makes use of a shift in the instrument's focal point to improve the visibility of deeper choroidal structures. Alternatively, the visibility of the choroid can be improved with the use of longer wavelength (e.g., 1060 nm) light sources, which provide deeper signal penetration.⁸⁰ These longer wavelengths are typically utilized in swept-source OCT devices, which make use of high-speed tunable lasers and higher scanning speeds, thereby allowing for better characterization of the deeper choroidal structures.⁸¹ Nonetheless, most commercially available OCT devices utilize shorter, near-infrared light sources, with wavelengths in the range of 820 to 870 nm.⁸²

To date, the primary metric derived from OCT images is choroidal thickness, which is typically defined as the axial distance between the posterior border of the retinal pigment epithelium and the anterior surface of the chorioscleral interface. In order to reliably derive thickness metrics from OCT, the impact of factors such as image tilt, image curvature, and the effects of ocular magnification upon the transverse scale of the OCT image needs to be considered.^{83,84} Unfortunately, as most commercial instruments also do not provide tools to automatically segment the chorioscleral interface,

many studies have had to rely on manual analysis of OCT images by trained observers.

In recent years, several methods have been proposed to automatically segment the choroid and extract thickness data from OCT images. The application in some more recent studies of deep learning algorithms,^{85,86} in place of standard image-processing methods,⁸⁷ substantially reduces analysis time, and some of these methods have shown a high level of accuracy, with mean absolute boundary errors below the instrument's resolution (e.g., 2.5 μm). However, it is worth noting that the choroid is a complex structure, and the chorioscleral boundary is also often of relatively low contrast, together making detection of its boundaries challenging. Thus, inspection of automatic segmentation outcomes and correction of errors, if present, are still recommended to improve the reliability of thickness data. This may be particularly relevant when subtle changes are anticipated, such as in studies investigating short-term choroidal changes of small magnitude (e.g., 5–10 μm).^{7,88,89}

Although choroidal thickness represents a fundamental metric to be extracted from OCT images, it does not allow understanding of within-tissue changes. The use of binarization techniques in OCT images can provide further valuable information regarding the choroidal structure. For example, a binarization technique will discriminate vascular luminal areas (hyporefectivity regions) from interstitial areas

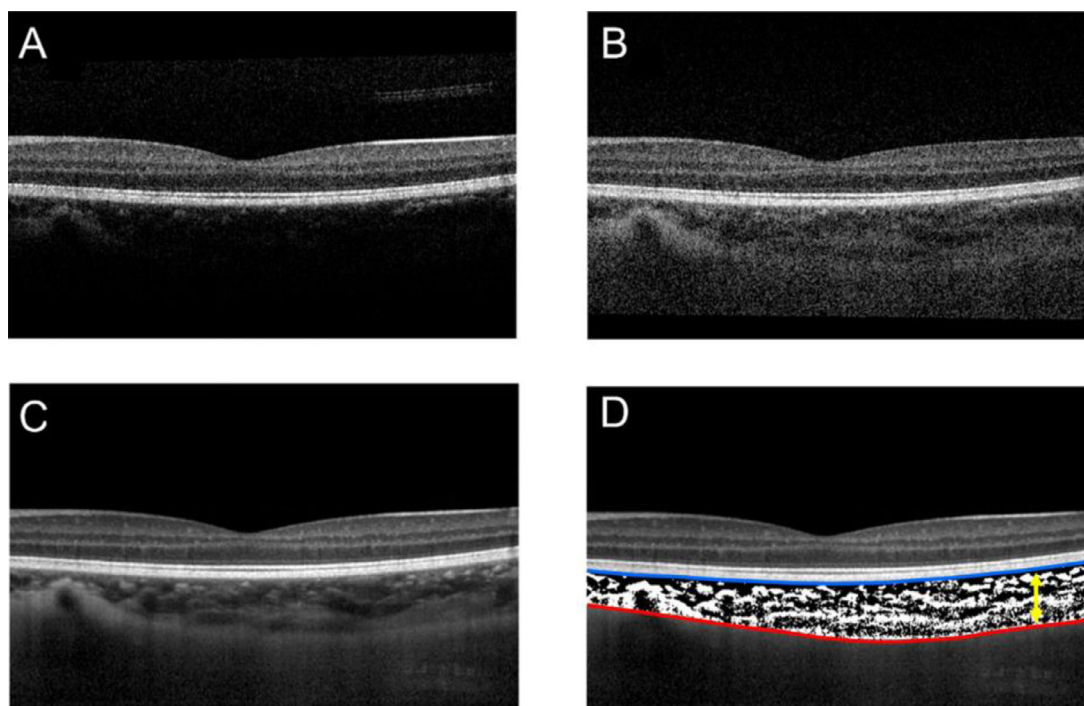


FIGURE 3. Example OCT images and analyses from a healthy young subject, including (A) a single OCT B-scan captured with standard focus, (B) a single OCT B-scan captured with enhanced depth imaging, (C) an averaged OCT B-scan captured with enhanced depth imaging (the average of 30 individual B-scans captured from the same retinal location), and (D) the same averaged OCT B-scan following segmentation analysis (to delineate the posterior boundary of the retinal pigment epithelium [blue line] and the inner boundary of the choroidoscleral interface [red line] to allow choroidal thickness [yellow arrow] to be calculated) and binarization analysis to allow the calculation of choroidal vascularity metrics (where *black pixels* indicate choroidal vascular luminal tissue and *white pixels* indicate choroidal vascular stromal tissue).

(hyperreflectivity regions) that correspond to the vascular walls and choroidal stromal connective tissue, respectively. Similar to the evolution of choroidal thickness evaluation, several studies have used traditional, local binarization methods to analyze the images,^{90,91} while more recent studies have applied deep learning strategies.⁹² Other studies have proposed automated analysis methods to delineate the medium and large vessel layers of the choroid⁹³ and to segment individual vessels within the choroid from OCT images.⁹⁴ Another relatively new parameter derived from such analyses for use in the quantitative evaluation of changes in the choroid vasculature is the choroidal vascularity index, which is defined as the ratio of vascular area to the total choroidal area, presented as a percentage.⁹⁵

Blood Flow and Perfusion Measurements

There are now a number of imaging methods that allow quantitative or qualitative assessment of the blood flow within the choroid, including laser doppler velocimetry and flowmetry, laser interferometry, and laser speckle flowgraphy.⁹⁶ These methods typically utilize a two-dimensional imaging approach, and hence the signals may include contributions from both retinal and choroidal blood flow. Thus, studies using these methods to assess the choroidal blood flow have focused on the avascular fovea, where the choroid represents the primary vasculature present.^{97,98} However, clinical use of these methods has been limited.

Indocyanine green angiography (ICGA) represents an older, albeit more invasive, technique that also provides two-dimensional en face images of the choroidal vasculature. ICGA makes use of near-infrared wavelengths for imaging, taking advantage of the better penetration of longer wavelengths through the retinal pigment epithelium. As ICG dye is strongly bound to serum proteins, it is retained with the choroidal vasculature, facilitating its visualization.⁹⁹ However, this technique has several limitations, including the need to intravenously inject a dye, a lengthy imaging time, and a lack of depth information, which is an inherent limitation of all two-dimensional imaging protocols.^{100,101}

Optical coherence tomography angiography (OCT-A) represents a functional extension of OCT and is based upon the motion contrast principle, making use of variations in OCT signal caused by moving red blood cells to capture the fine structural details of the retinal and choroidal vasculature. Postprocessing of multiple scans made at the same location is used to detect the motion of blood cells against the static tissue background components. Similar to OCT, OCT-A is a noninvasive, fast, high-resolution imaging technique. OCT-A allows three-dimensional volumetric assessment of both retinal and choroidal microvasculature, including the choriocapillaris, without the use of a dye.¹⁰² However, for the majority of commercially available OCT-A devices, the instrument's acquisition rate and signal penetration do not allow reliable capture of the deep choroidal structures, a deficiency that has been more recently overcome with the introduction of long-wavelength swept-source OCT-A devices.¹⁰³

Challenges in Quantifying Small Changes

Modern imaging methods, such as OCT, can provide high-resolution images of the choroid, thereby allowing choroidal thickness and vascular metrics to be captured.^{81,87} However, there are numerous challenges in developing consistent imaging and segmentation techniques to precisely quantify changes in choroidal thickness. The relatively small magnitude of changes reported in the many studies examining the physiological, pharmacologic, and optical influences on the human choroid highlights the need for optimized imaging and measurement protocols to provide the most reliable measurements possible. Improvements in measurement precision can be achieved through standardizing imaging protocols, the capture and averaging of multiple measurements within an experimental session, and the use of eye tracking to ensure that follow-up measurements are registered to the same location. Measurement protocols should also take into consideration known physiologic influences on the choroid, such as diurnal variations and other factors known to cause short-term choroidal changes, including variations in light exposure, accommodation, physical activity, and caffeine and alcohol intake, to limit their potential confounding influence on measurements. When analysis is performed in a manual or semimanual manner, the observer should be blinded to experimental conditions to minimize bias. Additionally, the use of validated, automated choroidal image analysis algorithms, although not currently widely available, is recommended to reduce the potential bias associated with manual analyses. With continued development, validation, and improved availability of relevant instrumentation, a reasonable goal is to

move toward standard measurement protocols and algorithms for adoption across laboratories and within clinical settings.

THE CHOROID AND REFRACTIVE ERROR IN HUMANS

With the increasing availability of high-quality instruments for in vivo imaging of the choroid and the evolving automated segmentation algorithms to calculate choroidal thickness, there are now several reports on the relationship of choroidal thickness to refractive error, particularly myopia, in humans. Table 1 provides a summary, albeit not exhaustive, of myopia-related findings from clinical choroidal studies. In general, studies in both adults^{104–107} and children^{87,108,109} have found thinner choroids to be associated with higher amounts of myopia (see reviews: Read et al.,¹¹⁰ Jonas et al.,¹¹¹ Prousalis et al.¹¹²). While fewer studies have investigated the association between choroidal thickness and axial length, longer eyes tend to have a thinner choroid,^{104,107,113–118} with studies reporting a 20- to 60- μ m thinner choroid per 1-mm increase in axial length,¹¹⁹ this rate of thinning being greater than predicted simply from axial elongation.¹²⁰ Published OCT studies have varied in the methodologies used, in terms of both instrumentation and choroidal thickness calculation protocols, with some examining only particular regions of the choroid, such as subfoveal or peripapillary regions, making interstudy comparisons challenging. In studies where relevant data are available, the reported subfoveal choroidal thickness for nonmyopic adults varies widely, from approximately 271 to

TABLE 1. Representative Studies That Have Examined Various Factors Influencing Choroidal Thickness in the Human Eye and Key Findings

First Author (Year)	Sample Size, <i>n</i>	Participant Characteristics			Factors Influencing Choroidal Thickness			
		Ethnicity	Age, y	Spherical Equivalent Refractive Error, D	Location	Axial Length	Refractive Error	Gender
Ouyang (2011) ¹³³	28	W, A, L	32.9 \pm 11.5 (20–68)	–8.0 to +2.50	T = F = N*	S > L		
Li (2011) ¹⁴¹	93	W	24.9 \pm 2.6 (20–33)	–1.43 \pm 2.9 (+4.50 to –11.25)		S > L	NM > M > HM	M > F
Chen (2011) ¹⁴²	64	A	NM = 34.8 \pm 10.8 M = 28.4 \pm 7.7 HM = 28.8 \pm 12.6	NM = –0.26 \pm 0.4 M = –3.9 \pm 1.3 HM = –9.29 \pm 3.1			NM > M > HM	
Sogawa (2012) ¹⁴³	25	A	30.1 \pm 2.8 (25–34)	–3.4 \pm 3.1 (+1.00 to –11.00)		S > L	NM > M	
Kim (2012) ¹⁴⁴	64	A	22.3 \pm 3.0 (20–25)	–3.89 \pm 2.00 (–0.13 to –8.63)	T = F > N	S > L	M > HM	No effect
Beijing Eye Study (2013) ¹⁴⁵	3468	A	64.6 \pm 9.8 (50–93)	–0.16 \pm 2.02		S > L	NM > M > HM	M > F
Read (2013) ⁸⁷	104	W, A	10–15	NM = +0.3 M = –2.4	T = F > N*	S > L	NM > M	No effect
Tan (2014) ¹¹⁹	124	A	21–33	–4.0 (+0.50 to –11.5)	T = F > N*	S > L	NM > M > HM	
Harb (2015) ¹⁰⁷	294	AA, W, L, A, M	24.3 \pm 1.4 (21–28)	–5.3 \pm 2.0 (–1.00 to –13.00)	F > T > N	S > L	M > HM	No effect
Karapetyan (2016) ¹³¹	88	AA, W, A	27.4 \pm 1.0 (20–40)	–1.2 \pm 1.4	T = F > N	S > L	NM > M	No effect
Xiong (2017) ¹⁰⁹	3001	A	11.7 \pm 3.4 (6–19)	–1.2 \pm 2.5 (+8.38 to –11.38)	T > F > N*	S > L	NM > M	No effect
Song (2021) ¹¹⁸	1619	A†	60.9 \pm 7.7	NA	T > N*	S > L		M > F
Xie (2022) ¹⁴⁶	2126	A	52.5 \pm 20.4 (18–93)	–5.3 \pm 5.4 (+7.75 to –25.5)	T > N	S > L		M > F

A, Asian; AA, African American; F, foveal; HM, high myopes; L, Latino; L, longer axial length; M, mixed; M, myopes; N, nasal; NA, not available; NM, nonmyopes; S, shorter axial length; T, temporal; W, white.

*Based on ETDRS quadrants.

†Multiethnic Asians (Chinese, Indian, Malay).

439 μm , as do values reported for highly myopic adults, from 96 to 245 μm . Refractive error-related differences have also been reported in children, with one study reporting average values of 359 μm in nonmyopic children and 303 μm in myopic children (mean spherical equivalent of approximately -2.4 D).⁸⁷

More recently, binarization analysis of OCT images has been performed to characterize the relative contribution of vascular (luminal) elements to choroidal thickness and also to differentiate the three vascular layers of the choroid, as defined above. Cross-sectional studies using this technique suggest that the reduction in choroidal thickness associated with increased axial length is due to reductions in luminal area (versus stromal area),⁹¹ with some studies further reporting relatively greater thinning in Sattler's and Haller's layers compared to the choriocapillaris.^{121–123} However, the challenge of visualizing and accurately measuring changes in the small choriocapillaris vessels and the variability in segmentation algorithms remain limitations of such studies.⁹³

There have been several reports on the possible relationship between gender and choroidal thickness, as well as others covering the influence of ethnicity, albeit far fewer. In relation to gender, there is no clear consensus, with some studies involving pediatric populations reporting either no effect of gender^{87,116,124–126} or that girls have thicker choroids,^{113,127,128} while males have been reported to have thicker choroids in some studies involving young adults (mean age 24.9 years)¹¹³ and older adults (50 years or older).^{115,118,129,130} Furthermore, no effect of gender was found in the large, multicentered Correction of Myopia Evaluation Trial (COMET) cohort, which involved adolescents.¹⁰⁷ However, the latter study did observe an effect of ethnicity, with African Americans having the thickest choroids, especially nasally, and Asians the thinnest.¹⁰⁷ While most other studies have involved relatively homogeneous Asian populations (wherein the prevalence of myopia is higher), two of three studies investigating ethnicity differences reported no differences^{131,132} and the other, thinner choroids in Malay Asians (compared to Indian or Chinese Asians).¹¹⁸

One relatively consistent observation across various studies of choroidal thickness is that the nasal choroid, typically defined as the region between the optic nerve and fovea, is as much as 100 μm thinner compared to the temporal region. This nasal-temporal asymmetry has been reported in both children with nonsignificant refractive errors^{108,127,128} and adults with a range of refractive errors.^{119,133–135} Interestingly, this nasal-temporal asymmetry appears to be exaggerated in myopic children,¹²⁵ being both larger than that recorded in nonmyopic children¹⁰⁷ and larger than the predicted effect of stretch during axial elongation.⁸⁷ The latter observations suggest that the choroidal region nasal to the fovea (i.e., between the fovea and optic nerve head) may be more vulnerable to subsequent degeneration with increasing myopia and are consistent with the fact that myopic degeneration tends to be observed more frequently clinically in this region. Thinner choroids, both in foveal¹⁰⁶ and peripapillary¹¹⁴ regions, have also been linked with posterior staphyloma in highly myopic eyes. Additionally, choroidal thickness has been shown to be a predictor of visual acuity in myopic eyes, with thinner choroids associated with lower visual acuity.^{105,129,136,137}

Choroidal thickness has also been suggested to be a biomarker for predicting future axial elongation (and thus myopia progression), with reduced axial elongation being tied to a thicker choroid,^{137,138} especially temporally.^{139;}

however, contradictory findings have also been reported.¹⁴⁰ Further research into the possible roles of the choroid in human myopia development and related pathologies is surely warranted, with the adoption of more standardized approaches to evaluating choroidal thickness being key to disentangling the effects of the many confounders that influence it.

CLINICAL APPLICATIONS OF CHOROIDAL IMAGING

There is no clear consensus on the role of choroidal imaging in the clinical management of myopia. In addition, for most clinicians, there remain significant barriers to measuring choroidal thickness, and current approaches are both challenging and time-consuming. For example, visualization of the choriocapillaris interface must be first optimized, and automated segmentation algorithms, as utilized in human myopia research, often require intervention in the form of manual corrections and are not commercially available. Also, as already discussed and considered further below, there are several confounding influences on choroidal thickness, making interpretation of data challenging. However, OCT imaging of the posterior segment is increasingly being included in myopia clinical trials (see review: Wolffsohn et al.¹⁴⁷), with choroidal thickness included as an outcome measure. Likewise, this imaging modality is becoming the standard of care for the myopic patient. As outlined in the International Myopia Institute (IMI) white paper on pathologic myopia,¹⁴⁸ OCT imaging is essential in the diagnosis of myopia-related maculopathies (e.g., dome-shaped macula, myopic traction maculopathy), with wide-field imaging allowing for better visualization and classification of staphylomas.

Choroidal thinning and the eventual formation and enlargement of holes in Bruch's membrane in the macular region represent the histopathology of high myopia as it progresses to pathologic myopia.¹⁴⁸ A recently developed OCT-based classification system for myopic maculopathy now allows the different types of myopic pathologies of the macula to be differentiated in a more accurate and objective way (see IMI white paper).¹⁴⁸

SHORT-TERM INFLUENCES ON CHOROIDAL THICKNESS

As discussed above, studies involving animal models have shown the choroid to be dynamic, with changes in its thickness observed in a matter of minutes in response to various physiologic, pharmacologic, optical, and environmental cues. Over the past couple of decades, there has been increasing evidence that the human choroid also undergoes dynamic thickness changes, although the changes are smaller and so more challenging to quantify than in animals. In young adults, short-term choroidal thickness changes are generally on the order of 5 to 30 μm , which, given the reciprocal changes in axial length, correspond to an optical change of approximately 0.02 to 0.1 D. Hence, these choroidal changes do not result in a perceptible change in retinal image quality but rather suggest the influence of some biological cascade targeting the choroid.

In order to rigorously study such changes in human choroidal thickness, it is important to consider the short-term modulatory influences that represent confounding factors. To this end, in choroid-related studies, it has become

standard to ask participants to refrain from intake of caffeine and alcohol before an experiment, to measure participants at a consistent time of day, and to include an initial “washout” period in which participants sit in standardized lighting and view a distant target before starting an experiment. The evidence regarding various physiologic and pharmacologic influences on choroidal thickness is summarized in the following sections.

Physiologic Influences

Now recognized physiologic influences on choroidal thickness are summarized in Table 2. It is well established that the human choroid undergoes diurnal variations in thickness.^{3,55,56} These diurnal variations in choroidal thickness, in concert with variations in axial length, may play a role in the regulation of eye growth and the development of refractive errors.⁵⁷ Using partial coherence interferometry to track choroidal thickness over a 15-hour period, Brown et al.⁵⁵ reported the first evidence that the human choroid undergoes diurnal variations. Their early observation has

since been confirmed using optical coherence tomography to track choroidal thickness in both adults and children; both showed robust diurnal variations over a 24-hour period, with an amplitude of approximately 25 μm and thickness peaking between approximately 2:00 AM and 4:00 AM and reaching a minimum at approximately 12:00 PM (Fig. 4).^{3,149,159} Of note, choroidal thickness variations were shown to be in antiphase with axial length and intraocular pressure rhythms.

Given that physical activity is known to alter blood flow in a variety of organs and tissues, choroidal effects would seem plausible. However, while early studies showed changes in choroidal blood flow with exercise as measured with laser Doppler flowmetry,¹⁶⁰ most studies examining ocular parameters shortly after physical exercise did not detect significant changes in choroidal thickness,^{151,161–164} with the exception in some studies of a temporary choroidal thickening a few minutes after exercise, followed by a reduction in thickness.^{4,150} On the other hand, thinning of the choroid was observed after endurance exercise (marathon running).¹⁶⁵

Water intake appears to influence choroidal thickness, by mechanisms that are not fully understood yet. Most studies made use of the water drinking test, a diagnostic tool used to study aqueous outflow in patients with glaucoma, in which systemic and ocular parameters are examined before and at defined time points after drinking 1 L of water within 5 minutes.^{166,167} Studies have shown choroidal thickening in healthy participants, as well as in patients with glaucoma,^{156,157,168–171} often followed by a rise in intraocular pressure, while retinal thickness seems not to change significantly.¹⁵⁶ One of these studies, using enhanced depth imaging OCT followed by binarization analysis, detected dilated choroidal vessels, offering a possible explanation for the choroidal thickening observed in healthy participants.¹⁵⁶ Another more recent study evaluated the choroidal responses of highly myopic and emmetropic eyes to the water drinking test and found no statistically significant changes related to the water drinking test in either group, although as expected, the choroids of highly myopic eyes were significantly thinner than those of emmetropic eyes.¹⁷²

Since the choroid is known to play an important modulatory role in ocular thermoregulation,¹⁷³ it has been speculated that ambient temperature may affect choroidal

TABLE 2. Studies of Physiologic Factors That Have Been Linked to Short-Term Subfoveal Choroidal Thickness Changes in the Human Eye, Along With Key Details and Findings

Short-Term Factor	Measurement Technique	Effect on Choroidal Thickness
Diurnal rhythm	OCT imaging every 4 hours for 24 hours in children and adults	25- to 27- μm diurnal variation ^{3,149}
Physical activity	OCT imaging immediately after and up to 15 minutes after 10 minutes of exercise	10- to 26- μm increase that returned to baseline 10–15 minutes after exercise ^{4,150} No change ¹⁵¹ No change ^{152–155}
Water intake	OCT imaging after 1 L water intake within 5 minutes	3- to 15- μm increase ^{156,157}
Pregnancy	OCT imaging in healthy pregnancies	40- to 96- μm increase ¹⁵⁸

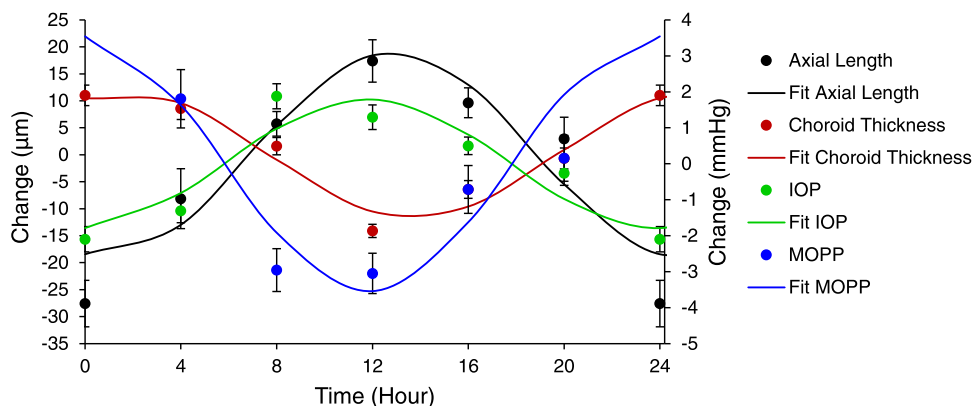


FIGURE 4. Mean (\pm standard error) 24-hour change in axial length (μm , black), choroidal thickness (μm , red), IOP (mm Hg, green), and mean ocular perfusion pressure (MOPP, mm Hg, blue) for children ages 10.06 ± 2.53 years, with spherical equivalent refractive errors of $+0.35 \pm 0.38$ D ($n = 18$); solid lines are cosinor fits to the data. Figure reproduced with permission from Ostrin LA, Jnawali A, Carkeet A, Patel NB. Twenty-four hour ocular and systemic diurnal rhythms in children. *Ophthalmic Physiol Opt.* 2019;39(5):358-369. © 2019 The College of Optometrists.

thickness. In skin, vasoconstriction is observed in response to cold temperatures, whereas vasodilation occurs in warmer temperatures.¹⁷⁴ However, there is no evidence that the choroid is influenced by ambient temperature, although it is possible that the choroid is under homeostatic control to maintain a consistent temperature.

Pregnancy has widespread effects on the body, influencing all organ systems, which include changes in metabolism, immune function, and hormones, such as steroid hormone, peptide hormone, and prostaglandins, that interact to expand blood and plasma volume.¹⁷⁵ The eye is not exempted from these anatomic and physiologic changes. Studies have shown, for example, increases in central corneal thickness, changes in corneal curvature, and decreases in IOP and corneal sensitivity, overall, with these changes being mostly physiologic and transient (see reviews: Khong et al.,¹⁷⁶ Anton et al.,¹⁷⁷ Roskal-Walek et al.¹⁷⁸). Given that the choroid is one of the most highly vascularized tissues of the body, with a high blood flow to tissue volume ratio, it may be susceptible to hemodynamic and hormonal changes during pregnancy. Studies have investigated choroidal thickness at different time points in uncomplicated pregnancy, with most studies being cross-sectional in nature^{179,180} and reporting either thickening or no change

in choroidal thickness in pregnancy compared to nonpregnant age-matched women. However, while a meta-analysis determined the choroidal thickness of healthy pregnant women to be significantly higher than that of the nonpregnant women,¹⁸¹ other studies have reported choroidal thinning over time from the first to third trimesters.^{152–155,158} On the other hand, choroidal thickening has been linked to complicated pregnancies. For example, diabetic pregnant females were found to have thicker choroids compared to nondiabetic pregnant women,¹⁸² and preeclampsia has also been linked with choroidal thickening, which seemed to be correlated with severity of the disease.^{183,184}

Pharmacologic Agents

Given the complex structure of the choroid, as well as its biomechanical and physiologic relationships with nearby structures, it is perhaps not surprising that a variety of pharmacologic agents have been shown to exert effects on the choroid. Several agents have been examined with respect to their effects on choroidal thickness, providing potential insight into receptor types localized within the choroid. Key findings are summarized in Table 3.

TABLE 3. Summary of Studies Examining Pharmacologically Induced Short-Term Subfoveal Choroidal Thickness Changes in the Human Eye

Pharmacologic Agent	Mechanism of Action	Protocol	Effect on Choroidal Thickness
Atropine 0.01%	Nonspecific muscarinic antagonist	OCT imaging 30 and 60 minutes after topical instillation	6- μ m increase at 60 minutes ¹⁸⁵
Homatropine 2%	Nonspecific muscarinic antagonist	OCT imaging 30 and 60 minutes after topical instillation	14- μ m increase at 60 minutes ⁶⁴
Tropicamide 1%	Nonspecific muscarinic antagonist	OCT imaging 40–55 minutes after topical instillation	22- to 26- μ m decrease ^{186,187}
Cyclopentolate 1%	Nonspecific muscarinic antagonist	OCT imaging 40–55 minutes after topical instillation	No change ¹⁸⁸ 20- μ m decrease ¹⁸⁷
Pilocarpine 2%	Nonspecific muscarinic agonist	OCT imaging 30 minutes after topical instillation	No change ¹⁸⁹ 22- μ m increase ¹⁸⁸ 22- μ m increase ¹⁸⁹
Phenylephrine 2.5%	α 1-adrenergic agonist	OCT imaging 30 and 60 minutes after topical instillation OCT imaging 45–50 minutes after topical instillation OCT imaging 30 minutes after topical instillation	No change at 60 minutes ⁶⁴ 17- to 25- μ m decrease ^{186,187} 10- μ m decrease ¹⁹⁰
Caffeine	Adenosine receptor blocker	OCT imaging 60 minutes after 25 cl (pharmacologically) Red Bull intake containing 80 mg caffeine, 1 g of taurine, vitamin B, sucrose, and glucose OCT imaging 30 minutes to 4 hours after 57–75 mg caffeine in coffee or a 200-mg capsule	14- μ m decrease ¹⁹¹ 25- to 50- μ m decrease up to 4 hours ^{5,192–195}
Nicotine	Nicotinic acetylcholine agonist	OCT imaging 5–30 minutes after tobacco cigarette and electronic cigarette smoking OCT image 60 minutes after 4 mg nicotine gum	No change ¹⁹⁶ No acute changes ¹⁹⁷ 50- μ m decrease ¹⁹⁸
Alcohol	Indirect GABA agonist	OCT imaging 1–2 hours after red wine intake (1.0 mg/kg of ethanol in 14.0% red wine)	25- μ m increase at 1 hour, return to baseline at 2 hours ¹⁹⁹

Nonselective muscarinic antagonists, including atropine, are among drugs targeted in pharmacologic studies of the human choroid. Atropine is of particular interest because of its increasing use for controlling myopia progression, despite there being no general agreement on the site and mechanism of action mediating the effect. Several studies have examined the effects on choroidal thickness of topical atropine and homatropine,^{64,200–202} with most studies reporting choroidal thickening, as examined in the short term (1 hour to 1 week), as well as long term (6 months to 2 years).^{200–202} In addition, both atropine and homatropine have been shown to prevent the choroidal thinning induced by imposed hyperopic defocus,^{185,203} leading to speculation that inhibition of signals generated by hyperopic defocus, including lag of accommodation during near work, may underlie or contribute to the myopia control effect of atropine. While curiously, 0.01% atropine concentration, as often used for myopia control, was shown to induce choroidal thinning,²⁰² choroidal thickening was observed in children after 6 months of daily topical 1% atropine in one study, with the 2-year data from the LAMP study confirming the latter observation and also showing a concentration-dependent (0.01%–0.05%) thickening of the choroid, evident at the first 4-month time point and sustained thereafter.²⁰⁰ Nonetheless, short-term choroidal thinning has also been reported with 1% tropicamide.¹⁸⁶ The origin of these contrasting effects on choroidal thickness of atropine and homatropine compared to 1% tropicamide may be related pharmacokinetic factors, including differences in their intraocular distribution.

Pilocarpine is a muscarinic agonist that induces accommodation and miosis. Croft et al.⁴³ reported that 4% pilocarpine led to choroidal thinning in the peripapillary region in adults. However, in another study in which the effects of 2% pilocarpine on subfoveal choroidal thickness, as well as 1% cyclopentolate, another antimuscarinic drug, were assessed 30 minutes after instillation in young adults,¹⁸⁹ choroidal thickening was observed with pilocarpine (22- μ m increase) and no change with cyclopentolate. The pilocarpine result in the latter study is somewhat paradoxical, as axial lengths were also observed to increase (by approximately 30 μ m), as is typically linked to and reciprocal with choroidal thinning. Nonetheless, given that pilocarpine also stimulates accommodation, it is possible that induced optical changes in the lens confounded measurements. With respect to cyclopentolate, another study reported an approximate 20- μ m decrease in choroidal thickness,¹⁸⁷ and yet another study reported a 22- μ m increase,¹⁸⁸ adding further to the confusing picture as it relates to the choroidal effects of antimuscarinic drugs.

Phenylephrine, a selective α 1-adrenergic agonist, is a commonly used clinical mydriatic agent, like tropicamide. While it is hypothesized that adrenergic stimulation may lead to choroidal thinning due to its vasoconstrictor action (via α 1 receptors on vascular muscle cells), variable effects of phenylephrine on choroidal thickness have been described, with one study reporting choroidal thinning and others reporting no change.^{64,186,204} The possibility that phenylephrine may have also affected the nonvascular smooth muscles cells of the choroid cannot be ruled out, with the role of these cells also being not well understood.

Numerous studies have evaluated the influence of oral caffeine on choroidal thickness, with most reporting acute choroidal thinning lasting up to 4 hours after ingestion.^{191–194} However, a more recent study found no effect of

compounded 200-mg caffeine pills on the choroid compared to a placebo.¹⁹⁶ Caffeine, a common dietary supplement, found in coffee, tea, and other caffeine-containing foods and beverages, is an adenosine receptor antagonist. Given its widespread consumption, it is important to consider the potential confounding effects of caffeine in studies of choroidal thickness, even though most studies indicate that participants were asked to refrain from caffeine beverages before and during experimental sessions. Both topical caffeine and oral 7-methylxanthine (a metabolite of caffeine) have recently been shown effective in slowing experimental myopia in rhesus monkeys,^{205,206} implicating adenosine receptors in eye growth and myopia. Interestingly, both daily topical caffeine and oral 7-methylxanthine resulted in increased choroidal thickness in monkeys after 6 months, in apparent contradiction to reported short-term thinning with oral caffeine in humans. In the case of caffeine, these findings raise the possibility of differences between acute and chronic effects on the choroid; it is important to consider how the delivery route and, for human participants, habitual consumption patterns might influence choroidal physiology and thickness changes.

The influence of nicotine on choroidal thickness has previously been examined following smoking tobacco, smoking electronic cigarettes, and chewing tobacco gum. Nicotine binds to nicotinic acetylcholine receptors, which have been shown to be present in both the retina and choroid.²⁰⁷ In one relevant study, no acute changes in thickness were observed after tobacco and electronic cigarette smoking,¹⁹⁷ while in another study, a 50- μ m decrease in thickness was observed 1 hour after chewing tobacco gum.¹⁹⁸ However, participants in the former study were habitual smokers, while those in the latter study were nonsmokers, offering a plausible explanation for these different outcomes. Similar to caffeine, most studies have asked participants to refrain from smoking for some period before, as well as during, choroid-related experiments. Alternatively, some studies have excluded habitual smokers. The above contrasting findings call into question the wisdom of asking participants to modify their behavior for such studies.

Alcohol acts as an indirect γ -aminobutyric acid agonist, which is known to cause central and peripheral vasodilation,²⁰⁸ with additional pleotropic actions, mediated in part by its various metabolites. In one study examining the acute effect of alcohol on choroidal thickness, 1.0 mg/kg of ethanol (14.0% in red wine) was administered orally over 10 minutes,¹⁹⁹ leading to a 25- μ m increase in choroidal thickness at 1 hour and a return toward baseline at 2 hours. The control condition, which involved drinking the same volume of water, was without effect.

Optical and Environmental Cues and Links With Ocular Accommodation

As discussed above, predictable changes in choroidal thickness in response to imposed monocular retinal image defocus have been well established in animal models of eye growth, with bidirectional choroidal responses to defocus occurring rapidly and correlating with both the sign and magnitude of imposed blur.^{1,47} These choroidal changes have been documented to occur in numerous animal species^{209–212} and to precede longer-term axial length changes. There is also evidence that defocus and other visual stimuli lead to choroidal changes in humans. A summary of

TABLE 4. Summary of Studies of Subfoveal Choroidal Thickness Changes Induced by Short-Term Manipulation of Visual Conditions in the Human Eye

Variable	Imposed Conditions	Measurement Technique	Effect on Choroidal Thickness*
Defocus	Myopic defocus (+2.0 to +3.0 D lens)	OCT imaging after 60 minutes	12- to 20- μ m increase ^{76,213}
	Hyperopic defocus (−2 D to −3.0 D lens)	OCT imaging after 60 minutes	20- μ m decrease ²¹³
Accommodation	Fixation at near point	Derived from Lenstar choroid peaks	No change ⁷⁶
	Reading at a 6 D accommodative demand	PCI biometer for axial length	Axial elongation of 5–13 μ m ²¹⁴
		OCT imaging after 10 minutes	5- μ m decrease ⁴⁴
Light intensity	1000 lux	OCT imaging after 120 minutes via light-emitting glasses between 9:00 AM and 12:00 PM	9- μ m increase ²¹⁵
	6,000–50,000 lux	OCT imaging after 120 minutes of outdoor sunlight beginning at 9:00 AM	6- μ m decrease ²¹⁶
Wavelength	Narrowband long wavelength	OCT imaging after 60-minute exposure to red LEDs	6- μ m decrease compared to blue light ⁶
	Narrowband short wavelength	OCT imaging after 60-minute exposure to blue LEDs	6- μ m increase compared to red light ⁶
Text polarity	Black text on white/gray background, OFF pathway stimulation	OCT imaging after 60 minutes of reading	9- to 16- μ m decrease ^{88,217}
	White text on black/gray background, ON pathway stimulation	OCT imaging after 60 minutes of reading	11- μ m increase ⁸⁸
Virtual reality	Virtual reality headset	OCT imaging after 40 minutes in virtual environment	0- to 10- μ m increase ²¹⁸
		OCT imaging after 2 hours in virtual environment	No change ²¹⁹

PCI, partial coherence tomography.

* All findings are changes in choroidal thickness except where indicated as changes in axial length.

relevant studies involving optical and environmental stimuli and choroidal thickness measurements in the human eye is presented in Table 4.

The first evidence that the human choroid can respond to retinal image defocus came from a study in which small reductions and increases in axial length were captured in young adults, in response to 60 minutes of monocular myopic and hyperopic defocus, respectively, using optical biometry.⁷⁶ These axial length changes were likely driven by changes in choroidal thickness. Using OCT imaging to directly monitor choroidal thickness in a closely related study, significant increases in subfoveal choroidal thickness with exposure to myopic defocus and reductions in thickness in response to hyperopic defocus were observed.²¹³ Similar, short-term bidirectional choroidal changes in response to imposed myopic and hyperopic defocus have also been demonstrated in children.²²⁰

The time course of the human eye's response to imposed optical defocus was more recently examined through serial axial length measurements during exposure to myopic and hyperopic defocus.⁷⁴ The response to defocus was found to be rapid, with significant increases in axial length detectible after as little as 2 minutes of imposed hyperopic defocus. While reductions in axial length with myopic defocus were slower in development, reductions reached significance after 40 minutes. Recovery from such changes was also rapid, with axial length returning to near-baseline levels only 2 minutes after defocus stimuli were removed. The rapid onset and recovery from these changes highlight the need for fast and efficient imaging procedures to reliably capture the choroidal and corresponding axial length changes in response to imposed defocus.

While most studies have been limited to short-term (1- to 2-hour) evaluations of changes in the human choroid in response to defocus, two other studies examined such changes over a 12-hour period in young adults.^{7,8} As in the short-term studies, significant increases and decreases in choroidal thickness were documented with myopic and hyperopic defocus, respectively. The longer 12-hour studies also revealed evidence of defocus-induced changes to the normal diurnal choroidal thickness rhythm; specifically, with myopic defocus, there was a significant phase shift, whereas hyperopic defocus resulted in an increase in amplitude. The time of day of defocus exposure has also been shown to influence the human choroid's response to optical defocus, suggesting an interaction between endogenous diurnal and defocus-driven influences.²²¹

Most of the studies to date examining the response of the human choroid to defocus have used simple, full-field spherical optical blur. However, a small number of studies have examined the response of the human eye to more complex patterns of defocus. In one such study, a 60-minute period of exposure to hemifield myopic defocus was found to result in a local regional choroidal thickening, with the thickening response largely localized to the region of the choroid exposed to blur, confirming that the human choroid is capable of a local, regional response to imposed blur.⁸⁹ The choroid has also been shown to be sensitive to short-term exposure (60 minutes) to astigmatic blur, with the thickness changes varying depending on the axis of imposed astigmatic blur²²²; specifically, significant choroidal thickening was observed in response to +3.0 D with-the-rule astigmatic defocus, contrasting with significant thinning in response to +3.0 D against-the-rule astigmatic defocus.

In optical defocus studies that have included both myopic and emmetropic participants, most have not reported any significant differences in choroidal responses to defocus associated with refractive error.^{74,76,213} However, an exception is a recent study that compared axial length changes (as a surrogate for choroidal thickness) in myopes and emmetropes after viewing movies with binocular myopic defocus, imposed with +2.5 D optical lenses. Here, only emmetropic participants showed a reduction in axial length, with myopes showing an increase in axial length instead, suggesting a loss of ability to decode the sign of defocus on the part of the myopic participants.⁷⁵

Associations between ocular accommodation, both voluntary and pharmacologically induced, have also been investigated, with conflicting findings. For example, an early study in young adult emmetropes and myopes using partial coherence tomography showed that during a maximum accommodative effort, elicited by bringing a target as close to the eye as possible with no reported blur, axial length increased.²¹⁴ In a more recent study using OCT to directly measure choroidal changes during accommodation, significant thinning was observed in young adults in response to a 6 D accommodative demand, with an amplitude of change on the order of 5 μm ; however, no significant changes were observed with a smaller, 3 D accommodative demand.⁴⁴ When the effects of accommodation were measured in combination with down gaze, as opposed to primary gaze, axial length (an assumed surrogate for choroidal thinning) was observed to increase by 23 μm after 10 minutes.²²³ The authors of the latter study speculated that repeated small increases in axial length, or decreases in choroidal thickness, could lead to long-term eye growth (i.e., accommodation, particularly in downgaze, could be myopiagenic). As noted earlier, pharmacologic stimulation of accommodation has been variously reported to induce both peripapillary choroidal thinning (after instillation of 4% pilocarpine)⁴³ and subfoveal choroidal thickening (after instillation of 2% pilocarpine).¹⁸⁹ While the latter finding is opposite of that with voluntary accommodation, it is possible that pilocarpine also acts directly on the choroid. For studies involving voluntary accommodation, lag of accommodation, which corresponds to imposed hyperopic defocus, represents an additional confounding and typically unquantified variable.

The growing evidence that exposure to outdoor light is protective for myopia in children has prompted studies examining the choroidal effect of light intensity, with interest in the spectral composition of light being driven in part by studies in monkeys showing that narrowband red light rearing prevents experimental myopia.²²⁴ Recent studies in humans aimed at understanding if the choroid may be involved in such protective effects have been largely short term in nature. In one such study, Read et al.²²⁵ reported a 5- μm increase in choroidal thickness following 7 days of morning light therapy, each of 30-minute duration and involving commercially available light therapy glasses, which directed blue-green light (peak wavelength 500 nm) of illuminance 506 lux toward the eye. While the pattern of diurnal variation in choroidal thickness was found to be similar at baseline and after the 1 week of therapy, there was an overall increase in choroidal thickness of 5 μm across the day that was evident at most of the sampled time points (3-hour intervals from 9:00 AM to 9:00 PM). Interestingly, choroidal thickening was also reported in children in an unrelated

study involving an intensive outdoor activity program for 1 week.²²⁶ On the other hand, young adults who spent 2 hours outdoors in high-intensity light exhibited choroidal thinning, with values returning to baseline within 1 hour of returning to normal indoor light levels.²¹⁶ Yet another study reported choroidal thickening following 2 hours of exposure to 1000 lux via light-emitting glasses.²¹⁵ In relation to red light exposure, two studies have reported choroidal thinning after 1 hour of exposure to red light,^{6,227} while another reported choroidal thickening in children undergoing 12 months of long-wavelength red light therapy for myopia, comprising 3 minutes of exposure twice a day.²²⁸ The inconsistency of trends described here suggests that short-term choroidal changes may not be a reliable biomarker for predicting the longer-term effects on choroidal thickness (and potential relationships with ocular growth) in response to various lighting conditions, such as outdoor light or narrow-band wavelength exposure. Of note, because the specifications of light sources used in many such studies are not fully described, the interpretation and comparisons in retinal “light dosing” across studies are not possible.

Results from animal studies indicate that the relative activity of ON and OFF retinal pathways (i.e., that respond to light increments and decrements, respectively) influences eye growth and thus the risk of myopia development.^{229,230} They have also provided motivation for studies examining the effects of overstimulation of these retinal pathways upon choroidal thickness in humans. Thus, it was reported that overstimulation of OFF pathways by asking young adult participants to view dark text on a bright background resulted in significant thinning of the choroid, while viewing text of the reverse polarity (i.e., bright text on a dark background to overstimulate ON pathways) resulted in choroidal thickening.⁸⁸ Enlarging the text enhanced these polarity-dependent effects on choroidal thickness, which have been documented in both myopes and emmetropes.⁷² Accommodation-induced choroidal thinning was also exaggerated by conditions that overstimulated the OFF pathways.²¹⁷ As an alternative to the use of text as stimuli, luminance has been modulated temporally to overstimulate either ON or OFF retinal pathways, with similar bidirectional changes in choroidal thickness observed.²³¹ Note that these studies have all involved short-term exposures, and while it has been hypothesized that the polarity of text read may contribute to or inhibit the development of myopia (dark text on bright background versus bright text on dark background),⁸⁸ longer-term studies are required to examine this hypothesis.

With the increasing popularity of virtual reality, head-mounted displays for gaming and education, the question of whether their use may impact choroidal thickness is of relevance. The image in virtual reality headsets is optically corrected to simulate distance viewing but is physically very close to the eyes. Of two relevant studies, one reported no change in choroidal thickness following use of a virtual reality smartphone-based head-mounted display for 2 hours,²¹⁹ while in the second study, up to a 10- μm increase in choroidal thickness was observed following 40 minutes of immersion in virtual environments, with the size of the effect varying with the type of virtual environment (indoor versus outdoors).²¹⁸ Based on the latter results, it was concluded that virtual reality headsets may not represent a myopiagenic stimulus, despite the physically close viewing distance.²¹⁸

IMPLICATIONS OF CHOROIDAL THICKNESS MODULATION FOR EFFICACY OF MYOPIA CONTROL

An accumulating list of myopia control interventions involves manipulation of retinal defocus, including orthokeratology, defocus incorporated multiple segments spectacles, spectacle lenses with highly aspherical lenslets, and dual-focus contact lenses (e.g., MiSight).²³² Other myopia control interventions include pharmacologic agents, including atropine and 7-MX, and environmental manipulations, such as increasing time outdoors²³³ or repeated low-level red light therapy.²³⁴ Increasingly, the effects of these interventions on choroidal thickness have become the focus of related studies.^{235–237} Measurements of choroidal thickness up to a month (1–4 weeks) following the initiation of optical myopia control treatments in myopic children have captured significant increases in choroidal thickness associated with a number of optical, myopia control treatments compared to children in traditional single-vision myopia correction,^{237–241} with evidence of sustained effects (i.e., thicker choroid) over 12 to 24 months of treatment in some cases.^{235,239,240} Furthermore, in the case of orthokeratology, the change in choroidal thickness after 1 month of lens wear was found to be associated with the degree of axial elongation observed over 12 months, suggesting that the shorter-term 1-month choroidal responses may be predictive of myopia control efficacy.²³⁹ Both increased light exposure (i.e., outdoor time) and red light therapy have also been associated with long-term increases in choroidal thickness,²²⁸ although the initial short-term response (1–2 hours) appears to be choroidal thinning.^{6,216} It is important to note that there is currently insufficient evidence to either support or refute the hypothesis that changes in choroidal thickness to short-term optical or environmental cues (i.e., 1-hour exposures) are reliable predictors of longer-term changes in axial length and thus whether a stimulus is myopiagenic or protective, as a marker of efficacy for myopia control treatments.

SUMMARY AND CONCLUSIONS

There is accumulating strong evidence that the human choroid is sensitive to numerous physiologic, optical, and pharmacologic factors, which together serve to modulate its thickness in a bidirectional manner. While studies involving the human choroid have been largely short term in nature, the potential significance of these various observations cannot be ignored, given the convincing evidence from animal model studies for local ocular growth regulation, combined with the strategic position of the choroid between the retina, the presumed source of growth-modulating signals, and the sclera, whose remodeling and growth define eye length. Among the questions yet to be resolved are the following: (1) what is the exact nature of the choroid's role in eye growth regulation, a signal relay, a diffusion barrier, or both? (2) Do observed short-term changes in the thickness of the human choroid, as summarized here for a variety of conditions, translate into more enduring changes in the rate of ocular growth? (3) Are the associations of thicker choroids with shorter eyes and/or less myopic refractive errors and, conversely, thinner choroids with longer eyes and/or more myopia causal or a by-product of altered growth? Additionally, conflicting findings across studies to various short- and long-term optical and pharmacologic interventions highlight the need for consensus on measurement protocols, combined with more rigorous study designs and a call for

investigators to be transparent in describing protocols and to acknowledge potential confounding variables. Answers to at least some of these questions and the potential application of short-term choroidal thickness changes as a biomarker of future ocular growth are likely to be obtained sooner rather than later due to the rapid advances in ophthalmic imaging technologies combined with the worldwide attention on myopia, with due recognition of its potential for blinding complications.

Acknowledgments

Special thanks to Jost Jonas for harmonization of this white paper.

Supported by the International Myopia Institute. The publication and dissemination costs of the International Myopia Institute reports were supported by donations from the Brien Holden Vision Institute, Carl Zeiss Vision, CooperVision, Essilor-Luxottica, Hoya, Thea, Alcon, and Oculus.

Disclosure: **L.A. Ostrin**, Meta (F); **E. Harb**, Google (C); **D.L. Nickla**, None; **S.A. Read**, CooperVision (F), Dopavision GmbH (F); **D. Alonso-Caneiro**, None; **F. Schroedl**, None; **A. Kaser-Eichberger**, None; **X. Zhou**, None; **C.F. Wildsoet**, CooperVision (C), Google (C), Alcon (F)

References

- Wallman J, Wildsoet C, Xu A, et al. Moving the retina: Choroidal modulation of refractive state. *Vis Res*. 1995;35:37–50.
- Nickla DL, Wallman J. The multifunctional choroid. *Prog Retin Eye Res*. 2010;29:144–168.
- Burfield HJ, Patel NB, Ostrin LA. Ocular biometric diurnal rhythms in emmetropic and myopic adults. *Invest Ophthalmol Vis Sci*. 2018;59:5176–5187.
- Sayin N, Kara N, Pekel G, Altinkaynak H. Choroidal thickness changes after dynamic exercise as measured by spectral-domain optical coherence tomography. *Indian J Ophthalmol*. 2015;63:445–450.
- Kocak N, Beldagli C, Yeter V. Acute effects of coffee on peripapillary and subfoveal choroidal parameters in young healthy subjects. *Eur J Ophthalmol*. 2022;32(6):3584–3591.
- Lou L, Ostrin LA. Effects of narrowband light on choroidal thickness and the pupil. *Invest Ophthalmol Vis Sci*. 2020;61:40.
- Chakraborty R, Read SA, Collins MJ. Monocular myopic defocus and daily changes in axial length and choroidal thickness of human eyes. *Exp Eye Res*. 2012;103:47–54.
- Chakraborty R, Read SA, Collins MJ. Hyperopic defocus and diurnal changes in human choroid and axial length. *Optom Vis Sci*. 2013;90:1187–1198.
- Alm A, Nilsson SF. Uveoscleral outflow—a review. *Exp Eye Res*. 2009;88:760–768.
- Platzl C, Kaser-Eichberger A, Benavente-Perez A, Schroedl F. The choroid-sclera interface: An ultrastructural study. *Heliyon*. 2022;8:e09408.
- Fields MA, Del Priore LV, Adelman RA, Rizzolo LJ. Interactions of the choroid, Bruch's membrane, retinal pigment epithelium, and neurosensory retina collaborate to form the outer blood-retinal-barrier. *Prog Retin Eye Res*. 2020;76:100803.
- Alm A, Bill A. Ocular and optic nerve blood flow at normal and increased intraocular pressures in monkeys (*Macaca irus*): A study with radioactively labelled microspheres including flow determinations in brain and some other tissues. *Exp Eye Res*. 1973;15:15–29.

13. Gelman S, Cone FE, Pease ME, Nguyen TD, Myers K, Quigley HA. The presence and distribution of elastin in the posterior and retrobulbar regions of the mouse eye. *Exp Eye Res.* 2010;90:210–215.
14. Quigley HA, Dorman-Pease ME, Brown AE. Quantitative study of collagen and elastin of the optic nerve head and sclera in human and experimental monkey glaucoma. *Curr Eye Res.* 1991;10:877–888.
15. De Stefano ME, Mugnaini E. Fine structure of the choroidal coat of the avian eye: Vascularization, supporting tissue and innervation. *Anat Embryol (Berl).* 1997;195:393–418.
16. May CA. Non-vascular smooth muscle cells in the human choroid: Distribution, development and further characterization. *J Anat.* 2005;207:381–390.
17. Poukens V, Glasgow BJ, Demer JL. Nonvascular contractile cells in sclera and choroid of humans and monkeys. *Invest Ophthalmol Vis Sci.* 1998;39:1765–1774.
18. Cioanca AV, Wu CS, Natoli R, et al. The role of melanocytes in the human choroidal microenvironment and inflammation: Insights from the transcriptome. *Pigment Cell Melanoma Res.* 2021;34:928–945.
19. McMenamin PG, Saban DR, Dando SJ. Immune cells in the retina and choroid: Two different tissue environments that require different defenses and surveillance. *Prog Retin Eye Res.* 2019;70:85–98.
20. Streilein JW. Ocular immune privilege: The eye takes a dim but practical view of immunity and inflammation. *J Leukoc Biol.* 2003;74:179–185.
21. De Stefano ME, Mugnaini E. Fine structure of the choroidal coat of the avian eye: Lymphatic vessels. *Invest Ophthalmol Vis Sci.* 1997;38:1241–1260.
22. Koina ME, Baxter L, Adamson SJ, et al. Evidence for lymphatics in the developing and adult human choroid. *Invest Ophthalmol Vis Sci.* 2015;56:1310–1327.
23. Krebs W, Krebs I. *Primate Retina and Choroid: Atlas of Fine Structure in Man and Monkey.* New York: Springer; 1991.
24. Schroedl F, Brehmer A, Neuhuber WL, Kruse FE, May CA, Cursiefen C. The normal human choroid is endowed with a significant number of lymphatic vessel endothelial hyaluronate receptor 1 (LYVE-1)-positive macrophages. *Invest Ophthalmol Vis Sci.* 2008;49:5222–5229.
25. Sugita A, Inokuchi T. Lymphatic sinus-like structures in choroid. *Jpn J Ophthalmol.* 1992;36:436–442.
26. Herwig MC, Munstermann K, Klarmann-Schulz U, et al. Expression of the lymphatic marker podoplanin (D2-40) in human fetal eyes. *Exp Eye Res.* 2014;127:243–251.
27. Troilo D, Smith EL, Nickla DL, et al. IMI—report on experimental models of emmetropization and myopia. *Invest Ophthalmol Vis Sci.* 2019;60:M31–M88.
28. Summers JA, Cano EM, Kaser-Eichberger A, Schroedl F. Retinoic acid synthesis by a population of choroidal stromal cells. *Exp Eye Res.* 2020;201:108252.
29. Mertz JR, Wallman J. Choroidal retinoic acid synthesis: A possible mediator between refractive error and compensatory eye growth. *Exp Eye Res.* 2000;70:519–527.
30. Saint-Geniez M, Maldonado AE, D'Amore PA. VEGF expression and receptor activation in the choroid during development and in the adult. *Invest Ophthalmol Vis Sci.* 2006;47:3135–3142.
31. Frank RN, Amin RH, Elliott D, Puklin JE, Abrams GW. Basic fibroblast growth factor and vascular endothelial growth factor are present in epiretinal and choroidal neovascular membranes. *Am J Ophthalmol.* 1996;122:393–403.
32. McDougal DH, Gamlin PD. Autonomic control of the eye. *Compr Physiol.* 2015;5:439–473.
33. Reiner A, Fitzgerald MEC, Del Mar N, Li C. Neural control of choroidal blood flow. *Prog Retin Eye Res.* 2018;64:96–130.
34. Bergua A, Junemann A, Naumann GO. NADPH-D reactive choroid ganglion cells in the human [in German]. *Klin Monbl Augenheilkd.* 1993;203:77–82.
35. Flugel C, Tamm ER, Mayer B, Lutjen-Drecoll E. Species differences in choroidal vasodilative innervation: Evidence for specific intrinsic nitrergic and VIP-positive neurons in the human eye. *Invest Ophthalmol Vis Sci.* 1994;35:592–599.
36. Stubinger K, Brehmer A, Neuhuber WL, Reitsamer H, Nickla D, Schrodl F. Intrinsic choroidal neurons in the chicken eye: Chemical coding and synaptic input. *Histochem Cell Biol.* 2010;134:145–157.
37. Schrodl F, De Laet A, Tassignon MJ, et al. Intrinsic choroidal neurons in the human eye: Projections, targets, and basic electrophysiological data. *Invest Ophthalmol Vis Sci.* 2003;44:3705–3712.
38. Matsusaka T. Cytoarchitecture of choroidal melanocytes. *Exp Eye Res.* 1982;35:461–469.
39. Stone RA, Tervo T, Tervo K, Tarkkanen A. Vasoactive intestinal polypeptide-like immunoreactive nerves to the human eye. *Acta Ophthalmol (Copenh).* 1986;64:12–18.
40. Schrodl F, Trost A, Strohmaier C, et al. Rat choroidal pericytes as a target of the autonomic nervous system. *Cell Tissue Res.* 2014;356:1–8.
41. Rucker F, Taylor C, Kaser-Eichberger A, Schroedl F. Parasympathetic innervation of emmetropization. *Exp Eye Res.* 2022;217:108964.
42. Parver LM, Auker C, Carpenter DO. Choroidal blood flow as a heat dissipating mechanism in the macula. *Am J Ophthalmol.* 1980;89:641–646.
43. Croft MA, Peterson J, Smith C, et al. Accommodative movements of the choroid in the optic nerve head region of human eyes, and their relationship to the lens. *Exp Eye Res.* 2022;222:109124.
44. Woodman-Pieterse EC, Read SA, Collins MJ, Alonso-Caneiro D. Regional changes in choroidal thickness associated with accommodation. *Invest Ophthalmol Vis Sci.* 2015;56:6414–6422.
45. van Alphen GW. Choroidal stress and emmetropization. *Vis Res.* 1986;26:723–734.
46. Summers JA. The choroid as a sclera growth regulator. *Exp Eye Res.* 2013;114:120–127.
47. Wildsoet C, Wallman J. Choroidal and scleral mechanisms of compensation for spectacle lenses in chicks. *Vis Res.* 1995;35:1175–1194.
48. Nickla DL, Wildsoet C, Wallman J. Compensation for spectacle lenses involves changes in proteoglycan synthesis in both the sclera and choroid. *Curr Eye Res.* 1997;16:320–326.
49. Guggenheim JA, Chen YP, Yip E, et al. Pre-treatment choroidal thickness is not predictive of susceptibility to form-deprivation myopia in chickens. *Ophthalmic Physiol Opt.* 2011;31:516–528.
50. Nickla DL, Totonelly K. Choroidal thickness predicts ocular growth in normal chicks but not in eyes with experimentally altered growth. *Clin Exp Optom.* 2015;98:564–570.
51. Nickla DL, Wildsoet C, Wallman J. Visual influences on diurnal rhythms in ocular length and choroidal thickness in chick eyes. *Exp Eye Res.* 1998;66:163–181.
52. Papastergiou GI, Schmid GF, Riva CE, Mendel MJ, Stone RA, Laties AM. Ocular axial length and choroidal thickness in newly hatched chicks and one-year-old chickens fluctuate in a diurnal pattern that is influenced by visual experience and intraocular pressure changes. *Exp Eye Res.* 1998;66:195–205.

53. Nickla DL, Wildsoet CF, Troilo D. Diurnal rhythms in intraocular pressure, axial length, and choroidal thickness in a primate model of eye growth, the common marmoset. *Invest Ophthalmol Vis Sci.* 2002;43:2519–2528.
54. Stone RA, Quinn GE, Francis EL, et al. Diurnal axial length fluctuations in human eyes. *Invest Ophthalmol Vis Sci.* 2004;45:63–70.
55. Brown JS, Flitcroft DI, Ying GS, et al. In vivo human choroidal thickness measurements: Evidence for diurnal fluctuations. *Invest Ophthalmol Vis Sci.* 2009;50:5–12.
56. Chakraborty R, Read SA, Collins MJ. Diurnal variations in axial length, choroidal thickness, intraocular pressure, and ocular biometrics. *Invest Ophthalmol Vis Sci.* 2011;52:5121–5129.
57. Chakraborty R, Ostrin LA, Nickla DL, Iuvone PM, Pardue MT, Stone RA. Circadian rhythms, refractive development, and myopia. *Ophthalmic Physiol Opt.* 2018;38:217–245.
58. Nickla DL. The phase relationships between the diurnal rhythms in axial length and choroidal thickness and the association with ocular growth rate in chicks. *J Comp Physiol A Neuroethol Sens Neural Behav Physiol.* 2006;192:399–407.
59. Stone RA, Wei W, Sarfare S, et al. Visual image quality impacts circadian rhythm-related gene expression in retina and in choroid: A potential mechanism for ametropias. *Invest Ophthalmol Vis Sci.* 2020;61:13.
60. Nickla DL, Wildsoet CF. The effect of the nonspecific nitric oxide synthase inhibitor NG-nitro-L-arginine methyl ester on the choroidal compensatory response to myopic defocus in chickens. *Optom Vis Sci.* 2004;81:111–118.
61. Feldkaemper M, Schaeffel F. An updated view on the role of dopamine in myopia. *Exp Eye Res.* 2013;114:106–119.
62. Nickla DL, Totonelly K, Dhillon B. Dopaminergic agonists that result in ocular growth inhibition also elicit transient increases in choroidal thickness in chicks. *Exp Eye Res.* 2010;91:715–720.
63. Nickla DL, Zhu X, Wallman J. Effects of muscarinic agents on chick choroids in intact eyes and eyecups: Evidence for a muscarinic mechanism in choroidal thinning. *Ophthalmic Physiol Opt.* 2013;33:245–256.
64. Sander BP, Collins MJ, Read SA. The effect of topical adrenergic and anticholinergic agents on the choroidal thickness of young healthy adults. *Exp Eye Res.* 2014;128:181–189.
65. Fitzgerald ME, Wildsoet CF, Reiner A. Temporal relationship of choroidal blood flow and thickness changes during recovery from form deprivation myopia in chicks. *Exp Eye Res.* 2002;74:561–570.
66. Coscas G, Lupidi M, Coscas F. Image analysis of optical coherence tomography angiography. *Dev Ophthalmol.* 2016;56:30–36.
67. Spaide RF, Fujimoto JG, Waheed NK, Sadda SR, Staurengi G. Optical coherence tomography angiography. *Prog Retin Eye Res.* 2018;64:1–55.
68. Zhang S, Zhang G, Zhou X, et al. Changes in choroidal thickness and choroidal blood perfusion in guinea pig myopia. *Invest Ophthalmol Vis Sci.* 2019;60:3074–3083.
69. Wu H, Chen W, Zhao F, et al. Scleral hypoxia is a target for myopia control. *Proc Natl Acad Sci USA.* 2018;115:E7091–E7100.
70. Zhou X, Zhang S, Zhang G, et al. Increased choroidal blood perfusion can inhibit form deprivation myopia in guinea pigs. *Invest Ophthalmol Vis Sci.* 2020;61:25.
71. Zhou X, Zhang S, Yang F, et al. Decreased choroidal blood perfusion induces myopia in guinea pigs. *Invest Ophthalmol Vis Sci.* 2021;62:30.
72. Swiatczak B, Schaeffel F. Transient eye shortening during reading text with inverted contrast: Effects of refractive error and letter size. *Transl Vis Sci Technol.* 2022;11:17.
73. Delshad S, Collins MJ, Read SA, Vincent SJ. The human axial length and choroidal thickness responses to continuous and alternating episodes of myopic and hyperopic blur. *PLoS ONE.* 2020;15:e0243076.
74. Delshad S, Collins MJ, Read SA, Vincent SJ. The time course of the onset and recovery of axial length changes in response to imposed defocus. *Sci Rep.* 2020;10:8322.
75. Swiatczak B, Schaeffel F. Emmetropic, but not myopic human eyes distinguish positive defocus from calculated blur. *Invest Ophthalmol Vis Sci.* 2021;62:14.
76. Read SA, Collins MJ, Sander BP. Human optical axial length and defocus. *Invest Ophthalmol Vis Sci.* 2010;51:6262–6269.
77. Read SA, Collins MJ, Alonso-Caneiro D. Validation of optical low coherence reflectometry retinal and choroidal biometry. *Opt Vis Sci.* 2011;88:855–863.
78. Guo B, Lau JK, Cheung SW, Cho P. Repeatability and reproducibility of manual choroidal thickness measurement using Lenstar images in children before and after orthokeratology treatment. *Cont Lens Anterior Eye* 2022;45:101484.
79. Spaide RF, Koizumi H, Pozzoni MC. Enhanced depth imaging spectral-domain optical coherence tomography. *Am J Ophthalmol.* 2008;146:496–500.
80. Zhang L, Buitendijk GH, Lee K, et al. Validity of automated choroidal segmentation in SS-OCT and SD-OCT. *Invest Ophthalmol Vis Sci.* 2015;56:3202–3211.
81. Adhi M, Ferrara D, Mullins RF, et al. Characterization of choroidal layers in normal aging eyes using enface swept-source optical coherence tomography. *PLoS ONE.* 2015;10:e0133080.
82. Verner-Cole EA, Campbell JP, Hwang TS, et al. Retinal and choroidal imaging with 870-nm spectral-domain OCT compared with 1050-nm spectral-domain OCT, with and without enhanced depth imaging. *Transl Vis Sci Technol.* 2014;3:3.
83. Alonso-Caneiro D, Read SA, Vincent SJ, Collins MJ, Wojtkowski M. Tissue thickness calculation in ocular optical coherence tomography. *Biomed Opt Express.* 2016;7:629–645.
84. Odell D, Dubis AM, Lever JF, Stepien KE, Carroll J. Assessing errors inherent in OCT-derived macular thickness maps. *J Ophthalmol.* 2011;2011:692574.
85. Kugelman J, Alonso-Caneiro D, Read SA, et al. Automatic choroidal segmentation in OCT images using supervised deep learning methods. *Sci Rep.* 2019;9:13298.
86. Zhang H, Yang J, Zhou K, et al. Automatic segmentation and visualization of choroid in OCT with knowledge infused deep learning. *IEEE J Biomed Health Inform.* 2020;24:3408–3420.
87. Read SA, Collins MJ, Vincent SJ, Alonso-Caneiro D. Choroidal thickness in myopic and nonmyopic children assessed with enhanced depth imaging optical coherence tomography. *Invest Ophthalmol Vis Sci.* 2013;54:7578–7586.
88. Aleman AC, Wang M, Schaeffel F. Reading and myopia: Contrast polarity matters. *Sci Rep.* 2018;8:10840.
89. Hoseini-Yazdi H, Vincent SJ, Collins MJ, Read SA. Regional alterations in human choroidal thickness in response to short-term monocular hemifield myopic defocus. *Ophthalmic Physiol Opt.* 2019;39:172–182.
90. Sonoda S, Sakamoto T, Yamashita T, et al. Choroidal structure in normal eyes and after photodynamic therapy determined by binarization of optical coherence tomographic images. *Invest Ophthalmol Vis Sci.* 2014;55:3893–3899.
91. Li Z, Long W, Hu Y, Zhao W, Zhang W, Yang X. Features of the choroidal structures in myopic children based

- on image binarization of optical coherence tomography. *Invest Ophthalmol Vis Sci.* 2020;61:18.
92. Muller J, Alonso-Caneiro D, Read SA, Vincent SJ, Collins MJ. Application of deep learning methods for binarization of the choroid in optical coherence tomography images. *Transl Vis Sci Technol.* 2022;11:23.
 93. Esmaelpour M, Kajic V, Zabihian B, et al. Choroidal Haller's and Sattler's layer thickness measurement using 3-dimensional 1060-nm optical coherence tomography. *PLoS ONE.* 2014;9:e99690.
 94. Zhou H, Bacci T, Freund KB, Wang RK. Three-dimensional segmentation and depth-encoded visualization of choroidal vasculature using swept-source optical coherence tomography. *Exp Biol Med (Maywood).* 2021;246:2238–2245.
 95. Betzler BK, Ding J, Wei X, et al. Choroidal vascularity index: A step towards software as a medical device. *Br J Ophthalmol.* 2022;106:149–155.
 96. Wei X, Balne PK, Meissner KE, Barathi VA, Schmetterer L, Agrawal R. Assessment of flow dynamics in retinal and choroidal microcirculation. *Surv Ophthalmol.* 2018;63:646–664.
 97. Fuchsjaeger-Mayrl G, Polska E, Malec M, Schmetterer L. Unilateral light-dark transitions affect choroidal blood flow in both eyes. *Vis Res.* 2001;41:2919–2924.
 98. Iwase T, Yamamoto K, Ra E, Murotani K, Matsui S, Terasaki H. Diurnal variations in blood flow at optic nerve head and choroid in healthy eyes: Diurnal variations in blood flow. *Medicine (Baltimore).* 2015;94:e519.
 99. Owens SL. Indocyanine green angiography. *Br J Ophthalmol.* 1996;80:263–266.
 100. Jia Y, Morrison JC, Tokayer J, et al. Quantitative OCT angiography of optic nerve head blood flow. *Biomed Opt Express.* 2012;3:3127–3137.
 101. Spaide RF, Klancnik JM, Cooney MJ. Retinal vascular layers imaged by fluorescein angiography and optical coherence tomography angiography. *JAMA Ophthalmol.* 2015;133:45–50.
 102. Turgut B. Optical coherence tomography angiography—a general view. *Eur Ophthalmic Rev.* 2016;10(1):39–42.
 103. Wang E, Zhao X, Yang J, Chen Y. Visualization of deep choroidal vasculatures and measurement of choroidal vascular density: A swept-source optical coherence tomography angiography approach. *BMC Ophthalmol.* 2020;20:321.
 104. Agawa T, Miura M, Ikuno Y, et al. Choroidal thickness measurement in healthy Japanese subjects by three-dimensional high-penetration optical coherence tomography. *Graefes Arch Clin Exp Ophthalmol.* 2011;249:1485–1492.
 105. Nishida Y, Fujiwara T, Imamura Y, Lima LH, Kurosaka D, Spaide RF. Choroidal thickness and visual acuity in highly myopic eyes. *Retina.* 2012;32:1229–1236.
 106. Ikuno Y, Tano Y. Retinal and choroidal biometry in highly myopic eyes with spectral-domain optical coherence tomography. *Invest Ophthalmol Vis Sci.* 2009;50:3876–3880.
 107. Harb E, Hyman L, Gwiazda J, et al. Choroidal thickness profiles in myopic eyes of young adults in the correction of myopia evaluation trial cohort. *Am J Ophthalmol.* 2015;160:62–71.e62.
 108. Ruiz-Moreno JM, Flores-Moreno I, Lugo F, Ruiz-Medrano J, Montero JA, Akiba M. Macular choroidal thickness in normal pediatric population measured by swept-source optical coherence tomography. *Invest Ophthalmol Vis Sci.* 2013;54:353–359.
 109. Xiong S, He X, Deng J, et al. Choroidal thickness in 3001 Chinese children aged 6 to 19 years using swept-source OCT. *Sci Rep.* 2017;7:45059.
 110. Read SA, Fuss JA, Vincent SJ, Collins MJ, Alonso-Caneiro D. Choroidal changes in human myopia: Insights from optical coherence tomography imaging. *Clin Exp Optom.* 2019;102:270–285.
 111. Jonas JB, Wang YX, Dong L, Guo Y, Panda-Jonas S. Advances in myopia research anatomical findings in highly myopic eyes. *Eye Vis (Lond).* 2020;7:45.
 112. Prousalis E, Dastiridou A, Ziakas N, Androudi S, Mataftsi A. Choroidal thickness and ocular growth in childhood. *Surv Ophthalmol.* 2021;66:261–275.
 113. Li XQ, Jeppesen P, Larsen M, Munch IC. Subfoveal choroidal thickness in 1323 children aged 11 to 12 years and association with puberty: The Copenhagen Child Cohort 2000 Eye Study. *Invest Ophthalmol Vis Sci.* 2014;55:550–555.
 114. Gupta P, Cheung CY, Saw SM, et al. Peripapillary choroidal thickness in young Asians with high myopia. *Invest Ophthalmol Vis Sci.* 2015;56:1475–1481.
 115. Tuncer I, Karahan E, Zengin MO, Atalay E, Polat N. Choroidal thickness in relation to sex, age, refractive error, and axial length in healthy Turkish subjects. *Int Ophthalmol.* 2015;35:403–410.
 116. Bidaut-Garnier M, Schwartz C, Puyraveau M, Montard M, Delbosc B, Saleh M. Choroidal thickness measurement in children using optical coherence tomography. *Retina.* 2014;34:768–774.
 117. Michalewski J, Michalewska Z, Nawrocka Z, Bednarski M, Nawrocki J. Correlation of choroidal thickness and volume measurements with axial length and age using swept source optical coherence tomography and optical low-coherence reflectometry. *Biomed Res Int.* 2014;2014:639160.
 118. Song Y, Tham YC, Chong C, et al. Patterns and determinants of choroidal thickness in a multiethnic Asian population: The Singapore Epidemiology of Eye Diseases Study. *Ophthalmol Retina.* 2021;5:458–467.
 119. Tan CS, Cheong KX, Lim LW, Li KZ. Topographic variation of choroidal and retinal thicknesses at the macula in healthy adults. *Br J Ophthalmol.* 2014;98:339–344.
 120. Read SA, Alonso-Caneiro D, Vincent SJ, Collins MJ. Longitudinal changes in choroidal thickness and eye growth in childhood. *Invest Ophthalmol Vis Sci.* 2015;56:3103–3112.
 121. Cheng W, Song Y, Lin F, et al. Choriocapillaris flow deficits in normal Chinese imaged by swept-source optical coherence tomographic angiography. *Am J Ophthalmol.* 2022;235:143–153.
 122. Panda-Jonas S, Holbach L, Jonas JB. Choriocapillaris thickness and density in axially elongated eyes. *Acta Ophthalmol.* 2021;99:104–110.
 123. Zhao J, Wang YX, Zhang Q, Wei WB, Xu L, Jonas JB. Macular choroidal small-vessel layer, Sattler's layer and Haller's layer thicknesses: The Beijing Eye Study. *Sci Rep.* 2018;8:4411.
 124. Ruiz-Medrano J, Flores-Moreno I, Pena-Garcia P, Montero JA, Duker JS, Ruiz-Moreno JM. Macular choroidal thickness profile in a healthy population measured by swept-source optical coherence tomography. *Invest Ophthalmol Vis Sci.* 2014;55:3532–3542.
 125. He X, Jin P, Zou H, et al. Choroidal thickness in healthy Chinese children aged 6 to 12: The Shanghai Children Eye Study. *Retina.* 2017;37:368–375.
 126. Zengin MO, Karahan E, Yilmaz S, Cinar E, Tuncer I, Kucukerdonmez C. Association of choroidal thickness with eye growth: A cross-sectional study of individuals between 4 and 23 years. *Eye (Lond).* 2014;28:1482–1487.
 127. Nagasawa T, Mitamura Y, Katome T, et al. Macular choroidal thickness and volume in healthy pediatric individuals measured by swept-source optical coherence

- tomography. *Invest Ophthalmol Vis Sci.* 2013;54:7068–7074.
128. Read SA, Collins MJ, Vincent SJ, Alonso-Caneiro D. Choroidal thickness in childhood. *Invest Ophthalmol Vis Sci.* 2013;54:3586–3593.
 129. Shao L, Xu L, Wei WB, et al. Visual acuity and subfoveal choroidal thickness: The Beijing Eye Study. *Am J Ophthalmol.* 2014;158:702–709.e701.
 130. Ooto S, Hangai M, Yoshimura N. Effects of sex and age on the normal retinal and choroidal structures on optical coherence tomography. *Current Eye Reseach.* 2015;40(2):213–225.
 131. Karapetyan A, Ouyang P, Tang LS, Gemilyan M. Choroidal thickness in relation to ethnicity measured using enhanced depth imaging optical coherence tomography. *Retina.* 2016;36:82–90.
 132. Bafiq R, Mathew R, Pearce E, et al. Age, sex, and ethnic variations in inner and outer retinal and choroidal thickness on spectral-domain optical coherence tomography. *Am J Ophthalmol.* 2015;160:1034–1043.e1031.
 133. Ouyang Y, Heussen FM, Mokwa N, et al. Spatial distribution of posterior pole choroidal thickness by spectral domain optical coherence tomography. *Invest Ophthalmol Vis Sci.* 2011;52:7019–7026.
 134. Gupta P, Jing T, Marziliano P, et al. Distribution and determinants of choroidal thickness and volume using automated segmentation software in a population-based study. *Am J Ophthalmol.* 2015;159:293–301.e293.
 135. Margolis R, Spaide RF. A pilot study of enhanced depth imaging optical coherence tomography of the choroid in normal eyes. *Am J Ophthalmol.* 2009;147:811–815.
 136. Wang NK, Lai CC, Chou CL, et al. Choroidal thickness and biometric markers for the screening of lacquer cracks in patients with high myopia. *PLoS ONE.* 2013;8:e53660.
 137. Ulaganathan S, Read SA, Collins MJ, Vincent SJ. Daily axial length and choroidal thickness variations in young adults: Associations with light exposure and longitudinal axial length and choroid changes. *Exp Eye Res.* 2019;189:107850.
 138. Lee SS, Alonso-Caneiro D, Lingham G, et al. Choroidal thickening during young adulthood and baseline choroidal thickness predicts refractive error change. *Invest Ophthalmol Vis Sci.* 2022;63:34.
 139. Tian F, Zheng D, Zhang J, et al. Choroidal and retinal thickness and axial eye elongation in Chinese junior students. *Invest Ophthalmol Vis Sci.* 2021;62:26.
 140. Hansen MH, Kessel L, Li XQ, Skovgaard AM, Larsen M, Munch IC. Axial length change and its relationship with baseline choroidal thickness—a five-year longitudinal study in Danish adolescents: The CCC2000 eye study. *BMC Ophthalmol.* 2020;20:152.
 141. Li XQ, Larsen M, Munch IC. Subfoveal choroidal thickness in relation to sex and axial length in 93 Danish university students. *Invest Ophthalmol Vis Sci.* 2011;52:8438–8441.
 142. Chen W, Wang Z, Zhou X, Li B, Zhang H. Choroidal and photoreceptor layer thickness in myopic population. *Eur J Ophthalmol.* 2012;22:590–597.
 143. Sogawa K, Nagaoka T, Takahashi A, et al. Relationship between choroidal thickness and choroidal circulation in healthy young subjects. *Am J Ophthalmol.* 2012;153:1129–1132.e1121.
 144. Kim M, Kim SS, Koh HJ, Lee SC. Choroidal thickness, age, and refractive error in healthy Korean subjects. *Optom Vis Sci.* 2014;91:491–496.
 145. Wei WB, Xu L, Jonas JB, et al. Subfoveal choroidal thickness: The Beijing Eye Study. *Ophthalmology.* 2013;120:175–180.
 146. Xie J, Ye L, Chen Q, et al. Choroidal thickness and its association with age, axial length, and refractive error in Chinese adults. *Invest Ophthalmol Vis Sci.* 2022;63:34.
 147. Wolffsohn JS, Kollbaum PS, Berntsen DA, et al. IMI—clinical myopia control trials and instrumentation report. *Invest Ophthalmol Vis Sci.* 2019;60:M132–M160.
 148. Ohno-Matsui K, Wu PC, Yamashiro K, et al. IMI pathologic myopia. *Invest Ophthalmol Vis Sci.* 2021;62:5.
 149. Ostrin LA, Jnawali A, Carkeet A, Patel NB. Twenty-four hour ocular and systemic diurnal rhythms in children. *Ophthalmic Physiol Opt.* 2019;39(5):358–369.
 150. Insa-Sanchez G, Fuentes-Broto L, Cobos A, et al. Choroidal thickness and volume modifications induced by aerobic exercise in healthy young adults. *Ophthalmic Res.* 2021;64:604–612.
 151. Kinoshita T, Mori J, Okuda N, et al. Effects of exercise on the structure and circulation of choroid in normal eyes. *PLoS ONE.* 2016;11:e0168336.
 152. Yildirim A, Kurt E, Altinisik M, Uyar Y. Evaluation of retinochoroidal tissues in third trimester pregnant: An optical coherence tomography angiography study. *Eur J Ophthalmol.* 2022;32:501–507.
 153. Azuma K, Okubo A, Suzuki T, et al. Assessment of the choroidal structure in pregnant women in the first trimester. *Sci Rep.* 2021;11:4629.
 154. Su L, Taweebanjongsin W, Gaw SL, Rabina G, Sadda SR, Tsui I. Evaluation of the choroid in women with uncomplicated pregnancy. *Transl Vis Sci Technol.* 2020;9:24.
 155. Dadaci Z, Alptekin H, Oncel Acir N, Borazan M. Changes in choroidal thickness during pregnancy detected by enhanced depth imaging optical coherence tomography. *Br J Ophthalmol.* 2015;99:1255–1259.
 156. Nagasato D, Mitamura Y, Egawa M, et al. Changes of choroidal structure and circulation after water drinking test in normal eyes. *Graefes Arch Clin Exp Ophthalmol.* 2019;257:2391–2399.
 157. Mansouri K, Medeiros FA, Marchase N, Tatham AJ, Auerbach D, Weinreb RN. Assessment of choroidal thickness and volume during the water drinking test by swept-source optical coherence tomography. *Ophthalmology.* 2013;120:2508–2516.
 158. Temel E, Kocamis O, Asikgarip N, Ornek K, Arioz O. Evaluation of choroidal thickness and choroidal vascularity index during pregnancy. *Can J Ophthalmol.* 2021;56:237–243.
 159. Burfield HJ, Carkeet A, Ostrin LA. Ocular and systemic diurnal rhythms in emmetropic and myopic adults. *Invest Ophthalmol Vis Sci.* 2019;60:2237–2247.
 160. Lovasik JV, Kergoat H, Riva CE, Petrig BL, Geiser M. Choroidal blood flow during exercise-induced changes in the ocular perfusion pressure. *Invest Ophthalmol Vis Sci.* 2003;44:2126–2132.
 161. Karakucuk Y, Okudan N, Bozkurt B, Belviranli M, Sezer T, Gorcuyeva S. Quantitative assessment of the effect of acute anaerobic exercise on macular perfusion via swept-source optical coherence tomography angiography in young football players. *Int Ophthalmol.* 2020;40:1377–1386.
 162. Hong J, Zhang H, Kuo DS, et al. The short-term effects of exercise on intraocular pressure, choroidal thickness and axial length. *PLoS One.* 2014;9:e104294.
 163. Alwassia AA, Adhi M, Zhang JY, et al. Exercise-induced acute changes in systolic blood pressure do not alter choroidal thickness as measured by a portable spectral-domain optical coherence tomography device. *Retina.* 2013;33:160–165.

164. Szalai I, Csorba A, Palya F, et al. The assessment of acute chorioretinal changes due to intensive physical exercise in young adults. *PLoS ONE*. 2022;17:e0268770.
165. Maugé-Faysse M, Arej N, Paternoster M, et al. Retinal and choroidal blood flow variations after an endurance exercise: A real-life pilot study at the Paris Marathon. *J Sci Med Sport*. 2021;24:1100–1104.
166. Miller D. The relationship between diurnal tension variation and the water-drinking test. *Am J Ophthalmol*. 1964;58:243–246.
167. Spaeth GL. The water drinking test: Indications that factors other than osmotic considerations are involved. *Arch Ophthalmol*. 1967;77:50–58.
168. De Moraes CG, Reis AS, Cavalcante AF, Sano ME, Susanna R. Choroidal expansion during the water drinking test. *Graefes Arch Clin Exp Ophthalmol*. 2009;247:385–389.
169. Arora KS, Jefferys JL, Maul EA, Quigley HA. Choroidal thickness change after water drinking is greater in angle closure than in open angle eyes. *Invest Ophthalmol Vis Sci*. 2012;53:6393–6402.
170. Kocabeyoglu S, Uzun S, Kadayifcilar S, Mocan MC, Irkeç M. The relationship between choroidal expansion and intraocular pressure rise during the water drinking test in healthy subjects and patients with exfoliation syndrome. *J Glaucoma*. 2016;25:e324–328.
171. Nongpiur ME, Foo VH, de Leon JM, et al. Evaluation of choroidal thickness, intraocular pressure, and serum osmolality after the water drinking test in eyes with primary angle closure. *Invest Ophthalmol Vis Sci*. 2015;56:2135–2143.
172. Germano RA, Hatanaka M, Susanna RJ. Choroidal thickness variation in highly myopic eyes during the water drinking test. *Arq Bras Oftalmol*. 2016;79:214–217.
173. Geiser MH, Bonvin M, Quibel O. Corneal and retinal temperatures under various ambient conditions: A model and experimental approach. *Klin Monbl Augenbeilkd*. 2004;221:311–314.
174. Song CW, Chelstrom LM, Levitt SH, Haumschild DJ. Effects of temperature on blood circulation measured with the laser Doppler method. *Int J Radiat Oncol Biol Phys*. 1989;17:1041–1047.
175. Lockitch G. Clinical biochemistry of pregnancy. *Crit Rev Clin Lab Sci*. 1997;34:67–139.
176. Khong EWC, Chan HHL, Watson SL, Lim LL. Pregnancy and the eye. *Curr Opin Ophthalmol*. 2021;32:527–535.
177. Anton N, Doroftei B, Ilie OD, Ciuntu RE, Bogdanici CM, Nechita-Dumitriu I. A narrative review of the complex relationship between pregnancy and eye changes. *Diagnostics (Basel)*. 2021;11:1329.
178. Roskal-Walek J, Laudanska-Olszewska I, Biskup M, Gierada M, Odrobina D. Choroidal thickness in women with uncomplicated pregnancy: Literature review. *Biomed Res Int*. 2017;2017:5694235.
179. Liu R, Kuang GP, Luo DX, Lu XH. Choroidal thickness in pregnant women: A cross-sectional study. *Int J Ophthalmol*. 2016;9:1200–1206.
180. Takahashi J, Kado M, Mizumoto K, Igarashi S, Kojo T. Choroidal thickness in pregnant women measured by enhanced depth imaging optical coherence tomography. *Jpn J Ophthalmol*. 2013;57:435–439.
181. Jiang MS, Xu XL, Yang T, Li F, Zhang XD. Comparison of choroidal thickness in preeclamptic, healthy pregnant, and nonpregnant women: A systematic review and meta-analysis. *Ophthalmic Res*. 2019;62:1–10.
182. Shalaby HS, ElSebaay ME, Samy MM. Comparison between central choroidal thickness in pregnant diabetic females and pregnant non-diabetic females. *Clin Ophthalmol*. 2021;15:105–111.
183. Evcimen Y, Onur IU, Cengiz H, Yigit FU. Optical coherence tomography findings in pre-eclampsia: A preliminary receiver operating characteristic analysis on choroidal thickness for disease severity. *Curr Eye Res*. 2019;44:916–920.
184. Sharudin SN, Saaid R, Samsudin A, Mohamad NF. Subfoveal choroidal thickness in pre-eclampsia. *Optom Vis Sci*. 2020;97:81–85.
185. Sander BP, Collins MJ, Read SA. Short-term effect of low-dose atropine and hyperopic defocus on choroidal thickness and axial length in young myopic adults. *J Ophthalmol*. 2019;2019:4782536.
186. Kara N, Demircan A, Karatas G, et al. Effects of two commonly used mydriatics on choroidal thickness: Direct and crossover effects. *J Ocul Pharmacol Ther*. 2014;30:366–370.
187. Yuvaci I, Pangal E, Yuvaci S, et al. An evaluation of effects of different mydriatics on choroidal thickness by examining anterior chamber parameters: The Scheimpflug Imaging and Enhanced Depth Imaging-OCT Study. *J Ophthalmol*. 2015;2015:981274.
188. Oner V, Bulut A, Oter K. The effect of topical antimuscarinic agents on subfoveal choroidal thickness in healthy adults. *Eye (Lond)*. 2016;30:925–928.
189. Bahar A, Pekel G. The effects of pharmacological accommodation and cycloplegia on axial length and choroidal thickness. *Arq Bras Oftalmol*. 2021;84:107–112.
190. Casado A, Lopez-de-Eguileta A, Gaitan J, Fonseca S, Gordo-Vega MA. Peripapillary and macular choroidal thickness before and after phenylephrine instillation. *Eye (Lond)*. 2019;33:1741–1747.
191. Arej N, Azar G, Salviat F, et al. Study of choroidal thickness variations after ingestion of a taurine and caffeine-containing energy drink. *Clin Nutr ESPEN*. 2021;43:245–249.
192. Dervisogullari MS, Totan Y, Yuce A, Kulak AE. Acute effects of caffeine on choroidal thickness and ocular pulse amplitude. *Cutan Ocul Toxicol*. 2016;35:281–286.
193. Altinkaynak H, Ceylan E, Kartal B, Keles S, Ekinci M, Olcaysu OO. Measurement of choroidal thickness following caffeine intake in healthy subjects. *Curr Eye Res*. 2016;41:708–714.
194. Zengin MO, Cinar E, Karahan E, Tuncer I, Kucukerdonmez C. The effect of caffeine on choroidal thickness in young healthy subjects. *Cutan Ocul Toxicol*. 2015;34:112–116.
195. Vural AD, Kara N, Sayin N, Pirhan D, Ersan HB. Choroidal thickness changes after a single administration of coffee in healthy subjects. *Retina*. 2014;34:1223–1228.
196. Lopez C, Ostrin LA. Ocular and systemic effects of oral caffeine (E-Abstract 225398). *Optom Vis Sci Suppl*. 2022;99.
197. Makri OE, Pallikari A, Kagkellaris K, et al. The acute effects of electronic cigarette vaping and tobacco cigarette smoking on choroidal thickness in young, healthy, habitual, dual smokers. *Toxics*. 2020;8:85.
198. Cinar E, Yuce B, Zengin MO, Kucukerdonmez C. The effect of nicotine on macular microcirculation in healthy subjects. *Ophthalmic Surg Lasers Imaging Retina*. 2019;50:691–700.
199. Kang HM, Woo YJ, Koh HJ, Lee CS, Lee SC. The effect of consumption of ethanol on subfoveal choroidal thickness in acute phase. *Br J Ophthalmol*. 2016;100:383–388.
200. Yam JC, Jiang Y, Lee J, et al. The association of choroidal thickening by atropine with treatment effects for myopia: Two-year clinical trial of the Low-concentration Atropine for Myopia Progression (LAMP) study. *Am J Ophthalmol*. 2022;237:130–138.
201. Hao Q, Zhao Q. Changes in subfoveal choroidal thickness in myopic children with 0.01% atropine, orthokeratology, or their combination. *Int Ophthalmol*. 2021;41:2963–2971.

202. Ye L, Shi Y, Yin Y, et al. Effects of atropine treatment on choroidal thickness in myopic children. *Invest Ophthalmol Vis Sci.* 2020;61:15.
203. Chiang ST, Phillips JR. Effect of atropine eye drops on choroidal thinning induced by hyperopic retinal defocus. *J Ophthalmol.* 2018;2018:8528315.
204. Bajenova N, Johnson MW, Vanderbeek BL. Change in choroidal thickness after instillation of topical phenylephrine detected by EDI OCT. *Invest Ophthalmol Vis Sci.* 2012;53:2648.
205. Smith EL, Hung LF, She Z, Beach K, Ostrin LA, Jong M. Topically instilled caffeine selectively alters emmetropizing responses in infant rhesus monkeys. *Exp Eye Res.* 2021;203:108438.
206. Hung LF, Arumugam B, Ostrin L, et al. The Adenosine receptor antagonist, 7-methylxanthine, alters emmetropizing responses in infant macaques. *Invest Ophthalmol Vis Sci.* 2018;59:472–486.
207. Kiuchi K, Matsuoka M, Wu JC, et al. Mecamylamine suppresses basal and nicotine-stimulated choroidal neovascularization. *Invest Ophthalmol Vis Sci.* 2008;49:1705–1711.
208. Altura BM, Altura BT. Peripheral and cerebrovascular actions of ethanol, acetaldehyde, and acetate: Relationship to divalent cations. *Alcohol Clin Exp Res.* 1987;11:99–111.
209. Howlett MH, McFadden SA. Spectacle lens compensation in the pigmented guinea pig. *Vis Res.* 2009;49:219–227.
210. Hung LF, Wallman J, Smith EL. Vision-dependent changes in the choroidal thickness of macaque monkeys. *Invest Ophthalmol Vis Sci.* 2000;41:1259–1269.
211. Siegwart JT, Norton TT. The susceptible period for deprivation-induced myopia in tree shrew. *Vis Res.* 1998;38:3505–3515.
212. Troilo D, Nickla DL, Wildsoet CF. Choroidal thickness changes during altered eye growth and refractive state in a primate. *Invest Ophthalmol Vis Sci.* 2000;41:1249–1258.
213. Chiang ST, Phillips JR, Backhouse S. Effect of retinal image defocus on the thickness of the human choroid. *Ophthalmic Physiol Opt.* 2015;35:405–413.
214. Drexler W, Findl O, Schmetterer L, Hitznerberger CK, Fercher AF. Eye elongation during accommodation in humans: Differences between emmetropes and myopes. *Invest Ophthalmol Vis Sci.* 1998;39:2140–2147.
215. Chakraborty R, Baranton K, Spiegel D, et al. Effects of mild- and moderate-intensity illumination on short-term axial length and choroidal thickness changes in young adults. *Ophthalmic Physiol Opt.* 2022;42:762–772.
216. Lou L, Ostrin LA. The outdoor environment affects retinal and choroidal thickness. *Ophthalmic Phys Opt.* 2023;43(3):572–583.
217. Hoseini-Yazdi H, Read SA, Alonso-Caneiro D, Collins MJ. Retinal OFF-pathway overstimulation leads to greater accommodation-induced choroidal thinning. *Invest Ophthalmol Vis Sci.* 2021;62:5.
218. Turnbull PRK, Phillips JR. Ocular effects of virtual reality headset wear in young adults. *Sci Rep.* 2017;7:16172.
219. Yoon HJ, Moon HS, Sung MS, Park SW, Heo H. Effects of prolonged use of virtual reality smartphone-based head-mounted display on visual parameters: A randomised controlled trial. *Sci Rep.* 2021;11:15382.
220. Wang D, Chun RK, Liu M, et al. Optical defocus rapidly changes choroidal thickness in schoolchildren. *PLoS ONE.* 2016;11:e0161535.
221. Moderiano D, Do M, Hobbs S, et al. Influence of the time of day on axial length and choroidal thickness changes to hyperopic and myopic defocus in human eyes. *Exp Eye Res.* 2019;182:125–136.
222. Hoseini-Yazdi H, Vincent SJ, Read SA, Collins MJ. Astigmatic defocus leads to short-term changes in human choroidal thickness. *Invest Ophthalmol Vis Sci.* 2020;61:48.
223. Ghosh A, Collins MJ, Read SA, Davis BA, Chatterjee P. Axial elongation associated with biomechanical factors during near work. *Optom Vis Sci.* 2014;91:322–329.
224. Hung LF, Arumugam B, She Z, Ostrin L, Smith EL. Narrow-band, long-wavelength lighting promotes hyperopia and retards vision-induced myopia in infant rhesus monkeys. *Exp Eye Res.* 2018;176:147–160.
225. Read SA, Pieterse EC, Alonso-Caneiro D, et al. Daily morning light therapy is associated with an increase in choroidal thickness in healthy young adults. *Sci Rep.* 2018;8:8200.
226. Ogawa M, Torii H, Yotsukura E, et al. Intensive outdoor activity for 1 week increased choroidal thickness. *Invest Ophthalmol Vis Sci.* 2022;63:246.
227. Thakur S, Dhakal R, Verkicharla PK. Short-term exposure to blue light shows an inhibitory effect on axial elongation in human eyes independent of defocus. *Invest Ophthalmol Vis Sci.* 2021;62:22.
228. Chen H, Wang W, Liao Y, et al. Low-intensity red-light therapy in slowing myopic progression and the rebound effect after its cessation in Chinese children: A randomized controlled trial. *Graefes Arch Clin Exp Ophthalmol.* 2023;261:575–584.
229. Chakraborty R, Park HN, Hanif AM, Sidhu CS, Iuvone PM, Pardue MT. ON pathway mutations increase susceptibility to form-deprivation myopia. *Exp Eye Res.* 2015;137:79–83.
230. Crewther DP, Crewther SG. Refractive compensation to optical defocus depends on the temporal profile of luminance modulation of the environment. *Neuroreport.* 2002;13:1029–1032.
231. Wang M, Aleman AC, Schaeffel F. Probing the potency of artificial dynamic ON or OFF stimuli to inhibit myopia development. *Invest Ophthalmol Vis Sci.* 2019;60:2599–2611.
232. Wildsoet CF, Chia A, Cho P, et al. IMI—Interventions Myopia Institute: Interventions for controlling myopia onset and progression report. *Invest Ophthalmol Vis Sci.* 2019;60:M106–M131.
233. Wu PC, Chen CT, Lin KK, et al. Myopia prevention and outdoor light intensity in a school-based cluster randomized trial. *Ophthalmology.* 2018;125:1239–1250.
234. Zhou L, Xing C, Qiang W, Hua C, Tong L. Low-intensity, long-wavelength red light slows the progression of myopia in children: An Eastern China-based cohort. *Ophthalmic Physiol Opt.* 2022;42:335–344.
235. Huang Y, Li X, Wu J, et al. Effect of spectacle lenses with aspherical lenslets on choroidal thickness in myopic children: A 2-year randomised clinical trial. *Br J Ophthalmol.* September 27, 2022; bjophthalmol-2022-321815. Online ahead of print.
236. Prieto-Garrido FL, Villa-Collar C, Hernandez-Verdejo JL, Alvarez-Peregrina C, Ruiz-Pomeda A. Changes in the choroidal thickness of children wearing MiSight to control myopia. *J Clin Med.* 2022;11:3833.
237. Chen Z, Xue F, Zhou J, Qu X, Zhou X. Effects of orthokeratology on choroidal thickness and axial length. *Optom Vis Sci.* 2016;93:1064–1071.
238. Li Z, Cui D, Hu Y, Ao S, Zeng J, Yang X. Choroidal thickness and axial length changes in myopic children treated with orthokeratology. *Cont Lens Anterior Eye.* 2017;40:417–423.
239. Li Z, Hu Y, Cui D, Long W, He M, Yang X. Change in subfoveal choroidal thickness secondary to orthokeratology and its cessation: A predictor for the change in axial length. *Acta Ophthalmol.* 2019;97:e454–e459.

240. Chun RK-m, Liu Z, Tang WC, Tse DY-y, Lam CSY, To CH. Effect of defocus incorporated multiple segments (DIMS) lenses on choroidal thickness in schoolchildren. *Invest Ophthalmol Vis Sci*. 2021;62:1389–1389.
241. Lau JK, Wan K, Cheung SW, Vincent SJ, Cho P. Weekly changes in axial length and choroidal thickness in children during and following orthokeratology treatment with different compression factors. *Transl Vis Sci Technol*. 2019;8:9.