

Received: 2020.11.03

Accepted: 2020.12.20

Available online: 2021.01.28

Published: 2021.03.08

Activated Prothrombin Complex Concentrate-Induced Atypical Hemolytic Uremic Syndrome Treated with Eculizumab

Authors' Contribution:

Study Design A
Data Collection B
Statistical Analysis C
Data Interpretation D
Manuscript Preparation E
Literature Search F
Funds Collection G

CDEF 1 **Hsin Hsiang Clarence Tsai**BCDE 2 **Justin Tyler Moyers**BE 3 **Christie J. Moore**DE 4 **MieMie Thinn**

1 School of Medicine, Loma Linda University, Loma Linda, CA, U.S.A.

2 Division of Hematology and Oncology, Department of Internal Medicine, Loma Linda University, Loma Linda, CA, U.S.A.

3 Department of Hematology and Oncology, Providence Cancer Institute, Portland, OR, U.S.A.

4 Department of Hematology and Oncology, Veterans Affairs Loma Linda Healthcare System, Loma Linda, CA, U.S.A.

Corresponding Author: Hsin Hsiang Clarence Tsai, e-mail: hctasai@students.llu.edu**Conflict of interest:** None declared

Patient: Male, 58-year-old
Final Diagnosis: Atypical hemolytic uremic syndrome • FEIBA induced aHUS
Symptoms: Anemia • renal failure • thrombocytopenia
Medication: —
Clinical Procedure: —
Specialty: Hematology • General and Internal Medicine

Objective: Challenging differential diagnosis


Background: Atypical hemolytic uremic syndrome (aHUS) is a set of heterogeneous disorders of thrombotic microangiopathy defined by thrombocytopenia, hemolytic anemia, and acute renal failure that is not mediated by shiga toxin. Factor Eight Inhibitor Bypassing Activity (FEIBA) is a concentrate of inactivated and activated coagulation factors that is approved for use to establish hemostasis in patients with hemophilia or acquired factor inhibitors. However, it has recently been used off-label as an anticoagulant reversal therapy among the general population. Additionally, post-market surveillance has shown increased thromboembolic adverse events, whereas micro-thrombotic complications are rarely described.

Case Report: A 58-year-old man with a history of hypertension and a single deep vein thrombosis on warfarin presented with right upper-quadrant tenderness extending to the right flank. He was found to have a hepatic hematoma and was given activated prothrombin complex concentrate (aPCC) of 14 150 units of anti-inhibitor coagulant complex at 100 units per kilogram due to concern for active hemorrhage. Subsequently, he developed anemia, thrombocytopenia, and renal failure consistent with atypical HUS. He was treated with hemodialysis, corticosteroids, plasma exchange, and 4 weekly doses of the anti-C5 antibody eculizumab. The patient subsequently recovered, demonstrating improved hemoglobin, creatinine, and platelets. He eventually achieved hemodialysis independence. Follow-up showed no evidence of recurrent atypical HUS and the patient has not needed maintenance eculizumab.

Conclusions: Herein, we report the first case of aHUS associated with administration of a single large dose of aPCC for anticoagulation reversal. We postulate a potential mechanism for FEIBA-induced aHUS and report the efficacy of a short trial of eculizumab.

Keywords: Blood Coagulation Factors • Case Reports • Drug-Related Side Effects and Adverse Reactions • Hemolytic-Uremic Syndrome • Thrombotic Microangiopathies • Anemia, Hemolytic • Acute Kidney Injury • Treatment Outcome • Thrombocytopenia


Abbreviations: aHUS – atypical hemolytic uremic syndrome; aPCC – active prothrombin complex concentrate; FEIBA – factor eight inhibitor bypassing activity; HD – hemodialysis; TTP – thrombotic thrombocytopenic purpura; PLX – plasma exchange

Full-text PDF: <https://www.amjcaserep.com/abstract/index/idArt/929616>

1621



2



21



Background

Hemolytic uremic syndrome (HUS) is a thrombotic microangiopathy (TMA) characterized by thrombocytopenia, microangiopathic hemolytic anemia, and renal impairment [1]. It is generally subdivided into typical or atypical. Shiga toxin-mediated TMA (ST-HUS) is caused by shiga toxin-producing *Escherichia coli* or *Shigella dysenteriae* infection, whereas atypical HUS is a heterogeneous group of TMA disorders that are both inherited and acquired, caused by complement dysregulation [2]. It has a poor prognosis, with more than half of patients requiring dialysis or experiencing significant renal injury within the first year after diagnosis [3].

Factor Eight Inhibitor Bypassing Activity (FEIBA) is an activated prothrombin complex concentrate (aPCC) composed of activated factor VII and inactivated factors II, IX, and X. It is FDA-approved to control bleeding in those with hemophilia A or B with acquired inhibitors or non-hemophiliacs with inhibitors to factors VIII, IX, or XI [4,5]. Recently, data have shown its efficacy in off-label emergent use for anticoagulant reversal therapy [6-9]. Herein, we describe the first reported case of atypical hemolytic uremic syndrome (aHUS) after administration of a large dose of FEIBA.

Case Report

A 58-year-old man taking warfarin for an unprovoked deep vein thrombosis presented with a 1-day history of abdominal and shoulder pain, which progressed to non-radiating right upper-quadrant abdominal pain. His past medical history was significant for hypertension, for which he was taking Lisinopril. He was a 15-pack-year smoker without alcohol or illicit drug use. His family history was significant for a father with liver cancer.

On physical examination, his vitals were stable, he was afebrile, with blood pressure of 130/87 mmHg, heart rate of 67 beats/minute, respiratory rate of 16 breaths/minute, oxygen saturation (SpO₂) of >95%, and body mass index of 48 kg/m². He was in mild distress from pain. His lungs were clear to auscultation and a cardiac examination demonstrated regular rhythm, with no extra heart sounds or murmurs. On abdominal examination, he had mild right upper-quadrant tenderness extending to the right flank. No rashes were found on skin examination. His neurologic exam showed no focal neurological deficits. An initial complete blood count and comprehensive metabolic panel were unremarkable. His INR was therapeutic at 2.8 with platelet count of 259×10⁹/L, creatinine of 1.06 mg/dL, and hemoglobin of 12.9 g/dL. An abdominal ultrasound and subsequent CT abdomen showed a 10-cm-diameter hepatic hematoma suggestive of active bleeding and rupture. Due to concern for potential decompensation, he was

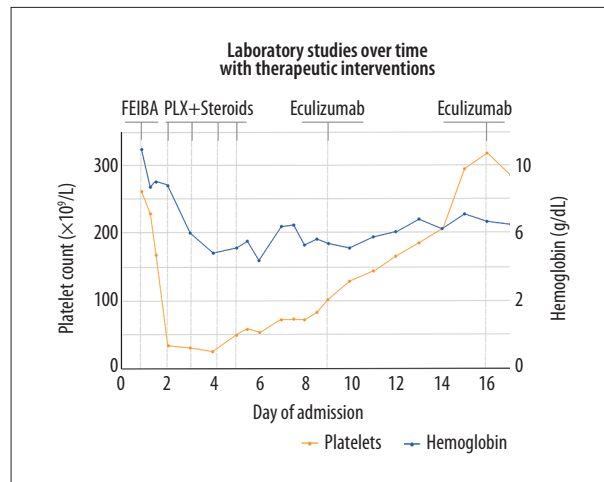


Figure 1. Hemoglobin and platelet count over time by day of admission during hospital course along with temporal relationship of therapeutic interventions (FEIBA, Steroids, Plasma Exchange [PLX], and eculizumab). Each point represents a lab value measurement.

given 5 mg of intravenous vitamin K and 14 150 units of anti-inhibitor coagulant complex at 100 units per kilogram infused over 1 hour for reversal of therapeutic anticoagulation and establishment of hemostasis. He was transferred to our institution for further management in the Intensive Care Unit.

Within 24 hours of admission, he became oliguric and laboratory studies revealed potassium of 6 mmol/L and creatinine of 5.51 mg/dL (ref 0.84-1.21 mg/dL). Additional laboratory studies showed LDH 2618 IU/L, total bilirubin 0.6 mg/dL, platelet count of 33×10⁹/L, hemoglobin of 8.0 g/dL, reticulocyte count 2.4% (absolute 53.7 cells/mm³), haptoglobin of <30 g/dL, fibrinogen of 445 mg/dL, C3 of 110 mg/dL (ref 96-185 mg/dL), and C4 of 44 mg/dL (ref 18-53 mg/dL). Laboratory trends are shown in **Figure 1**. A blood smear was significant for schistocytes, spherocytes, and anisocytosis. He was started on hemodialysis for acute renal failure.

Due to presumptive diagnosis of thrombotic thrombocytopenic purpura (TTP), he was begun on plasma exchange and given IV methylprednisolone 1 mg/kg after ADAMTS-13 level was drawn. A stool culture did not grow enterohemorrhagic *Escherichia coli* (EHEC) strains and antigen PCR was negative for shiga-like toxins 1 and 2. ADAMTS-13 levels returned with 74% activity, showing normal activity (ref >20% activity). Steroids and plasma exchange were discontinued, and he was diagnosed with atypical HUS and given 1 dose 900 mg of intravenous eculizumab per week for a total of 4 weeks. Following administration, his microangiopathic hemolytic anemia improved (Hgb of 8 g/dL), his platelets and LDH corrected toward normal limits (Plts 348×10⁹ and LDH 222 IU/L after 3 weeks of eculizumab), his total bilirubin was 0.3 mg/dL,

and his renal function improved (creatinine 2.96 mg/dL after 3 weeks of eculizumab), allowing discontinuation of hemodialysis after 2 months. Given the temporal relationship and negative stool cultures, the atypical HUS was deemed to be due to FEIBA administration. Notably, he had no family history of atypical HUS and declined genetic testing due to cost. Hypercoagulable work-up after resolution of the acute event showed heterozygosity for factor V Leiden mutation and was negative for lupus anticoagulant and prothrombin gene mutation and serum levels of protein C and S level within normal limits. Follow-up over 4 years after hospitalization showed no evidence of recurrent atypical HUS and the patient has not needed maintenance eculizumab.

Discussion

This is the first report in the literature of an acquired TMA disorder/atypical HUS secondary to administration of the aPCC FEIBA. Use of aPCCs has been gaining favor over component blood products when reversing vitamin K antagonists and direct oral anticoagulants. Several small trials have been conducted that used small doses of 500-1000 units FEIBA infused at 1-2 units per minute to achieve good reversal of vitamin K antagonist [7,8]. This range of fixed doses is much smaller than the therapeutic dose studied in those treated for hemophilia or acquired inhibitors at 50-100 units/kg [5].

Common adverse events of FEIBA include diarrhea, nausea, and vomiting. However, initial studies using FEIBA for hemophiliacs with joint and muscle bleeding [10] or as prophylaxis for bleeding in those with inhibitors [5] did not report thrombotic complications. However, post-marketing surveillance has revealed macro-thrombotic complications (strokes, pulmonary embolisms, and DVTs) in those receiving aPCC, particularly when administered at high doses or increased frequency [4], whereas micro-thrombotic complications are rarely described.

There is a single case report of the prothrombin complex concentrate K-Centra causing atypical HUS. This patient was treated in a similar fashion with HD and eculizumab to achieve a similarly good result [3]. The mechanism of aHUS is hypothesized to occur from impaired regulation of the terminal complement pathway. Terminal complement activation leads to endothelial damage and development of thrombosis and the 3 features of aHUS: microangiopathic hemolytic anemia, thrombocytopenia, and renal injury [2]. This also explains the efficacy of eculizumab, a monoclonal antibody directed against complement protein C5 [11], in achieving temporary or total remission of atypical HUS in other case reports and in our patient. Thus, the mechanism of FEIBA-induced aHUS may be due to terminal complement activation.

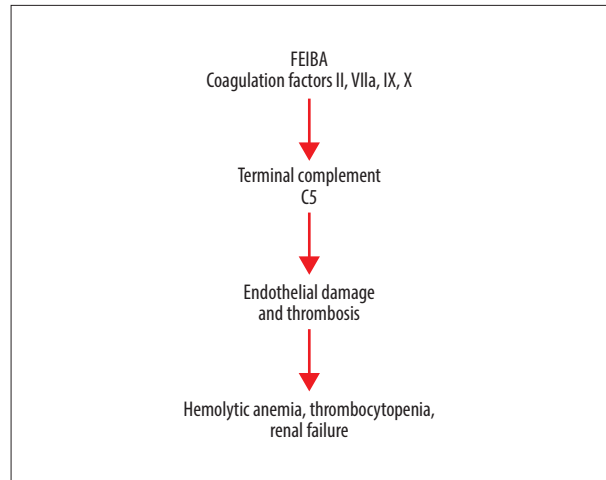


Figure 2. Proposed mechanism of Factor Eight Inhibitor Bypassing Activity (FEIBA)-induced Atypical Hemolytic Uremic Syndrome (aHUS).

The intricate interplay between the coagulation cascade and complement system is well known; however, the specific physiologic mechanism remains elusive [12]. In vitro assays and in vivo mouse studies have shown the ability of thrombin to activate complement [12,13]. Furthermore, additional ex vivo studies have shown the ability of factors IXa, Xa, XIa, thrombin, and plasmin to cleave C3 and C5 into their activated forms [14,15]. However, more recently, in vivo baboon studies have shown that supraphysiologic levels of factor 10 are able to induce complement activation, but thrombin and plasmin did not activate complement in baboons [16]. Taken together, this demonstrates the potential of coagulation factors to activate terminal complement through both thrombin-dependent and thrombin-independent mechanisms. Herein lies a possible mechanism by which aHUS can be caused by factor administration, as in our patient.

Our patient was treated with a very large dose of FEIBA containing coagulation factors II, VII, IX, and X [17]. Therefore, we hypothesize the supraphysiologic dose of constituent coagulation factors induced terminal complement activation. The resultant terminal complement activation can serve as the impetus for the development of atypical HUS, as illustrated in **Figure 2**. Unfortunately, we were unable to measure C5 levels during his treatment and further research would be needed to support this mechanism. At the time of this case, our institution did not have ability to measure C5 levels and to track this with treatment. In the setting of emergent anticoagulation reversal therapy with FEIBA in those without hemophilia, this case shows the need to consider conservative dosing to avoid risk of adverse effects.

In addition, debate remains concerning the optimal duration of eculizumab treatment due to its financial burden.

Recommendations based on limited case reports and data suggest that for secondary aHUS caused by drugs, eculizumab may be discontinued when hematologic remission is established [18,19]. In some cases of aHUS, eculizumab has been recommended for indefinite use. However, the scarcity of outcomes data for drug-induced aHUS outside the context of certain drugs like gemcitabine and tacrolimus universal recommendations cannot be made for all drug-induced aHUS [20]. Our case report highlights the efficacy of a limited trial of eculizumab treatment of FEIBA-induced aHUS.

The lack of complete and serial laboratory testing limits our report. Low serum C3 level was observed in a previous case report, while initial complement level was normal in our patient [3]. Low C3 level is not universally observed in the acute phase and the comprehensive complement panel was not available at our institution at the time [21]. Our report also differs by the category of agent used, in that K-Centra contains no activated factors but FEIBA contains activated factor VII. Additionally, work-up for atypical HUS should include genetic testing, but this was not covered by his insurance.

References:

1. Noris M, Remuzzi G. Atypical hemolytic-uremic syndrome. *N Engl J Med*, 2009;361(17):1676-87
2. Afshar-Kharghan V. Atypical hemolytic uremic syndrome. *Hematology*, 2016; 2016(1):217-25
3. Thajudeen B, Sussman A, Bracamonte E. A case of atypical hemolytic uremic syndrome successfully treated with eculizumab. *Case Rep Nephrol Urol*, 2013;3(2):139-46
4. Corp BH. FEIBA NF (Anti-Inhibitor Coagulant Complex) [package insert]. 2013
5. Hilgartner MW, Knatterud GL. The use of factor eight inhibitor by-passing activity (FEIBA immuno) product for treatment of bleeding episodes in hemophiliacs with inhibitors. *Blood*, 1983;61(1):36-40
6. Awad NI, Cocchio C. Activated prothrombin complex concentrates for the reversal of anticoagulant-associated coagulopathy. *P T*, 2013;38(11):696-701
7. Stewart WS, Pettit H. Experiences with an activated 4-factor prothrombin complex concentrate (FEIBA) for reversal of warfarin-related bleeding. *Am J Emerg Med*, 2013;31(8):1251-54
8. Wojcik C, Schymik ML, Cure EG. Activated prothrombin complex concentrate factor VIII inhibitor bypassing activity (FEIBA) for the reversal of warfarin-induced coagulopathy. *Int J Emerg Med*, 2009;2(4):217-25
9. Yasaka M, Sakata T, Minematsu K, Naritomi H. Correction of INR by prothrombin complex concentrate and vitamin K in patients with warfarin-related hemorrhagic complication. *Thromb Res*, 2002;108(1):25-30
10. Sjamsoedin LJ, Heijnen L, Mauser-Bunschoten EP, et al. The effect of activated prothrombin-complex concentrate (FEIBA) on joint and muscle bleeding in patients with hemophilia A and antibodies to factor VIII. A double-blind clinical trial. *N Engl J Med*, 1981;305(13):717-21
11. Legendre CM, Licht C, Muus P, et al. Terminal complement inhibitor eculizumab in atypical hemolytic-uremic syndrome. *N Engl J Med*, 2013;368(23):2169-81
12. Krisinger MJ, Goebeler V, Lu Z, et al. Thrombin generates previously unidentified C5 products that support the terminal complement activation pathway. *Blood*, 2012;120(8):1717-25
13. Huber-Lang M, Sarma JV, Zetoune FS, et al. Generation of C5a in the absence of C3: A new complement activation pathway. *Nat Med*, 2006;12(6):682-87
14. Amara U, Flierl MA, Rittirsch D, et al. Molecular intercommunication between the complement and coagulation systems. *J Immunol (Baltimore, Md, 1950)*, 2010;185(9):5628-36
15. Amara U, Rittirsch D, Flierl M, et al. Interaction between the coagulation and complement system. *Adv Exp Med Biol*, 2008;632:71-79
16. Keshari RS, Silasi R, Lupu C, et al. In vivo-generated thrombin and plasmin do not activate the complement system in baboons. *Blood*, 2017;130(24):2678-81
17. Turecek PL, Varadi K, Gritsch H, Schwarz HP. FEIBA: Mode of action. *Haemophilia*, 2004;10(Suppl. 2):3-9
18. Caverio T, Rabasco C, Lopez A, et al. Eculizumab in secondary atypical haemolytic uraemic syndrome. *Nephrol Dial Transplant*, 2017;32(3):466-74
19. Fakhouri F, Loirat C. Anticomplement treatment in atypical and typical hemolytic uremic syndrome. *Semin Hematol*, 2018;55(3):150-58
20. Olson SR, Lu E, Sulpizio E, et al. When to stop eculizumab in complement-mediated thrombotic microangiopathies. *Am J Nephrol*, 2018;48(2):96-107
21. Noris M, Galbusera M, Gastoldi S, et al. Dynamics of complement activation in aHUS and how to monitor eculizumab therapy. *Blood*, 2014;124(11):1715-26

Conclusions

As FEIBA gains further clinical use, this case report will serve as a precaution for the potential development of aHUS as a complication of FEIBA administration. In addition, this case report suggests more conservative dosing of FEIBA in the reversal of vitamin K antagonists in those with no history of hemophilia, as shown in previous small trials. The potential mechanism discussed herein serves as a catalyst for future study and the short trial of eculizumab shows its efficacy in treating aHUS secondary to FEIBA.

Conflicts of Interest

None.