



Pulmonary Fibrosis Due to COVID-19 Pneumonia

Servet Kayhan, MD¹, Ercan Kocakoç, MD²

Departments of ¹Chest Disease and ²Radiology, Bahçelievler Medicalpark Hospital, Altınbaş University, Istanbul, Turkey

Dear Editor,

We read the recent article published in KJR titled "Prediction of the Development of Pulmonary Fibrosis Using Serial Thin-Section CT and Clinical Features in Patients Discharged after Treatment for COVID-19 Pneumonia" with great interest (1). The authors assessed the predictors of pulmonary fibrosis using clinical data and follow-up chest computed tomography (CT) in patients with coronavirus disease (COVID-19) pneumonia (1). The most common CT findings in COVID-19 pneumonia have been described as ground-glass opacities (GGOs) with or without consolidation, crazy-paving pattern, interstitial thickening, irregular interface, and parenchymal band mainly bilateral and lower lobes predilection with peripheral locations (1). Authors found evidence of fibrosis, i.e., irregular interface and parenchymal bands, in nearly half of the patients on initial CT, and in about 85–92% of the patients on follow-up CT, and they speculated that interstitial thickening, irregular interface, coarse reticular pattern and parenchymal band, manifesting in the process of the disease, might be predictors of pulmonary fibrosis in patients who recovered from COVID-19 pneumonia (1, 2). An irregular interface and parenchymal band might be two early predictors of pulmonary fibrosis (1). From the clinical point of view, fibrosis can be usually seen in elderly patients with severe

clinical conditions, especially in patients with higher level of C-reactive protein and interleukin-6 (1). We are not sure whether the authors detected typical pulmonary fibrosis and honeycomb appearances during the follow-up of COVID-19 patients. We encountered a typical pulmonary fibrosis during the follow-up of one COVID-19 patient, whose initial CT examination showed only GGO. Interstitial thickening, irregular interface, or parenchymal bands were not detected on initial CT examination.

A 59-year old man was admitted to the chest department with a one-week history of dry cough and acute onset of fever and dyspnea. Unenhanced CT revealed focal GGOs in the left upper lobe of the lung (Fig. 1A). Laboratory results showed elevated C-reactive protein, D-dimer, lactate dehydrogenase, and ferritin levels, and decreased leukocyte, and lymphocyte counts. Oxygen saturation level was 85% at room air. COVID-19 infection was suspected; antiviral treatment (oseltamivir 75 mg 2 x 1, favipiravir 2 x 1600 mg first two days, then 2 x 600 mg) and supportive treatment were started. At admission, reverse transcriptase-polymerase chain reaction test (RT-PCR test) result was negative. One week later, control chest CT was obtained and chest CT showed bilateral multifocal mixed GGOs and crazy-paving pattern (Fig. 1B). A repeat RT-PCR test result was positive. Five days later, fever decreased, oxygen saturations levels improved and control chest CT showed decreased GGOs and crazy-paving patterns with peripheral cystic changes and interlobular septal thickening causing the typical 'honeycomb' appearances due to pulmonary fibrosis (Fig. 1C). Respiratory rehabilitations were started and four days later, all symptoms including fever, cough, and dyspnea improved. The patient was discharged and recommended to continue respiratory rehabilitations.

In conclusion, although some fibrosis indicators such as irregular interfaces, parenchymal bands, and fibrotic changes during the follow-up of COVID-19 patients have been described in the literature, typical honeycomb appearances and typical pulmonary fibrosis have not been described before, to the best of our knowledge (1, 3). Irregular interface and parenchymal bands, which were described as two early predictors of pulmonary fibrosis may not be seen on initial CT examination.

Received: May 27, 2020 **Revised:** May 27, 2020

Accepted: June 5, 2020

Corresponding author: Ercan Kocakoç, MD, Department of Radiology, Bahçelievler Medicalpark Hospital, Altınbaş University, Kultur Street No:1 E5 highway 34160 Bahçelievler-Istanbul-TR, Istanbul, Turkey.

• E-mail: ercankocakoc@yahoo.com

This is an Open Access article distributed under the terms of the Creative Commons Attribution Non-Commercial License (<https://creativecommons.org/licenses/by-nc/4.0>) which permits unrestricted non-commercial use, distribution, and reproduction in any medium, provided the original work is properly cited.

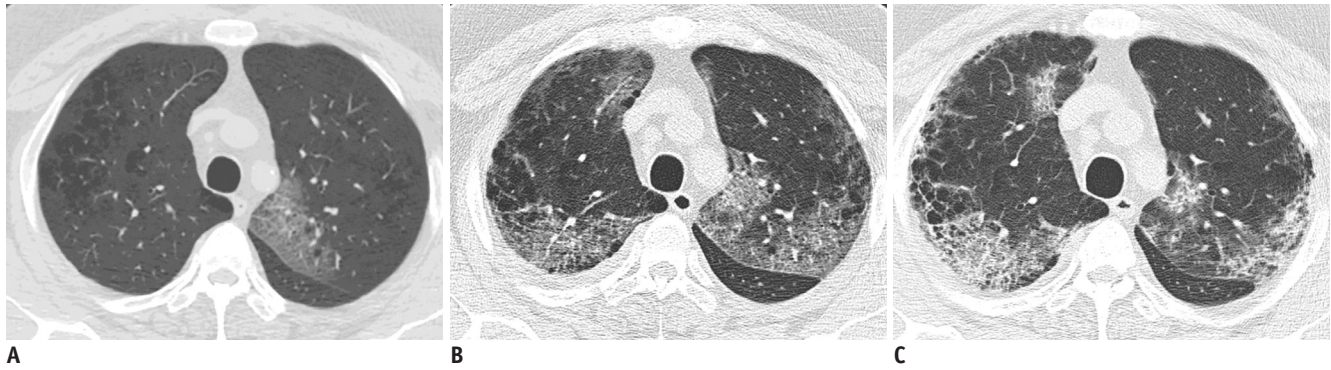


Fig. 1. 59-year old man with one-week history of dry cough and acute onset of fever and dyspnea.

A. Unenhanced chest CT obtained on day 7 after onset of symptoms reveals focal ground-glass opacities in left upper lobe of lung. **B.** Chest CT was obtained one week later and shows bilateral multifocal mixed ground-glass opacities and crazy-paving pattern. **C.** Chest CT obtained on day 19 shows decreased ground-glass opacities and crazy-paving patterns with peripheral cystic changes and interlobular septal thickening causing typical 'honeycomb' appearances due to pulmonary fibrosis.

ORCID iDs

Ercan Kocakoç

<https://orcid.org/0000-0002-0060-3296>

Servet Kayhan

<https://orcid.org/0000-0003-4226-2781>

REFERENCES

1. Yu M, Liu Y, Xu D, Zhang R, Lan L, Xu H. Prediction of the

development of pulmonary fibrosis using serial thin-section CT and clinical features in patients discharged after treatment for COVID-19 pneumonia. *Korean J Radiol* 2020;21:746-755

2. Ward PA, Hunninghake GW. Lung inflammation and fibrosis. *Am J Respir Crit Care Med* 1998;157:S123-S129

3. Wei J, Yang H, Lei P, Fan B, Qiu Y, Zeng B, et al. Analysis of thin-section CT in patients with coronavirus disease (COVID-19) after hospital discharge. *J Xray Sci Technol* 2020;28:383-389

Response

Minhua Yu, MD, Haibo Xu, MD, PhD

All authors: Department of Radiology, Zhongnan Hospital of Wuhan University, Wuchang District, Wuhan, China

To the Editor,

We sincerely appreciate your comments on our article.

Concerning the typical pulmonary fibrosis feature “honeycombing,” the article “Fleischner Society: Glossary of Terms for Thoracic Imaging” published in *Radiology* in 2008 has clearly defined it (1).

On CT scans, the appearance of honeycombing is clustered cystic air spaces, typically of comparable diameters of the order of 3–10 mm, but occasionally as large as 2.5 cm (1). Honeycombing is usually subpleural and is characterized by well-defined walls (1).

In our study, we found that pulmonary fibrosis on chest CT imaging included parenchymal bands, irregular interfaces, coarse reticular pattern, and traction bronchiectasis (2). We have not found a typical feature of honeycombing in the follow-up of coronavirus disease (COVID-19) patients during the retrospective study.

You have encountered and reported a 59-year-old COVID-19 patient with typical pulmonary fibrosis features of “honeycombing” during follow-up. In figure 1C, the chest CT obtained on day 19 after the onset of symptoms, shows a more “coarse reticular pattern” rather than “typical honeycombing” in the subpleural area of the right upper lobe of the lung. A lot of normal parenchyma that is not completely destroyed in this area can be recognized, with

interlobular septal thickening and interlobular exudation. A continued long-time follow-up in this patient is advised, to see whether such features on chest CT scan can be finally resorbed.

The initial features of COVID-19 on the CT scan are ground-glass opacities, with or without consolidation (3). Fibrous stripes could also be observed in patients initially (3). In our study, fibrosis features, such as irregular interface and parenchymal band, appeared in some patients initially, and these could be the early predictors of pulmonary fibrosis.

We sincerely appreciate your comments and we believe that your comments have enriched our study.

ORCID iDs

Haibo Xu

<https://orcid.org/0000-0002-8451-8979>

Minhua Yu

<https://orcid.org/0000-0001-9360-4177>

REFERENCES

1. Hansell DM, Bankier AA, MacMahon H, McLoud TC, Müller NL, Remy J. Fleischner Society: glossary of terms for thoracic imaging. *Radiology* 2008;246:697-722
2. Yu M, Liu Y, Xu D, Zhang R, Lan L, Xu H. Prediction of the development of pulmonary fibrosis using serial thin-section CT and clinical features in patients discharged after treatment for COVID-19 pneumonia. *Korean J Radiol* 2020;21:746-755
3. Pan Y, Guan H, Zhou S, Wang Y, Li Q, Zhu T, et al. Initial CT findings and temporal changes in patients with the novel coronavirus pneumonia (2019-nCoV): a study of 63 patients in Wuhan, China. *Eur Radiol* 2020;30:3306-3309