

Leiomyoma of the thyroid gland with psammoma bodies

Aminu Zakari Mohammed, Steven Tijjani Edino¹, Ali Bala Umar

Departments of Pathology and ¹Surgery, Bayero University Kano, Aminu Kano Teaching Hospital, Kano, Nigeria

ABSTRACT

We report a rare case of leiomyoma of the thyroid gland associated with psammoma bodies. The patient was a 9-year-old black African boy. Prior to this, only five cases of primary thyroid leiomyoma have been reported. Histologically, thyroid leiomyoma was characterised by bundles of spindle smooth muscle cells with blunt-ended nuclei. Psammoma bodies were widely distributed within the tumour. Immunohistochemistry showed positive immunoreactivity for smooth muscle actin, vimentin and desmin, but was negative for a cytokeratin cocktail. Further reports of similar cases is required to ascertain the clinical significance of this lesion.

Key words: Leiomyoma, psammoma bodies, smooth muscle tumours, thyroid

Address for correspondence:

Dr. A. Z. Mohammed,
Department of Pathology,
Aminu Kano Teaching Hospital,
P.M.B 3452, Kano, Nigeria.
E-mail: aminuzm@yahoo.com

INTRODUCTION

Primary leiomyoma of the thyroid gland is a rare lesion, with only five cases reported to date.¹⁻⁴ There has been no previous report of this uncommon neoplasm in an African patient. The present report describes a case of primary leiomyoma of the thyroid gland in a 9-year-old Nigerian boy. Microscopically, the tumour was associated with psammoma bodies, which is usually observed in papillary thyroid carcinoma.

CASE REPORT

A 9-year-old boy presented to the surgical out patient clinic of Aminu Kano Teaching Hospital, Kano in July 2003 with a painless thyroid mass dating back five years. Over the years, the mass had increased progressively in size, but there were no symptoms of compression or toxicity. He achieved milestones with normal development and his family revealed no history of similar illness.

On physical examination, the thyroid mass involved the right lobe of the gland. It was oval shaped, measured 10 × 6 cm and had a smooth surface. It was hard to palpation and mobile with no evidence of attachment to underlying structures. It had caused tracheal deviation to the left, but no other significant findings were noticed on physical

examination. Indirect laryngoscopy showed normal vocal cards.

Haematological and biochemical investigations including tests of thyroid function were within normal reference values. An antero-posterior X-ray of the neck confirmed tracheal deviation to the left. Fine-needle aspiration cytology of the lesion showed features of a benign smooth muscle tumour.

The patient underwent a right hemi-thyroidectomy during which the lesion was shelled out with a rim of uninvolved gland. The postoperative state was uneventful and no recurrence was detected clinically during the following 2 years of follow-up.

Pathological findings

Gross findings

The tumour was very firm, measured 9 × 6 cm and weighed 120 g. The cut surface was well-demarcated, grey white and displayed a whorled appearance. Dark brown areas of haemorrhage were noted.

Microscopic findings

Well-circumscribed lesion consisting of interlacing bundles of spindle-shaped smooth muscle cells. The nuclei were elongated, blunt ended and centrally situated. Psammoma bodies were distributed widely within the tumour as were foci of calcification [Figures 1 and 2]. Normal compressed thyroid follicles were noted at the margins of the lesion [Figure 3].

Immunohistochemistry

Immunohistochemistry showed positive immunoreactivity for smooth muscle actin, vimentin and desmin, but was negative for a cytokeratin cocktail [Figures 4 and 5].

Access this article online

Quick Response Code:



Website:

www.nigeriamedj.com

DOI:

10.4103/0300-1652.149176

DISCUSSION

Primary thyroid leiomyomas are rare, with only five cases been reported to date, and only one of them being in a male patient.¹⁻⁴ This may suggest a predilection of the condition for females amongst whom uterine leiomyoma are extremely common. Since the condition was first described in a 3-year old girl by Hendrick,¹ subsequent reports have been in middle-aged individuals, with the present case being the second reported in a child. Additionally, it is the first documented case in a black African patient.

Clinically most cases of thyroid leiomyoma present as painless, nodular masses of the gland,⁵ or as a cold thyroid nodule.³ Delayed presentation is probably responsible for the large size of the lesion seen in our patient.

The histogenesis of smooth muscle tumours of the thyroid remains uncertain, but is believed to probably arise from smooth muscle in the vascular walls of the

thyroid blood vessels.³ Histologically, it is characterised by a fibrous capsule enclosing bundles of spindle-shaped smooth muscle cells. They have elongated, centrally located blunt-ended nuclei. Immunohistochemistry usually demonstrates immunoreactivity for smooth muscle actin, vimentin and desmin, while electron microscopy shows ultra-structural features of smooth muscle.³⁻⁵

Quite remarkable is the detection of laminated concretions (Psammoma bodies) distributed within the tumour. This finding in thyroid specimens is usually indicative of papillary carcinoma of thyroid. However, no evidence of this cancer was detected in our patient.⁶ Because of the high frequency of microscopic carcinomas either ipsilateral or contralateral in patients with non-tumour associated psammoma bodies in their thyroid,^{6,7} the entire excised specimen was submitted to identify any microscopic carcinoma. A discussion with the surgeons also emphasised the need for close clinical follow-up.

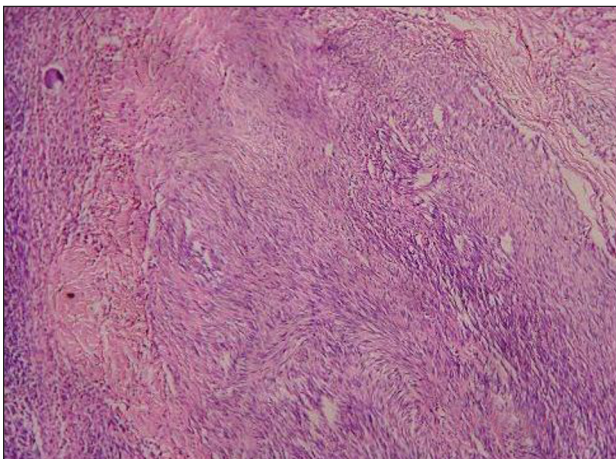


Figure 1: Leiomyoma showing closely packed bundles of spindle shaped smooth muscle cells. A focal area of calcification is present (*upper left corner*). H and E $\times 40$

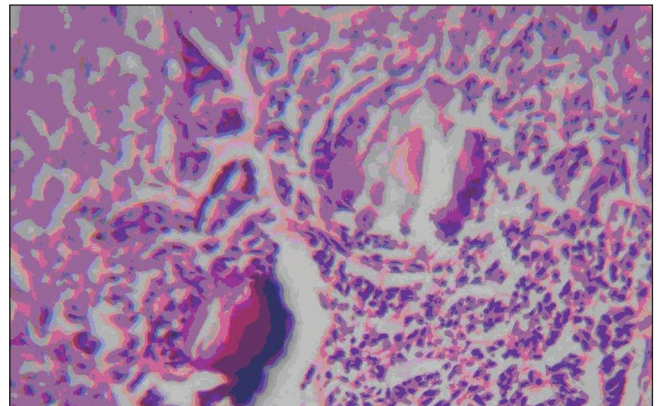


Figure 2: Psammoma body with adjacent foci of calcification surrounded by smooth muscle. H and E $\times 100$

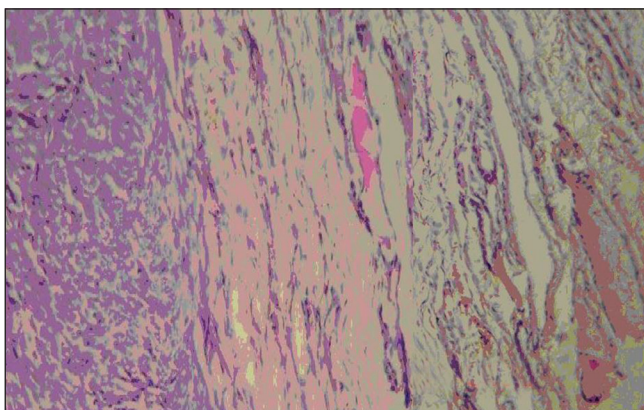


Figure 3: Border of the lesion demonstrating compressed thyroid follicles at the periphery. H and E $\times 40$

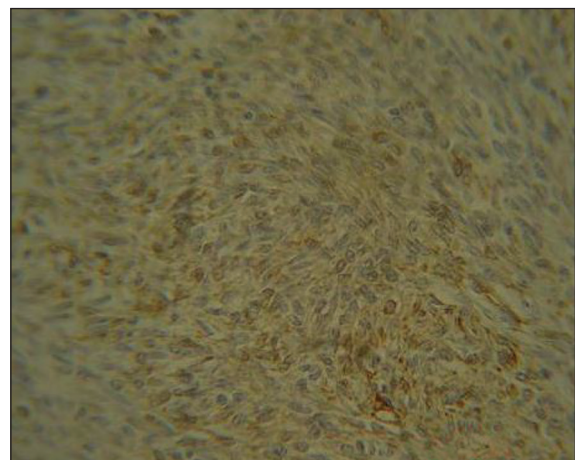


Figure 4: Immunoperoxidase staining demonstrating positive smooth muscle actin immunoreactivity

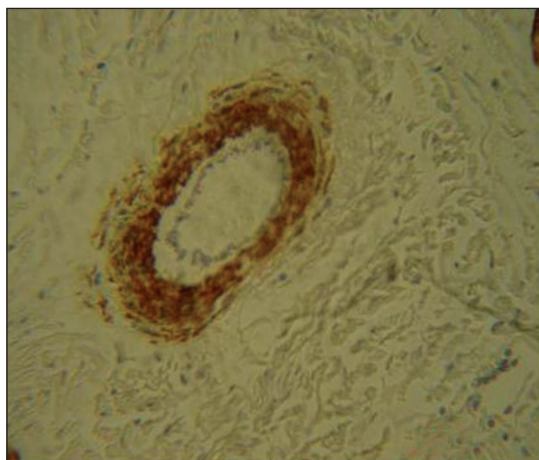


Figure 5: Medium sized artery demonstrating positive smooth muscle actin immunoreactivity of the tunica media

The origin of psammoma bodies is controversial, but has been hypothesised to originate from a single necrotic tumour cell, which serves as a nidus for a deposition of successive layers of calcium salts.⁸ The role of osteopontin production by macrophages has recently been gaining increasing attention in the development of psammoma bodies.^{9,10} Their significance in leiomyoma in the absence of thyroid carcinoma is uncertain, but psammoma bodies are not significant prognostic indicators in papillary thyroid carcinoma.¹⁰ Furthermore, recurrence has not been noted in our case after 2 years of surgery, similar to other reports in the literature. An accumulation of additional cases is required to ascertain the clinical significance of this lesion.

ACKNOWLEDGEMENT

We are grateful to Dr Sarki Abba Abdulkadir of Vanderbilt University Medical Centre, The Vanderbilt Clinic, Nashville, Tennessee for his assistance with the Immunohistochemistry.

REFERENCES

1. Hendrick JW. Leiomyoma of thyroid gland; report of case. *Surgery* 1957;42:597-9.
2. Andrión A, Bellis D, Delsedime L, Bussolati G, Mazzucco G. Leiomyoma and neurilemoma: Report of two unusual non-epithelial tumors of the thyroid gland. *Virchows Arch A Pathol Anat Histopathol* 1988;413:367-72.
3. Thompson LD, Wenig BM, Adair CF, Shmookler BM, Heffess CS. Primary smooth muscle tumours of the thyroid gland. *Cancer* 1997;79:579-87.
4. Biankin SA, Cachia AR. Leiomyoma of the thyroid gland. *Pathology* 1999;31:64-6.
5. Erkilic S, Erkilic A, Bayazit YA. Primary leiomyoma of the thyroid gland. *J Laryngol Otol* 2003;117:832-4.
6. Livosli VA. *Surgical pathology of the thyroid: Major problems in pathology*. 1st ed. Vol 2. Philadelphia: WB Saunders; 1991. p. 253-70.
7. Hunt JL, Barnes EL. Non-tumour associated psammoma bodies in the thyroid. *Am J Clin Pathol* 2003;119:90-4.
8. Johannessen JV, Sobrinho-Simoes M. The origin and significance of thyroid psammoma bodies. *Lab Invest* 1980;43:287-96.
9. Sodek J, Zhu B, Huynh MH, Brown TJ, Ringuette M. Novel functions of the matricellular proteins osteopontin and osteonectin/SPARC. *Connect Tissue Res* 2002;43:308-19.
10. Nakayama H, Okumichi T, Nakashima S, Kimura A, Ikeda M, Kajihara H. Papillary adenocarcinoma of the sigmoid colon associated with psammoma bodies and hyaline globules: Report of a case. *Jpn J Clin Oncol* 1997;27:193-6.

How to cite this article: Mohammed AZ, Edin o ST, Umar AB. Leiomyoma of the thyroid gland with psammoma bodies. *Niger Med J* 2015;56:71-3.

Source of Support: Nil, **Conflict of Interest:** None declared.

Staying in touch with the journal

1) Table of Contents (TOC) email alert

Receive an email alert containing the TOC when a new complete issue of the journal is made available online. To register for TOC alerts go to www.nigeriamedj.com/signup.asp.

2) RSS feeds

Really Simple Syndication (RSS) helps you to get alerts on new publication right on your desktop without going to the journal's website. You need a software (e.g. RSSReader, Feed Demon, FeedReader, My Yahoo!, NewsGator and NewzCrawler) to get advantage of this tool. RSS feeds can also be read through FireFox or Microsoft Outlook 2007. Once any of these small (and mostly free) software is installed, add www.nigeriamedj.com/rssfeed.asp as one of the feeds.