

Delayed Treatment of Iatrogenic Brachial Arteriovenous Fistula

Young-jin Youn, M.D., Chang Wan Kim, M.D., Il Hwan Park, M.D., Ph.D., Chun Sung Byun, M.D., Ph.D.

Department of Thoracic and Cardiovascular Surgery, Yonsei University Wonju College of Medicine, Wonju, Korea

ARTICLE INFO

Received March 27, 2020

Revised May 17, 2020

Accepted May 28, 2020

Corresponding author

Chun Sung Byun

Tel 82-33-741-1323

Fax 82-33-742-0666

E-mail csbyun@yonsei.ac.kr

ORCID

https://orcid.org/0000-0001-5409-6798

Iatrogenic vascular injuries may occur during venipuncture, arterial cannulation, or catheterization procedures. Brachial arteriovenous fistula (AVF) resulting from antecubital vascular access is rare and develops slowly. We report the case of an 18-year-old man who had developed iatrogenic brachial AVF. He had a history of several venipunctures in the left arm at the age of 10 months. Doppler ultrasonography and computed tomographic angiography were used to establish a diagnosis of brachial AVF, and surgical correction of the AVF was performed. As our case indicates, delayed surgery can be considered as a treatment option and may be associated with a decreased risk of vascular complications in the management of iatrogenic brachial AVF in infants.

Keywords: Arteriovenous fistula, Brachial artery injury, Vascular system injury

Case report

An 18-year-old man was referred to the department of thoracic and cardiovascular surgery in Wonju Severance Christian Hospital with a pulsatile swelling on his left arm that had been present for more than 17 years. When the patient was 10 months old, he was admitted to the hospital for the treatment of pneumonia. At that time, he received several venipunctures in his left antecubital area. When the patient presented as an adult, he had no specific symptoms, such as dyspnea or steal syndrome of the distal arm. Physical examination revealed a non-tender pulsating fusiform mass measuring 4 cm long and 2 cm wide on the medial side of the left upper arm, just proximal to the antecubital area. A palpable thrill was detected, and a grade 3 continuous murmur was heard. The left radial and ulnar pulses were palpable. The patient's blood pressure was normal, with no difference between the right and left arms. No changes in blood pressure or heart rate were observed upon compression of the fistula, and the laboratory results were normal. Color Doppler ultrasonography of the left arm revealed a communication channel between the brachial artery and vein. The flow volume was 240 mL/min. Computed tomographic (CT) angiography revealed a brachial arteriovenous fistula (AVF) (Fig. 1A). With the patient under general anesthesia, a skin incision was made on

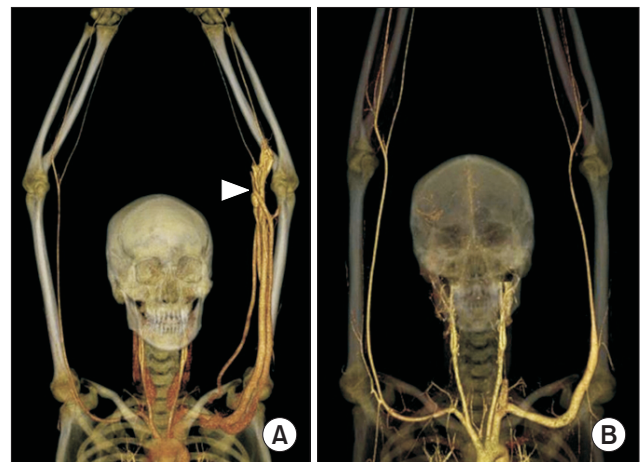


Fig. 1. Preoperative CT angiogram. (A) A brachial arteriovenous fistula (white arrowhead) with an engorged vein. (B) Postoperative 6-month CT angiogram showed a normalized artery. CT, computed tomography.

the medial side of the left upper arm. Pulsating venous engorgement was noted and measured 4 cm in diameter. After a vertical venous incision was made with compression of the proximal and distal vessel, the fistula was measured to be approximately 1 cm long and 0.5 cm wide (Fig. 2A, B). The fistulous opening was closed continuously with non-absorbable monofilament polypropylene 6-0 suture

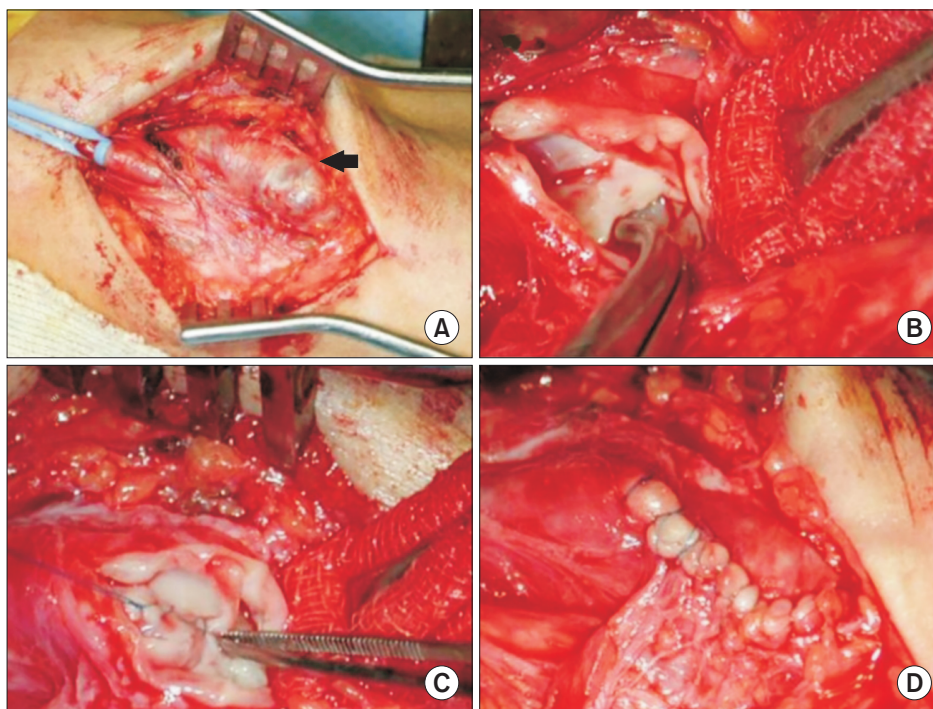


Fig. 2. (A) The black arrow shows the engorged vein, and the proximal part of the brachial artery was encircled with a rubber sling. (B) A fistulous opening to the arterial lumen was noted. (C) The fistula was repaired continuously. (D) The vein was closed.

through the venous side (Fig. 2C, D). Postoperative 6-month CT angiography showed normalized vessels (Fig. 1B). The patient provided written informed consent for publication of clinical details and images.

Discussion

Pediatric vascular injuries are becoming increasingly common, and repeated venipuncture may result in pseudoaneurysm or AVF, especially in infants [1]. Complications of vascular injury, such as limb ischemia, may arise due to small vessel size and are important problems to address. Early diagnosis and surgical correction have been indicated in pediatric patients as opposed to delayed operation [2]. However, the natural history of peripheral vascular injuries is uncertain, and surgical dicta previously mandated prompt operative repair. We describe a rare case illustrating the long-term natural course of such an injury over 17 years and the delayed operative result of an iatrogenic brachial AVF.

The incidence of pediatric iatrogenic vascular injuries is increasing with the development of percutaneous techniques and minimally invasive procedures [1]. Iatrogenic femoral AVF as a result of attempts at arterial or venous access such as venipuncture, arterial cannulation, or catheterization procedures is common, with a reported incidence of 0.86% [3]. In infants, the radial artery at the wrist

is the most common site for arterial blood sampling. Iatrogenic brachial AVFs in infancy are rare and can be diagnosed as late as school age. The case in this report was diagnosed at high-school age, and 17 years had passed since the brachial vessel was injured. Acquired fistulas may also arise slowly. Megremis et al. [4] reported a 5-year natural history of a chronic brachial AVF secondary to venipuncture in an infant; the swelling was first noticed by the patient's mother 2 years before the patient presented to the clinic. In our case, we report 17 years of natural history, and our patient's mother noticed the condition 15 years prior to presentation. Iatrogenic brachial AVFs without coagulation deficiencies are rare, especially in infancy. Repeated venipuncture to determine bilirubinemia in the neonatal period may cause accidental arterial puncture and pseudoaneurysm.

A diagnosis of pseudoaneurysm can be confirmed through ultrasonography or CT angiography. Once the diagnosis is confirmed, a follow-up ultrasound examination should be arranged at 1-week intervals until resolution of the false aneurysm. Because the incidence of intragenic AVF is relatively low in children compared to adults, the diagnostic approaches have been extrapolated from the guidelines for adults.

The natural history of untreated brachial vessel injuries is not well known, and serious complications can occur months or even years after injury. Spontaneous closure was

noted within 1 year in 38% of adult catheterization patients, and clinicians were unable to predict whether a fistula would close spontaneously. Early diagnosis with surgical treatment has been the treatment option in the past. The accepted diagnosis clues are arterial steal with ischemia, cardiovascular dilatation, myocardial hypertrophy, congestive heart failure, and failure of spontaneous fistula closure. Few reports have been published regarding the use of endovascular stents to treat iatrogenic brachial fistula [5]. Migration or fracture of the stent may also arise after endovascular procedures.

Pediatric vascular injuries require a clear plan for management and timely intervention in order to avoid early and late complications. Pediatric vascular injury is associated with some unique concerns regarding the small size of the injured vessel, and complications can occur more frequently than in adults. If we can predict the natural course of vascular injuries in pediatric patients, delaying the operation until the child grows larger has some advantages for preventing surgical complications. Regular follow-up with ultrasonography is very helpful in deciding between prompt or delayed surgery. In our patient, we closed the fistulous opening directly via the venous side without separating the artery and vein. This is thought to carry a risk of AVF recurrence; therefore, we have used Doppler ultrasonography to check the patient's arm regularly. However, no postoperative complication has been observed in the past 3 years. Conclusively, delayed surgery can be considered as a treatment option and may be associated with a decreased risk of vascular complications compared with prompt operation in the management of iatrogenic brachi-

al AVF in an infant if the patient is followed up regularly.

Conflict of interest

No potential conflict of interest relevant to this article was reported.

ORCID

Young-jin Youn: <https://orcid.org/0000-0003-4694-9206>

Chang Wan Kim: <https://orcid.org/0000-0001-9818-8379>

Il Hwan Park: <https://orcid.org/0000-0001-8155-1880>

Chun Sung Byun: <https://orcid.org/0000-0001-5409-6798>

References

1. Ontell SJ, Gauderer MW. *Iatrogenic arteriovenous fistula after multiple arterial punctures*. Pediatrics 1985;76:97-8.
2. Dzepina I, Unusic J, Mijatovic D, Bulic K. *Pseudoaneurysms of the brachial artery following venipuncture in infants*. Pediatr Surg Int 2004;20:594-7.
3. Kelm M, Perings SM, Jax T, et al. *Incidence and clinical outcome of iatrogenic femoral arteriovenous fistulas: implications for risk stratification and treatment*. J Am Coll Cardiol 2002;40:291-7.
4. Megremis SD, Christaki MA, Mourkoyiannis NK, Papadopoulos GS, Tsilimigaki AM. *Iatrogenic brachial arteriovenous fistula in a child: color Doppler ultrasonographic evaluation*. J Ultrasound Med 2006; 25:809-12.
5. Cronin P, McPherson SJ, Meaney JF, Mavor A. *Venous covered stent: successful occlusion of a symptomatic internal iliac arteriovenous fistula*. Cardiovasc Intervent Radiol 2002;25:323-5.