



Vitamin C deficiency in a 12-year-old male presenting with knee pain: a case report

Kellie Cloney¹ · Suzanne Ramsey² · Emma Burns³

Received: 3 February 2022 / Accepted: 21 April 2022 / Published online: 9 May 2022

© The Author(s), under exclusive licence to Canadian Association of Emergency Physicians (CAEP)/ Association Canadienne de Médecine d'Urgence (ACMU) 2022

Keywords Pediatrics · Nutritional Deficiencies · Limp

Introduction

Vitamin C deficiency is a relatively rare pediatric disease, the literature in children being largely made up of case reports. However, the incidence of vitamin C deficiency in children may be on the rise [1]. Increased risk for nutritional deficiencies is especially true given the COVID-19 pandemic. It is estimated that since March 2020, food insecurity has tripled in households with young children [2] making it more important than ever to understand this diagnosis.

Vitamin C deficiency can result in symptoms of scurvy after only 3 months of restricted intake. Vitamin C is crucial for making pro-collagen, therefore deficiency results in collagen abnormalities throughout the body: abnormal dentition, changes in vasculature, and abnormal osteoid matrix [3]. Consistent with abnormal collagen production symptoms of [3]. Musculoskeletal (MSK) changes are also commonly present, including joint pain, myalgias, weakness, and decreased weight-bearing [4]. Here we outline the case of a pediatric patient presenting with leg pain who was ultimately diagnosed with vitamin C deficiency.

Clinical presentation

A 12-year-old male with high functioning autism spectrum disorder (ASD) was brought to the emergency department (ED) after falling down two stairs, landing on his right knee. Weeks prior to the fall, he was having non-specific leg pain, located at the mid-quadriceps level bilaterally. After the fall, he complained of painful gait, right knee and ongoing quadricep pain. His right knee was tender, with mild bruising over the patella, but no joint effusion, joint line tenderness or instability. He had no hip pain and had a normal hip exam. He was found to have a petechial rash on his shins (Fig. 1A) that was reportedly present intermittently over the last few months. He was systemically well. X-rays were done of his knee and hip with no evidence of fracture, slipped capital femoral epiphysis, or joint effusions (Fig. 1B, C). He was discharged home with a diagnosis of soft tissue injury.

The patient returned to the ED 2 days later with increasing leg pain and inability to weight bear. He remained systemically well with an unchanged exam, making a septic joint unlikely. Due to progression of symptoms, bloodwork was sent. His CBC, INR and PTT were normal. His inflammatory markers were elevated (CRP of 26.4 mg/L, ESR of 50 mm/h). A consultant in the ED recognized the perifollicular hemorrhagic rash as consistent with vitamin C deficiency. Upon review of the patient's dietary history, he was found to have an extremely limited diet with no consumption of fruits, vegetables, or vitamin supplements. His diet had worsened during the pandemic lockdown. Vitamin C levels were drawn, and vitamin C 500 mg po BID was started in the ED based on the high index of suspicion and risk of bleeding.

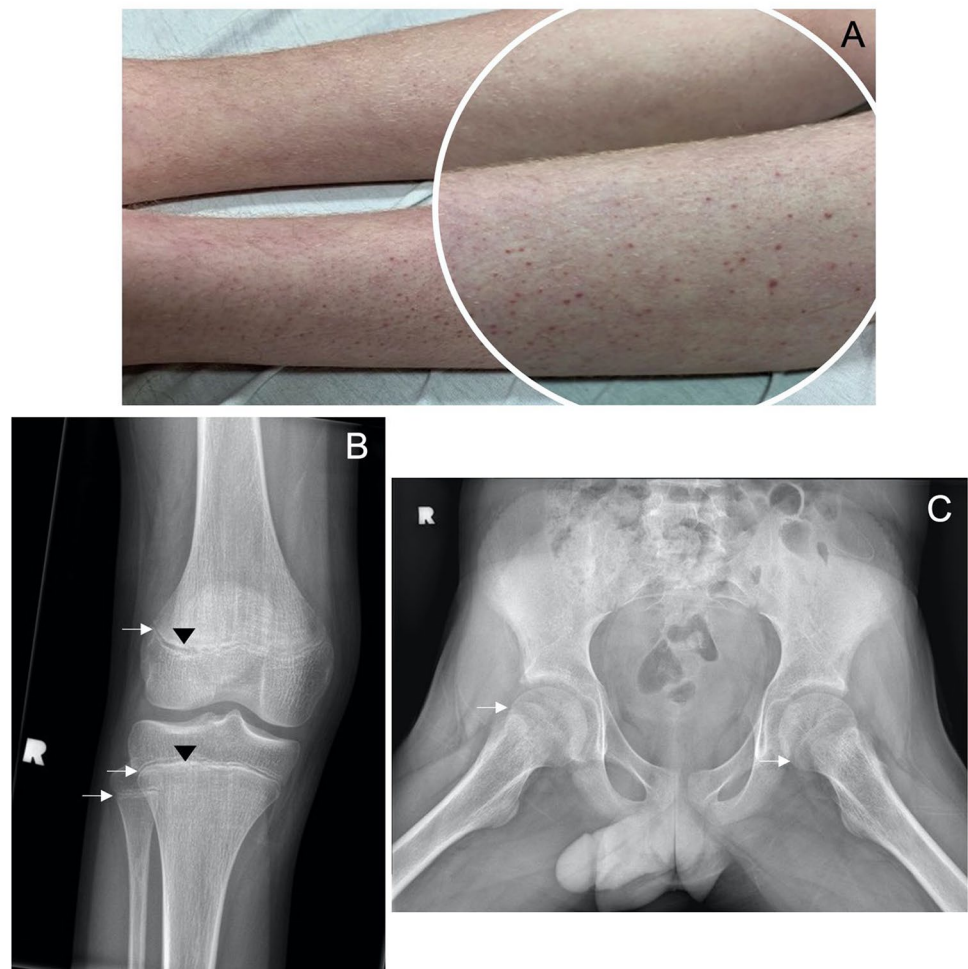
✉ Emma Burns
ecburns@dal.ca

¹ Pediatric Resident, Dalhousie University, IWK Health, 5850 University Ave, Halifax, NS B3J 3G9, Canada

² Division of Pediatric Rheumatology, Dalhousie University, IWK Health, Halifax, NS, Canada

³ Division of Pediatric Emergency Medicine, Dalhousie University, IWK Health, Halifax, NS, Canada

Fig. 1 **A** Patient's lower legs showing petechial rash consistent with perifollicular hemorrhagic rash. **B** Plain film, AP view, of right knee, showing healthy and open growth plates of the femur, fibula, and tibia (arrows) and no evidence of fractures, osteopenia, or soft tissue inflammation. Increased lucency on the diaphysis side, in keeping with Frankel's lines (black arrowhead). **C** Plain film, frog leg view of the hips, showing healthy and open growth plates of the femur (arrows), with no displacement of the femoral head. No fractures



Discussion

In the ED, the differential for difficulty weight-bearing is lengthy and includes, trauma, infection, hemarthrosis, neoplasm, and inflammatory causes. However, in children with a restricted diet, nutrient deficiencies must be considered. Eighty percent of patients with scurvy present with musculoskeletal pathology [4]. Symptoms include, arthralgias in the knees or ankles, and myalgias. Children often first present with limp or refusal to walk [4]. Unlike physical exam findings with inflammatory joint changes range of motion of affected joints can be normal. This results in a seemingly well child whose sole complaint is decreased weight-bearing. To confirm the diagnosis, serum vitamin C levels must be assessed; however, radiographic investigations can yield diagnostic clues. X-ray findings include diffuse osteopenia, as well as Frankel's lines — lucent areas at the zone of calcification that represent disorganized osteoid matrix, as seen on the images of our patient's femur (Fig. 1B). MRI changes are also common in scurvy. The typical findings are areas of decreased

signal on T1-weighted imaging and increased signal on T2-weighted images within the bone marrow [6]. These changes were seen in the pelvis, hip, and femur of our patient.

Symptoms of scurvy are varied, and early signs and symptoms can be vague, such as fatigue and malaise, resulting in a difficult diagnosis to make in the ED. Dermatological findings can be an important sign of vitamin C deficiency [3]. Oral mucosa will often have gingival disease, highlighted by bleeding from the gums and loose teeth. Skin changes include a spectrum from petechia through significant ecchymoses and hemorrhage. Corkscrew hairs and hyperkeratosis can also occur. Lower limb petechia are commonly found at the base of the hair follicles (Fig. 1A) [3]. The presence of a perifollicular hemorrhagic rash should raise suspicion of vitamin C deficiency.

The most abundant sources of vitamin C are fruits and vegetables [5]. Patients with ASD often have challenges with sensory input, and eating can be a source of difficulty resulting in nutrient deficiencies. In a time where food security is of increasing concern, a quick dietary screen in the emergency department can be essential [1]. Our patient's

serum vitamin C level confirmed the diagnosis with a level of $< 5 \mu\text{mol/L}$ (normal $> 28 \mu\text{mol/L}$). Vitamin C deficiency is easy to treat, and often results in timely symptom reversal while awaiting lab confirmation.

Take-home points

Musculoskeletal symptoms, such as knee and ankle pain, resulting in antalgic gait and decreased weight-bearing, are a common feature of vitamin C deficiency. Symptoms can mimic inflammatory arthropathy, including elevated inflammatory markers. However, patients have normal joint exams and no evidence of inflammatory changes on plain film joint images. It is important that vitamin C deficiency be included in the differential diagnosis for children with MSK complaints in the Emergency Department.

Perifollicular hemorrhagic rash can be a dermatologic representation of vitamin C deficiency. Coagulation profiles are normal.

Children with ASD and/or food insecurity often have restricted diets, which can result in nutritional deficiencies. Although vitamin C deficiency is rare in pediatrics, certain comorbid conditions and exacerbating circumstances put children at higher risk.

Declarations

Conflict of interest None of the authors have any conflicts of interest or financial relationships to declare. No funding was received for this case report.

Informed consent Informed consent was received from the patient's father to submit this case for publication.

References

1. Ma NS, Thompson C, Weston S. Brief report: scurvy as a manifestation of food selectivity in children with Autism. *J Autism Develop Disorders*. 2016;46(4):1464–70.
2. Nagata JM, Seligman HK, Weiser SD. Perspective: The convergence of coronavirus disease 2019 (COVID-19) and food insecurity in the United States. *Advances in Nutrition*. 2021;12(2):287–90.
3. Weinstein M, Babyn P, Zlotkin S. An orange a day keeps the doctor away: Scurvy in the year 2000. *Pediatrics*. 2001;108(3):E55.
4. Fain O. Musculoskeletal manifestations of scurvy. *Joint Bone Spine*. 2015;72(2):124–8.
5. Levine M. New concepts in the biology and biochemistry of ascorbic acid. *N Engl J Med*. 1986;314(14):842–902.
6. Gulko E, Collins LK, Murphy RC, Thornhill BA, Taragin BH. MRI findings in pediatric patients with scurvy. *Skeletal Radiol*. 2015;44(2):291–7.