Review Article

The angiosome and woundosome concepts in guiding revascularization for chronic limb-threatening ischemia and diabetic foot ulcers—a narrative review

Theodoros Moysidis[1]^, Lorenzo Patrone[2], Dittmar Böckler[3], Kathrin Niemöller[1], Grigorios Korosoglou[4,5]

[1]Division of Internal Medicine V, Department of Angiology, Knappschaft Kliniken Westfalen, Dortmund, Germany; [2]Vascular and Endovascular Surgery Unit, San Giovanni di Dio Hospital, Florence, Italy; [3]Department of Vascular Surgery, University Hospital Heidelberg, Heidelberg, Germany; [4]Department of Cardiology and Vascular Medicine, GRN Hospital Weinheim, Weinheim, Germany; [5]Cardiovascular Imaging Center, Hector Foundation, Weinheim, Germany

Contributions: (I) Conception and design: T Moysidis, G Korosoglou; (II) Administrative support: G Korosoglou; (III) Provision of study materials or patients: L Patrone; (IV) Collection and assembly of data: T Moysidis; (V) Data analysis and interpretation: T Moysidis, L Patrone, G Korosoglou; (VI) Manuscript writing: All authors; (VII) Final approval of manuscript: All authors.

Correspondence to: Theodoros Moysidis, MD. Division of Internal Medicine V, Department of Angiology, Knappschaft Kliniken Westfalen, Am Knappschaftskrankenhaus 1, 44309 Dortmund, Germany. Email: theodoros.moysidis@knappschaft-kliniken.de; t.moysidis@outlook.de.

Background and Objective: The angiosome concept, introduced by Taylor *et al.* and further applied by Neville *et al.*, divides the body into three-dimensional blocks of tissue supplied by specific source arteries. This anatomical framework has been instrumental in guiding targeted revascularization strategies, thus enhancing blood flow to ischemic wounds. Building upon this, the woundosome concept was recently introduced, which focuses on individualized perfusion targeting, based on (I) anatomic variations; (II) the presence and extent of collateral circulation; and (III) wound characteristics. The woundosome concept may offer a potentially more tailored approach, paving the way for more thoughtful tissue revascularization. This review aims to investigate the role of angiosome- and woundosome-directed endovascular revascularization for the improvement of outcomes in patients with chronic limb-threatening ischemia (CLTI).

Methods: We conducted a systematic search in PubMed, Web of Science, and Cochrane Library from 1990 to February 2025 using combinations of the terms "angiosome", "woundosome", "critical limb ischemia", "diabetic foot ulcer", "direct revascularization", and "indirect revascularization". After screening 480 records, 14 studies were included in our analysis. Data were extracted regarding study design, patient population, revascularization strategy, and outcomes (wound healing, limb salvage). Findings were narratively synthesized with respect to study methodology and limitations.

Key Content and Findings: Most retrospective studies reported improved wound healing and limb salvage rates following angiosome-guided direct revascularization (DR), particularly when inline flow could be restored. However, comparable outcomes were observed with indirect revascularization (IR) in the presence of robust collateral circulation. Evidence for woundosome-guided revascularization remains limited but suggests that a perfusion-oriented, individualized strategy may be especially valuable in anatomically complex cases.

Conclusions: Incorporating angiosome- and woundosome-based strategies in CLTI management may improve limb- and patient-related outcomes. The decision on which particular territory needs primary attention and how many vessels require revascularization largely depends on the patency of feeding arteries in the wound area. In the future, a standardized way to measure the intra- and post-procedural arterial flow to the wound would be necessary, to study the clinical applications of the mentioned strategies. Future studies should therefore prospectively validate woundosome-guided strategies and integrate standardized

^ ORCID: 0009-0009-6024-9100.

© AME Publishing Company.

perfusion assessment tools to guide individualized treatment decisions.

Keywords: Peripheral arterial disease; chronic limb-threatening ischemia (CLTI); diabetic foot ulcer; revascularization

Submitted Jun 09, 2025. Accepted for publication Dec 09, 2025. Published online Dec 24, 2025.
doi: 10.21037/cdt-2025-305
View this article at: https://dx.doi.org/10.21037/cdt-2025-305

Introduction

Chronic limb-threatening ischemia (CLTI) remains a major cause of non-healing wounds and lower-extremity amputation despite advances in endovascular therapy. Clinicians face the challenge of determining whether direct revascularization (DR) of a specific angiosome improves outcomes compared with indirect approaches, particularly in patients with multilevel disease and variable collateral circulation. Furthermore, the recently proposed "woundosome" concept raises the question of whether a perfusion-oriented, individualized strategy could further optimize wound healing. This review aims to critically evaluate the available evidence on angiosome- and woundosome-guided revascularization, summarize reported outcomes, and identify key methodological gaps and future research needs.

Objectives

Sufficient tissue perfusion is of paramount importance for wound healing and limb salvage in CLTI patients and those with diabetic foot ulcers. The angiosome model, initially described by Taylor and Pan (1), has gained wide acceptance and has become a means in defining specific vascular territories perfused by individual arteries. This strategy anticipates that DR of the affected angiosome will lead to optimal perfusion and therefore maximized supply of oxygen and nutrients to the ischemic tissue. However, clinical observations have suggested that this strategy may be limited by the extent of collateral circulation and by individual variations in vascular anatomy. The concept of the 'woundosome' was therefore recently proposed, suggesting that revascularization needs to be based on the real perfusion requirements of the wound, which could extend beyond the classical angiosome concept (2). Herein, we systematically examined these two paradigms within a critical review of the literature, using an explicit methodology for searching and reporting. We present this article in accordance with the Narrative Review reporting checklist (available at https://cdt.amegroups.com/article/view/10.21037/cdt-2025-305/rc).

Methods

A systematic literature search was performed in three primary databases—PubMed, Web of Science, and the Cochrane Library—using the keywords "angiosome", "woundosome", "chronic limb ischemia", "diabetic foot ulcer", "direct revascularization", and "indirect revascularization". Boolean operators were used as follows: ("Angiosome" OR "Woundosome") AND ("critical limb ischemia" OR "diabetic foot ulcer").

The search period covered all available publications from the inception of each database from 1990 to February 2025. To ensure completeness, the reference lists of relevant review articles were manually screened to identify additional primary studies; however, the reviews themselves were excluded from the qualitative and quantitative synthesis. The items used in our search strategy are displayed in *Table 1*.

The search initially yielded 480 results using the term "angiosome". After applying additional filters ("critical limb ischemia", "direct revascularization"), 71 results remained. In a next step, we screened review articles to identify additional primary studies through their reference lists; however, the reviews themselves were excluded from the qualitative and quantitative synthesis. Following screening by title and abstract, and after deduplication, one duplicate and one irrelevant article were excluded, leaving 14 studies that formed the basis for the primary analysis. The items for the searching process are shown in *Table 1* and the resultant analysis can be appreciated in *Figure 1*.

© AME Publishing Company.

Table 1 Search strategy

Items	Specification
Date of search	13th February 2025
Databases and other sources searched	PubMed, Web of Science, Cochrane Library
Search terms used	"Angiosome", "woundosome", "critical limb ischemia", "diabetic foot ulcer", "direct revascularization", "indirect revascularization"
Timeframe	1990–February 2025
Inclusion and exclusion criteria	Inclusion criteria: primary studies. Exclusion criteria: review articles, duplicates, irrelevant articles
Selection process	Selection conducted independently from each author

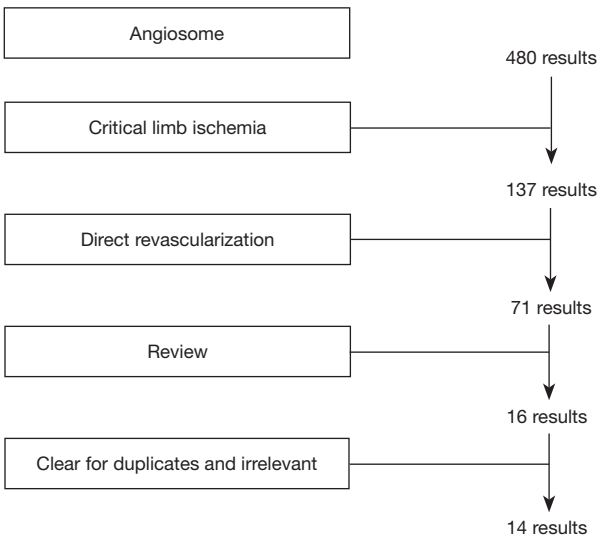

Figure 1 Results based on our literature research.

Critical review of the literature supporting the angiosome concept

Different studies investigated the applicability of the angiosome concept in the context of wound healing and limb salvage in CLTI. Most of them, however, were retrospective, and defined different endpoints. While DR of an angiosome seems to be more accessible by endovascular procedures, indirect revascularization (IR) through collaterals seems to be accessible through both, endovascular and open surgical procedures. Nevertheless, findings of most retrospective studies vary, without clear supporting one revascularization strategy (e.g., DR *vs.* IR) over the other. *Table 2* provides an overview of the retrospective literature on the role of angiosome-guided revascularization in terms of wound healing and limb salvage, regarding endovascular and open surgical studies (3-15). The differences in the observed findings are likely to be attributed to the blood inflow to the wound, either direct, through the main vessel of the angiosome, or indirect, through collaterals of different sizes.

The angiosome concept

The term "angiosome", as mentioned before, is based on a model of three-dimensional blocks of tissue perfused by specific arterial sources and corresponding venous drainage (1). This anatomical framework has since been applied in various medical disciplines, particularly in vascular medicine, plastic surgery, and wound management. The underlying rationale of the angiosome concept is that DR of the leading vessel in the area increases direct blood flow and therefore, enhances wound healing by optimizing oxygen and nutrient delivery (16). The concept is relevant in the management of patients with peripheral arterial disease (PAD), particularly those in the stage of CLTI, or also in patients with diabetic foot and an underlying vascular disease, where compromised blood supply contributes to non-healing wounds and increases the risk of major amputations (17). Biancari and Juvonen (18) concluded that DR of the main vessel supplying the affected angiosome may be more effective than IR, thus more effectively reducing amputation rates and promoting wound healing in patients with CLTI and diabetic foot ulcers. Similarly, Jongsma *et al.* indicated that DR according to the angiosome concept significantly improved wound healing and reduced major amputation rates in patients with CLTI (19). However, the benefits were more pronounced in endovascular treatments compared to surgical bypass procedures.

© AME Publishing Company.

Table 2 Retrospective studies favoring the angiosome concept

First author	Publication year	Study period	Type of study	Number of patients	Type of therapy	Mean age (years)	DM	ESRD	Follow-up duration (months)
Alexandrescu (3)	2008	2005–2008	Retrospective; single arm	98	Endovascular	72.8	100%	22%	17.8
Alexandrescu (4)	2011	2001–2010	Retrospective; two arms	208	Endovascular	74.3	100%	18%	38.6
Iida (5)	2012	2004–2010	Retrospective; two arms	329	Endovascular	70	73%	63%	18.0
Söderström (6)	2013	2007–2011	Retrospective; two arms	226	Endovascular	71.2	100%	16%	12.0
Shiraki (7)	2015	2004–2012	Retrospective; two arms	734	Endovascular	71.0	75%	64%	21.0
Jeon (8)	2016	2011–2013	Retrospective; two arms	70	Endovascular	69.6	100%	34%	13.0
Špillerová (9)	2017	2008–2013	Retrospective; two arms	545	Endovascular & surgical	~72	100%	~20%	24
Neville (10)	2009	NM	Retrospective; two arms	43	Open surgical	NM	88%	52%	NM
Kabra (11)	2013	2007–2008	Retrospective; two arms	64	Open surgical	NM	81%	NM	6.0
Lejay (12)	2014	2003–2009	Retrospective; two arms	54	Open surgical	69.5	100%	55%	48.0
Suh (13)	2016	NM	Retrospective; single center	NM	Open surgical	NM	NM	NM	NM
Popitiu (14)	2024	2018–2019	Retrospective; single center	51	Endovascular	69	NM	NM	12
Meta-analysis									
Tarricone (15)	2024	Until 2023	Retrospective	985	Endovascular & open surgical	NM	73.6%	NM	79.0

DM, diabetes mellitus; ESRD, end stage renal disease; NM, not mentioned.

This is conceivable since with open repair, the surgeon usually places the distal anastomosis of the vein bypass at the site of the most well preserved and less diseased crural conduit independent of the angiosome concept. In addition, the presence of collateral circulation also influenced outcomes, with IR yielding comparable results to DR when adequate collaterals were present (20). This could be the reason why the angiosome concept may not be universally applicable in patients with lower extremity arterial disease: Spillerova *et al.* (9) performed a propensity-matched analysis, which could not support the superiority of angiosome-guided revascularization in CLTI patients with multilevel peripheral artery disease (PAD). The study found no significant differences in terms of amputation-free survival, freedom from major adverse limb events (MALE), or healing rates between direct and IR groups. Similarly, Alexandrescu *et al.* (3) demonstrated that wound-targeted revascularization was linked to significantly higher rates of wound healing and, also shorten the healing time in patients with diabetes mellitus, when compared to IR. In contrast to the benefits of wound-targeted revascularization over indirect or even collateral oriented revascularization in wound healing, there were no differences between these strategies regarding MALE or amputation free survival.

© AME Publishing Company.

Dworak *et al.* showed that fluorescent angiography was a useful tool to guide angiosome-directed endovascular therapy (21). Tange *et al.* utilized near-infrared fluorescence imaging with indocyanine green to assess the applicability of the angiosome concept (22): the study demonstrated that both DR and IR led to significant improvements in perfusion parameters. Furthermore, Ricco *et al.* evaluated the impact of angiosome-targeted peroneal bypass on limb salvage and healing in CLTI patients (23). The findings suggested that patency of both peroneal branches and the pedal arch were associated with better outcomes, irrespective of wound angiosome location. In the same direction, Troisi and Turini showed that the patency of the pedal arch was the strongest predictor of wound healing in patients with diabetic foot ulcers, with limb salvage rates over a 5-year follow-up period of above 94% in cases of a patent pedal arch compared to 67%, in cases where the pedal arch could not be reconstructed (24). In contrast, Rashid *et al.* reported no differences in limb salvage rates after distal bypass for CLTI based on the quality of the pedal arch, but instead found a direct influence on healing rates and time to healing (20).

Despite the smaller size and the retrospective and single-center nature of most studies, the existing findings support the notion that DR leads to improved wound healing and reduced amputation rates compared to IR in the lack of collateral circulation. This suggests that restoring direct blood flow to the ischemic territory enhances tissue perfusion, facilitates granulation tissue formation, and accelerates wound closure, ultimately improving clinical outcomes. However, regardless of the advantages of angiosome-directed revascularization, there still are some limitations. Not all anatomical territories have discrete vascularization, and the presence of collateral circulation can sometimes compensate for IR. In certain cases, an IR strategy—where blood flow is restored to an adjacent angiosome with robust collateral networks—can achieve similar or satisfactory outcomes, a finding supported by the review of Bunte and Shishehbor (25). This is particularly relevant in patients with heavily diseased or occluded target vessels, where DR may not be feasible. Moreover, variations in vascular anatomy and the degree of microvascular dysfunction further complicate the predictability of outcomes solely based on the angiosome concept. Iida *et al.*, in their review, concluded that DR is superior to IR in the presence of diabetes mellitus and wound infection (26).

The woundosome concept

This novel concept, recently introduced by Patrone *et al.*, challenges the strict anatomical boundaries of the angiosome model by emphasizing on the importance of wound-feeding arteries over territorial arterial supply (2). This novel approach builds on clinical observations showing that the wound bed, the area needing perfusion the most, often extends beyond predefined angiosomal territories, especially in patients with advanced vascular disease. Patrone *et al.* proposed that a revascularization strategy targeting the actual wound area rather than predefined angiosomal territories may lead to better healing outcomes, particularly when collateral circulation is not sufficient. Thus, rather than strictly adhering to anatomical maps, clinicians may need to focus more on the arteries directly feeding the wound tissue, as these may be more critical for tissue survival and repair than the primary angiosomal arteries. This approach is particularly valuable in cases of anatomical variation of below-the-knee (BTK) arteries, single peroneal run off feeding one or both the anterior and posterior foot circulation, multi-segmental arterial disease, or recurrent wounds, where standard angiosome-directed strategies may not be available. The woundosome concept underscores the need for a functional, perfusion-based approach that adapts to the complexity of the individual vascular conditions of the patients.

The role of a wound-perfusion based revascularization in critical limb ischemia was described earlier by Bunte and Shishehbor in 2013 (25) and in a meta-analysis by Kim *et al.* 2021 referred to as "indirect revascularization via collateral flow (IRc)" (27). Different reviews underline the key-role of wound perfusion in limb-salvage, regardless the revascularization type, as shown in *Tables 2-4*. Recent developments, such as micro-oxygen sensors, speckle-contrast imaging and pedal-acceleration time, are tools that could objectively measure tissue perfusion during the endovascular treatment, and therefore be useful to guide such revascularization procedures (9-19,27), thus enhancing the accuracy of conventional angiography guided procedures.

Comparative analysis and reasoning

A side-by-side evaluation of the two concepts reveals important differences as shown in *Table 5*.

© AME Publishing Company.

Table 3 Retrospective studies not supporting the role of angiosome concept

First author	Publication year	Study period	Type of study	Number of patients	Type of therapy	Mean age (years)	DM	ESRD	Follow-up duration (months)
Kawarada (28)	2012	2002–2009	Retrospective; two arms	85	Endovascular	69.0	78%	51%	27.0
Fossaceca (29)	2013	2005–2011	Retrospective; two arms	201	Endovascular	75.5	100%	7.4%	17.5
Acín (30)	2014	1999–2009	Retrospective; three arms	92	Endovascular	72.0	100%	0%	24.0
Pavé (31)	2016	2007–2011	Retrospective; two arms	139	Endovascular	74.2	60%	31%‡	14.7
Soares (32)	2016	2009–2013	Retrospective; two arms	95	Endovascular	72.9	76.1	22.8‡	12.0
Ambler (33)	2017	2009–2016	Retrospective; three arms	221	Endovascular	75.0	32%	15%†‡	24.0
Troisi (24)	2017	2014–2015	Retrospective; two arms	93	Endovascular	74.6	100%	33%§	7.6
Weaver (34)	2018	2012–2017	Retrospective; two arms	99	Endovascular & surgical	63.3	100%	19%‡	21.0
Azuma (35)	2012	2003–2009	Retrospective; two arms	228	Open surgical	67.0	81%	49%	24.0
Rashid (20)	2013	2004–2011	Retrospective; two arms	154	Open surgical	75.0	76%	28%‡	12.0
Kret (36)	2014	2005–2011	Retrospective; two arms	97	Open surgical	67.8	63%	12%	NM
Ricco (23)	2017	2004–2015	Retrospective; two arms	120	Open surgical	78.0	57%	NM†	79.0
Rohrich (37)	2025	2022–2023	Retrospective; two arms	33	Endovascular, prior local flap reconstruction	78.2	93.9%	33.3%	3.0

†, glomerular filtration rate of <60 mL/min/1.73 m^2 in 21% of the patients; ‡, defined as chronic renal disease; §, serum creatinine ≥1.5mg/dL. DM, diabetes mellitus; ESRD, end stage renal disease; NM, not mentioned.

Exemplary cases

Case 1: wound healing after revascularization based on the angiosome concept

A 66-year-old male patient with history of type 2 diabetes mellitus, hypertension and dyslipidemia, suffering from a gangrene of his first and second toe (*Figure 2*). Examination confirmed sensoric and autonomous neuropathy. Duplex ultrasound revealed BTK PAD. Angiography was performed, which demonstrated a proximal occlusion of the posterior tibial artery, a distal occlusion of the anterior tibial artery and diseased anterior and posterior branches of the peroneal artery supplying the anterior and posterior circulation (*Figure 3A*). Antero-posterior view of the foot demonstrated very poor flow to the "woundosome" supplied by the dorsalis pedis (*Figure 3B*). Endovascular recanalization and angioplasty by 3.0 mm angioplasty balloon of the occluded distal anterior tibial artery with in-line flow to the fore foot was achieved (*Figure 3C*). The anteroposterior view of the foot demonstrates improved flow to the wound following the angiosome concept (*Figure 3D*). Complete wound healing achieved at 2 months after amputation of the second toe (*Figure 4*). This case shows very clear the role of in-line flow in the wound,

© AME Publishing Company.

Table 4 Studies highlight the woundosome concept

First author	Publication	Study period	Type of study	No. of patients	Type of therapy	Mean age (years)	DM	ESRD	Follow-up duration (months)
Studies highlighting the role of the woundosome concept (collateral circulation)									
Varela (38)	2010	2005–2008	Retrospective; three arms	76	Endovascular & surgical	NM	78%	4%	14.2
Kawarada (28)	2012	2002–2009	Retrospective; two arms	85	Endovascular	69.0	78%	51%	27.0
Acín (30)	2014	1999–2009	Retrospective; three arms	92	Endovascular	72.0	100%	0%	24.0
Zheng (39)	2016	2005–2014	Retrospective; three arms	486	Endovascular	69.1	50%	4.9%	12.0
Iida (26)	2013	2004–2010	Retrospective; two arms	718	Endovascular	70.0	75%	68%	12.0
Troisi (24)	2017	2014–2015	Retrospective; two arms	93	Endovascular	74.6	100%	33%	7.6
Serizawa (40)	2024	2019–2021	Prospective; observational	27	Surgical	70.2	70%	78%	1
Meta-analysis									
Jongsma (19)	2017	1999–2014	Retrospective	3932	Endovascular & surgical	67–75.5	63–100%	0–67%	13–39
Kim (27)	2021	2010–2020	Retrospective	NM	Endovascular	NM	NM	NM	1–12.0

DM, diabetes mellitus; ESRD, end stage renal disease; NM, not mentioned.

Table 5 Comparison of the angiosome and woundosome concepts

Feature	Angiosome concept	Woundosome concept
Theoretical basis	Anatomical mapping of vascular territories	Angiographic assessment rather than pure anatomical mapping focusing on the actual perfusion needs of the wound area
Clinical reasoning	Direct revascularization of a specific angiosome helps to optimize wound healing	Real-time perfusion dynamics show individual variability in perfusion at the wound bed level and a wound-tailored approach can help optimizing wound-healing
Evidence	Improved outcomes with angiosome-targeted revascularization (9,16)	Evidence suggesting potential benefits in complex cases with extensive occlusion (6,27,40)
Limitations	May not fully account for compensatory collateral circulation	Requires advanced imaging techniques and standardization for clinical application

underlining the significance of the "angiosome" concept.

Case 2: indirect flow restitution via the foot arch based on the woundosome concept

A 73-year-old patient presented with a non-healing ulcer since 1 year (bone exposed) at the level of the first metatarsal head (*Figure 5*). The patient had so far not undergone invasive treatment because previous Duplex scans reporting adequate arterial flow till the ankle level. The laboratory examinations showed strongly elevated C-reactive protein (CRP) values. Duplex ultrasound revealed poor perfusion of the plantar arch. An invasive approach was scheduled. The angiogram demonstrated a short occlusion of the common plantar artery, supplying a relatively healthy foot arch, and an occlusion of the distal dorsalis pedis artery (*Figure 6A*).

© AME Publishing Company.



Figure 2 Case 1. Gangrene of the first and second toe; diabetic foot; status at presentation. Note the mazeration of the first toe due to exudation from the gangrenous second toe, the peeling of the dry skin, which combined with the redness and the moderate swelling indicate the underlying diabetic autonomous neuropathy.



Figure 4 Case 1. Clinical presentation 2 months after successful revascularization and amputation of the gangrenous second toe, showing a completely healed amputation areal.

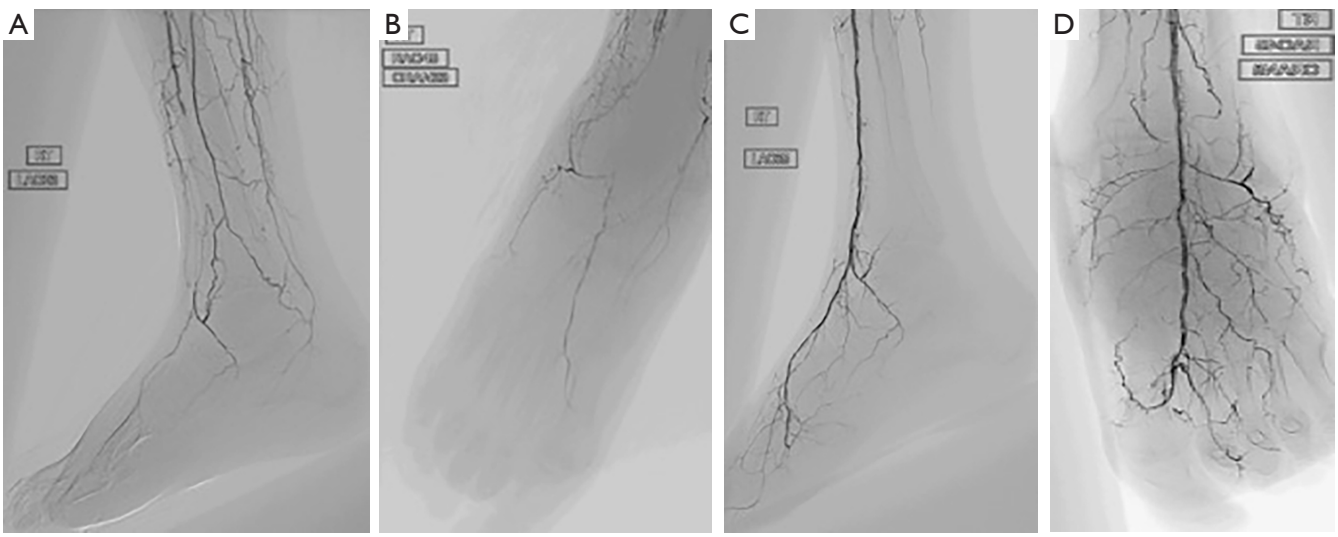

Figure 3 Case 1. Angiograms. (A) Severe diseased vessels of the distal calf. Note the long occlusion of the posterior tibial artery with poor collaterals, the distal occlusion of the anterior tibial artery and the diseased feeding branches of the peroneal artery. (B) Anterio-posterior view of the foot, demonstrates very poor flow to the wound areal supplied by the dorsalis pedis artery. (C) Restored in-line flow after recanalization and balloon-angioplasty of the distal anterior tibial artery. (D) Anterior-posterior view of the foot demonstrating an improved in-line flow to the wound areal following the angiosome concept compared to (B).

© AME Publishing Company.



Figure 5 Case 2. Non-healing ulcer at the level of the head of the first metatarsal bone; status at presentation.

After performing a balloon angioplasty with a 3mm-balloon of the common plantar artery the angiogram demonstrated patency of in-line flow to the foot via the posterior circulation (*Figure 6B*). Antero-posterior view of the foot demonstrating direct arterial flow to the "woundosome" via the foot arch, directly supplied by the restored posterior circulation (*Figure 6C*). Complete wound healing achieved at 2-month follow-up is shown in *Figure* 7.

Case 3: IR with blood flow through a peroneal artery

A 68-year-old non-diabetic patient presented with acute infection of his first toe (*Figure 8*). Laboratory findings confirmed elevated CRP values and leukocytes). Systemic antibiotic treatment was initiated, and a wound-debridement was undertaken. Duplex sonography revealed a BTK occlusive disease. The angiogram showed the peroneal artery as a single vessel run-off to the foot supplying the dorsalis pedis and the foot arch via the anterior-lateral malleolar artery (*Figure 9A*). The revascularization of the peroneal artery was performed via angioplasty of the occluded tract using a 3.0 mm angioplasty balloon (*Figure 9B*). Brisk flow to the forefoot via good-size anterior-lateral malleolar artery was demonstrated, so that

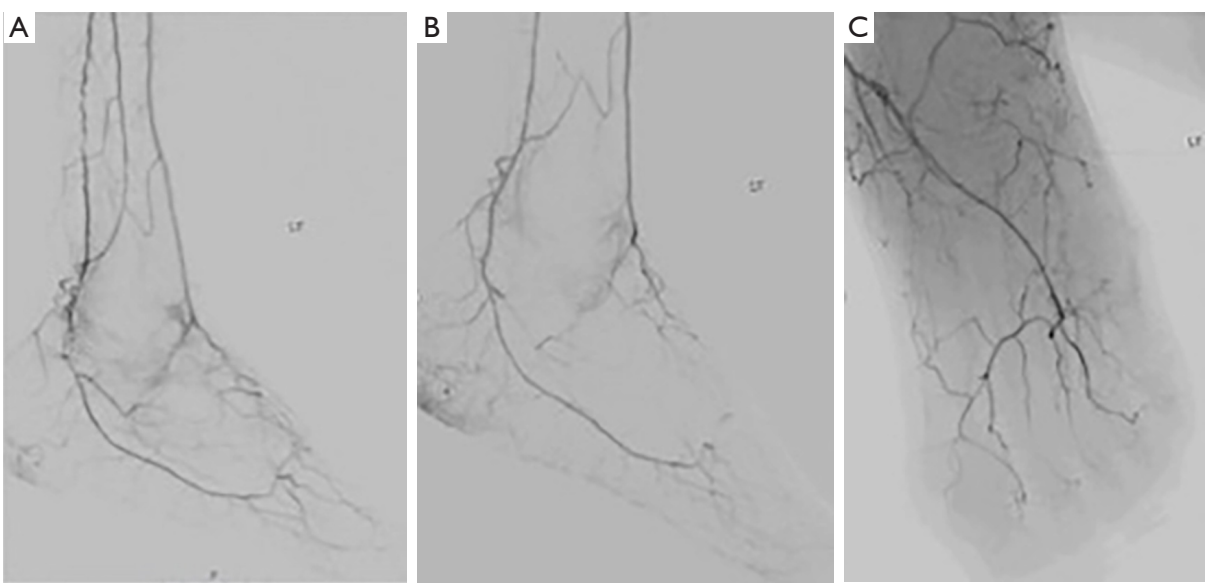

Figure 6 Case 2. Angiograms. (A) Demonstrates short occlusion of the common plantar artery. Note the relatively healthy foot arch, and the occlusion of the distal dorsalis pedis artery. (B) After angioplasty of the common plantar artery by 3 mm balloon. Note the patency of in-line flow to the foot via the posterior circulation. (C) Antero-posterior view of the foot demonstrating direct arterial flow to the "woundosome" via the foot arch, directly supplied by the restored posterior circulation.

© AME Publishing Company.



Figure 7 Case 2. Healing process 2 months after revascularization based on the woundosome concept.



Figure 8 Case 3. Non-diabetic gangrene of the first toe with infection. Note the previous amputated second toe.

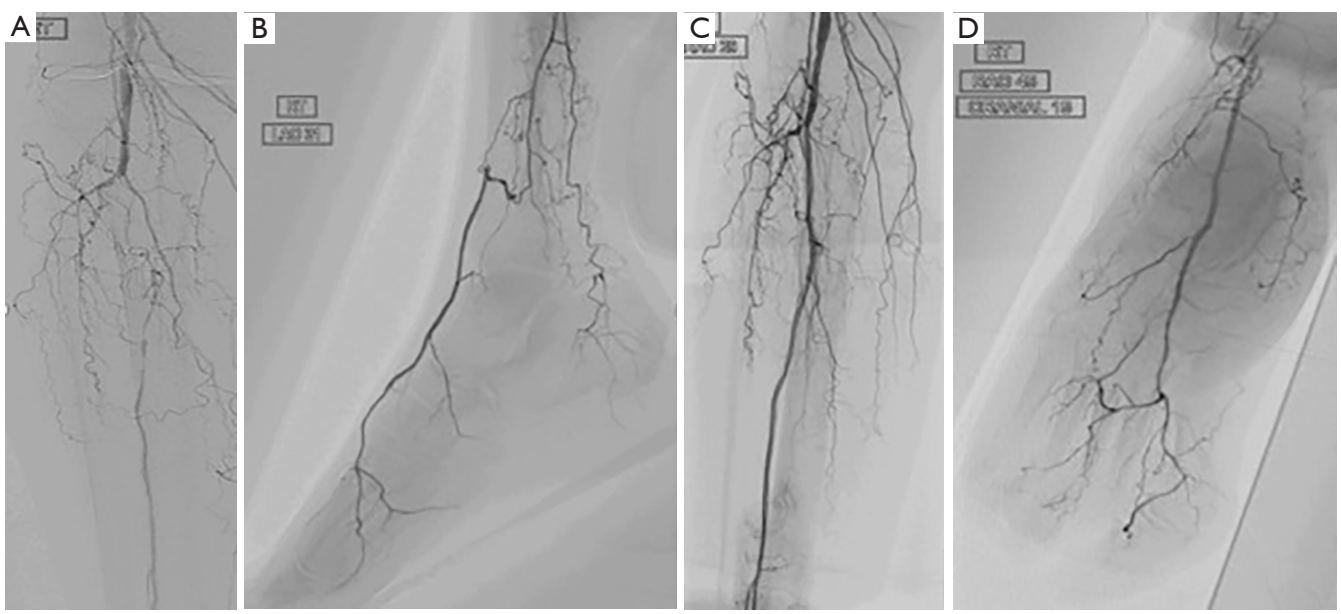

Figure 9 Case 3. Angiograms. (A) Peroneal artery as single vessel run-off to the foot. (B) Brisk flow to the forefoot via good-size anterior-lateral malleolar artery. (C) Revascularization of the peroneal artery via angioplasty of the occluded tract by 3 mm balloon. (D) Antero-posterior view of the foot, confirming satisfactory flow to the woundosome, supplied via the foot arch, fed by good-size collateral from the peroneal artery.

© AME Publishing Company.



Figure 10 Case 3. Status 45 days after amputation of the first toe and successful revascularization.

the additional recanalization of the anterior tibial artery was deferred (*Figure 9C*). The anterior-posterior view of the foot confirmed a satisfactory flow to the woundosome, supplied via the foot arch, fed by good-size collateral from the peroneal artery (*Figure 9D*). The first toe was hereafter amputated, due to presence of osteomyelitis, confirmed through a CT scan (not shown). After 45 days, complete wound healing was achieved (*Figure 10*).

Discussion

The angiosome and woundosome concepts each offer distinct but mainly complementary perspectives for optimizing revascularization strategies, in CLTI patients. The angiosome model provides a well-established but rigid anatomical framework that helps guide targeted interventions, whereas the woundosome concept offers a more flexible, functionally driven approach that accounts for individual variations in vessel anatomy and tissue perfusion.

While numerous studies support angiosome directed interventions, as shown in *Table 2*, the success of IR highlights the importance of collateral circulation, which is more rigorously implemented in the woundosome concept (*Tables 3,4*). In practice, this means that a strict angiosomal approach may not always be feasible or convenient in the absence of receiving vessels in the anatomical predefined region. Instead, individual factors, such as vessel patency in neighboring anatomical areas, collateral flow sustained by decent size collaterals, either existing or dormant, and the extent of ischemic damage, should guide the selection of the most appropriate vessel to recanalize. In addition, the woundosome concept shifts the focus from purely anatomical mapping to an assessment of wound perfusion (22). This paradigm shift underscores the necessity of advanced imaging modalities, such as super selective injection of the contrast media as distal as possible in the periphery, using magnification and orthogonal projections, where the wound areal is as clearly demonstrated, determining the actual feeding arteries of the wound bed.

Nevertheless, several methodological concerns limit the strength of current evidence. Most studies are retrospective, single-center analyses with heterogeneous definitions of wound healing and variable follow-up durations. Few studies systematically used objective perfusion measurements such as transcutaneous oxygen pressure ($TCPO_2$) or pedal acceleration time (PAT), which may lead to misclassification of clinical success. Additionally, some studies combine both surgical and endovascular interventions, complicating the interpretation of results by introducing treatment heterogeneity.

Another limitation is the lack of standardized wound classification and severity reporting, making comparisons across studies cumbersome. Many studies also fail to report the presence or quality of collateral circulation in a consistent way, despite its clear influence on outcomes in IR strategies. These methodological weaknesses contribute to conflicting findings regarding the superiority of direct versus IR.

In patients with diabetes, the diagnosis of PAD is often complicated by medial arterial calcification, which leads to falsely elevated Ankle-Brachial Index (ABI) values and can mask the presence of significant ischemia. Duplex ultrasound, although widely available, may have reduced diagnostic accuracy in the presence of extensive calcification or multilevel disease, particularly below the knee. Therefore, an integrated diagnostic approach combining ABI, toe-brachial index (TBI), duplex findings, and, when needed, computed tomography angiography/magnetic

© AME Publishing Company.

resonance angiography (CTA/MRA) or digital subtraction angiography is recommended to define the true extent of ischemia and plan targeted revascularization.

The assessment of tissue oxygenation by $TCPO_2$ has emerged as a valuable tool to evaluate the perfusion status of the wound bed and to predict the likelihood of wound healing after revascularization. $TCPO_2$ is independent of the degree of arterial calcification and reflects microcirculatory function, thus complementing angiographic findings. Recent evidence suggests that $TCPO_2$ thresholds can help guide the decision to proceed with revascularization and objectively monitor its effectiveness. Importantly, diabetes is associated with significant microcirculatory dysfunction—characterized by impaired capillary recruitment and endothelial dysfunction—that may limit the benefit of technically successful revascularization and contribute to delayed or incomplete healing (41).

Both the angiosome and woundosome concepts rely on the assumption that restored inline flow translates into sufficient tissue oxygenation. In diabetic patients, however, this is not always the case, since microangiopathy and neuropathy may prevent adequate perfusion despite patency of the target vessel. The integration of perfusion metrics into procedural planning allows verification that the chosen revascularization strategy restores adequate functional perfusion of the wound bed. This combined macro- and microcirculatory assessment may improve patient selection, optimize procedural outcomes, and, therefore, ultimately enhance wound healing and limb salvage rates. This assessment can also be performed during an angioplasty, providing the interventionalist with useful feedback, since they can monitor the perfusion of the wound area.

Pedal-acceleration time is another practical and easily applicable tool for assessing perfusion during an interventional procedure and can be used as a concomitant measurement. Studies support the beneficial effects of such measurements during revascularization procedures (24). Recent studies focus on duplex-ultrasound based measurements, since this application is well-spread, requires no other investment other than a modern ultrasound system and a well-trained sonographer. On behalf of this topic, Sommerset *et al.* (42) helped establish the PAT as a helpful tool in assessing tissue perfusion during the revascularization procedure. In a more recent review by Souza *et al.* (43), the evidence for this method became more apparent, since its reliability and reproducibility could be further established. Further, Pinelo *et al.* showed a comparable value of pedal-acceleration time to $TCPO_2$ (44).

Although techniques such as $TCPO_2$ and PAT have emerged as promising adjuncts for physiological assessment, no universally accepted thresholds exist to guide angiosome- or woundosome-directed decision making. For example, $TCPO_2$ values above 30–40 mmHg are cited as predictive of healing, and a PAT <225 ms has been associated with improved outcomes, but these values lack standardization and broad validation. Future consensus-driven efforts are therefore necessary to establish reproducible, clinically actionable cut-off points for perfusion assessment, since no consensus yet exists on perfusion thresholds predictive of wound healing or limb salvage.

From a clinical point of view, integrating both concepts may yield the most effective outcomes. While the angiosome concept offers a structured guideline for vascular interventions, incorporating the woundosome approach can provide additional flexibility, particularly in complex cases where anatomical boundaries do not align with perfusion requirements. This integrated approach could be valuable in patients with multiple occluded vessels BTK or even below-the-ankle disease, where rigid adherence to one concept may limit therapeutic options and flexibility in optimal revascularization management. Since the wider use of adjuvant tools, such as transcutaneous oximetry and sonographic measurements, guiding of revascularization to the proper vascular territory, either in terms of direct in-line flow or indirect collateral flow optimization, is becoming crucial, regardless the initial attempt. Therefore, in terms of wound healing, it is important to restore blood flow to the wound bed, regardless the direction of the inflow. This later consideration was supported by a recent retrospective multicenter study covering a period of 3 years, led by Iida and Soga (5).

The clinical applicability of angiosome- and woundosome-directed strategies may not be uniform across all subgroups of CLTI. Patients with advanced diabetes, renal dysfunction, or multi-level disease often present with complex microvascular and collateral adaptations that may limit the predictive value of strict angiosome-based targeting. Current evidence is largely derived from heterogeneous populations, and subgroup-specific outcome data remain insufficient. Dedicated studies are required to define which patient subsets derive the greatest benefit from woundosome-guided interventions.

Most published reports on angiosome- and woundosome-based revascularization focus on mid-term results (up to 2–3 years), with limited data extending beyond 3 years. Long-term studies regarding limb salvage, wound

© AME Publishing Company.

healing durability, reintervention rates, and survival rates are required.

Limitations

Our analysis has some limitations. The angiosome concept has been studied multiple times since its first description. After some early euphoria it became apparent that the concept is not widely applicable (*Table 3*). Since different circumstances, like infection, edema and pressure can influence wound healing apart from tissue level perfusion, study results can vary, depending on the presence and degree of such underlying conditions in different patient cohorts. Therefore, a comparison of the available studies is difficult, since most of them are retrospective, non-randomized and sometimes contain both surgical and endovascularly revascularized patients. Furthermore, most of the retrospective studies referred to wound healing, without describing the wound extension and severity. This is associated with a generally missing model for standardized reporting of wound care. On the other hand, the woundosome concept, appears very fascinating but still needs to be supported by a reliable and easy-to-use foot arterial perfusion system, able to set up perfusion thresholds, which would ultimately be able to predict wound healing and limb salvage.

Conclusions

While the angiosome concept is based on restoring blood flow direct to the main vessel of the associated anatomical area, the woundosome concept offers a more adaptable, patient-specific approach by prioritizing wound perfusion through collaterals above and beyond anatomical territories, and considering the presence of anatomic variations. With the woundosome concept IR in the presence of good size collaterals/foot arch patency could be equivalent to DR. Future research should focus on comparing the clinical outcomes of strict angiosome-based revascularization versus woundosome-guided interventions in large-scale, multicenter studies. Current evidence supports the rationale of enhancing blood flow in the wound territory, regardless of the leading inflow artery. Additionally, developing standardized protocols for perfusion assessment correlated to wound classification (21) will be essential to optimize individualized treatment strategies and improve long-term limb salvage rates. Therefore, a possible approach for interventional treatment in CLTI can be described as follows: prior to the revascularization of the occluded main artery supplying in-line blood flow to a wound, the perfusion to that wound, provided by potential collaterals, needs to be assessed in the context of the clinical presentation of the patients.

Acknowledgments

None.

Footnote

Reporting Checklist: The authors have completed the Narrative Review reporting checklist. Available at https://cdt.amegroups.com/article/view/10.21037/cdt-2025-305/rc

Peer Review File: Available at https://cdt.amegroups.com/article/view/10.21037/cdt-2025-305/prf

Funding: None.

Conflicts of Interest: All authors have completed the ICMJE uniform disclosure form (available at https://cdt.amegroups.com/article/view/10.21037/cdt-2025-305/coif). G.K. serves as an unpaid editorial board member of *Cardiovascular Diagnosis and Therapy* from January 2025 to December 2026. L.P. received honoraria for lectures, presentations, speakers bureaus from Abbott, Angiodroid, Asahi, BD, Bentley, COOK, Shockwave and Terumo. K.N. received honoraria for presentations and workshops from Shockwave Medical and Philips Healthcare. The other authors have no conflicts of interest to declare.

Ethical Statement: The authors are accountable for all aspects of the work in ensuring that questions related to the accuracy or integrity of any part of the work are appropriately investigated and resolved. Patients' consent was obtained for the publication of the images.

Open Access Statement: This is an Open Access article distributed in accordance with the Creative Commons Attribution-NonCommercial-NoDerivs 4.0 International License (CC BY-NC-ND 4.0), which permits the non-commercial replication and distribution of the article with the strict proviso that no changes or edits are made and the original work is properly cited (including links to both the formal publication through the relevant DOI and the license). See: https://creativecommons.org/licenses/by-nc-nd/4.0/.

References

1. Taylor GI, Pan WR. Angiosomes of the leg: anatomic study and clinical implications. Plast Reconstr Surg 1998;102:599-616; discussion 617-8.
2. Patrone L, Pasqui E, Conte MS, et al. The "Woundosome" Concept and Its Impact on Procedural Outcomes in Patients With Chronic Limb-Threatening Ischemia. J Endovasc Ther 2025;32:1765-76.
3. Alexandrescu VA, Hubermont G, Philips Y, et al. Selective primary angioplasty following an angiosome model of reperfusion in the treatment of Wagner 1-4 diabetic foot lesions: practice in a multidisciplinary diabetic limb service. J Endovasc Ther 2008;15:580-93.
4. Alexandrescu V, Hubermont G. Primary infragenicular angioplasty for diabetic neuroischemic foot ulcers following the angiosome distribution: a new paradigm for the vascular interventionist? Diabetes Metab Syndr Obes 2011;4:327-36.
5. Iida O, Soga Y, Hirano K, et al. Long-term results of direct and indirect endovascular revascularization based on the angiosome concept in patients with critical limb ischemia presenting with isolated below-the-knee lesions. J Vasc Surg 2012;55:363-370.e5.
6. Söderström M, Albäck A, Biancari F, et al. Angiosome-targeted infrapopliteal endovascular revascularization for treatment of diabetic foot ulcers. J Vasc Surg 2013;57:427-35.
7. Shiraki T, Iida O, Takahara M, et al. Predictors of delayed wound healing after endovascular therapy of isolated infrapopliteal lesions underlying critical limb ischemia in patients with high prevalence of diabetes mellitus and hemodialysis. Eur J Vasc Endovasc Surg 2015;49:565-73.
8. Jeon EY, Cho YK, Yoon DY, et al. Clinical outcome of angiosome-oriented infrapopliteal percutaneous transluminal angioplasty for isolated infrapopliteal lesions in patients with critical limb ischemia. Diagn Interv Radiol 2016;22:52-8.
9. Špillerová K, Settembre N, Biancari F, et al. Angiosome Targeted PTA is More Important in Endovascular Revascularisation than in Surgical Revascularisation: Analysis of 545 Patients with Ischaemic Tissue Lesions. Eur J Vasc Endovasc Surg 2017;53:567-75.
10. Neville RF, Attinger CE, Bulan EJ, et al. Revascularization of a specific angiosome for limb salvage: does the target artery matter? Ann Vasc Surg 2009;23:367-73.
11. Kabra A, Suresh KR, Vivekanand V, et al. Outcomes of angiosome and non-angiosome targeted revascularization in critical lower limb ischemia. J Vasc Surg 2013;57:44-9.
12. Lejay A, Georg Y, Tartaglia E, et al. Long-term outcomes of direct and indirect below-the-knee open revascularization based on the angiosome concept in diabetic patients with critical limb ischemia. Ann Vasc Surg 2014;28:983-9.
13. Suh HS, Oh TS, Lee HS, et al. A New Approach for Reconstruction of Diabetic Foot Wounds Using the Angiosome and Supermicrosurgery Concept. Plast Reconstr Surg 2016;138:702e-9e.
14. Popitiu MI, Alexandrescu VA, Clerici G, et al. Angiosome-Targeted Infrapopliteal Angioplasty: Impact on Clinical Outcomes-An Observational Study. J Clin Med 2024;13:883.
15. Tarricone A, Gee A, de la Mata K, et al. Outcomes for Patients With Chronic Limb-Threatening Ischemia After Direct and Indirect Endovascular and Surgical Revascularization: A Meta-Analysis and Systematic Review. J Endovasc Ther 2024. [Epub ahead of print]. doi: 10.1177/15266028241248524.
16. Unno N, Inuzuka K, Yamamoto N, et al. The Patency of Tibial/Peroneal Arteries Affects the Increment of Regional Tissue Saturation of Oxygen in Each Angiosome after Superficial Femoral Artery Revascularization. Ann Vasc Dis 2022;15:14-21.
17. Bunte MC, Shishehbor MH. Angiosome-Guided Intervention in Critical Limb Ischemia. Interv Cardiol Clin 2017;6:271-7.
18. Biancari F, Juvonen T. Angiosome-targeted lower limb revascularization for ischemic foot wounds: systematic review and meta-analysis. Eur J Vasc Endovasc Surg 2014;47:517-22.
19. Jongsma H, Bekken JA, Akkersdijk GP, et al. Angiosome-directed revascularization in patients with critical limb ischemia. J Vasc Surg 2017;65:1208-1219.e1.
20. Rashid H, Slim H, Zayed H, et al. The impact of arterial pedal arch quality and angiosome revascularization on foot tissue loss healing and infrapopliteal bypass outcome. J Vasc Surg 2013;57:1219-26.
21. Dworak M, Andraska EA, Gharacholou SM, et al. Fluorescent angiography used as a tool to guide angiosome-directed endovascular therapy for diabetic foot ulcers. J Vasc Surg Cases Innov Tech 2021;7:159-63.
22. Tange FP, Ferrari BR, van den Hoven P, et al. Evaluation of the Angiosome Concept Using Near-Infrared Fluorescence Imaging with Indocyanine Green. Ann Vasc Surg 2023;93:283-90.
23. Ricco JB, Gargiulo M, Stella A, et al. Impact of angiosome- and nonangiosome-targeted peroneal bypass

© AME Publishing Company.

on limb salvage and healing in patients with chronic limb-threatening ischemia. J Vasc Surg 2017;66:1479-87.
24. Troisi N, Turini F, Chisci E, et al. Pedal arch patency and not direct-angiosome revascularization predicts outcomes of endovascular interventions in diabetic patients with critical limb ischemia. Int Angiol 2017;36:438–44.
25. Bunte MC, Shishehbor MH. Treatment of infrapopliteal critical limb ischemia in 2013: the wound perfusion approach. Curr Cardiol Rep 2013;15:363.
26. Iida O, Takahara M, Soga Y, et al. Worse limb prognosis for indirect versus direct endovascular revascularization only in patients with critical limb ischemia complicated with wound infection and diabetes mellitus. Eur J Vasc Endovasc Surg 2013;46:575-82.
27. Kim KG, Meshkin DH, Tirrell AR, et al. A systematic review and meta-analysis of endovascular angiosomal revascularization in the setting of collateral vessels. J Vasc Surg 2021;74:1406-1416.e3.
28. Kawarada O, Fujihara M, Higashimori A, et al. Predictors of adverse clinical outcomes after successful infrapopliteal intervention. Catheter Cardiovasc Interv 2012;80:861-71.
29. Fossaceca R, Guzzardi G, Cerini P, et al. Endovascular treatment of diabetic foot in a selected population of patients with below-the-knee disease: is the angiosome model effective? Cardiovasc Intervent Radiol 2013;36:637-44.
30. Acín F, Varela C, López de Maturana I, et al. Results of infrapopliteal endovascular procedures performed in diabetic patients with critical limb ischemia and tissue loss from the perspective of an angiosome-oriented revascularization strategy. Int J Vasc Med 2014;2014:270539.
31. Pavé M, Benadiba L, Berger L, et al. Below-The-Knee Angioplasty for Critical Limb Ischemia: Results of a Series of 157 Procedures and Impact of the Angiosome Concept. Ann Vasc Surg 2016;36:199-207.
32. Soares Rde A, Brochado Neto FC, Matielo MF, et al. Concept of Angiosome Does Not Affect Limb Salvage in Infrapopliteal Angioplasty. Ann Vasc Surg 2016;32:34-40.
33. Ambler GK, Stimpson AL, Wardle BG, et al. Infrapopliteal angioplasty using a combined angiosomal reperfusion strategy. PLoS One 2017;12:e0172023.
34. Weaver ML, Hicks CW, Canner JK, et al. The Society for Vascular Surgery Wound, Ischemia, and foot Infection (WIfI) classification system predicts wound healing better than direct angiosome perfusion in diabetic foot wounds. J Vasc Surg 2018;68:1473-81.
35. Azuma N, Uchida H, Kokubo T, et al. Factors influencing wound healing of critical ischaemic foot after bypass surgery: is the angiosome important in selecting bypass target artery? Eur J Vasc Endovasc Surg 2012;43:322-8.
36. Kret MR, Cheng D, Azarbal AF, et al. Utility of direct angiosome revascularization and runoff scores in predicting outcomes in patients undergoing revascularization for critical limb ischemia. J Vasc Surg 2014;59:121-8.
37. Rohrich RN, Li KR, Lava CX, et al. Angiosome-Guided Revascularization in Local Flap Reconstruction of the Foot and Ankle: Comparable Outcomes With Both Direct and Indirect Revascularization. Ann Plast Surg 2025;94:195-203.
38. Varela C, Acín F, de Haro J, et al. The role of foot collateral vessels on ulcer healing and limb salvage after successful endovascular and surgical distal procedures according to an angiosome model. Vasc Endovascular Surg 2010;44:654-60.
39. Zheng XT, Zeng RC, Huang JY, et al. The Use of the Angiosome Concept for Treating Infrapopliteal Critical Limb Ischemia through Interventional Therapy and Determining the Clinical Significance of Collateral Vessels. Ann Vasc Surg 2016;32:41-9.
40. Serizawa F, Nakano Y, Hashimoto M, et al. Distal Bypass Improves Skin Perfusion Pressure at the Whole Foot Regardless of Angiosomes in Patients with Chronic Limb-Threatening Ischemia. Ann Vasc Dis 2024;17:150-6.
41. Gazzaruso C, Montalcini T, Gallotti P, et al. Impact of microvascular complications on the outcomes of diabetic foot in type 2 diabetic patients with documented peripheral artery disease. Endocrine 2023;80:71-8.
42. Sommerset J, Karmy-Jones R, Dally M, et al. Plantar Acceleration Time: A Novel Technique to Evaluate Arterial Flow to the Foot. Ann Vasc Surg 2019;60:308-14.
43. Souza DA, Medrado PVF, Santos VA, et al. Duplex ultrasound and pedal acceleration time as tools to evaluate foot perfusion: a literature review. J Vasc Bras 2024;23:e20230017.
44. Pinelo A, Afonso M, Silva I. Comparative Outcomes of Targeted Versus Nontargeted Angiosome Revascularization for Diabetic Foot Wounds Impact of Target Arterial Path on Wound Healing. Ann Vasc Surg 2025;110:233-43.

Cite this article as: Moysidis T, Patrone L, Böckler D, Niemöller K, Korosoglou G. The angiosome and woundosome concepts in guiding revascularization for chronic limb-threatening ischemia and diabetic foot ulcers—a narrative review. Cardiovasc Diagn Ther 2025;15(6):1227-1241. doi: 10.21037/cdt-2025-305

© AME Publishing Company.