



Since January 2020 Elsevier has created a COVID-19 resource centre with free information in English and Mandarin on the novel coronavirus COVID-19. The COVID-19 resource centre is hosted on Elsevier Connect, the company's public news and information website.

Elsevier hereby grants permission to make all its COVID-19-related research that is available on the COVID-19 resource centre - including this research content - immediately available in PubMed Central and other publicly funded repositories, such as the WHO COVID database with rights for unrestricted research re-use and analyses in any form or by any means with acknowledgement of the original source. These permissions are granted for free by Elsevier for as long as the COVID-19 resource centre remains active.

CLINICAL ELECTROPHYSIOLOGY

Prone and Supine 12-Lead ECG Comparisons



Implications for Cardiac Assessment During Prone Ventilation for COVID-19

David Chieng, MBBS,^{a,b,c} Hariharan Sugumar, MBBS, PhD,^{a,b,c} David Kaye, MBBS, PhD,^{a,b,d} Sonia Azzopardi, RN,^{a,b} Donna Vizi, RN,^b Erina Rossi, BS,^b Aleksandr Voskoboinik, MBBS, PhD,^{a,b,c} Sandeep Prabhu, MBBS, PhD,^{a,b,c} Liang-Han Ling, MBBS, PhD,^{a,b,c} Geoffrey Lee, MBChD, PhD,^{c,e} Jonathan M. Kalman, MBBS, PhD,^{c,d,e} Peter M. Kistler, MBBS, PhD^{a,b,c,d}

ABSTRACT

OBJECTIVES This study sought to describe expected changes in a mirror-image prone electrocardiogram (ECG) compared with normal supine, including a range of cardiac conditions.

BACKGROUND Unwell COVID-19 patients are at risk of cardiac complications. Prone ventilation is recommended but poses practical challenges to acquisition of a 12-lead ECG. The effects of prone positioning on the ECG remain unknown.

METHODS 100 patients each underwent 3 ECGs: standard supine front (SF); prone position with precordial leads attached to front (PF); and prone with precordial leads attached to back in a mirror image to front (PB).

RESULTS Prone positioning was associated with QTc prolongation (PF 437 ± 32 ms vs. SF 432 ± 31 ms; $p < 0.01$; PB 436 ± 34 ms vs. SF 432 ± 31 ms; $p = 0.02$). In leads V_1 to V_3 on PB ECG, a qR morphology was present in 90% and changes in T-wave polarity in 84%. In patients with anterior ischemia, ST-segment changes in V_1 to V_3 on supine ECG were no longer visible on PB in 100% and replaced by an R-wave in V_1 . Bundle branch block (BBB) remained detectable in 100% on PB, with left BBB appearing as right BBB on PB in 71% and QRS narrowing with qR in V_1 for right BBB. ST-segment/T-wave changes in limb leads and arrhythmia detection were largely unaffected in PB.

CONCLUSIONS As expected, the PB ECG is unreliable for the detection of anterior myocardial injury but remains useful for ST-segment/T-wave abnormalities in limb leads, BBB detection, and rhythm monitoring. The prone ECG is a useful screening tool with diagnostic utility in COVID-19 patients who require prone ventilation.

(J Am Coll Cardiol EP 2021;7:1348–1357) © 2021 by the American College of Cardiology Foundation.

From the ^aBaker Heart and Diabetes Research Institute, Melbourne, Australia; ^bDepartment of Cardiology, Alfred Hospital, Melbourne, Australia; ^cUniversity of Melbourne, Melbourne, Australia; ^dMonash Health, Melbourne, Australia; and the ^eDepartment of Cardiology, Royal Melbourne Hospital, Melbourne, Australia.

Joshua Cooper, MD, served as Guest Editor for this paper. William Stevenson, MD, served as Guest Editor-in-Chief for this paper. The authors attest they are in compliance with human studies committees and animal welfare regulations of the authors' institutions and Food and Drug Administration guidelines, including patient consent where appropriate. For more information, visit the [Author Center](#).

Manuscript received January 20, 2021; revised manuscript received April 12, 2021, accepted April 21, 2021.

The coronavirus-2019 (COVID-19) disease was declared a pandemic in March 2020. As of April 2021, the pandemic has infected more than 135 million people worldwide and caused more than 2.9 million deaths, with North America and Europe currently experiencing an upsurge in infections (1).

COVID-19 disease ranges from influenza-type symptoms to respiratory failure from acute respiratory distress syndrome (ARDS), to multiorgan failure. COVID-19 disease is associated with cardiac complications, which contribute to overall mortality (2). Hospitalized patients are generally older with cardiovascular comorbidities, which increases the risk of morbidity and mortality (3). Myocardial injury had been observed in 36% of hospitalized COVID-19 patients (4). Cardiac arrhythmias have also been reported (5).

In view of this, cardiac monitoring with telemetry and/or electrocardiogram (ECG) is recommended in hospitalized COVID-19 patients (6). Furthermore, cardiac monitoring is important because pharmacotherapy may be proarrhythmic. In particular, hydroxychloroquine and azithromycin are known to prolong the QT interval, with the risk of torsade de pointes heightened by concomitant illness and polypharmacy (7).

In COVID-19 patients with hypoxic respiratory failure, early intubation and ventilation have been recommended in society guidelines. Early proning has become an important ventilation strategy that improves oxygenation (8). A prone ECG avoids repositioning patients for a 12-lead ECG, which may result in oxygen desaturation and is labor-intensive. Although prone positioning is useful, the impact on the 12-lead ECG is relatively unknown. ECG leads V₇ to V₉, as an extension of precordial leads V₁ to V₆, have long existed to diagnose a posterior infarct. However, the utility of a complete posterior ECG as a mirror image to the usual supine precordial V₁ to V₆ arrangement has not been well described. Smaller studies have reported expected differences in ECG appearances in a supine versus prone position, although the studies were confined to healthy volunteers (9,10).

As the COVID-19 pandemic continues to challenge health care systems, a prone ventilation strategy is increasingly used. The 12-lead ECG is the cornerstone of cardiac assessment and provides an inexpensive, repeatable assessment for cardiac complications. The present prospective study was designed to: 1) describe expected differences in the 12-lead ECG in the prone position compared with the supine and; 2) determine the usefulness of the prone ECG in

detecting myocardial injury and abnormalities in rhythm and conduction.

METHODS

STUDY DESIGN. This was a prospective, multicenter, observational study comparing the 12-lead ECG appearances in supine and prone positions conducted in Melbourne, Australia. Consecutive patients were recruited from cardiology units in September 2020. Exclusion criteria were an inability to consent or to lie prone to perform 12-lead ECGs. To protect research staff from unnecessary exposure to SARS-CoV-2, no COVID-19-positive patient was recruited. Due to COVID-19 hospital precautions, access to intubated patients within the intensive care unit was not permitted.

Patient demographics, including age, body mass index, comorbidities, and echocardiographic data, were collected.

The study was granted expedited ethics approval as a COVID-19-related research activity (Alfred HREC 67556)

ECG ACQUISITION. The ECGs were acquired with the PageWriter Cardiograph TC50 machine (Philips, Amsterdam, the Netherlands) at a paper speed of 25 mm/s, and low-frequency limit of 0.05 Hz.

The precordial leads (V₁ to V₆) were attached to the chest in the standard configuration (Figure 1):

- V₁ and V₂ were placed in the fourth intercostal space.
- V₃ to V₆ were placed in the fifth intercostal space: V₄ at the left mid-clavicular line, and V₆ at the left mid-axillary line.
- Limb leads (right and left, upper and lower limbs) were attached as per standard configuration.

A 12-lead ECG was acquired with the patient lying in a supine position (hereon referred to as the supine front [SF] position). Patients were then turned into a prone position with the precordial leads still attached to the chest, with another ECG acquired (hereon referred to as the prone front [PF] position).

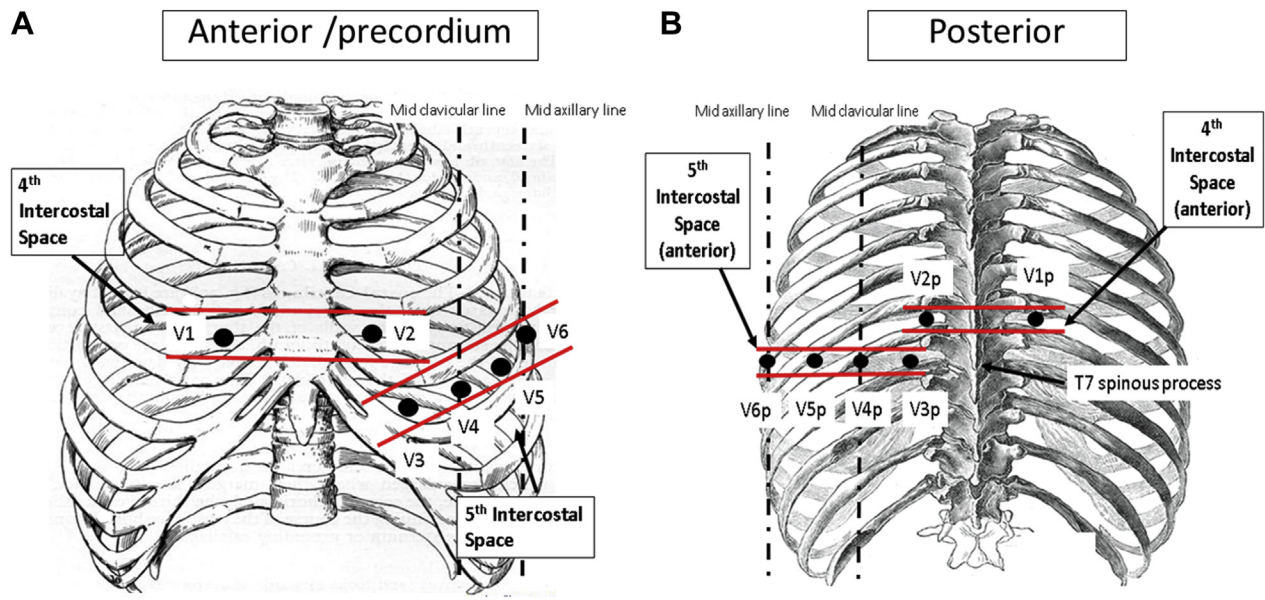
The precordial leads were then repositioned to the back in a mirror image to the chest positions (Figure 1):

- V_{3p} to V_{6p} were placed in an exact mirror image position to V₃ to V₆ anteriorly in the fifth intercostal space, with V_{4p} in the mid-clavicular line and V_{6p} in the mid-axillary line. The V_{3p} to V_{6p} location approximates the T7 vertebrae spinous

ABBREVIATIONS AND ACRONYMS

AF	= atrial fibrillation
ARDS	= acute respiratory distress syndrome
BBB	= bundle branch block
COVID-19	= coronavirus-2019
ECG	= electrocardiogram
ICC	= intraclass correlation coefficient
LBBB	= left bundle branch block
PB	= prone back
PF	= prone front
RBBB	= right bundle branch block
SF	= supine front
STEMI	= ST-segment elevation myocardial infarction
TWI	= T-wave inversion

FIGURE 1 Supine and Prone Electrocardiogram Lead Placement



(A) Precordial lead positioning in a supine front (SF) position; (B) lead positioning in a prone back (PB) position.

process, which served as a landmark for lead positioning.

- V_{1p} and V_{2p} were placed 1 intercostal space higher than V_{3p} to V_{6p}, with V_{1p} placed right of spine (as opposed to left of spine in the anterior position), and V_{2p} placed left of spine (as opposed to right of spine in the anterior position).

Another ECG was acquired in this position (hereon referred to as the prone back [PB] position). In total, 3 ECGs were recorded for each patient (1 in the supine position, 2 in the prone position), acquired in a single, consecutive sequence within minutes of each other.

ECG ANALYSIS/ADJUDICATION. Supine and prone ECGs were individually analyzed by 2 cardiologists who were blinded to the body positions in which the ECGs were recorded, as well as the patients' underlying clinical condition. The following parameters in each ECG lead were collected and subsequently compared between the supine and prone positions:

- Intervals: PR interval, QRS duration, QTc interval (Bazett's formula [$QTc = QT/\sqrt{RR}$]).
- QRS: relative amplitude of Q, R, and S waves of QRS complex, and axis shift.
- ST segment: significant deviation (elevation/depression) in at least 1 lead, measured at the J point + 80 ms

- ST-segment elevation/depression: at least 2 mm in V₁ to V₃ or at least 1 mm in all other leads.

- T-wave: polarity (positive/negative) and amplitude.
- Bundle branch block (BBB): polarity change (left BBB [LBBB]/right BBB [RBBB]).
- Arrhythmia detection: atrial fibrillation (AF) and flutter.

STATISTICAL ANALYSIS. Correlation scatterplots were derived for PR interval, QRS duration, QTc interval, and QRS axes in paired sets of ECGs (SF vs. PF; and SF vs. PB) for each patient, and evaluated using intraclass correlation coefficient (ICC). ICC was evaluated using 2-way mixed model and absolute agreement. Paired analysis of ECG intervals was performed using the Student's *t*-test. In a subset of patients with normal ECG at baseline (SF position), the relative changes in P-wave, QRS-complex, and T-wave amplitudes with different body positions were evaluated by dividing the 12-lead ECG into subregions (I, aVL: lateral limb leads; II, III, and aVF: inferior leads; V₁ to V₃: anterior precordial leads; V₄ to V₆: lateral precordial leads). Paired analyses (SF vs. PF; and SF vs. PB) within each subregion were performed using the Student's *t*-test if data were normally distributed, and the Wilcoxon signed rank test if data were non-normally distributed. Data normality was assessed using the Shapiro Wilks test. A *p* value of <0.05 was

TABLE 1 Patient Cohort Characteristics (N = 100)

Age, yrs	66 ± 14
Range	23-92
Male	52 (52)
BMI, kg/m ²	29.1 ± 6.8
Comorbidities	
Cardiomyopathy	38 (38)
Ischemic heart disease	44 (44)
Hypertension	49 (49)
Diabetes mellitus	17 (17)
HCM	3 (3)
Arrhythmia	
AF	22 (22)
AFL	3 (3)
Echocardiogram	
LVEDD, mm	47.5 ± 7.3
LVESD, mm	33.5 ± 8.4
LVEF, %	52.0 ± 12.7
LAVI, ml/m ²	44.1 ± 20.5
RVSP, mm Hg	32.5 ± 9.7
Medications	
Anticoagulation agent	22 (22)
Aspirin	55 (55)
Antiplatelet agent	37 (37)
Beta blocker	62 (62)
Antiarrhythmic drug	11 (11)
ACE inhibitor/ARB	47 (47)

Values are mean ± SD or n (%) except as noted.
 ACE = angiotensin-converting enzyme; AF = atrial fibrillation; AFL = atrial flutter; ARB = angiotensin receptor blocker; BMI = body mass index; HCM = hypertrophic cardiomyopathy; LAVI = left atrial indexed volume; LVEDD = left ventricular end-diastolic diameter; LVESD = left ventricular end-systolic diameter; LVEF = left ventricular ejection fraction; RVSP = right ventricular systolic pressure.

considered statistically significant. Study analyses were performed using IBM SPSS Statistics 26 software (IBM, Chicago, Illinois).

RESULTS

BASELINE CHARACTERISTICS. The study population included 100 patients (mean age 66 years; 48% female; mean body mass index 29.1 kg/m²). The main admission diagnoses were non-ST-segment elevation myocardial infarction (non-STEMI) in 18%, STEMI in 13%, and arrhythmia in 12%. The most common comorbidities were hypertension (49%), ischemic heart disease (44%), congestive cardiac failure (38%), and arrhythmias (27%). Baseline characteristics are summarized in [Table 1](#).

INTERVALS. The PR interval was highly correlated between SF and PF (SF 176.9 ± 31.5 ms vs. PF 175.6 ± 29.9 ms; ICC 0.98, 95% confidence interval: 0.98 to 0.99), as well as between SF and PB (SF 176.9 ±

31.5 ms vs. PB 176.1 ± 27.8 ms; ICC 0.97, 95% confidence interval: 0.95 to 0.98). There was no statistically significant difference in the PR intervals between different body positions ([Supplemental Figure 1](#)). High ICC scores were observed for QRS duration and QTc intervals between the SF position and the PF and PB positions, respectively ([Supplemental Figure 1](#)). The mean QTc interval was significantly longer in the PF position (437 ± 32 ms) compared with the SF position (432 ± 31 ms; p < 0.01); and in the PB position (PB 436 ± 34 ms vs. SF 432 ± 31 ms; p = 0.02).

NORMAL BASELINE ECG AND EFFECTS OF BODY POSITION. A normal ECG was recorded in 24 patients in the SF position, and a detailed analysis of the P, Q, R, S, and T waves and ST-segment in response to body position changes was undertaken ([Table 2](#)). Compared with a SF position, there were significant changes in amplitude, but not polarity, in a PF position:

- Reduced R-wave amplitude in leads V₁ to V₃ (PF 3.4 ± 1.8 mV vs. SF 4.7 ± 2.1 mV; p < 0.01).
- Increased S-wave amplitude in leads V₄ to V₆ (PF -2.8 ± 2.1 mV vs. SF -2.1 ± 1.6 mV; p < 0.01). attributable to a later precordial R-wave transition in PF position; and
- Increased T-wave amplitude in leads V₄ to V₆ (PF 2.3 ± 1.0 mV vs. SF 1.6 ± 0.7 mV; p < 0.01).

Conversely, marked changes were seen in a PB position when compared with a SF position:

- New Q-wave in leads V₁ to V₃ (PB -1.09 ± 0.5 mV vs. SF 0 mV; p < 0.01).
- New Q-wave in leads V₄ to V₆ (PB -0.2 ± 0.4 mV vs. SF 0 mV; p < 0.01).
- Reduced R-wave amplitude in leads V₁ to V₃ (PB 2.5 ± 0.9 mV vs. SF 4.7 ± 2.1 mV; p < 0.01); and leads V₄ to V₆ (PB 6.9 ± 2.6. mV vs. SF 9.8 ± 3.5 mV; p < 0.01).
- Reduced S-wave amplitude in V₁ to V₃ (PB 0.04 ± 0.2 mV vs. SF -7.5 ± 3.3 mV; p < 0.01); and leads V₄ to V₆ (PB -0.5 ± 0.1 mV vs. SF -2.1 ± 1.6 mV; p < 0.01).
- T-wave flattening in leads V₁ to V₃ (T-wave amplitude PB -0.01 ± 0.1 mV vs. SF 1.7 ± 1.4 mV; p < 0.01).

QRS MORPHOLOGY CHANGES. Excluding 13 patients who had BBB on baseline ECG, the predominant precordial QRS morphology in the SF position was an rS pattern in V₁ to V₃ (76%) ([Supplemental Figure 2](#)). In the PF position, the ECG was largely unchanged aside from a delay in precordial R-wave transition by ≥1 V lead (n = 32, 91%). In a PB position, changes in

TABLE 2 Changes in P, Q, R, S, and T Waves and ST Segment Across SF, PF, and PB Positions in Subset of Patients With Normal ECG

ECG Lead	ECG Component	Supine Front Mean \pm SD	Prone Front ^a Mean \pm SD	Prone Back ^b Mean \pm SD
I/aVL	P	0.35 \pm 0.4	0.41 \pm 0.3	0.32 \pm 0.3
	Q	-0.04 \pm 0.1	-1.25 \pm 0.3	-0.10 \pm 0.4
	R	5.84 \pm 2.8	6.18 \pm 3.0	6.22 \pm 2.9
	S	-0.52 \pm 0.7	-0.65 \pm 0.9	-0.71 \pm 0.9
	ST	0	0	0
II/III/aVF	P	0.81 \pm 0.4	0.84 \pm 0.4	0.93 \pm 0.6
	Q	-0.08 \pm 0.3	-0.15 \pm 0.5	-0.15 \pm 0.5
	R	4.02 \pm 2.5	3.67 \pm 2.2	3.64 \pm 1.8
	S	-1.83 \pm 2.2	-2.11 \pm 2.1	-1.99 \pm 2.2
	ST	0	0	0
V ₁ -V ₃	P	0.45 \pm 0.4	0.35 \pm 0.5	0.36 \pm 0.4
	Q	0.00 \pm 0	-0.08 \pm 0.3	-1.09 \pm 0.5^c
	R	4.68 \pm 2.1	3.38 \pm 1.8^c	2.49 \pm 0.9^c
	S	-7.47 \pm 3.3	-8.03 \pm 3.6	0.04 \pm 0.2^c
	ST	0.11 \pm 0.3	0.11 \pm 0.3	0.00^d
V ₄ -V ₆	P	0.58 \pm 0.4	0.63 \pm 0.4	0.57 \pm 0.4
	Q	-0.06 \pm 0.2	-0.06 \pm 0.2	-0.24 \pm 0.4^c
	R	9.81 \pm 3.5	9.90 \pm 4.0	6.86 \pm 2.6^c
	S	-2.12 \pm 1.6	-2.82 \pm 2.1^c	-0.51 \pm 0.1^c
	ST	0.00 \pm 0.2	-0.04 \pm 0.2	-0.01 \pm 0.1
	T	1.58 \pm 0.7	2.26 \pm 1.0^c	1.59 \pm 0.7

Values in bold are statistically significant. ^aComparison between prone front (PF) and supine front (SF). ^bComparison between prone back (PB) and SF. ^cp < 0.01. ^dp < 0.05.
ECG = electrocardiogram.

QRS morphology were seen in all patients, confined to the precordial leads only. An initial Q-wave was present in leads V₁ to V₃ in 78 patients (90%), followed by low-amplitude R waves across the precordial leads (n = 83, 95.3%).

ST-SEGMENT CHANGES. Thirty-seven patients had significant ST-segment abnormality (elevation/depression) in the SF position, which included multiple regions in 18 patients. ST-segment abnormalities were seen in the inferior leads (n = 28), followed by leads V₁ to V₃ (n = 22) and V₄ to V₆ (n = 16) (Supplemental Figure 3). In a PF position, 10 of 37 patients (27%) had changes in the ST segment, with 11 of 14 ST-segment abnormalities (78.6%) showing either a reduction in amplitude or resolution of the ST-segment elevation depression.

In a PB position, 26 of 37 patients (78%) demonstrated changes in the ST-segment abnormality, particularly in the precordial leads. In 22 patients, which included 9 with anterior ischemia/infarct, anterior ST-segment elevation/depression was no longer present in leads V₁ to V₃ in all (100%) in the PB position (Central Illustration). All anterior STEMIs had

Q waves in V₁ to V₃ on SF ECG, which presented as an R-wave in V₁ to V₃ on PB. In the PF position, ST-segment elevation/depression in leads V₁ to V₃ remained visible in all but 1 patient. ST-segment changes in leads V₄ to V₆ (SF) were not seen in the PB position in 44%. By contrast, 95% of ECGs with ST-segment elevation/depression in the limb leads (SF position) were unchanged in the PB position. Figure 2 illustrates an anterior STEMI ECG with significant ST-segment changes in the PB position.

T-WAVE CHANGES. Positive T waves were present in leads V₁ to V₃ in 42 of 100 patients in the SF position. In the PB position, 31 of 42 (74%) developed a negative/flat T-wave appearance in V₁ to V₃.

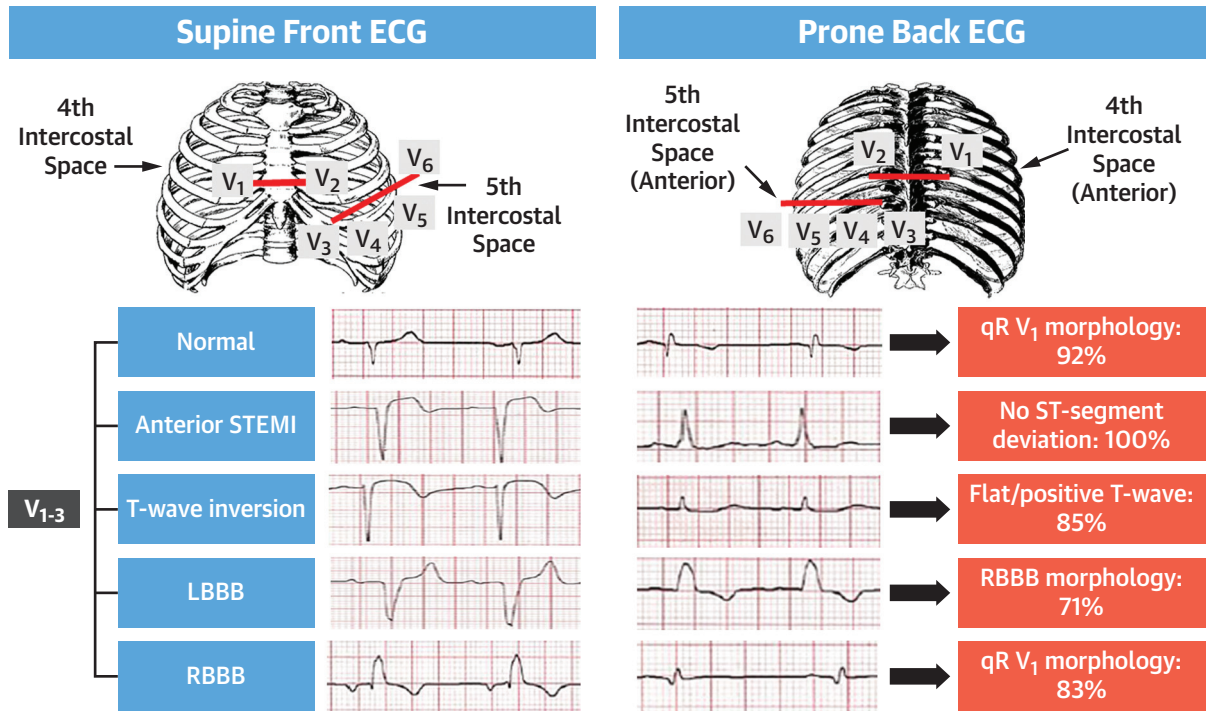
A T-wave abnormality was seen in the SF position in 58 patients, with T-wave inversion (TWI) present in at least 1 ECG region in 55 patients; 25 of 55 (46%) had T-wave changes involving more than 1 region. In the PF position, 8 of 58 patients (16%) had evidence of changes to the T-wave, which were mostly polarity changes in the same leads: TWI in V₁ to V₃ (SF) changed to positive on PF in 1 patient, TWI in V₄ to V₆ (SF) changed to positive/flat on PF in 4 patients, and TWI in I, aVL (SF) changed to positive on PF in 1 patients (Supplemental Figure 4).

In the PB position, there were changes in the abnormal T-wave in 53 of 58 patients (91%). Eleven of 13 ECGs (85%) with TWI in leads V₁ to V₃ demonstrated a positive/flat T-wave in a PB position. Of the 70 ECGs with TWI in the lateral precordial/limb leads on SF, 59 (84%) showed a new negative/flat T-wave in V₁ to V₃ in a PB position. The TWI in the lateral precordial/limb leads remained unaffected in leads V₄ to V₆ by PB positioning. Figure 3 illustrates an ECG with deep precordial TWI in SF position, with reversed T-wave polarity in V₁ to V₄ in the PB position.

BUNDLE BRANCH BLOCK. Thirteen patients had underlying BBB (7 LBBB, 6 RBBB) in the SF position. Significant changes in the ECG were seen in all in a PB position (Supplemental Figure 5). In particular, 5 patients (71%) with LBBB demonstrated a RBBB pattern in a PB position (Figure 4). In RBBB, the predominant change in the PB position was narrowing of the QRS complexes from 145 \pm 17.1 ms on SF to 103 \pm 16.9 ms on PB with a qR morphology in V₁ to V₃ (p = 0.03) (Figure 5).

ARRHYTHMIA. Ten patients were in AF/atrial flutter at the time of the ECG recording. The arrhythmias were all successfully reported by clinicians in all 3 positions. However, the automated reporting from the ECG machine incorrectly labelled 1 atrial flutter ECG as normal when recorded in a PB position.

CENTRAL ILLUSTRATION Supine Front and Prone Back ECG Changes in Normal ECG, Anterior STEMI, TWI, LBBB, and RBBB



Chieng, D. et al. J Am Coll Cardiol EP. 2021;7(11):1348-1357.

ECG = electrocardiogram; LBBB = left bundle branch block; RBBB = right bundle branch block; STEMI = ST-segment elevation myocardial infarction; TWI = T-wave inversion.

DISCUSSION

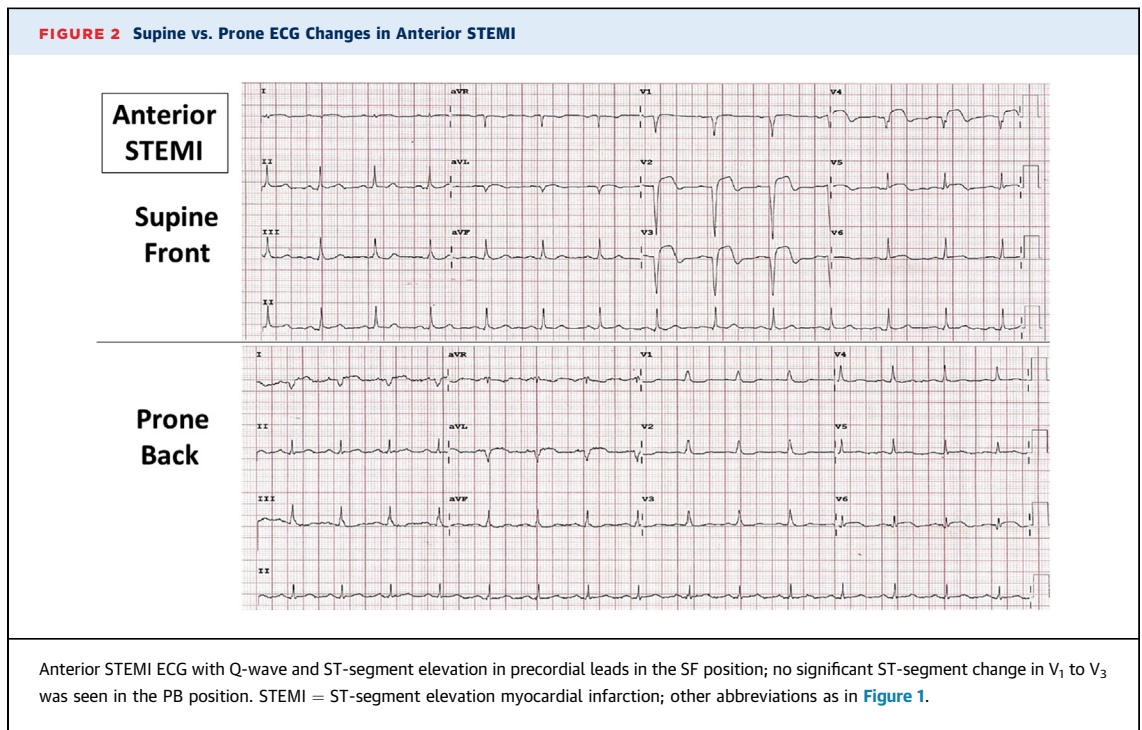
The present study describes a comparison of the traditional ECG recorded SF versus PF and PB positions. Although posterior leads V₇ to V₉ have long existed, the utility of a mirror-image prone ECG has not previously described. In patients with COVID-19 and oxygen desaturation, prone ventilation has been beneficial and may avoid the need for mechanical ventilation. The ability to interpret an ECG in the prone position maintains the utility of the ECG and avoids patient repositioning, which may compromise their respiratory status. We present significant findings on the 12-lead ECG performed in the prone position:

- a) Prone positioning was associated with a numerically small, but statistically significant, QTc prolongation.
- b) Prone positioning with precordial leads attached in a mirror-image position on the back (PB) was associated with new qR morphology in leads V₁ to V₃ in 90% and a significant reduction in R-, S-, and T-wave amplitude in leads V₁ to V₃.

- c) In patients with anterior myocardial ischemia/infarct with ST changes in leads V₁ to V₃ on SF ECG, these changes were no longer visible in V₁ to V₃ on PB. In patients with lateral ST changes in leads V₄ to V₆ on SF ECG these changes were no longer visible in 44% on PB. By contrast, ST-segment elevation/depression in the limb leads remained mostly unchanged in the PB position.
- d) PB positioning was associated with a change in the polarity of the T-wave in leads V₁ to V₃ in 84%. TWI in lateral precordial/limb leads remained unaffected by PB positioning.
- e) LBBB demonstrated a polarity shift, with a RBBB appearance in a PB position.
- f) RBBB became narrower with a qR appearance in V₁ to V₃.
- g) Arrhythmia detection was not affected by prone positioning.

COVID-19 DISEASE AND CARDIAC COMPLICATIONS.

There is an increasing body of literature on COVID-19 disease and associated cardiac complications. Elevated cardiac troponin-I levels has been reported in



36% of patients, consistent with myocardial injury (4). The mechanisms responsible for myocardial insult are multifactorial and include ischemia, systemic inflammatory response, and microthrombi (11). A case series of COVID-19 patients with ST-segment elevation on ECG portended a poor prognosis (12). Arrhythmias are reported in 25% of COVID-19 patients, with AF/atrial flutter being the most common (13).

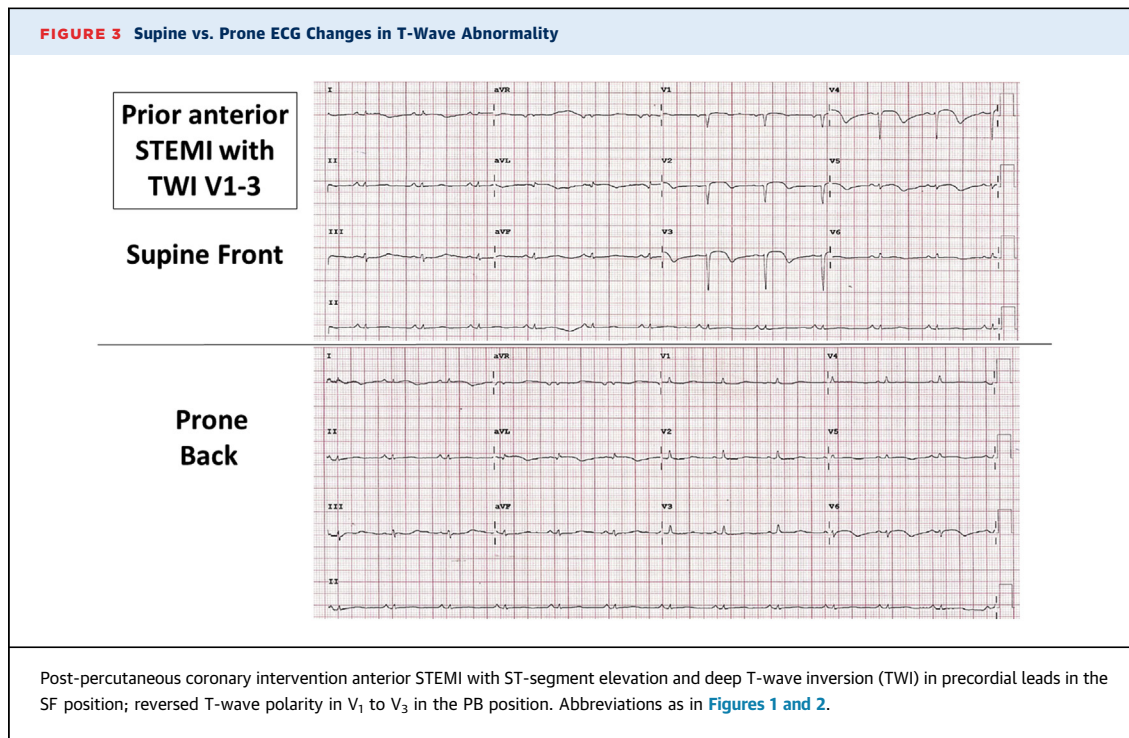
Several studies have demonstrated a poorer prognosis of an abnormal supine ECG in patients with COVID-19 (14). Bertini et al. (15) reported ECG findings in 431 COVID-19 patients. Among them, 24% were on mechanical ventilation, and 35% on supine noninvasive ventilation, at the time of ECG recording. The ECG was abnormal in 93%, with the most common findings being nonspecific repolarization abnormalities, QTc prolongation, and right ventricular pressure overload. The study was limited by the inability to distinguish between pre-existing and new-onset COVID-19-related ECG abnormalities but nonetheless demonstrated the fundamental importance of the 12-lead ECG.

PRONE VENTILATION. The benefits of prone positioning in non-COVID-19-related ARDS has been well described. Prone positioning results in improved ventilation-perfusion matching. Consequently, better oxygenation is attained, with improved survival outcomes demonstrated in patients with moderate to severe ARDS (16). As such, guidelines have

recommended prone positioning ≥ 12 h a day in mechanically ventilated patients with severe ARDS, including in the setting of COVID-19 (16). There has been a significant uptake of prone positioning in the COVID-19 pandemic with the Danish PROVENT-COVID (Practice of Ventilation in COVID-19 Patients) study showing that prone positioning was used in over one-half of 530 patients (17).

Recent studies have also demonstrated the feasibility of proning in nonintubated patients (18,19). Oxygenation substantially improved from supine to prone positioning (19). Importantly, early prone positioning was associated with better maintenance of oxygenation during hospitalization. These findings are substantial because they show that proning in nonintubated patients can be safely performed on wards outside of the intensive care unit (18). A large meta-trial is currently underway looking at the efficacy of awake prone positioning in COVID-19 patients (20). Under such circumstances, the ability to perform and interpret a 12-lead ECG in the prone position will avoid repositioning patients with the potential for respiratory deterioration.

PRONE VERSUS SUPINE ECG. ECG lead placement in a posterior body position is not a unique concept. Classically posterior leads V₇ to V₉, have been used as an extension of precordial leads V₁ to V₆ in the detection of posterior myocardial infarction (21). Lead V₇ is placed at the left posterior axillary line at the



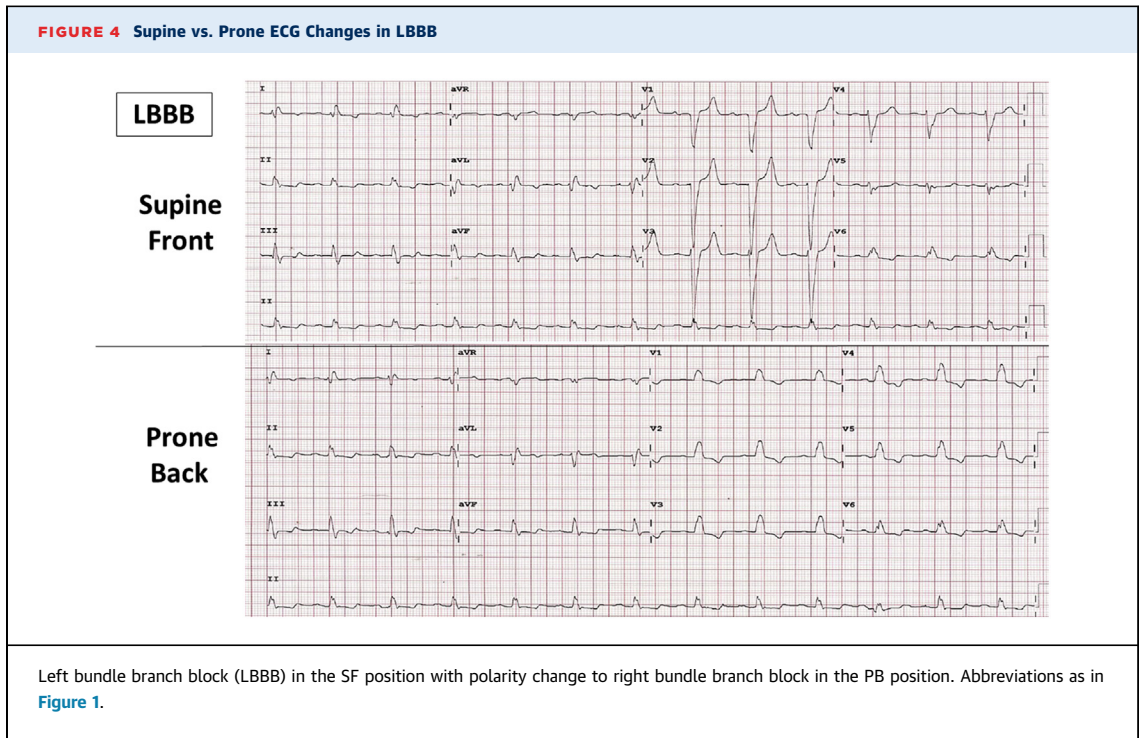
level of V₆, lead V₈ at the left mid-scapular line, and lead V₉ at the left paravertebral border (21). The present study extends this concept to explore both the effects of prone positioning and a complete posterior ECG as a mirror image to the precordial V₁ to V₆. Prior small studies have compared the appearance of the prone and supine ECG in healthy volunteers. Mangar et al. (10) studied 12 healthy volunteers with prone ECG performed with the precordial leads taped to the chest, similar to the PF position in the present study. Changes in QRS axis and morphology between different positions were reported. Nguyen et al. (22) reported on the effect of prone positioning on ECG appearances in 20 COVID-19 patients, with the chest leads placed on the back in a mirror image to the precordium (similar to the PB position in the present study). As in the present study, leads V₁ to V₃ showed prominent Q waves, and there was a significant reduction in QRS amplitude in leads V₁ to V₅ in the prone position.

A significantly different ECG appearance in a prone position is hardly surprising. The Q-wave appearance in V₁ to V₃ on the prone ECG is explained by the initial electrical force being directed anteriorly away from the leads positioned on the back. We hypothesize that differences in the ST-segment and T-wave between the supine and prone positions in leads V₁ to V₃ are explained by the change in position of the ECG leads in relation to the wave-front

vector for depolarization (ST-segment) and repolarization (T-wave). In some patients, signal attenuation could be explained by a more ventral position of the heart in the prone position coupled with increased muscle and bone between the heart and the prone ECG leads.

CLINICAL IMPLICATIONS. The present study describes the utility of the 12-lead ECG performed PB in a range of common cardiac conditions. The PB ECG provides reliable rhythm monitoring and detection of myocardial injury involving the inferior and lateral myocardium, making it a useful alternative to the traditional supine ECG to avoid repositioning a patient who requires prone ventilation. However, the PB ECG is not reliable for the detection of anterior ischemia. The typical ST-T-wave changes in the precordial leads for anterior myocardial ischemia are generally no longer present. Rather, the PB ECG features of an anteroseptal infarct is the presence of an R-wave instead of a qR morphology in leads V₁ to V₃. For BBB, a LBBB appears more like a RBBB. A RBBB is more difficult to detect with a narrower QRS width and a qR in leads V₁ to V₃.

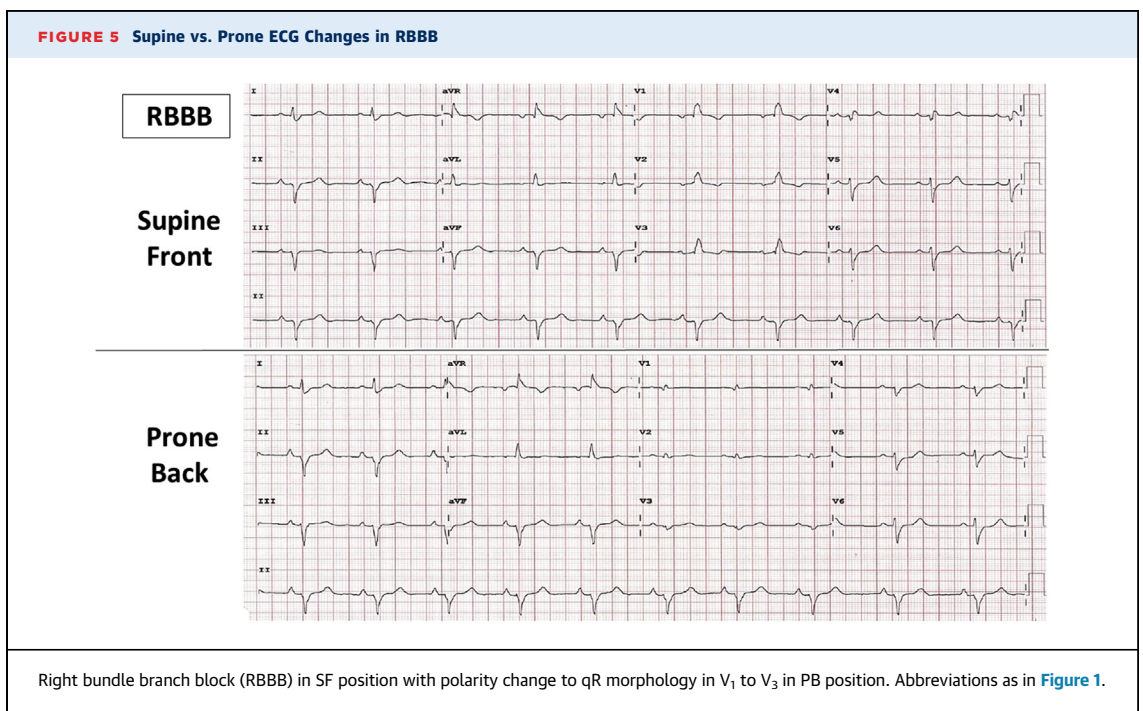
STUDY LIMITATIONS. A major limitation was the exclusion of intubated patients, which was performed to minimize disruption in the intensive care unit and avoid unnecessary exposure of research staff to COVID-19. Thus, the effects of mechanical ventilation



on ECG appearances are not reported. However, Bertini et al. (15) previously reported no difference in ECG features between ventilated and nonventilated patients. Although COVID-19 patients were not recruited into the study, the results are likely generalizable, given cardiac complications of COVID-19 are common to non-COVID-19 patients.

CONCLUSIONS

The 12-lead ECG is an important tool in the early detection and management of cardiac conditions in COVID-19. Prone positioning to improve oxygenation in patients with more severe COVID-19 provides practical challenges to the acquisition of the



traditional supine 12-lead ECG. As expected, the PB ECG is less reliable for the detection of anterior myocardial injury; however, it remains useful for ST-segment/T-wave abnormalities in the limb leads and rhythm monitoring. There are also differences in the appearance of BBB. The prone ECG is a useful screening tool with diagnostic utility in unwell COVID-19 patients who require prone ventilation.

FUNDING SUPPORT AND AUTHOR DISCLOSURES

Dr. Chiang is supported by a cofunded National Health and Medical Research Council/ National Heart Foundation post-graduate scholarship. Dr. Kalman has received research and fellowship support from Medtronic and Biosense Webster. Prof. Kistler has received funding from Abbott Medical; and fellowship support from Biosense Webster. All other authors have reported that they have no relationships relevant to the contents of this paper to disclose.

ADDRESS FOR CORRESPONDENCE: Prof. Peter M. Kistler, Department of Cardiology, Alfred Hospital, 55 Commercial Road, Melbourne 3004, Australia. E-mail: Peter.kistler@baker.edu.au.

PERSPECTIVES

COMPETENCY IN MEDICAL KNOWLEDGE: Prone positioning imposes practical challenges on the acquisition of a 12-lead ECG in COVID-19 patients with respiratory failure who are managed with a prone ventilation strategy. Using a prone back ECG allows for reliable detection of ST-segment/T-wave changes in limb leads, bundle branch blocks, and arrhythmia. However, it is not useful for the detection of anterior myocardial injury/ ischemia.

TRANSLATIONAL OUTLOOK: Machine learning-based prediction models could be developed to predict ECG appearances in a traditional supine front position based on the appearance of a prone back ECG. To facilitate this, a large volume of supine front versus prone back ECG comparisons would be required, which may yield further insights into anterior myocardial injury detection from a prone position.

REFERENCES

1. Worldometer. COVID-19 Coronavirus Pandemic 2020. Available at: <https://www.worldometers.info/coronavirus/>. Accessed April 9, 2021.
2. Turagam MK, Musikantow D, Goldman ME, et al. Malignant arrhythmias in patients with COVID-19: incidence, mechanisms and outcomes. *Circ Arrhythm Electrophysiol*. 2020;13(11):e008920.
3. Clerkin KJ, Fried JA, Raikhelkar J, et al. Coronavirus disease 2019 (COVID-19) and cardiovascular disease. *Circulation*. 2020;141:1648-1655.
4. Lala A, Johnson KW, Januzzi JL, et al. Prevalence and impact of myocardial injury in patients hospitalized with COVID-19 infection. *J Am Coll Cardiol*. 2020;76:533-546.
5. Wang D, Hu B, Hu C, et al. Clinical characteristics of 138 hospitalized patients with 2019 novel coronavirus-infected pneumonia in Wuhan, China. *JAMA*. 2020;323:1061-1069.
6. Lakkireddy D, Chung MK, Gopinathannair R, et al. Guidance for cardiac electrophysiology during the COVID-19 pandemic from the Heart Rhythm Society COVID-19 task force; Electrophysiology Section of the American College of Cardiology; and the Electrocardiography and Arrhythmias Committee of the Council on Clinical Cardiology, American Heart Association. *Heart Rhythm*. 2020;17:e233-e241.
7. Fernandes FM, Silva EP, Martins RR, Oliveira AG. QTc interval prolongation in critically ill patients: prevalence, risk factors and associated medications. *PLOS One*. 2018;13:e0199028.
8. Poston JT, Patel BK, Davis AM. Management of critically ill adults with COVID-19. *JAMA*. 2020;323:1839-1841.
9. Adams MG, Drew BJ. Body position effects on the ECG: implications for ischaemia monitoring. *J Electrocardiol*. 1997;30:285-291.
10. Mangar D, Lightly GW, Camporesi EM. Electrocardiographic changes associated with the prone position. *J Clin Monit*. 1992;8:92-93.
11. Atri D, Siddiqi HK, Lang JP, et al. COVID-19 for the cardiologist: basic virology, epidemiology, cardiac manifestations, and potential therapeutic strategies. *J Am Coll Cardiol Basic Trans Science*. 2020;5:518-536.
12. Bangalore S, Sharma A, Slotwiner A, et al. ST-segment elevation in patients with Covid-19—a case series. *N Engl J Med*. 2020;382:2478-2480.
13. Peltzer B, Manocha KK, Ying X, et al. Arrhythmic complications of patients hospitalized with COVID-19: incidence, risk factors and outcomes. *Circ Arrhythm Electrophysiol*. 2020;13(10):e009121.
14. Lanza GA, Vita AD, Ravenna SE, et al. Electrocardiographic findings at presentation and clinical outcome in patients with SARS-CoV-2 infection. *Europace*. 2021;23:123-129.
15. Bertini M, Ferrari R, Guardigli G, et al. Electrocardiographic features of 431 consecutive, critically ill COVID-19 patients: an insight into the mechanisms of cardiac involvement. *Europace*. 2020;22:1848-1854.
16. Fan E, Sorbo LD, Goligher EC, et al. An official American Thoracic Society/European Society of Intensive Care Medicine/Society of Critical Care Medicine clinical practice guideline: mechanical ventilation in adult patients with acute respiratory distress syndrome. *Am J Respir Crit Care Med*. 2020;195:1253-1263.
17. Botta M, Tsonas AM, Pillay J, et al. Ventilation management and clinical outcomes in invasively ventilated patients with COVID-19 (PROVENT-COVID): a national, multicentre, observational cohort study. *Lancet Respir Med*. 2021;9:139-148.
18. Paul V, Patel S, Roysse M, et al. Prone in non-intubated (PINI) in times of COVID-19: case series and a review. *J Intensive Care Med*. 2020;35:818-824.
19. Coppo A, Bellani G, Winterton D, et al. Feasibility and physiological effects of prone positioning in non-intubated patients with acute respiratory failure due to COVID-19 (PRON-COVID): a prospective cohort study. *Lancet Respir Med*. 2020;8:765-774.
20. Tavernier E, McNicholas B, Pavlov I, et al. Awake prone positioning of hypoxaemic patients with COVID-19: protocol for a randomised controlled open-label superiority meta-trial. *BMJ Open*. 2020;10:e041520.
21. van Gorpelen EOF, Verheugt FWA, Meursing BTJ, Oude Ophuis AJM. Posterior myocardial infarction: the dark side of the moon. Case report and review of electrocardiographic diagnosis. *Neth Heart J*. 2007;15:16-21.
22. Nguyen HH, Trohman RG, Huang HD. Challenges in clinical electrocardiography: influence of prone positioning on electrocardiogram in a patient with COVID-19. *JAMA Intern Med*. 2020;180:1521-1523.

KEY WORDS COVID-19, electrocardiogram, prone, supine

APPENDIX For supplemental figures, please see the online version of this paper.