

Secondary tumours of the ampulla of Vater: Case report and review of the literature

FRANCESCA SAROCCHI¹, MAGDALENA M. GILG^{1,2}, FLORIAN SCHREIBER³ and CORD LANGNER¹

¹Institute of Pathology, and ²Department of Orthopedics and Trauma Surgery, Medical University of Graz, A-8036 Graz; ³Department of Internal Medicine, Division of Gastroenterology and Hepatology, Medical University of Graz, A-8036 Graz, Austria

Received July 6, 2017; Accepted November 23, 2017

DOI: 10.3892/mco.2017.1535

Abstract. Secondary tumours of the ampulla of Vater are rare. Underlying primary tumours, clinical presentation, macroscopic appearance, treatment strategies and outcome of secondary ampullary lesions have not been systematically analysed. The present case study reported a 57-year old patient with an ampullary metastasis from renal cancer and a literature review was performed in which a further 32 patients were included. The most common responsible primary tumours were malignant melanoma and renal clear cell carcinoma, followed by breast cancer. The time interval between the diagnosis of the primary tumour and the ampullary metastasis was highly variable, and may be as long as 10 years, particularly for renal cancer. Patients may present with unspecific abdominal discomfort, jaundice or upper gastrointestinal bleeding. The gross appearance was largely indistinguishable from that of a primary tumour. Lesions may present as polypoid or irregular, soft and friable tumour mass, in certain cases with superficial ulceration. In ~50% of cases, the ampullary metastasis was the only metastatic lesion, while in the remaining cases, the cancer had spread to one or more organs. The prognosis was generally poor. The management requires a multi-modal approach, including endoscopic, surgical and oncological procedure.

Introduction

The ampulla of Vater was first described in a detailed manner by Abraham Vater in 1720 and it consists of three different anatomical structures: the duodenum, the terminal tract of the pancreatic duct and the final portion of the common bile duct (1). These elements have distinct functions and histological features, comprising intestinal, pancreatobiliary and gastric mucosal types (2).

Primary ampullary cancer comprises two main histological subtypes, the pancreatobiliary type and the intestinal type, but also rarer variants such as signet ring cell, adenocarcinoma, mucinous, clear cell, papillary, and neuroendocrine carcinoma (3,4). Adsay *et al* (2) classified ampullary cancers into four subtypes based upon their location which reflects different prognosis: intra-ampullary, peri-ampullary/duodenal, ampullary-ductal and ampullary lesions not otherwise specified. Occasionally, tumours of the pancreatic head or distal bile duct may extend into the ampullary region, thereby mimicking a primary ampullary neoplasm.

Several malignancies have been reported to involve the upper gastrointestinal tract in a secondary manner and among these lung cancer, breast cancer and malignant melanoma seem to be the most common primary sites (5). Within the upper gastrointestinal tract, the stomach is more often affected by secondary tumours than the duodenum. However, metastasis to the ampulla of Vater is exceedingly rare, with only 31 cases reported so far (6-33).

Herein we report the case of a 57-year-old patient who developed ampullary metastasis from renal cell carcinoma 3.5 years following initial diagnosis. Additionally, we conducted a systematic and comprehensive literature review summarizing all cases of secondary ampullary tumours documented in MEDLINE/PubMed until December 2016.

Case report

A 57-year-old male patient presented with subacute upper gastrointestinal bleeding 3.5 years at the Department of Gastroenterology, Medical University of Graz (Graz, Austria) following nephrectomy for renal clear cell carcinoma (pT3b, G2, N0, M0, R0). The requirement for written informed consent was waived for the present case report. The patient did not undergo any further adjuvant treatment but had regular follow-up until the occurrence of upper gastrointestinal bleeding. Upon gastroscopy, the ampulla of Vater was irregularly enlarged, vulnerable (Fig. 1A), and multiple biopsies were taken. All other parts of the upper gastrointestinal tract were entirely normal.

Histology showed well differentiated cancer cells with clear cytoplasm and small to moderately enlarged, hyperchromatic nuclei. The tumour cells were arranged in alveolar pattern (Fig. 1B-C) and were detected mainly in the submucosa

Correspondence to: Dr Cord Langner, Institute of Pathology, Medical University of Graz, Auenbruggerplatz 25, A-8036 Graz, Austria

E-mail: cord.langner@medunigraz.at

Key words: ampulla of Vater, ampullary tumour, metastasis, secondary tumour, histology, differential diagnosis

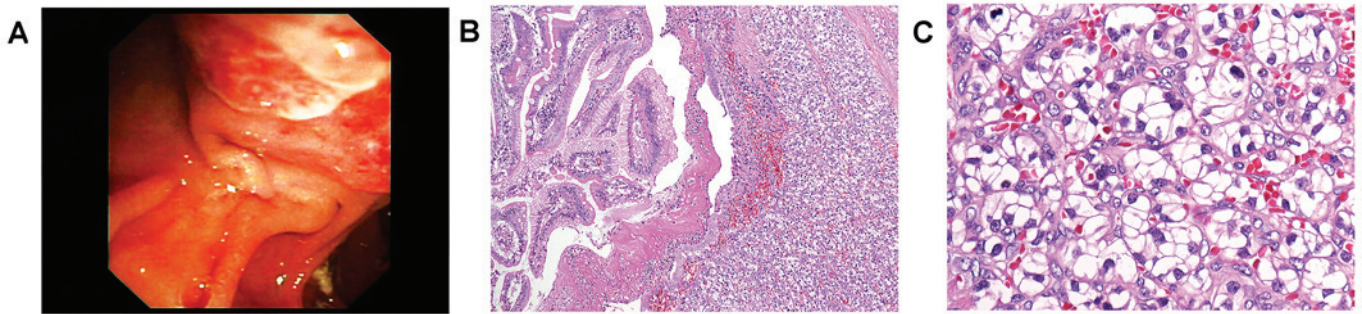


Figure 1. A, irregular enlargement of the ampulla. B, renal clear cell carcinoma which is developed mainly in the submucosa with secondary ulceration of the mucosal surface (original magnification, x100) C, well differentiated cancer cells arranged in typical alveolar pattern (original magnification, x250).

with secondary ulceration of the mucosal surface. Findings ultimately prompted diagnosis of secondary ampullary carcinoma, that is, metastatic disease from renal cell cancer.

Staging including CT of chest, abdomen and pelvis as well as whole body bone scan did not reveal further metastatic lesions. The patient underwent pylorus-preserving pancreaticoduodenectomy (Whipple procedure). Macroscopic workup of the surgical specimen showed a yellowish tumour mass within the ampulla, measuring 3 cm in largest diameter. All surgical resection margins and all dissected lymph nodes were free of cancer. The postoperative course was uneventful, and the patient discharged on postoperative day 15. Since then, the patient undergoes regular controls, including CT scans of the abdomen in regular intervals and there is now, four years after resection, no evidence of local recurrence or distant metastasis.

Discussion

We presented a rare case of secondary tumour of the ampulla of Vater. The corresponding primary tumour was renal clear cell carcinoma that had been operated 3.5 years earlier. Following pancreaticoduodenectomy, the patient is free of cancer for four years now.

A total of 32 secondary tumours, including our own case, have been reported to occur within the ampulla so far (Table I). Mean age at diagnosis of the secondary tumour is 56 years (median 55; range 27-81) (6-33). Renal carcinoma (n=11; 34%), malignant melanoma (n=10; 31%) and breast cancer (n=4, 13%) are the most common corresponding primary tumours. These three entities account for approximately three fourths of cases.

The mean time interval (known for 29 patients) between the diagnosis of the primary tumour and the ampullary metastasis is 4.8 years (median 3.5; range 0-17.5). However, lesions may also be detected synchronously with the primary tumour (n=5). Of note, time intervals for metastatic renal cancer lesions are particularly long (mean 8.8 years, median 10 years; range 0-17.5). In only one third of patients (n=12, 38%), as in the presented case, the ampullary metastasis was the only metastatic lesion, while in the remaining patients cancer spread to one or more organs was observed, most commonly to brain, liver, lungs, and bone. Notably, the majority of malignant melanomas showed involvement of several distant organs (Table I).

Clinical symptoms of secondary ampullary tumours are unspecific and similar to the presentation of primary tumours.

Affected individuals may present with abdominal discomfort (n=13, 41%), jaundice and related symptoms (n=18, 56%), such as pruritus or alterations in stool and urine or with upper gastrointestinal bleeding (n=11, 34%).

Likewise, endoscopic presentation is indistinguishable from that of primary tumours apart from metastatic melanomas which occasionally appear as pigmented lesions (34,35). According to the data retrieved from literature, the majority (n=24/26, 92%) of lesions are polypoid and irregular, soft and friable masses which can also be ulcerated. In addition to endoscopy, several imaging methods, such as transpapillary intraductal ultrasonography and computed tomography, may be applied to detect small lesions of the papilla and to provide a proper staging (36). However, criteria to differentiate primary from secondary ampullary tumours have not been developed for these techniques. Definitive diagnosis requires clinical data and standard biopsies: cyto-architectural appearance and immunohistochemical profile are analysed to exclude primary neoplasms or less common lesions, e.g., sarcomas, GISTs and malignant lymphomas (37). In the evaluation of primary ampullary tumours, the diagnostic accuracy of forceps biopsies is known to range from 47 to 95% (37). False negative results may result from submucosal localisation of the tumour, and it is expected that the diagnostic accuracy for secondary tumours is lower, as these usually do not originate for the mucosa, but affect the luminal surface in a secondary manner (37).

As the prognosis of patients with secondary ampullary tumours is poor and a surgical approach bears a considerable risk of postoperative morbidity and mortality surgical intervention should be planned carefully (38). Outcome data was available for 19 patients. Three patients (16%), including our own patient, remained free of cancer after surgery for more than 2.5 years (2.5, 4, 5 years, respectively) and one patient is alive with residual disease 6.5 years following resection (Table I). Notably, all four of them were patients with metastatic renal cell carcinoma.

Data regarding therapeutic strategies were available in 31 (97%) patients and one half of patients underwent a surgical procedure (n=16), including Whipple resection (n=10). A total of 15 (48%) patients received chemotherapy, either in addition to surgery or alone. Drainage and/or stenting were applied in 10 (31%) patients, in five patients combined with chemotherapy. For small lesions, endoscopic (or surgical) ampullectomy appears to be an alternative with reduced length of inpatient stay, lower morbidity and mortality (38). However, endoscopic

Table I. Secondary tumours of the ampulla of Vater- literature overview and case report.

Authors, year	No.	Sex	Age at diagnosis of metastasis	Macroscopy of ampullary lesion	Location of primary tumour	Diagnosis of primary tumour	Time interval between diagnosis of primary tumour and metastasis	Symptoms ^a	Additional metastases (at time of diagnosis of ampullary tumour)	Therapy ^b	Outcome	(Refs.)
England and Sarr, 1990	1	M	70	NS	Skin: posterior thorax	Malignant melanoma	3 years	1, 3, 4	Bone, liver	3, 4, 5	NS	(6)
Sans <i>et al</i> , 1996	2	M	51	1	Skin (NS)	Malignant melanoma	3 months	1, 3	Brain	2	Succumbed after 3 months	(7)
Meyers <i>et al</i> , 1998	3	M	56	1, 3	Skin: left upper back	Malignant melanoma	3 years	2, 3	Brain, skin	3	Succumbed after 4,5 months	(8)
Caballero-Mendoza <i>et al</i> , 1999	4	M	48	NS	Skin: back	Malignant melanoma	Synchronous	1, 3, 4	Lungs, stomach, mediastinum, liver, spleen	2, 4	Succumbed after 4 months	(9)
Le Borgne <i>et al</i> , 2000	5	F	62	3	Skin (NS)	Malignant melanoma	8 years	3	No	3, 4	No evidence of disease 12 months after resection	(10)
Le Borgne <i>et al</i> , 2000	6	F	33	3	Skin (NS)	Malignant melanoma	NS	3	NS	3	Survived 2 months after resection	(10)
van Bokhoven <i>et al</i> , 2006	7	F	66	1	Skin: left side of the trunk	Malignant melanoma (2 primary lesions)	3 years	1, 3	No	2	NS	(11)
Marks <i>et al</i> , 2010	8	F	66	1, 3	Skin: right forearm	Malignant melanoma	4 years	1, 3	Right superior eyelid, chest, gallbladder, abdomen, pelvis, superficial soft tissue	2, 4	Succumbed after 15 months	(12)
Uiterwaal <i>et al</i> , 2011	9	F	41	NS	Skin: left shoulder	Malignant melanoma	10 months	1	Brain	4, 5	Succumbed 8 months	(13)
Nakayama <i>et al</i> , 2011	10	F	81	1	Vagina	Malignant melanoma	Synchronous	2, 4	Liver, the primary lesion extended to the cervix of uterus and to the pelvis, behind the bladder	1	Succumbed after 1 month	(14)

Table I. Continued.

Authors, year	No.	Sex	Age at diagnosis of metastasis	Macroscopy of ampullary lesion	Location of primary tumour	Diagnosis of primary tumour	Time interval between diagnosis of primary tumour and metastasis	Symptoms ^a	Additional metastases (at time of diagnosis of ampullary tumour)	Therapy ^b	Outcome	(Refs.)
McKenna and Kozarek, 1989	11	M	52	1	Kidney (right)	Clear cell carcinoma	10 years	3, 4	Left kidney, right lower pulmonary lobe	2, 3	NS	(15)
Robertson and Gertler, 1990	12	M	70	1, 2, 3	Kidney (left)	Clear cell carcinoma	12 years	2, 4	No	3	NS	(16)
Venu <i>et al.</i> , 1991	13	M	64	1, 2	Kidney (left)	Clear cell carcinoma	11 years	2, 4	Bone	3, 4	Succumbed postoperatively due to massive pulmonary embolism	(17)
Bolkier <i>et al.</i> , 1991	14	F	55	1	Kidney (left)	Clear cell carcinoma	NS	3	Left breast, brain	2	Succumbed after 2 months	(18)
Leslie <i>et al.</i> , 1996	15	F	78	1, 3	Kidney (left)	Clear cell carcinoma	10 years	3, 4	No	3	No evidence of disease	(19)
Leslie <i>et al.</i> , 1996	16	M	53	1, 3	Kidney (right)	Clear cell carcinoma	8 years	2, 4	Mesenteric nodulation, retroperitoneal mass	3, 4	2.5 years after resection	(19)
Janzen <i>et al.</i> , 1998	17	M	75	1, 3	Kidney (left)	Clear cell carcinoma	17.5 years	2, 3	Spleen	3	NS	(20)
Mendoza <i>et al.</i> , 2001	18	M	49	1, 2, 3	Kidney (right)	Clear cell carcinoma	2.5 years	1, 2	No	3	Succumbed after 3 months	(21)
Hata <i>et al.</i> , 2013	19	F	50	1, 2, 3	Kidney (left)	Clear cell carcinoma	13 years	2	Bone, spleen	3	Alive with residual disease	(22)
-	20	M	57	1, 2, 3	Kidney (left)	Clear cell carcinoma	3.5 years	2	No	3	No evidence of disease	Present case
											1 year after resection	4 years after resection

Table I. Continued.

Authors, year	No.	Sex	Age at diagnosis of metastasis	Macroscopy of ampullary lesion	Location of primary tumour	Diagnosis of primary tumour	Time interval between diagnosis of primary tumour and metastasis	Symptoms ^a of ampullary tumour	Additional metastases (at time of diagnosis of ampullary tumour)	Therapy ^b	Outcome	(Refs.)
Haidong <i>et al</i> , 2014	21	M	50	NS	Kidney (right)	Clear cell carcinoma	Synchronous	3	No	3,4	No evidence of disease 5 years after resection	(32)
Titus <i>et al</i> , 1997	22	F	50	1, 3	Breast (left)	Invasive carcinoma of no special type	4 years	3	No	3, 4	alive after 4 months	(23)
Rego <i>et al</i> , 2009	23	F	66	NS	Breast (left)	Invasive carcinoma of no special type	2 years	4	No	4	NS	(24)
Rego <i>et al</i> , 2009	24	F	39	1	Breast (NS)	Invasive lobular carcinoma	NS	1	NS	3	NS	(24)
Bastos <i>et al</i> , 2014	25	F	63	1	Breast	Invasive lobular carcinoma	1.5 years	1,3	Lumbar spine	2	NS	(33)
Lee <i>et al</i> , 2005	26	F	50	1, 2	Uterine cervix	Squamous cell carcinoma	2 years	1	No	4	NS	(25)
Sreenarasimhaiah and Hoang, 2005	27	M	62	1	Oesophagus	Squamous cell carcinoma	Synchronous	NS	No	4, 5	NS	(26)
Buyukcelik <i>et al</i> , 2003	28	M	71	1, 2, 3	Larynx	Squamous cell carcinoma	5 years	1, 3	Right adrenal gland, multiple pulmonary nodules	2, 4	Succumbed after 1 year	(27)
Kamusella <i>et al</i> , 2007	29	M	41	1, 2	Lung (right superior lobe)	Adenocarcinoma	Synchronous	NS	No	2	NS	(28)
Silva <i>et al</i> , 1996	30	F	53	NS	Ovary and uterus	Endometrioid adenocarcinoma (both ovaries and endometrium)	5 years	1, 2, 3	NS	2, 4	No evidence of disease 9 months after resection	(29)
Green <i>et al</i> , 2008	31	M	54	1	Bladder	Urothelial carcinoma	3 years	1, 3	No	2, 4	NS	(30)
Kadokia <i>et al</i> , 1992	32	M	27	1, 2	Right femur	Osteosarcoma	4 years	1, 2, 4	NS	NS	NS	(31)

^a1, upper GI complaint (including nausea, vomiting and pain); 2, bleeding (including melena and anaemia); 3, jaundice and related symptoms (including pruritus, alterations in stool and urine); 4, general discomfort, weakness, weight loss and/or shortness of breath. ^b1, best supportive care; 2, drainage and/or stent; 3, surgery; 4, chemotherapy; 5, radiotherapy. F, female; M, male; DOD, dead of disease; NS, not specified. 1, polyp/mass; 2, ulcer; 3, pancreatic involvement

ampullectomy is considered a 'high-risk' procedure due to potential complications (39). These can be classified as early (pancreatitis, bleeding, perforation, and ampullectomy reported from large, tertiary care referral centres varies between 8 and 35% (39). So far, this technique has not been applied for secondary ampullary lesions, but it could be the best approach in cases presenting with mechanical cholestasis or even cholangitis and poor prognosis due to progress of the systemic malignant disease.

As seen in our case, ampullary metastases from renal cell cancer seem to behave differently both in terms of time intervals until the development of secondary tumours and overall prognosis. Similarly, in renal cell carcinoma metastatic to the stomach the mean time interval until the detection of a secondary tumour to the ampulla was around ten years (40). When complete resection of all metastatic lesions can be achieved patient show improved survival (41). Thus, Whipple resection with or without pylorus preservation which is the standard treatment for primary ampullary cancer may be also performed in these cases when all metastatic sites are amenable to wide resection (42,43).

In conclusion, secondary tumours of the ampulla of Vater are uncommon and malignant melanoma, renal and breast cancer are the most frequent primaries. Patients may present with jaundice or upper gastrointestinal bleeding. The time interval between the diagnosis of the primary tumour and the ampullary metastasis is highly variable and may be >10 years, particularly in patients with renal cancer. The management of metastatic ampullary lesions requires a multi-modal approach, including endoscopic, surgical, and oncological procedures.

References

- Horiguchi S and Kamisawa T: Major duodenal papilla and its normal anatomy. *Dig Surg* 27: 90-93, 2010.
- Adsay V, Ohike N, Tajiri T, Kim GE, Krasinskas A, Balci S, Bagci P, Basturk O, Bandyopadhyay S, Jang KT, et al: Ampullary region carcinomas: Definition and site specific classification with delineation of four clinicopathologically and prognostically distinct subsets in an analysis of 249 cases. *Am J Surg Pathol* 36: 1592-1608, 2012.
- Perysinakis I, Margaris I and Kouraklis G: Ampullary cancer--a separate clinical entity? *Histopathology* 64: 759-768, 2014.
- Albores-Saavedra JHR, Klimstra DS and Zamboni G: Invasive adenocarcinoma of the ampullary region 2. In: WHO Classification of Tumours of the Digestive System. Bosman F, Hruban RH and Theise ND (eds). IARC Press, Lyon, pp87-91, 2010.
- Wei SC, Su WC, Chang MC, Chang YT, Wang CY and Wong JM: Incidence, endoscopic morphology and distribution of metastatic lesions in the gastrointestinal tract. *J Gastroenterol Hepatol* 22: 827-831, 2007.
- England MD and Sarr MG: Metastatic melanoma: An unusual cause of obstructive jaundice. *Surgery* 107: 595-596, 1990.
- Sans M, Llach J, Bordas JM, Andreu V, Campo A, Castells A, Mondelo E, Terés J and Rodés J: Metastatic malignant melanoma of the papilla of Vater: An unusual case of obstructive cholestasis treated with biliary prostheses. *Endoscopy* 28: 791-792, 1996.
- Meyers MO, Frey DJ and Levine EA: Pancreaticoduodenectomy for melanoma metastatic to the duodenum: A case report and review of the literature. *Am Surg* 64: 1174-1176, 1998.
- Caballero-Mendoza E, Gallo-Reynoso S, Arista-Nasr J and Angeles-Angeles A: Obstructive jaundice as the first clinical manifestation of a metastatic malignant melanoma in the ampulla of vater. *J Clin Gastroenterol* 29: 188-189, 1999.
- Le Borgne J, Partensky C, Glemain P, Dupas B and de Kerviller B: Pancreaticoduodenectomy for metastatic ampullary and pancreatic tumors. *Hepatogastroenterology* 47: 540-544, 2000.
- van Bokhoven MM, Aarntzen EH and Tan AC: Metastatic melanoma of the common bile duct and ampulla of Vater. *Gastrointest Endosc* 63: 873-874, 2006.
- Marks JA, Rao AS, Loren D, Witkiewicz A, Mastrangelo MJ and Berger AC: Malignant melanoma presenting as obstructive jaundice secondary to metastasis to the Ampulla of Vater. *JOP* 11: 173-175, 2010.
- Uiterwaal MT, Mooi WJ and Van Weyenberg SJ: Metastatic melanoma of the ampulla of Vater. *Dig Liver Dis* 43: e8, 2011.
- Nakayama H, Miyazaki S, Kikuchi H, Saito N, Shimada H, Sakai S, Suzuki M and Kimura K: Malignant vaginal melanoma with metastases to the papilla of Vater in a dialysis patient: A case report. *Intern Med* 50: 345-349, 2011.
- McKenna JI and Kozarek RA: Metastatic hypernephroma to the ampulla of Vater: An unusual cause of malabsorption diagnosed at endoscopic sphincterotomy. *Am J Gastroenterol* 84: 81-83, 1989.
- Robertson GS and Gertler SL: Late presentation of metastatic renal cell carcinoma as a bleeding ampullary mass. *Gastrointest Endosc* 36: 304-306, 1990.
- Venu RP, Rolny P, Geenen JE, Hogan WJ, Komorowski RA and Ferstenberg R: Ampullary tumor caused by metastatic renal cell carcinoma. *Dig Dis Sci* 36: 376-378, 1991.
- Bolkier M, Ginesin Y, Moskovitz B, Munichor M and Levin DR: Obstructive jaundice caused by metastatic renal cell carcinoma. *Eur Urol* 19: 87-88, 1991.
- Leslie KA, Tsao JI, Rossi RL and Braasch JW: Metastatic renal cell carcinoma to ampulla of Vater: An unusual lesion amenable to surgical resection. *Surgery* 119: 349-351, 1996.
- Janzen RM, Ramj AS, Flint JD, Scudamore CH and Yoshida EM: Obscure gastrointestinal bleeding from an ampullary tumour in a patient with a remote history of renal cell carcinoma: A diagnostic conundrum. *Can J Gastroenterol* 12: 75-78, 1998.
- Mendoza JL, Lana R, Defarges V, Meroño E, Candía A and Loscos JM: Late metastasis of hypernephroma of the Vater's ampulla. *Rev Esp Enferm Dig* 93: 606-608, 2001.
- Hata T, Sakata N, Aoki T, Yoshida H, Kanno A, Fujishima F, Motoi F, Masamune A, Shimosegawa T and Unno M: Repeated pancreatotomy for metachronous duodenal and pancreatic metastases of renal cell carcinoma. *Case Rep Gastroenterol* 7: 442-448, 2013.
- Titus AS, Baron TH, Listinsky CM and Vickers SM: Solitary breast metastasis to the ampulla and distal common bile duct. *Am Surg* 63: 512-515, 1997.
- Rego RF, Atiq M, Velchala N, Nevin D, McElreath DP, McKnight WD and Aduli F: Ampullary metastasis from breast cancer: An unusual finding. *Endoscopy* 41 (Suppl 2): E278-E279, 2009.
- Lee TH, Park SH, Lee CK, Lee SH, Chung IK, Kim SJ and Kim SW: Ampulla of Vater metastasis from recurrent uterine cervix carcinoma presenting as groove pancreatitis. *Gastrointest Endosc* 73: 362-363, 2011.
- Sreenarasimhaiah J and Hoang MP: Esophageal squamous cell carcinoma with metastasis to the ampulla. *Gastrointest Endosc* 62: 310-311, discussion 311, 2005.
- Büyükcelik A, Ensari A, Sarioğlu M, İşikdoğan A and İçli F: Squamous cell carcinoma of the larynx metastasized to the ampulla of Vater. Report of a case. *Tumori* 89: 199-201, 2003.
- Kamusella P, Wissgott C and Steinkamp HJ: [Extrahepatic biliary obstruction caused by papillary metastasis of pulmonary adenocarcinoma]. *RoFo Fortschr Geb Rontgenstr Nuklearmed* 179: 1272-1273, 2007.
- Silva R, Paiva ME and Santos CC: Obstructive jaundice caused by ampullary metastases of an endometrioid adenocarcinoma. *Gastrointest Endosc* 44: 195-197, 1996.
- Green D, Rowsell C and Cohen L: Metastatic bladder carcinoma to ampulla of Vater. *Gastrointest Endosc* 68: 199-200, 2008.
- Kadokia SCPA, Parker A and Canales L: Metastatic tumors to the upper gastrointestinal tract: Endoscopic experience. *Am J Gastroenterol* 87: 1418-1423, 1992.
- Haidong W, Jianwei W, Guizhong L, Ning L, Feng H and Libo M: Ampullary tumor caused by metastatic renal cell carcinoma and literature review. *Urol J* 11: 1504-1507, 2014.
- Bastos T, Souza TF, Otoch JP, Grecco E, Avila F and Artifon EL: Metastasis of breast cancer to major duodenal papilla. *Rev Gastroenterol Peru* 34: 149-150, 2014.
- Buissin D, Sterle A, Schmiegelow P, Wassenberg D and Ambe PC: Primary anorectal malignant melanoma: a rare but aggressive tumor: report of a case. *World J Surg Oncol* 13: 12, 2015.
- Weigt J and Malfertheiner P: Metastatic Disease in the Stomach. *Gastrointest Tumors* 2: 61-64, 2015.

36. Ito K, Fujita N, Noda Y, Kobayashi G and Horaguchi J: Diagnosis of ampullary cancer. *Dig Surg* 27: 115-118, 2010.
37. Wiech T, Walch A and Werner M: Histopathological classification of nonneoplastic and neoplastic gastrointestinal submucosal lesions. *Endoscopy* 37: 630-634, 2005.
38. Ceppa EP, Burbridge RA, Rialon KL, Omotosho PA, Emick D, Jowell PS, Branch MS and Pappas TN: Endoscopic versus surgical ampullectomy: An algorithm to treat disease of the ampulla of Vater. *Ann Surg* 257: 315-322, 2013.
39. De Palma GD, Masone S, Rega M, Simeoli I, Donisi M, Addeo P, Iannone L, Pilone V and Persico G: Metastatic tumors to the stomach: Clinical and endoscopic features. *World J Gastroenterol* 12: 7326-7328, 2006.
40. Pollheimer MJ, Hinterleitner TA, Pollheimer VS, Schlemmer A and Langner C: Renal cell carcinoma metastatic to the stomach: Single-centre experience and literature review. *BJU Int* 102: 315-319, 2008.
41. Leibovich BCCJ, Chevillat JC, Lohse CM, Zincke H, Frank I, Kwon ED, Merchan JR and Blute ML: A scoring algorithm to predict survival for patients with metastatic clear cell renal cell carcinoma: A stratification tool for prospective clinical trials. *J Urol* 174: 1759-1763, discussion 1763, 2005.
42. Hornick JR, Johnston FM, Simon PO, Younkin M, Chamberlin M, Mitchem JB, Azar RR, Linehan DC, Strasberg SM, Edmundowicz SA, et al: A single-institution review of 157 patients presenting with benign and malignant tumors of the ampulla of Vater: Management and outcomes. *Surgery* 150: 169-176, 2011.
43. Klein F, Jacob D, Bahra M, Pelzer U, Puhl G, Krannich A, Andreou A, Gül S and Guckelberger O: Prognostic factors for long-term survival in patients with ampullary carcinoma: The results of a 15-year observation period after pancreaticoduodenectomy. *HPB Surg* 2014: 970234, 2014.



This work is licensed under a Creative Commons Attribution-NonCommercial-NoDerivatives 4.0 International (CC BY-NC-ND 4.0) License.