

Available online at www.sciencedirect.com

ScienceDirect

journal homepage: www.elsevier.com/locate/radcr

Case Report

Transarterial chemoembolization for hepatocellular carcinoma in Fontan surgery patient[☆]

Antonio Orlacchio, M.D.^{a,*}, Fulvio Gasparrini, M.D.^a, Ilaria Lenci, M.D.^b,
 Maria Giulia Gagliardi, M.D.^c, Marco Spada, M.D.^d, Manlio Guazzaroni, M.D.^a,
 Giorgio Ciccarese, M.D.^a, Mario Angelico, M.D.^b

^a Department of Diagnostic and Interventional Radiology, University Hospital Tor Vergata, Rome, Italy

^b Liver Unit, University Hospital Tor Vergata, Rome, Italy

^c Department of Cardiology, Division of Grow Up Congenital Heart, Bambino Gesù Children's Hospital IRCCS, Rome, Italy

^d Department of Abdominal Transplantation and Hepatobiliopancreatic Surgery, Bambino Gesù Children's Hospital IRCCS, Rome, Italy

ARTICLE INFO

Article history:

Received 18 August 2020

Revised 29 September 2020

Accepted 30 September 2020

Keywords:

Cardiac cirrhosis

Congenital heart disease

Fontan operation

Hepatocellular carcinoma

trans-arterial embolization

ABSTRACT

We describe the case of a 41-year-old woman who developed a liver neoplasm due to previous Fontan surgery for a single ventricle anomaly and pacemaker implantation. She was admitted to our hospital for moderate ascites and she was affected by hepatocellular carcinoma treated by trans-arterial chemoembolization (TACE). Computed tomography showed features of chronic liver disease and 4 cm hepatic nodules with arterial enhancement. Laboratory analyses documented preserved liver function and increased levels of alpha-fetoprotein. TACE was performed obtaining complete necrosis at 4 weeks of follow up and significant reduction of alpha-fetoprotein after 2 months. The patient is currently in follow-up, being evaluated for further treatments and/or combined liver/heart transplantation. TACE is a therapeutic option for the treatment of patients with unresectable HCC and with severe heart disease, like those submitted to FS.

© 2020 The Authors. Published by Elsevier Inc. on behalf of University of Washington.

This is an open access article under the CC BY-NC-ND license

(<http://creativecommons.org/licenses/by-nc-nd/4.0/>)

Abbreviations: US, ultrasound; HCC, hepatocellular carcinoma; ceCT, contrast enhanced Computed Tomography; PET-CT, positron emission tomography; 18F-FDG, 2-deoxy-2-[fluorine-18]fluoro- D-glucose; DSA, Digital Subtraction Angiography; TACE, Trans Arterial ChemoEmbolization.

[☆] Declaration of Competing Interest: Corresponding authors declare no conflict of interest for all 169 the other authors.

* Corresponding author.

E-mail address: aorlacchio@uniroma2.it (A. Orlacchio).

<https://doi.org/10.1016/j.radcr.2020.09.056>

1930-0433/© 2020 The Authors. Published by Elsevier Inc. on behalf of University of Washington. This is an open access article under the CC BY-NC-ND license (<http://creativecommons.org/licenses/by-nc-nd/4.0/>)

Introduction

The Fontan surgery allows blood from the systemic circulation to reach the pulmonary circulation through a direct connection between the inferior vena cava and the pulmonary arteries bypassing the right heart [1].

The operation has increased the survival of patients with single ventricle physiology, with 83% surviving to 20 years [2]. As a result, late complications of congenital heart disease are becoming clinically relevant in these adult patients. Liver disease is a recognized complication of the Fontan procedure for cyanotic congenital heart disease [2], primarily due to chronic venous congestion. The association of liver disease is a significant prognostic factor in these patients. Hepatocellular carcinoma (HCC) occurs generally late after the Fontan procedure (> 10 years) and it is associated with high mortality [3].

There are several difficulties in determining therapeutic strategies for HCC patients with congenital heart disease because of the poor general condition of the patient, complicated hemodynamics, and hepatic dysfunction [4,5]. Trans-arterial chemoembolization (TACE) is one of the first choice treatments for unresectable HCC. In literature we found only a small number of patients submitted to the Fontan surgery suitable for curative treatments for HCC.

We describe a case of HCC complicating Fontan surgery associated with liver disease treated with TACE as a bridge to combined heart/liver transplantation.

Case report

A 41-year-old woman with a previous history of Waterson systemic-pulmonary shunt at age 1 and Fontan surgery (total cavo-pulmonary connection; TCPC) for tricuspid atresia at the age of 4 year and Pace-Maker implantation was followed for atrial fibrillation and chronic heart failure NYHA class II up (Fig. 1). Thirty years after Fontan surgery, she had a diagnosis of liver cirrhosis, with moderate ascites, slight increase of total bilirubin (2 mg/dl) and of prothrombin time (international normalized ratio, INR, 1.36).

For this reason, the patient underwent repeated ultrasound exams of the liver, showing the presence of multiple hyperechoic nodules, the largest of which were 10 mm in size at the 8th segment and 20 mm at the level of the 7th hepatic segment, which increased in size during the follow up (Fig. 2). MELD score was 9, Child-Turcotte-Pugh stage was B8, for the presence of ascites.

Therefore, a dynamic contrast enhanced computed tomography was performed. A focal 48 mm lesion with blurred margins, characterized by tenuous contrast impregnation in the arterial phase, late wash-out with a peripheral hypertrophic arterial evidence, and a pseudocapsule appearance in the following phases was depicted (Fig. 3).

Due to a further increase of alpha-fetoprotein (AFP), raising up to 4.332 ng/mL (UI/mL) a positron emission tomography (PET) was performed, showing the presence in the VII hepatic

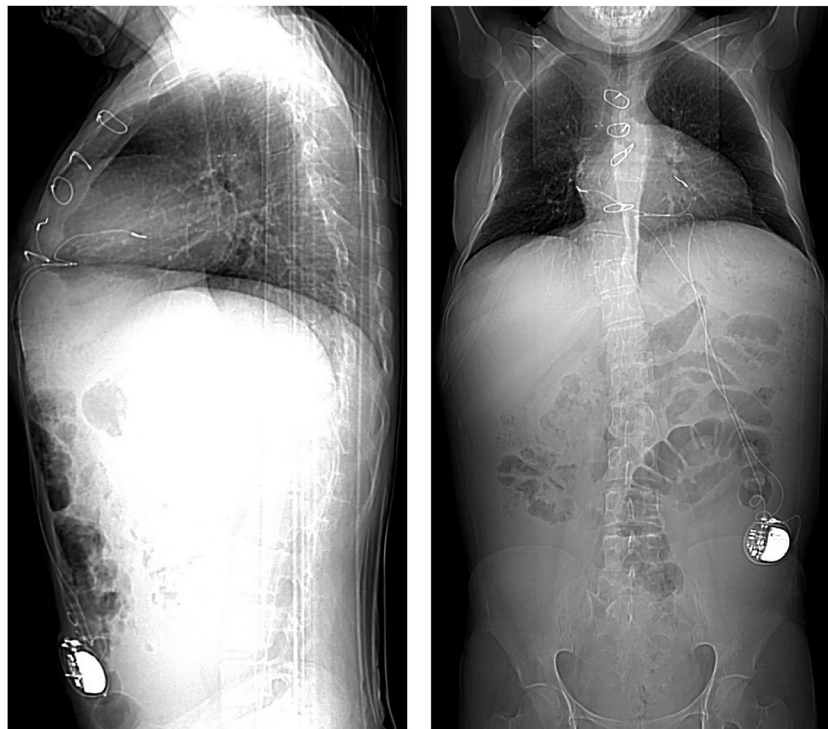


Fig. 1 – Normal chest sagittal and lateral digital scanogram views show the normal aspect of thoracic structures with a light enlargement of the heart and dual-chamber pacemaker with the generator in the subcutaneous left abdominal pouch. Metallic surgical sutures of previous sternotomy are also evident.

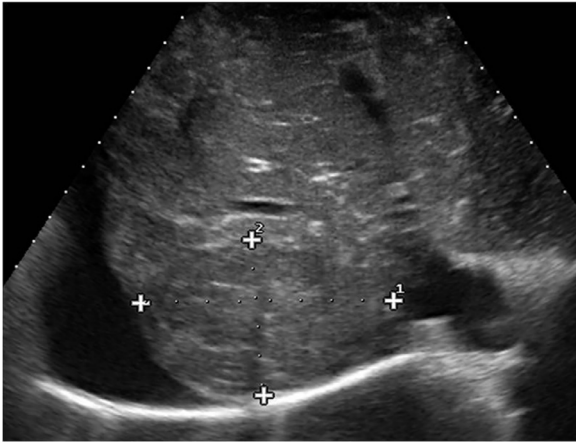


Fig. 2 – US scan depicts multiple hepatic nodules, the largest of which was at the level of the 7th segment (8.15 x 5.32 cm) compatible with HCC. Ascites was evident.

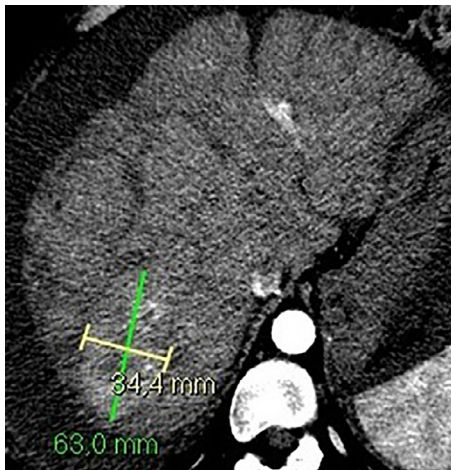

Fig. 3 – Axial ceCT scan in arterial phase shows enhanced lesion in VII liver segment (63 x 34.4 mm).

segment of a significant focal uptake of the ^{18}F -FDG related to hepatic tumor (Fig. 4).

Therefore, a multidisciplinary board decided to perform TACE as a palliative treatment to prevent tumor increase and to alleviate abdominal swelling.

Written informed consent was obtained from the patient; TACE was performed by experienced interventional radiologist.

During TACE, in interventional radiology suite, a team of cardiologists monitored the patient to prevent any risk of cardio-circulatory complications as arrhythmic and thromboembolic complications.

Digital subtraction angiography of the celiac trunk and hepatic artery showed multiple hypervascular masses in the right hepatic lobes (Fig. 5). The feeding artery of the target tumor at S7 was selected with a microcatheter; subsequently, subsegmental feeding arteries were embolized

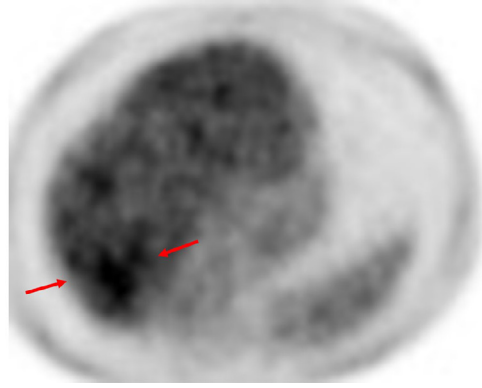


Fig. 4 – PET-CT scan shows ^{18}F -FDG uptake in the VII liver segment corresponding to the CT lesion.

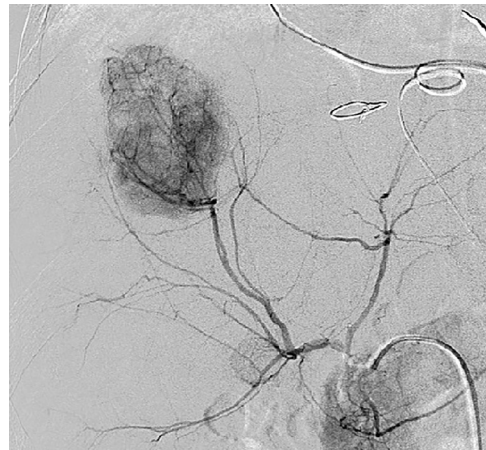


Fig. 5 – DSA of hepatic artery confirms the large hyper-vascular lesion in the liver.

using degradable starch microspheres (Embocepts 50 micron—Pharmacepts Germany), mixed with contrast medium (CM) (6 mL of iodinate CM—300 mgI/mL) and 50 mg of doxorubicin (Fig. 6). After TACE, there were no major complications such as unintended systemic embolization or hepatic failure. No postprocedural hemodynamic and cardio-circulatory complications occurred.

The patient reported slight upper abdominal pain and temperature for 10 days after TACE, which were considered symptoms due to post-embolization syndrome.

After TACE, the patient presented good general conditions, treatable abdomen not painful to superficial and deep palpation and dullness typical for ascites. Vital parameters were PA 110-60 mmHg, cardiac frequency 57 bpm, SPO2 96%, T 36°.

Follow-up dynamic contrast enhanced computed tomography at 4 weeks and 3 months after TACE showed complete response of the treated lesion (Fig. 7A,B), according to mRECIST criteria, absence of further suspect liver nodules and excluded the presence of secondary localizations.

Haematochemical tests showed microcytic anemia (HB 11.6 g/dl, Ht 37.9%, MCV 60.4 fl, MCH 18.5 pg), platelets (PLT 126.000/uL), increase in liver cytolysis, and cholestasis indices

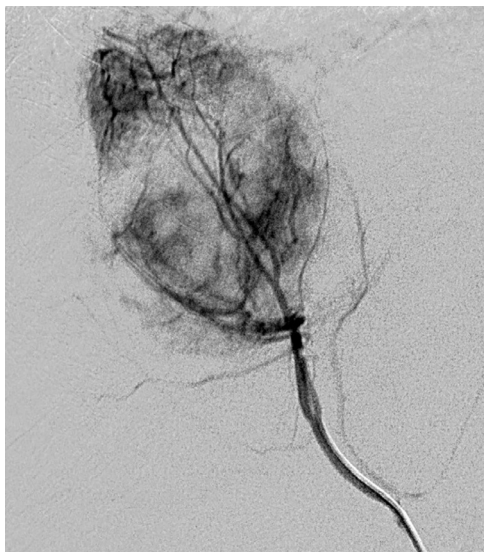

Fig. 6 – Pre-TACE selective DSA better depicts the feeding artery of the lesion.

(AST 52 IU/L, gGT 61 IU/L, total bilirubin 1.25 mg/dl, direct bilirubin 0.6 mg/dl), and alteration of coagulation function (PT 56%, INR 1.36). AFP dropped by initial value of 4332 IU/mL, to 445.58 IU/mL in the following 5 weeks and 8.01 IU/mL 3 months later, a value in the normal range.

Discussion

Fontan surgery has improved survival of patients with cardiac malformation but Liver disease strongly increases in these patients and this is an important negative prognostic factor for overall survival. The risk of liver disease for these patients begins after 10 years from FS (2). Liver disease related to Fontan surgery is a multifactorial process related to chronic venous congestion, reduced systemic cardiac output,

systemic hypoxia secondary to left ventricular dysfunction and diffuse pulmonary veno-venous shunts [6].

The American College of Cardiology has provided general recommendations for the management of Liver disease related to Fontan surgery [3]. The American College of Cardiology indicates ultrasonography (US) as a first diagnostic step to identify Liver disease in adults submitted to Fontan surgery. Tellez et al. [7] found that US had a much lower sensitivity in identifying liver nodules than magnetic resonance imaging (MRI), or computed tomography (CT). However, the diagnosis of liver disease and HCC is challenging, as the clinical presentation is extremely heterogeneous in this patient cohort. Abnormal hepatic blood flow may influence the typical arterial enhancing pattern of HCC on CT imaging [8], necessitating biopsy to confirm histologically the diagnosis. HCC development was a relatively rare event (1.3%), being associated with moderately increased AFP [5]. AFP had a central role in oncogenesis and growth of liver cancer [9].

In patients with HCC the post-treatment AFP reduction has a better prognosis of those without AFP response. [10]

In our case, the patient had very high AFP value (4.332 U/mL). AFP decreased to 445.58 IU/mL in the following 5 weeks and 8.01 IU/mL 3 months later after the treatment of the tumor with TACE.

Retrospective studies reported an annual risk of HCC in patients submitted to Fontan surgery and liver disease ranging from 1.5% to 5%. [11] We suppose that the actual risk of HCC may be underestimated, because the study is based on small series and with limited follow-up. The development of HCC is strictly time-dependent, with an increased risk every 10 years after Fontan surgery. This appears to be clinically relevant given that survivors after Fontan surgery may reach their forties and fifties [7].

It is particularly difficult to select the treatment strategy for HCC resulting from cardiac cirrhosis with congenital heart disease because these patients are in poor general health, with hepatic dysfunction and complicated hemodynamics. According to the Barcelona Clinic Liver Cancer staging classification, [12] nonsurgical therapeutic options for HCC include TACE and hepatic artery infusion chemotherapy; percutaneous ablation (radiofrequency ablation or ethanol injection); and use

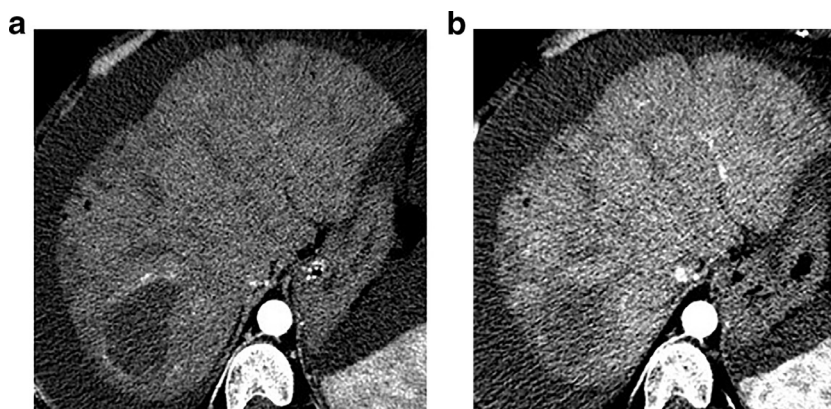


Fig. 7 a,b – Post TACE axial ceCT scan in arterial phase A. after 1 month shows complete absence of enhancing of the liver lesion; B. confirmed on CT scan after 3 months from TACE.

of drugs with molecular targets, such as sorafenib. TACE and sorafenib are usually selected as the first choice of treatment for multiple (≥ 4) unresectable HCC in adult patients. In patients with cirrhosis, hepatic resection for HCC is recommended if the MELD score is ≤ 8 . [12] In patients with MELD score ≥ 9 , other treatment modalities should be considered.

In the present case, MELD score was 9, while the Child-Turcotte-Pugh stage was B8, for the presence of ascites. TACE was performed after careful discussion in a multidisciplinary team and with the patient. No major complications were correlate with TACE.

The development of HCC after Fontan surgery is a rare event, with the first case series published in 2013 [4]. There are few cases reported in literature, with only a small number of patients suitable for curable treatment for HCC. The lack of comprehensive screening guidelines for HCC in patients with liver disease related to Fontan surgery is likely to have contributed to patients presenting at an advanced stage.

Conclusion

With recent advances in pediatric surgery and cardiology, >80% of patients with congenital heart disease now survive to adulthood increasing the incidence of cardiac cirrhosis and HCC. TACE offers in these patients a therapeutic option for unresectable HCC to improve survival and to bridge to liver/heart transplantation.

Patient consent statement

Informed consent was obtained for experimentation with human subjects.

Declaration of Competing Interest

Corresponding authors declare no conflict of interest for all the other authors.

REFERENCES

- [1] Asrani SK, Asrani NS, Freese DK, Phillips SD, Warnes CA, Heimbach J, et al. Congenital heart disease and the liver. *Hepatology* 2012;56:1160–9. doi:10.1002/hep.25692.
- [2] Baek JS, Bae EJ, Ko JS, Kim GB, Kwon BS, Lee SY, et al. Late hepatic complications after Fontan operation; non-invasive markers of hepatic fibrosis and risk factors. *Heart* 2010;96:1750–5. doi:10.1136/hrt.2010.201772.
- [3] Mazzaelli MDCannon, Hudson M, Heaton N, Sarker D, Kane P, et al. Hepatocellular Carcinoma as a complication of vascular disease of the liver after Fontan procedure. *Hepatology* 2019;69(2):911–13. doi:10.1016/j.ijscr.2019.05.029.
- [4] Daniels CJ, Bradley EA, Landzberg MJ, Aboulhosn J, Beekman RH, Book W, et al. Fontan-Associated Liver Disease: Proceedings from the American College of Cardiology Stakeholders Meeting, October 1 to 2, 2015. Washington DC: Journal of the American College of Cardiology; 2017. doi:10.1016/j.jacc.2017.10.045.
- [5] Asrani SK, Warnes CA, Kamath PS. Hepatocellular carcinoma after the Fontan procedure. *N Engl J Med* 2013;368:1756–7. doi:10.1056/NEJMc1214222.
- [6] Wong FS. *The liver in heart failure. Handbook of Liver Disease 2018 eBook ISBN: 9780323478809.*
- [7] Téllez L, Rodríguez de Santiago E, Minguez B, Payance A, Clemente A, Baiges A, et al. Prevalence, features and predictive factors of liver nodules in Fontan surgery patients: The VALDIG Fonliver prospective cohort. *J Hepatol* 2020;72:702–10. doi:10.1016/j.jhep.2019.10.027.
- [8] Kim TH, Yang HK, Jang HJ, Yoo SJ, Khalili K, Kim TK. *Abdominal imaging findings in adult patients with Fontan circulation. Insights into Imaging* 2018;9:357–67.
- [9] Mizejewski GJ. Nonsecreted cytoplasmic alpha-fetoprotein: a newly discovered role in intracellular signaling and regulation. An update and commentary. *Tumor Biol.* 2015;36:9857–64. doi:10.1007/s13277-015-3736-0.
- [10] He C, Peng W, Liu X, Li C, Li X, Wen TF. Post-treatment alpha-fetoprotein response predicts prognosis of patients with hepatocellular carcinoma: A meta-analysis. *Medicine (Baltimore)* 2019;98:e16557. doi:10.1097/MD.00000000000016557.
- [11] Nandwana SB, Olaiya B, Cox K, Sahu A, Mittal P. Abdominal Imaging Surveillance in Adult Patients After Fontan Procedure: Risk of Chronic Liver Disease and Hepatocellular Carcinoma. *Curr Probl Diagn Radiol* 2018;47:19–22. doi:10.1067/j.cpradiol.2017.04.002.
- [12] Llovet JM, Brú C, Bruix J. Prognosis of hepatocellular carcinoma: The BCLC staging classification. *Semin Liver Dis* 1999;19:329–38. doi:10.1055/s-2007-1007122.