

Cataract in retinopathy of prematurity – A review

Sudarshan Khokhar^{1,3}, Abhidnya Surve^{1,2,3}, Saurabh Verma^{1,2,3}, Shorya Azad^{2,3}, Parijat Chandra^{2,3}, Chirakshi Dhull^{1,2,3}, Rajpal Vohra^{2,3}

Preterm babies with retinopathy of prematurity (ROP) can become blind if they do not receive appropriate timely intervention. The presence of cataract in these individuals in addition to visual deprivation amblyopia, also delays proper screening, adequate treatment, and makes follow-up assessment difficult. Anatomical differences in these infants and amblyopia management, especially in unilateral cataract, are other important concerns, and hence, management of these cases with cataract and ROP is challenging. In this review, studies where ROP cases were associated with cataract, were evaluated with a focus on preterm individuals less than 6 months age. Preterm babies are at increased risk of developing cataract because of systemic factors. In addition, those with ROP may have cataract associated with retinal detachment or treatment received. The type of cataract, risk factors, and pathophysiology associated with each cause varies. This review highlights these different aspects of cataract in ROP including causes, pathophysiology, types of cataracts, and management. The management of these cases is critical in terms of the timing of cataract surgery and the challenges associated with surgery and posterior segment management for ROP. Anatomical differences, preoperative retina status, pupillary dilatation, neovascularization of iris in aggressive posterior ROP, fundus examination, amblyopia, and follow-up are various important aspects in the management of the same. The preoperative workup, intraoperative challenges, postoperative care, and rehabilitation in these individuals are discussed.

Key words: Cataract, causes, complications, intraoperative challenges, retinopathy of prematurity, surgery

A cataract is defined as any opacity in the lens and has a prevalence of 1.2–6 cases per 10,000 infants.^[1] The normal development of a fetus occurs up to 40 weeks gestational age (GA). In India, babies born before 34 weeks GA, having birth weight (BW) less than 2,000 g and those >34 weeks GA or >2,000 g BW with high-risk factors are at risk for retinopathy of prematurity (ROP) and need to be screened.^[2] The incidence of ROP in these preterm babies has increased due to an increased survival rate of preterm and poor health care regulations regarding neonatal care and screening guidelines. These preterm low BW babies are also at risk to have cataract and an incidence of 0.97–1.9% is seen.^[3,4] These lenticular opacities can lead to difficulty in assessment of the posterior segment status and management of same. Herein, we review the characteristics of cataract in ROP babies and the management of these cases.

Methods

A literature search including Medline, PubMed, and Scopus was performed using the keywords “cataract,” “cataract surgery,” “preterm babies,” and “retinopathy of prematurity” using “and/or.” All longitudinal studies retrospective, prospective, and case reports published before May 2021

where cataract developed in ROP and cataract surgery was performed were evaluated. Cited studies not identified through these sources were identified by reviewing the reference list in individual articles. Studies that did not have ROP cases were excluded. Herein, we have primarily discussed the morphology and causes of cataract in young preterm babies with ROP, their effect on the evaluation of ROP screening, and how to manage such cases to allow a child to have good visual acuity. Further, an additional literature search was made on “Pediatric cataract surgery in individuals less than 6 months” for guiding the operative and postoperative management in these young preterm babies.

Morphology of Cataracts

Different morphologies of cataract [Fig. 1a-d] seen in babies with ROP [Table 1] include focal, zonular, total, anterior subcapsular, or posterior subcapsular opacities.^[3,5-9] Focal opacities, either punctate or vacuolated, are seen in approximately 2.7% of low BW infants, while total or posterior subcapsular opacities are usually associated with retinal detachment (RD).^[10,11]

¹Cataract and Refractive Service, ²Vitreoretinal, Uvea and ROP Service, ³Dr. Rajendra Prasad Center for Ophthalmic Sciences, All India Institute of Medical Sciences, Ansari Nagar, New Delhi, India

Correspondence to: Dr. Abhidnya Surve, Vitreo-Retinal, Trauma and Uvea Services, Dr. Rajendra Prasad Centre for Ophthalmic Sciences, All India Institute of Medical Sciences, Ansari Nagar, New Delhi - 110 029, India. E-mail: abhidnyasurve@gmail.com

Received: 22-Jan-2021

Revision: 04-Apr-2021

Accepted: 10-Oct-2021

Published: 27-Jan-2022

Access this article online

Website:

www.ijo.in

DOI:

10.4103/ijo.IJO_125_21

Quick Response Code:



This is an open access journal, and articles are distributed under the terms of the Creative Commons Attribution-NonCommercial-ShareAlike 4.0 License, which allows others to remix, tweak, and build upon the work non-commercially, as long as appropriate credit is given and the new creations are licensed under the identical terms.

For reprints contact: WKHLRPMedknow_reprints@wolterskluwer.com

Cite this article as: Khokhar S, Surve A, Verma S, Azad S, Chandra P, Dhull C, et al. Cataract in retinopathy of prematurity – A review. Indian J Ophthalmol 2022;70:369-77.

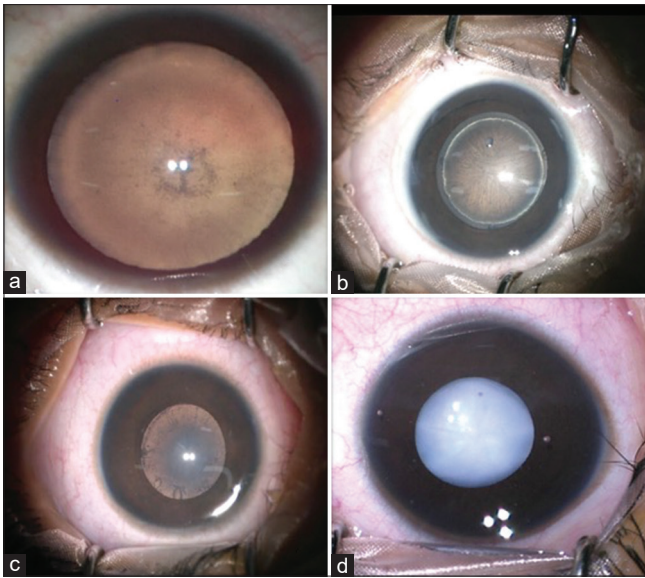


Figure 1: Anterior segment images showing different morphology of cataracts in babies with retinopathy of prematurity. (a) Focal punctate opacities, (b) Zonular cataract, (c) Posterior subcapsular cataract, (d) Total cataract

Etiology and Pathophysiology

Infantile cataract can develop due to various reasons including intrauterine infection, drug/drug metabolite-related deposition, metabolic disorders, and inherited disorders. Many of these cases are bilateral but asymmetrical presentation is common.^[1,12] Premature babies are further at more risk because of various factors. Cataract formation is seen at different durations ranging from 10 days to 13 months in laser-treated and 2 months to 5.6 years in post-vitreotomized eyes.^[3,4,13-15] Pathophysiology of cataract in cases with ROP may be related to different etiology as discussed below:

1. Systemic factors

Preterm babies are at risk of metabolic acidosis and sepsis during their treatment phase. These can lead to osmotic changes in the lens causing cataract formation. The usual form seen in these cases is the bilateral clear vacuoles formation along the apices of the posterior lens surface. These opacities are transient, visually insignificant, and mostly clear over several months but can progress to total opacification in some.^[1,4,10,11]

2. Complicated cataract

A complicated cataract is seen in those associated with RD, mostly in cases with advanced stage retinopathy.^[16] It may present as a posterior subcapsular cataract with polychromatic luster or partially absorbed membranous cataract.

3. Post-treatment

Various management options in ROP include cryotherapy, laser therapy, intravitreal anti-vascular endothelial growth factor (VEGF), and pars plana vitrectomy (PPV). Association of cataract development with treatment modality is variable in literature and needs to be studied.

a. Cryotherapy: Though previously used as a treatment of choice for threshold ROP, it is known to cause more inflammation in comparison to laser because of the

blood-retinal barrier breakdown. Still, cataract was not seen as a major complication in various studies.^[17,18] In the CRYO-ROP study, cataract surgery was performed in only 2% of the cases with equal distribution in treated and nontreated cases.^[19] This may be related to a broad area treated at a single moment and the short duration of inflammation associated with it.

b. Laser: Laser is preferred over cryotherapy because of lesser complications of pain, adnexal edema, exudative RD, vitreoretinal traction, and vitreous hemorrhage. The type of laser used in the treatment of ROP includes argon, diode, and df-NdYAG laser. The incidence of cataract in laser-treated ROP is variable ranging from 0.003 to 6%.^[4,15,20-23] Among them, argon laser had the highest rate of secondary cataract development.^[15,24] Prominent anterior vasculosa lentis, inadvertent burns placed on the iris or ciliary body, and confluent laser therapy are the proposed risk factors for cataract formation post-laser. The following mechanisms may play a role:

- *Thermal injury:* The total amount of laser energy used depends on the type, power, duration of laser, and the number of laser spots. Lens protein and hemoglobin absorb the energy of the laser. This prominently occurs in the case of persistent tunica vasculosa lentis (TVL), commonly present in preterm babies.^[20] As longer wavelength energy (810 nm) is less absorbed by hemoglobin, the incidence of cataract was found lower with diode laser energy.^[25] But Davitt *et al.*^[4] found no correlation between cataract and energy of the laser used.
- *TVL:* Premature infants have some amount of intact TVL. The hemoglobin absorbs laser energy at the lens surface leading to alteration in the permeability of the lens anterior capsule. This further affects the osmotic balance and leads to the formation of a cataract. In a very premature child, aggressive posterior ROP (APROP) represents an aggressive form of the disease with iris neovascularization, poor pupillary dilatation, hazy vitreous, a large area of avascular retina, and severe plus disease. These cases require higher power, duration, and more laser leading to higher cumulative energy being used further increasing the risk. But studies have also shown a similar incidence of cataract in ROP cases not having prominent TVL indicating other factors also do play a role.^[20,21]
- *Anterior segment ischemia:* The anterior segment of the eye is supplied by the anastomosis of the anterior ciliary artery (ACA) and long posterior ciliary artery (LPCA). Damage to the LPCA can lead to anterior segment ischemia.^[26] It can present as congestion, corneal edema, shallow anterior chamber (AC), hyphema, cataract, posterior synechiae in the acute phase, and hypotony, iris atrophy, ciliary body atrophy in the late phase. Some of these eyes can progress to phthisis bulbi.^[26,27]
- *Uveal effusion:* The higher amount of thermal energy and immature blood-retinal barrier puts the baby at a higher risk of uveal effusion. It can lead to anterior rotation of the ciliary body and shallow AC which may cause corneo-lenticular apposition and cataract formation.^[25] Thus, the use of a df-NdYAG laser with appropriate technique, lower cumulative energy, and avoidance of high indentation may help further decrease the chances of cataract formation.

Table 1: Studies on cataract surgery in retinopathy of prematurity babies

Author	Journal, Year	No. of Eyes	Previous Retinal Treatment (eyes)	Gestational Age (wks)	Birth Weight (g)	Age at surgery (Mean)	Follow-up PCIO/L (mean)	Type of Cataract Complications (eyes)	Intraoperative Complications (eyes)	Postoperative Complications (eyes)	Vision
Krollicki TJ et al. ^[6]	JAMA Ophthalmology, 1995	14 eyes (Regressed ROP)	Retinal surgery-4 Cryotherapy-2	-	-	16-43 y (34.9 y)	4-269 m	N-9 PCR - 2 PSC-4 ASC-1	VAO-6 Glaucoma-5 Retinal detachment - 1	VAO-6 Glaucoma-5 Retinal detachment - 1	BCVA >20/200-5
Farr et al. ^[97]	Am J Ophthalmol, 2001	20 eyes	Retinal surgery-2 Cryotherapy-1	-	-	17-73 y (44.6 y)	6-103 m (32 m)	- Zonular weakness-2	Zonular weakness-2	Retinal detachment-1 Glaucoma - 8 eyes	BCVA >20/200-13
Yu et al. ^[5]	J Cataract Refract Surg, 2004	8 eyes - ROP (stages 1-2 Stage 2-2 Stages 3-4)	Cryotherapy-3	26-36 (30)	800-2500 (1439)	0.2-5.5 y (1.5 y)	0.5-3.1 y (1.4 y)	T-4 N-4	Pupillary membrane-1 Esotropia-1	Pupillary membrane-1 Esotropia-1	Central steady reflex-5 Not centered reflex-1 BCVA >20/200-4 BCVA >20/200-39 BCVA <4/200-13
Kaiser et al. ^[97]	Am J Ophthalmol, 2008	66 eyes (18%-No peripheral changes 38%-stage 1 15%-stage 2 21%-stage 3 8%-stage 4)	-	24-30 (27)	679-1698 (1018)	7-66 y (40.31 y)	1 m- 38.1 y (12 y)	-	Retinal tear or retinal detachment - 15	Retinal tear or retinal detachment - 15	Retinal tear or retinal detachment - 15
Ezisi et al. ^[3]	Br J Ophthalmol, 2017	28 eyes (stages 4-13)	Retinal surgery-20 Laser-3	-	-	0.2 m- 12 y (18.9 m)	1-132 m (2 y)	T-12 Z-5 N-4 PSC-5 ASC-1	PCR-2	VAO-4 Secondary glaucoma-2 IOL capture-1	BCVA >20/200-11 Myopic shift 2 y (pseudophakic-3.07 D; aphakic-8.75 D)
Nguyen et al. ^[78]	Open J of Ophth, 2017	19 eyes	Laser-13 Retinal surgery-5 Intravitreal injection-1	24.8	747+233	Mean-6.7 y	1.5-16.8 y (10.1 y)	-	PCR-3 Pupillary miosis-3 Anterior capsular fibrosis-3 Posterior synechiae-3	VAO-10 Pupillary membrane-1 Acute angle-closure glaucoma-1 Band-shaped keratopathy-3 Optic atrophy-6 Nystagmus-6 Strabismus-7	BCVA >20/200-11
Quan et al. ^[27]	Retina cases & brief report, 2015	3 eyes (stages 3-2, stages 4-1)	Diode laser-3	22-26	-	-	11-13 y	T-3	Anterior segment ischemia, cataract, phthisis bulbi	Anterior segment ischemia, cataract, phthisis bulbi	No PL to PL positive Refraction -5 to -17.5 BCVA >20/200-1
Vanathi et al. ^[7]	J Pediatr Ophthalmol Strabismus, 2019	3 eyes (stage 3-3)	Intravitreal anti-VEGF-3	28-30	980-1040	9m-2 y (14 m)	3-6 m	Z-1 PSC-2	Peripheral dehiscence of posterior capsule-1	Peripheral dehiscence of posterior capsule-1	BCVA >20/200-1
Chandra et al. ^[9]	Indian pediatrics, 2016	2 eyes (APROP)	Laser-2	26	1200	36 wks	40 wks	T-2	-	-	Mild vitreous hemorrhage
Khokhar et al. ^[9]	J Pediatr Ophthalmol Strabismus, 2019	2 eyes (APROP)	Intravitreal bevacizumab	28	1050	35 wks	-	T-2	-	-	-

wks: weeks; m: months; y: years; g: grams; VEGF: vascular endothelial growth factor; PCIO/L: posterior capsular intraocular lens; T-Total; N-nuclear; Z-Zonular; PSC-posterior subcapsular; ASC: Anterior subcapsular; VAO: visual axis opacification; PCR: Posterior capsular rupture; BCVA: Best-corrected visual acuity; PL: perception of light; retinal surgery includes pars plana vitrectomy and/or scleral buckle.

c. *Post-injection*: VEGF is an important molecule involved in the cascade of events in ROP involved in both the angiogenesis and vasculogenesis phases. The use of intravitreal anti-VEGF in ROP allows for fast disease regression, improved vascular re-growth, and a better field of vision along with a high risk of recurrence.^[23,28,29] In adults, cataract incidence varies from 0 to 0.14% in cases receiving intravitreal anti-VEGF.^[30,31] It most commonly occurs due to mechanical lens injury. In preterm babies, the lens is thicker as compared to other ocular structures and the pars plana are also not formed.^[32,33] Hence, if one is not familiar with the anatomy of these small eyes, there is a higher chance of mechanical lens injury. The injection in these children is usually given at 1.75 mm from the limbus with the needle tip directed posteriorly toward the optic disc. Also, the sclera in children is more deformable than adults and localized deformation at the injection site can potentially lead to zonular tension and damage to the posterior capsule.

Pre-existing dehiscence of the posterior capsule has also been suspected.^[9] There have also been reports of cataract formation in post-intravitreal anti-VEGF with no lens injury documented, which could probably be related to the molecule itself. VEGF receptors are expressed in the lens and VEGF has a well-established role in the development of TVL and persistence of hyaloid vasculature, both of which have an important role in the development of the lens.^[34-36] In a mice-based model, Garcia *et al.*^[36] demonstrated that deletion of VEGF-A expression resulted in smaller lenses with many having mild nuclear opacities. The avascular retina in ROP leads to increased expression of hypoxia-inducible factor (HIF) which in addition to driving VEGF production, also promotes accumulation of VEGF-A transcripts in epithelial and fiber cells of lens. Interruption of this said mechanism by anti-VEGFs can also be one of the culprits in causing lenticular opacities.

A proper technique with the care of the site of injection, the direction of the needle, and type of needle is important to avoid mechanical lens injury. SAFER-ROP protocol has given updated protocol for safer anti-VEGF injection in ROP children.^[37]

d. *Post-surgery*: Cataract formation after lens-sparing vitrectomy for ROP surgery can occur but is less frequent as compared to PPV in adults. Different studies have shown cataract formation in 5.6–19% of the cases after lens-sparing vitrectomy.^[13,13,14] As described above, anatomical differences and lens retina approximation are some of the risk factors for lens touch. Chemical changes also are known to occur with vitrectomy itself and depending on the tamponade agent used. The ascorbic acid concentration in the vitreous is several times that of plasma and is suggested to have a major role as an antioxidant.^[38] Decreased levels of the said antioxidants in vitreous post-PPV can lead to increased oxidative damage to the lens, thus, contributing to cataract formation.

4. Steroid-induced cataracts: Though long-term steroids are known to cause cataracts, there are no reports of steroid-induced cataracts in preterm babies.

Management

The treatment of ROP is important and is a priority as timely intervention in these cases can prevent adverse outcomes. Obscuration of posterior segment visualization by cataract can preclude the screening and management of these cases. Hence, the need to manage cataract as soon as possible is essential to allow intervention for the posterior segment, monitor the disease, and prevent amblyopia. In cases where the retina is hazily seen, showing the early stage of ROP but is at risk of progression and laser could not be performed, intravitreal anti-VEGF can be given till the cataract surgery is done. Stage 4/5 ROP associated with cataract or where retina is near the posterior capsule, combined lensectomy and vitrectomy is required to achieve optimal results.

Preoperative challenges

Pediatric cataract surgery is challenging in terms of a smaller eye with lesser scleral rigidity, higher elasticity of the anterior capsule, and steeper anterior curvature of the lens. The anterior

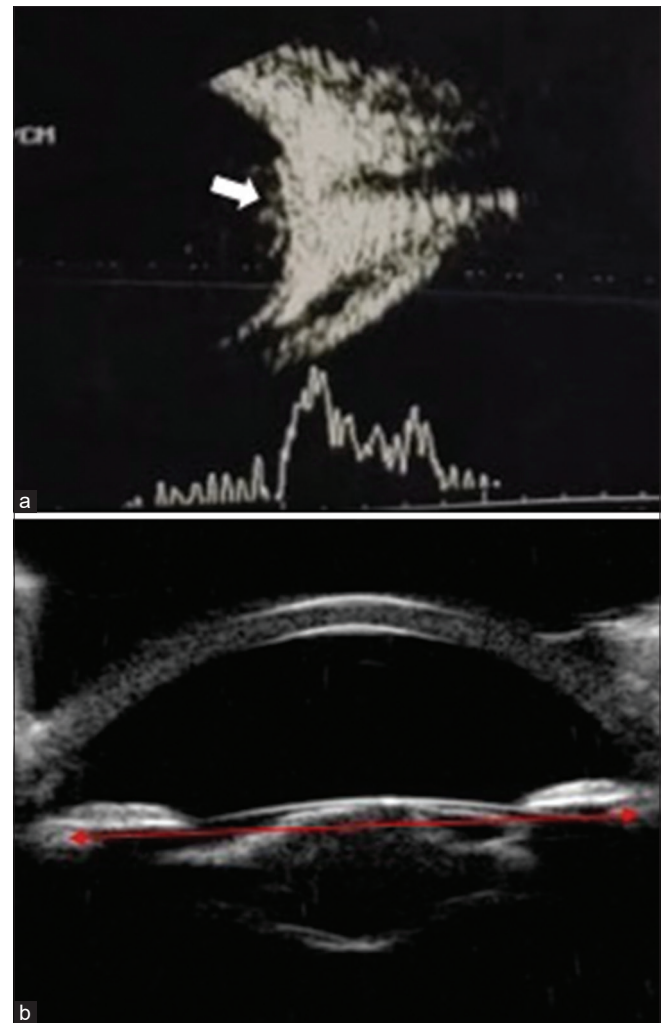


Figure 2: Combined vector scan ultrasonography imaging (a) showing tractional membranes at the posterior pole (white arrow) in a 34-week-old child with retinopathy of prematurity (ROP). Ultrasound biomicroscopy of the anterior segment (b) in a case of ROP with cataract showing intact posterior capsule and sulcus to sulcus diameter (red line)

segment in a preterm child is further different in terms of steeper cornea, shallow AC, more anteriorly inserted iris with a thicker and more spherical lens.^[33,39] Further, these parameters may vary with spontaneously regressed or laser-treated ROP. These differences not only pose intraoperative challenges but also affect the pattern of ocular growth.^[5,33,40-43] This has a significant effect on the selection of appropriate intraocular lens (IOL) power and the amount of undercorrection required.

Preoperative B-scan imaging is important to rule out the possibility of RD in cases where the posterior segment is not visible [Fig. 2a]. Preoperative ultrasound biomicroscopy (UBM) can help us to determine the area of the posterior synechiae, whether the posterior iris has adhered to the anterior capsule, the status of the posterior capsule for the presence of any pre-existing defects, and the sulcus to sulcus (STS) diameter [Fig. 2b].^[12,44] The preoperative detection of pre-existing defects can help one to anticipate complications and take necessary steps to prevent them. However, in these younger preterm babies, performing UBM is limited by child cooperation, and hence, should be performed before surgery under anesthesia to allow for appropriate assessment.

Poor pupillary dilatation can create problems during surgery. Tropicamide (0.5%) and phenylephrine (2.5%) combination is used for dilatation in these preterm babies. As used for ROP screening, the drops should be instilled two times 10 minutes apart half an hour before the surgery. In cases with APROP, neovascularization of the iris is often present. This causes non-dilatation of the pupil, difficulty in the visualization of the lens status and posterior segment with the risk of intraoperative bleeding. In these cases, with severe neovascularization, in the absence of RD, intravitreal anti-VEGF before cataract surgery may help in the regression of neovascularization. This decreases the risk of bleeding and allows dilatation of the pupil. All the factors including posterior segment status, treatment required, amblyopia therapy, prognosis, need for postoperative care, refractive correction, and the complications associated should be explained to the parents/caregivers.

Intraoperative challenges

Approach and dilatation: The preferable approach in preterm babies is superior corneal incision as with other pediatric cases. The superior wound is covered with the upper eyelid, and hence, is at a lesser risk of trauma and exposure, thereby, decreasing the risk of infection. Pupillary miosis and posterior synechiae can be present, especially in advanced ROP or APROP. The use of high-density visco-cohesive is preferred to maintain the AC and have minimum fluctuations in AC depth. The synechiae could be initially released to assess pupillary dilatation. In cases with non-dilating pupils, various maneuvers like mechanical stretching, sphincterotomy, and use of mechanical devices like iris hooks can be tried. The use of other mechanical devices like the Malyugin ring in such small eyes is not preferable due to the lesser space for maneuvering these devices.

Anterior continuous capsulorhexis (ACC) and lens aspiration: The anterior capsule can be stained using 0.06% trypan blue dye to visualize it. Trypan blue dye is known to have biochemical effects on the lens capsule, decreasing its elasticity.^[45,46] The ACC can be started with the capsulotomy 26-Gauge needle and further performed using capsulorhexis forceps. The forceps allow for controlled maneuvering of the elastic capsule.^[47] But

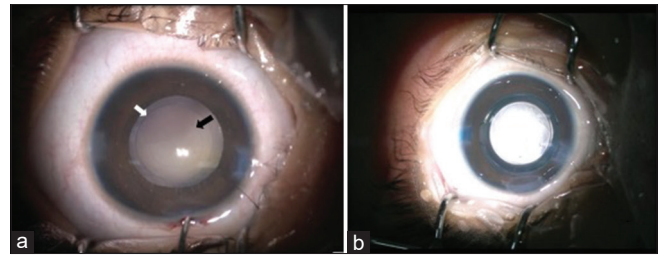


Figure 3: Intraoperative anterior segment images showing anterior (a—white arrow) and posterior capsulorhexis (a—black arrow) and intraocular lens in the bag (b)

before starting, the AC should be formed with a high-density visco-cohesive substance to avoid AC depth fluctuation and flatten the anterior capsule. The appropriate size of the ACC is approximately 4.5–5 mm.^[48] The use of a Callisto-guided marking system can help in this aspect. Multiple quadrant hydrodissection can be performed in cases where the posterior capsular defect is not suspected. This facilitates easy cortex removal with lesser fluid volume needed.^[48,49] The lens aspiration can be performed using the bimanual technique which allows complete removal of the lens matter without undue stress on the bag. Any residual lens matter could lead to excess inflammation in these pediatric cases, and hence, should be avoided.

Posterior continuous capsulorhexis (PCC), vitrectomy, and fundus examination: PCC can be made after partially filling the posterior chamber with high-density visco-cohesive. Complete fill should be avoided as this may lead to an increase bowing of the posterior capsule causing increasing angulation of the instrument leading to difficult maneuvering. Also, there is an increase in pressure on the posterior capsule, especially at the posterior-most point, creating a high risk of irregular extension. The PCC is performed with capsulorhexis forceps after initiation with a capsulotomy needle and should ideally be 3.5–4 mm approximately.^[48,50,51] [Fig. 3a]. PCC can also be performed using vitrectomy but can have radial extension and IOL stability issues. It can also be performed after IOL placement with a vitrectomy probe using the pars plana approach. Anterior vitrectomy (AV) is then performed beyond the margin and 2 mm deeper from the posterior capsule.^[51] However, caution must be exercised and overzealous AV should be avoided as these cases may have peripheral vitreoretinal traction. A complete AV and PCC reduce the chances of postoperative posterior capsular opacification (PCO) significantly.^[51-58] The posterior segment can be visualized at this stage using the endo-illuminator and wide-angle retinal lens [Fig. 4].^[59,60] The AC should be formed with viscoelastic before inserting the endo-illuminator. It allows us to assess the status of the optic disc, posterior pole, and the periphery. The zone of vascularization, presence of ROP, stage, and disease can be determined. This visualization helps in the further management of the ROP as postoperative fundus examination with speculum and indentation may not be possible in the initial 2 weeks considering the wound stability.

Intraocular lens: Another question arises if the IOL can be placed, and if yes, what power to be used? The IOL can be placed if the size of the corneal diameter >10 mm, STS diameter >9 mm, axial length >17 mm, and if no additional ocular features precluding IOL placement are present.^[12,48] In

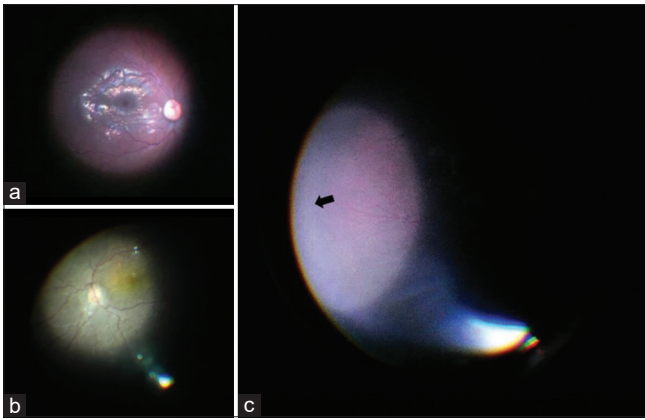


Figure 4: Intraoperative fundus image of a case of a preterm baby with zone II retinopathy of prematurity showing dilated and tortuous vessels suggestive of plus disease (a and b). Peripheral fundus showed avascular retina (c—black arrow)

the cases where the anterior and posterior capsulorhexis is intact and well sized, the IOL can be placed in the bag, while in compromised capsulorhexis, a multipiece IOL to be placed in the sulcus [Fig. 3b]. The optic capture involves fixing the lens optic behind the posterior capsule while the haptics remains in place and allows better stabilization of the lens and further prevents visual axis opacification (VAO).^[61-63] In case of no capsular support, the child may be left aphakic and iris-fixated IOL or AC-IOL can be placed later in life. These ROP cases usually have myopia, thin sclera, and retinal involvement. Hence, scleral fixated IOL is usually avoided in these cases.

The IOL power in pediatric cases depends on the age of the patient at surgery, preoperative biometry, and predicted postoperative change. The younger the child at the time of implantation, the more is the myopic shift expected, and to avoid this higher refractive error in the future, the IOL power needs to be undercorrected accordingly.^[64-67] Various formulas have been given over a period, but the variance is seen more in children of less than 2 years.^[64,67-69] Further, these preterm eyes will have more growth at a rapid rate initially as compared to normal eyes. The usual correlation between the axial length and refractive error is not seen in small preterm babies.^[13,39] Also, those treated with the laser have more axial length growth as compared to those treated with anti-VEGF or spontaneously regressed. These factors need to be taken into consideration as these cases may require more undercorrection as compared to normal eyes.^[70,71] While some studies have found IOL implantation with appropriate undercorrection, refractive correction, and amblyopia treatment to have similar results in terms of glaucoma, visual acuity, and secondary intervention, others have recommended against their use in children of less than 6 months of age. A decision should be individually decided based on the complete profile of the case including the anterior and posterior segment findings, social status, and understanding of the parents of the future needs of the child.^[48,72-74]

A single-piece hydrophobic acrylate IOL can be placed in the bag using a proper technique if the criteria for IOL placement are fulfilled. A 3.5 mm incision allows easy insertion of the injector without any undue pressure on the wound, thereby, maintaining the AC. The AC and intraocular bag should be adequately filled with the visco-cohesive substance. While

injecting the IOL, the leading haptic should be placed against the posterior surface of the anterior capsule to avoid any unnecessary strain on the posterior capsule and dislocation of the IOL into the vitreous cavity. The trailing haptic can be released in the pupillary plane and then tucked in the bag using a Sinsky hook. The viscoelastic should be completely removed and the wound sutured using the 10-0 monofilament nylon suture at the end.^[75-77] It is important to suture the incision in these children in view of low scleral rigidity and their tendency to rub the eyes. In cases where the IOL cannot be placed, secondary IOL can be planned after 2 years of age.^[12,61,76]

Vitreotomized eyes: Further cataract surgery in a vitrectomized eye would be moreover challenging.^[78,79] The loss of posterior support can lead to hypotony, zonular instability, complicated capsulorhexis, and damage to the posterior capsule. Zonular instability along with increased iris lens diaphragm mobility may lead to AC depth fluctuation. In cases with lens touch or pre-existing defects, there is a risk of posterior dislocation of lens fragments. The collapse of the AC should be avoided at any step in these cases. The irrigation parameters are to be kept on the lower side and the overfilling of AC with the viscoelastic needs to be avoided. Hydrodelineation should be done gently while hydrodissection and lens rotation should be completely avoided.^[80] The lens aspiration should be performed trying to maintain the posterior cortex which should be aspirated at the end.

In cases with PC tear, low flow rate, high vacuum, and low phacoemulsification energy are recommended.^[81] In case of a sudden posterior capsular tear, it is important not to panic and remove the instruments suddenly from the eye. The AC should be formed with a combination of sodium hyaluronate 3.0%-chondroitin sulfate 4.0% before removing the instruments. It coats the posterior capsular opening preventing anterior vitreous herniation and lens matter posterior dislocation. The remaining lens matter can be easily removed using the bimanual or vitreous cutter followed by complete AV. Depending on the amount of PC tear and sulcus availability, a multipiece IOL can be placed. If the defect at the posterior capsule is small, it can be converted to PCC and a single-piece IOL can be placed in the bag.^[12,61,81]

Postoperative complications

The postoperative complications of cataract surgery include inflammation, pupillary membrane formation, posterior synechiae, glaucoma, re proliferation of lens material, posterior capsule opacity, and RD [Table 1].

Inflammation: The postoperative treatment with topical cycloplegics and steroids is important.^[51,82,83] The severity of postoperative inflammation is higher in cases with iris neovascularization and those having posterior synechiae because of the iris manipulation and bleeding risk. Hence, topical steroids are required frequently and tapered slowly in these cases. This prevents postoperative posterior iris synechiae formation which may hamper complete visualization of the retina and could lead to glaucoma.

Amblyopia treatment: Stimulation deprivation amblyopia is an important cause of vision loss in children with unilateral congenital cataracts. Cases with unilateral cataracts either left aphakic or IOL placed require appropriate refraction at frequent follow-up post-operatively to avoid amblyopia.

Hence, with appropriate refractive correction, occlusion therapy is needed to prevent amblyopia in these cases.^[84-86] The better visual acuity eye is occluded for a significant period of early childhood which allows the child to keep focusing with the other eye and prevents amblyopia from developing. But at that the same time, it is important to evaluate the fundus periodically to check for ROP-related changes and assess the other eye vision to prevent reverse amblyopia.

Visual outcome: The follow-up post-cataract surgery should be synchronized with ROP monitoring and treatment to prevent unwanted outcomes. The improvement in visual acuity and fixation is evident after cataract surgery in ROP cases but is limited because of the ocular morbidities.^[3,6,78,87] In children, refractive changes after cataract surgery are extensively studied and myopic shift is seen. This shift was more in younger children, aphakic, and laser-treated eyes. Thus, long-term refractive changes depend on various factors including GA, age of the child at the time of surgery, presence of ROP, type of treatment received, and progression of myopia.^[40-43,68] How much each of these factors contributes and affects the growth of the eyeball is unknown and still being studied. Hence, frequent refraction with appropriate correction glasses should be provided to avoid amblyopia. Glasses with appropriate fitting and counseling of the parents/caregivers to ensure the use of glasses are needed.

VAO: It is common after cataract surgery in infants and depends upon whether PCC and AV are done.^[52,88] This can cause significant vision loss with the risk of amblyopia, and hence, the need to look for VAO in the follow-up period.^[53] To avoid VAO, PCC should be done in all cases less than 6 years and AV up to 5 years of age.^[48,53,54,58,89] In older cases with mental retardation and those who cannot co-operate for slit-lamp YAG capsulotomy, PCC and AV can be done.^[12]

Glaucoma: It is a common complication associated with both premature babies and pediatric cataract surgery.^[52,90,91] The incidence of glaucoma in pediatric cataracts varies from 3 to 32% and further increases in cases with aphakia, age at surgery, posterior intervention, and secondary intervention.^[48,89,92-96] The difference in the anterior segment of these preterm individuals increases the risk of glaucoma.^[33] Hence, the intraocular pressure and the optic disc cupping in these individuals should be monitored on follow-up.

RD: One of the complications seen with pediatric cataract surgery and well documented after cataract surgery in adult ROP cases.^[6,87,97] The Early Treatment for Retinopathy of Prematurity Study (ETROP) study had 16% cases with RD after treatment by 9 months of the corrected age. Ezisi *et al.*^[3] had RD in 3.5% of the ROP cases after cataract surgery. Thus, the disease itself is at risk of progression even after treatment and may not be contributed to cataract surgery alone. A good prognosis is obtained in stage 4 as compared to stage 5 ROP disease.^[15,56] Thus, these cases need a long-term regular follow-up for early detection of RD and intervention for the same.

Conclusion

Preterm children with cataracts are at risk of vision loss because of various factors including retinal changes, glaucoma, and amblyopia. With an appropriate approach and combined effort of the pediatrician, ophthalmologist, and anesthesiologist, early identification, prompt intervention, precise surgical techniques,

proper counseling, and postoperative care including amblyopia management, these children can have good vision. Further, with anti-VEGF developing as a prominent treatment option, its definitive role in cataract development needs to be studied.

Financial support and sponsorship

Nil.

Conflicts of interest

There are no conflicts of interest.

References

- Lambert SR, Drack AV. Infantile cataracts. *Surv Ophthalmol* 1996;40:427-58.
- Shukla R, Murthy GVS, Gilbert C, Vidyadhar B, Mukpalkar S. Operational guidelines for ROP in India: A Summary. *Indian J Ophthalmol* 2020;68(Suppl 1):S108-14.
- Ezisi CN, Kekunnaya R, Jalali S, Balakrishnan D, Kumari PR, Mohamed A, *et al.* Cataract surgery in children with retinopathy of prematurity (ROP): Surgical outcomes. *Br J Ophthalmol* 2017;101:1128-31.
- Davitt BV, Christiansen SP, Hardy RJ, Tung B, Good WV, Early Treatment for Retinopathy of Prematurity Cooperative Group. Incidence of cataract development by 6 months' corrected age in the Early Treatment for Retinopathy of Prematurity study. *J AAPOS* 2013;17:49-53.
- Yu YS, Kim S-J, Chang BL. Cataract surgery in children with and without retinopathy of prematurity. *J Cataract Refract Surg* 2004;30:89-94.
- Krolicki TJ, Tasman W. Cataract extraction in adults with retinopathy of prematurity. *Arch Ophthalmol* 1995;113:173-7.
- Vanathi M, Kumawat D, Singh R, Chandra P. Iatrogenic crystalline lens injury in pediatric eyes following intravitreal injection for retinopathy of prematurity. *J Pediatr Ophthalmol Strabismus* 2019;56:162-7.
- Chandra P, Khokhar S, Kumar A. Bilateral total cataract after laser treatment of aggressive posterior retinopathy of prematurity. *Indian Pediatr* 2016;53:S157-8.
- Khokhar S, Chandra P, Gupta Y, Kumawat D, Dhull C. Bilateral total cataract after intravitreal bevacizumab injection in aggressive posterior retinopathy of prematurity. *J Pediatr Ophthalmol Strabismus* 2019;56:e28-30.
- Alden ER, Kalina RE, Hodson WA. Transient cataracts in low-birth-weight infants. *J Pediatr* 1973;82:314-8.
- Drack AV, Burke JP, Pulido JS, Keech RV. Transient punctate lenticular opacities as a complication of argon laser photocoagulation in an infant with retinopathy of prematurity. *Am J Ophthalmol* 1992;113:583-4.
- Khokhar SK, Pillay G, Dhull C, Agarwal E, Mahabir M, Aggarwal P. Pediatric cataract. *Indian J Ophthalmol* 2017;65:1340-9.
- Choi J, Kim JH, Kim S-J, Yu YS. Long-term results of lens-sparing vitrectomy for stages 4B and 5 retinopathy of prematurity. *Korean J Ophthalmol* 2011;25:305-10.
- Lakhanpal RR, Davis GH, Sun RL, Albini TA, Holz ER. Lens clarity after 3-port lens-sparing vitrectomy in stage 4A and 4B retinal detachments secondary to retinopathy of prematurity. *Arch Ophthalmol* 2006;124:20-3.
- Gold RS. Cataracts associated with treatment for retinopathy of prematurity. *J Pediatr Ophthalmol Strabismus* 1997;34:123-4.
- Knight-Nanan DM, Algawi K, Bowell R, O'Keefe M. Advanced cicatricial retinopathy of prematurity--outcome and complications. *Br J Ophthalmol* 1996;80:343-5.
- Trese MT, Shokoohi FK. Immediate complications of cryotherapy in children. *Retina (Philadelphia, Pa)* 1990;10:159.
- Multicenter trial of cryotherapy for retinopathy of prematurity. Preliminary results. *Cryotherapy for Retinopathy of Prematurity*

- Cooperative Group. Arch Ophthalmol 1988;106:471-9.
19. Repka MX, Tung B, Good WV, Shapiro M, Capone A, Baker JD, *et al.* Outcome of eyes developing retinal detachment during the Early Treatment for Retinopathy of Prematurity Study (ETROP). Arch Ophthalmol 2006;124:24-30.
 20. Christiansen SP, Bradford JD. Cataract in infants treated with argon laser photocoagulation for threshold retinopathy of prematurity. Am J Ophthalmol 1995;119:175-80.
 21. O'Neil JW, Hutchinson AK, Saunders RA, Wilson ME. Acquired cataracts after argon laser photocoagulation for retinopathy of prematurity. J AAPOS 1998;2:48-51.
 22. Paysse EA, Miller A, Brady McCreery KM, Coats DK. Acquired cataracts after diode laser photocoagulation for threshold retinopathy of prematurity. Ophthalmology 2002;109:1662-5.
 23. Mintz-Hittner HA, Kennedy KA, Chuang AZ, BEAT-ROP Cooperative Group. Efficacy of intravitreal bevacizumab for stage 3+retinopathy of prematurity. N Engl J Med 2011;364:603-15.
 24. Cuthbertson F, Newsom R. UK retinopathy of prematurity treatment survey. Eye (Lond) 2007;21:156-7.
 25. Campolattaro BN, Lueder GT. Cataract in infants treated with argon laser photocoagulation for threshold retinopathy of prematurity. Am J Ophthalmol 1995;120:264-6.
 26. Kaiser RS, Trese MT. Iris atrophy, cataracts, and hypotony following peripheral ablation for threshold retinopathy of prematurity. Arch Ophthalmol 2001;119:615-7.
 27. Quan AV, Pineles SL, Tsui I, Velez FG. Phthisis bulbi following lensectomy in retinopathy of prematurity eyes previously treated with laser photocoagulation. Retin Cases Brief Rep 2015;9:67-71.
 28. Stahl A, Lepore D, Fielder A, Fleck B, Reynolds JD, Chiang MF, *et al.* Ranibizumab versus laser therapy for the treatment of very low birthweight infants with retinopathy of prematurity (RAINBOW): An open-label randomized controlled trial. Lancet 2019;394:1551-9.
 29. Chen TA, Shields RA, Bodnar ZH, Callaway NF, Schachar IH, Moshfeghi DM. A spectrum of regression following intravitreal bevacizumab in retinopathy of prematurity. Am J Ophthalmol 2019;198:63-9.
 30. Fung AE, Rosenfeld PJ, Reichel E. The international intravitreal bevacizumab safety survey: Using the internet to assess drug safety worldwide. Br J Ophthalmol 2006;90:1344-9.
 31. Meyer CH, Rodrigues EB, Michels S, Mennel S, Schmidt JC, Helb H-M, *et al.* Incidence of damage to the crystalline lens during intravitreal injections. J Ocul Pharmacol Ther 2010;26:491-5.
 32. Hairston RJ, Maguire AM, Vitale S, Green WR. Morphometric analysis of pars plana development in humans. Retina (Philadelphia, Pa) 1997;17:135-8.
 33. Chang SHL, Lee Y-S, Wu S-C, See L-C, Chung C-C, Yang M-L, *et al.* Anterior chamber angle and anterior segment structure of eyes in children with early stages of retinopathy of prematurity. Am J Ophthalmol 2017;179:46-54.
 34. Shui Y-B, Wang X, Hu JS, Wang S-P, Garcia CM, Potts JD, *et al.* Vascular endothelial growth factor expression and signaling in the lens. Invest Ophthalmol Vis Sci 2003;44:3911-9.
 35. Ash JD, Overbeek PA. Lens-specific VEGF-A expression induces angioblast migration and proliferation and stimulates angiogenic remodeling. Dev Biol 2000;223:383-98.
 36. Garcia CM, Shui Y-B, Kamath M, DeVillar J, Johnson RS, Gerber H-P, *et al.* The function of VEGF-A in lens development: Formation of the hyaloid capillary network and protection against transient nuclear cataracts. Exp Eye Res 2009;88:270-6.
 37. Beck KD, Rahman EZ, Ells A, Mireskandari K, Berrocal AM, Harper CA. SAFER-ROP: Updated protocol for anti-VEGF injections for retinopathy of prematurity. Ophthalmic Surg Lasers Imaging Retina 2020;51:402-6.
 38. Takano S, Ishiwata S, Nakazawa M, Mizugaki M, Tamai M. Determination of ascorbic acid in human vitreous humor by high-performance liquid chromatography with UV detection. Curr Eye Res 1997;16:589-94.
 39. Fledelius HC. Preterm delivery and the growth of the eye. An oculometric study of eye size around term-time. Acta Ophthalmologica 1992;70:10-5.
 40. Laws DE, Haslett R, Ashby D, O'Brien C, Clark D. Axial length biometry in infants with retinopathy of prematurity. Eye 1994;8:427-30.
 41. Azad RV, Lakshminarayana P, Kumar H, Talwar D, Pal N, Chandra P. Ocular growth pattern in cryotherapy- and laser-treated infants with prethreshold retinopathy of prematurity. J Pediatr Ophthalmol Strabismus 2005;42:149-54.
 42. Axer-Siegel R, Bourla D, Kremer I, Weinberger D, Snir M. Effect of peripheral retinal ablation with cryotherapy versus diode laser photocoagulation on axial length in the growing rabbit eye. Br J Ophthalmol 2006;90:491-5.
 43. Cook A, White S, Batterbury M, Clark D. Ocular growth and refractive error development in premature infants with or without retinopathy of prematurity. Invest Ophthalmol Vis Sci 2008;49:5199-207.
 44. Deramo VA, Shah GK, Bauml CR, Fineman MS, Corr ea ZM, Benson WE, *et al.* The role of ultrasound biomicroscopy in ocular trauma. Trans Am Ophthalmol Soc 1998;96:355-65; discussion 365-7.
 45. Dick HB, Aliyeva SE, Hengerer F. Effect of trypan blue on the elasticity of the human anterior lens capsule. J Cataract Refract Surg 2008;34:1367-73.
 46. Pandey SK, Wilson ME, Trivedi RH, Izak AM, Macky TA, Werner L, *et al.* Pediatric cataract surgery and intraocular lens implantation: Current techniques, complications, and management. Int Ophthalmol Clin 2001;41:175-96.
 47. Guo S, Wagner RS, Caputo A. Management of the anterior and posterior lens capsules and vitreous in pediatric cataract surgery. J Pediatr Ophthalmol Strabismus 2004;41:330-7; quiz 356-7.
 48. Ram J, Brar GS, Kaushik S, Sukhija J, Bandyopadhyay S, Gupta A. Primary intraocular lens implantation in the first two years of life: Safety profile and visual results. Indian J Ophthalmol 2007;55:185-9.
 49. Vasavada AR, Trivedi RH, Apple DJ, Ram J, Werner L. Randomized, clinical trial of multiquadrant hydrodissection in pediatric cataract surgery. Am J Ophthalmol 2003;135:84-8.
 50. Parks MM. Management of the posterior capsule in congenital cataracts. J Pediatr Ophthalmol Strabismus 1984;21:114-7.
 51. Gimbel H, DeBroff B, Dunbar J, Nihalani B. Surgical management of pediatric cataracts and aphakia. In: Cataract Surgery: Technique, Complications, and Management. Philadelphia: Elsevier Saunders; 2009. p. 399-410.
 52. Astle WF, Alewenah O, Ingram AD, Paszuk A. Surgical outcomes of primary foldable intraocular lens implantation in children: Understanding posterior opacification and the absence of glaucoma. J Cataract Refract Surg 2009;35:1216-22.
 53. Vasavada AR, Praveen MR, Tassignon M-J, Shah SK, Vasavada VA, Vasavada VA, *et al.* Posterior capsule management in congenital cataract surgery. J Cataract Refract Surg 2011;37:173-93.
 54. Raina UK, Mehta DK, Monga S, Arora R. Functional outcomes of acrylic intraocular lenses in pediatric cataract surgery. J Cataract Refract Surg 2004;30:1082-91.
 55. Buckley EG, Klombers LA, Seaber JH, Scalise-Gordy A, Minzter R. Management of the posterior capsule during pediatric intraocular lens implantation. Am J Ophthalmol 1993;115:722-8.
 56. Koenig SB, Ruttum MS. Management of the posterior capsule during pediatric intraocular lens implantation. Am J Ophthalmol 1993;116:656-7.
 57. Koch DD, Kohnen T. Retrospective comparison of techniques to prevent secondary cataract formation after posterior chamber intraocular lens implantation in infants and children. J Cataract Refract Surg 1997;23:657-63.

58. Vasavada A, Desai J. Primary posterior capsulorhexis with and without anterior vitrectomy in congenital cataracts. *J Cataract Refract Surg* 1997;23:645-51.
59. Kim YJ, Park SJ, Lee JY, Lee DY, Nam DH. Intraoperative complications of cataract surgery using intracameral illumination in the elderly over 75 years. *J Ophthalmol* 2019;2019:e1594152. doi: 10.1155/2019/1594152.
60. Khokhar S, Bhayana AA, Singhal T, Banerjee M. Technique for posterior segment evaluation in pediatric cases undergoing cataract surgeries. *BMJ Case Rep* 2021;14:e240931.
61. Gimbel HV. Posterior capsulorhexis with optic capture in pediatric cataract and intraocular lens surgery. *Ophthalmology* 1996;103:1871-5.
62. Gimbel HV. Posterior continuous curvilinear capsulorhexis and optic capture of the intraocular lens to prevent secondary opacification in pediatric cataract surgery. *J Cataract Refract Surg* 1997;23:652-6.
63. Faramarzi A, Javadi MA. Comparison of 2 techniques of intraocular lens implantation in pediatric cataract surgery. *J Cataract Refract Surg* 2009;35:1040-5.
64. Dahan E, Drusedau MU. Choice of lens and dioptric power in pediatric pseudophakia. *J Cataract Refract Surg* 1997;23:618-23.
65. Weakley DR, Lynn MJ, Dubois L, Cotsonis G, Wilson ME, Buckley EG, *et al.* Myopic shift 5 years after intraocular lens implantation in the infant aphakia treatment study. *Ophthalmology* 2017;124:822-7.
66. McClatchey SK, Parks MM. Myopic shift after cataract removal in childhood. *J Pediatr Ophthalmol Strabismus* 1997;34:88-95.
67. Enyedi LB, Peterseim MW, Freedman SF, Buckley EG. Refractive changes after pediatric intraocular lens implantation. *Am J Ophthalmol* 1998;126:772-81.
68. Khokhar SK, Tomar A, Pillay G, Agarwal E. Biometric changes in Indian pediatric cataract and postoperative refractive status. *Indian J Ophthalmol* 2019;67:1068-72.
69. McClatchey SK. Choosing IOL power in pediatric cataract surgery. *Int Ophthalmol Clin* 2010;50:115-23.
70. Astle WF, Ingram AD, Isaza GM, Echeverri P. Pediatric pseudophakia: Analysis of intraocular lens power and myopic shift. *Clin Exp Ophthalmol* 2007;35:244-51.
71. Lambert SR. Changes in ocular growth after pediatric cataract surgery. *Dev Ophthalmol* 2016;57:29-39.
72. Lambert SR, Aakalu VK, Hutchinson AK, Pineles SL, Galvin JA, Heidary G, *et al.* Intraocular lens implantation during early childhood: A report by the American Academy of Ophthalmology. *Ophthalmology* 2019;126:1454-61.
73. Lambert SR, Cotsonis G, DuBois L, Nizam Ms A, Kruger SJ, Hartmann EE, *et al.* Long-term effect of intraocular lens vs contact lens correction on visual acuity after cataract surgery during infancy: A randomized clinical trial. *JAMA Ophthalmol* 2020;138:365-72.
74. Hutchinson AK, Wilson ME, Saunders RA. Outcomes and ocular growth rates after intraocular lens implantation in the first 2 years of life. *J Cataract Refract Surg* 1998;24:846-52.
75. Basti S, Krishnamachary M, Gupta S. Results of sutureless wound construction in children undergoing cataract extraction. *J Pediatr Ophthalmol Strabismus* 1996;33:52-4.
76. Lavrich JB, Goldberg DS, Nelson LB. Suture use in pediatric cataract surgery: A survey. *Ophthalmic Surg* 1993;24:554-5.
77. Matalia J, Panmand P, Ghalla P. Comparative analysis of non-absorbable 10-0 nylon sutures with absorbable 10-0 Vicryl sutures in pediatric cataract surgery. *Indian J Ophthalmol* 2018;66:661-4.
78. Nguyen H, Yen KG. Outcome of cataract surgery in patients treated for retinopathy of prematurity. *Open J Ophthalmol* 2017;7:293-302.
79. Cole CJ, Charteris DG. Cataract extraction after retinal detachment repair by vitrectomy: Visual outcome and complications. *Eye (Lond)* 2009;23:1377-81.
80. Saeed MU, Prasad S. Management of cataract caused by inadvertent capsule penetration during intravitreal injection of ranibizumab. *J Cataract Refract Surg* 2009;35:1857-9.
81. Vajpayee RB, Sharma N, Dada T, Gupta V, Kumar A, Dada VK. Management of posterior capsule tears. *Surv Ophthalmol* 2001;45:473-88.
82. Jameson NA, Good WV, Hoyt CS. Inflammation after cataract surgery in children. *Ophthalmic Surg* 1992;23:99-102.
83. Kaur S, Sukhija J. Difluprednate versus prednisolone acetate for inflammation following cataract surgery in pediatric patients: A randomized safety and efficacy study. *Eye (Lond)* 2017;31:506.
84. Lloyd IC, Dowler JG, Kriss A, Speedwell L, Thompson DA, Russell-Eggitt I, *et al.* Modulation of amblyopia therapy following early surgery for unilateral congenital cataracts. *Br J Ophthalmol* 1995;79:802-6.
85. Smith KH, Baker DB, Keech RV, Adams LW, Rosa RH, Austin CJ, *et al.* Monocular congenital cataracts: Psychological effects of treatment. *J Pediatr Ophthalmol Strabismus* 1991;28:245-9.
86. Birch EE, Swanson WH, Stager DR, Woody M, Everett M. Outcome after very early treatment of dense congenital unilateral cataract. *Invest Ophthalmol Vis Sci* 1993;34:3687-99.
87. Farr AK, Stark WJ, Haller JA. Cataract surgery by phacoemulsification in adults with retinopathy of prematurity. *Am J Ophthalmol* 2001;132:306-10.
88. O'Keefe M, Fenton S, Lanigan B. Visual outcomes and complications of posterior chamber intraocular lens implantation in the first year of life. *J Cataract Refract Surg* 2001;27:2006-11.
89. Chrousos GA, Parks MM, O'Neill JF. Incidence of chronic glaucoma, retinal detachment and secondary membrane surgery in pediatric aphakic patients. *Ophthalmology* 1984;91:1238-41.
90. Bremer DL, Rogers DL, Good WV, Tung B, Hardy RJ, Fellows R. Glaucoma in the Early Treatment for Retinopathy of Prematurity (ETROP) study. *J AAPOS* 2012;16:449-52.
91. Chandra P, Tewari R, Salunkhe N, Kumawat D, Chaurasia AK, Gupta V. Short-term incidence and management of glaucoma after successful surgery for stage 4 retinopathy of prematurity. *Indian J Ophthalmol* 2019;67:917.
92. Michaelides M, Bunce C, Adams GG. Glaucoma following congenital cataract surgery--the role of early surgery and posterior capsulotomy. *BMC Ophthalmol* 2007;7:13. doi: 10.1186/1471-2415-7-13.
93. Kirwan C, Lanigan B, O'Keefe M. Glaucoma in aphakic and pseudophakic eyes following surgery for congenital cataract in the first year of life. *Acta Ophthalmol* 2010;88:53-9.
94. Vishwanath M, Cheong-Leen R, Taylor D, Russell-Eggitt I, Rahi J. Is early surgery for congenital cataract a risk factor for glaucoma? *Br J Ophthalmol* 2004;88:905-10.
95. Urban B, Bakunowicz-Lazarczyk A. Aphakic glaucoma after congenital cataract surgery with and without intraocular lens implantation. *Klin Oczna* 2010;112:105-7.
96. Mills MD, Robb RM. Glaucoma following childhood cataract surgery. *J Pediatr Ophthalmol Strabismus* 1994;31:355-60; discussion 361.
97. Kaiser RS, Fenton GL, Tasman W, Trese MT. Adult retinopathy of prematurity: Retinal complications from cataract surgery. *Am J Ophthalmol* 2008;145:729-35.e1.