

## Invited Clinical Commentary

# MSK Ultrasound - An IJSPT Perspective

Phil Page, PT, PhD, ATC, CSCS, FACSM<sup>1, a</sup>, Robert C Manske, PT, DPT, Med, SCS, ATC, CSCS<sup>2</sup>, Michael Voight, PT, DHSC, SCS, OCS, ATC, CSCS, FAPTA<sup>3</sup>, Chris Wolfe, PT, DPT, OCS, Cert MDT<sup>3</sup>

<sup>1</sup> Doctor of Physical Therapy Program, Franciscan University, <sup>2</sup> Doctor of Physical Therapy Program, Wichita State University, <sup>3</sup> School of Physical Therapy, Belmont University

Keywords: MSK ultrasound, PT imaging

<https://doi.org/10.26603/001c.68184>

---

## International Journal of Sports Physical Therapy

Vol. 18, Issue 1, 2023

---

MSK ultrasound is a valuable imaging technique which has become increasingly popular in recent years. This efficient technique proves beneficial in a variety of ways. MSK ultrasound effectively streamlines the process by enabling practitioners to securely and accurately image and assess structures all in one simple step. By allowing healthcare providers to access critical information quickly and conveniently, MSK ultrasound can help identify conditions early when interventions are most effective. Moreover, it may be able to shorten diagnostic times and reduce costs through more cost-effective use of resources such as imaging and laboratory testing. Furthermore, MSK ultrasound can provide additional insights into musculoskeletal anatomy and help improve patient care and outcomes. In addition, utilizing this method reduces exposure to radiation and provides enhanced patient comfort with its quick scan duration. MSK ultrasound has a high potential to provide quick and accurate diagnosis of MSK disturbances when used correctly. As clinicians become more comfortable and familiar with this technology, we will continue to see its use expand for various MSK assessments. In this commentary we'll explore how ultrasound can be used in physical therapy, specifically for musculoskeletal assessment. We'll also look at some of the potential benefits and limitations of using ultrasound in PT practice.

### BACKGROUND

Point of Care Ultrasound (POCUS) is commonly used in various medical disciplines to assess structures quickly and conveniently such as the heart, lungs and bladder. Musculoskeletal (MSK) ultrasound (US) is quickly growing as a non-invasive and safe manner of assessing musculoskeletal structures (bones, muscles, tendons, ligaments) without the need for expensive or potentially harmful studies such as radiograph or MRI.

MSK-US provides clinicians with a "window" through the skin to examine different tissues including muscle, bone, tendon, and ligament. In addition to structural integrity, visualizing inflammation using MSK-US may support a physical therapy diagnosis and guide appropriate physical therapy interventions. While physical therapists (PTs) are familiar with "therapeutic" ultrasound, MSK-US is not widely used by PTs. The earliest publications of MSK-US use by PTs were in the 1980s, focusing on the quadriceps muscle to describe its size.<sup>1,2</sup> In the 1990's, researchers and clinicians at the University of Queensland identified the

activity of the deep multifidus and transverse abdominus muscles in relation to other abdominal muscles in patients with lower back pain.<sup>3,4</sup> They discovered that the multifidus was atrophied and the transverse abdominus muscle was delayed in activation in patients diagnosed with lower back pain; they subsequently used MSK-US to provide visualization of patients for real-time feedback during rehabilitation.<sup>5</sup> More recently, researchers reported high levels of agreement when PTs using MSK-US were compared with radiologists on 40 cadaveric shoulders.<sup>6</sup>

"Rehabilitative" ultrasound imaging (RUSI) was the term initially used to describe its use in evaluating soft tissue structures during tasks.<sup>7</sup> Since then, 4 categories of ultrasonography have been identified in physical therapy: *diagnostic*, *rehabilitation*, *interventional*, and *research* ultrasound.<sup>8</sup> Because these categories were only recently described, the terminology used in the literature may not be consistent; therefore, this review will follow the descriptions provided by Whittaker et al.<sup>8</sup> In general, POCUS consists of diagnostic, rehabilitative, and interventional US; research US is used for scientific purposes:

---

a Corresponding Author:  
[phillip.page@franu.edu](mailto:phillip.page@franu.edu)

**Diagnostic US:** diagnosis and monitor pathology (haemarthrosis, sprains, strains, healing stage, lesions, disease)

**Rehabilitative US:** evaluate muscle and other soft tissue structure and function (including biofeedback) during physical tasks

**Interventional US:** guide percutaneous procedures involving 'dry' (acupuncture) or 'wet' needling (injection)

**Research US:** measurement; explore muscle and soft tissue structure and function; develop and evaluate screening tools and interventions

## DIAGNOSTIC MSK ULTRASOUND

Although PTs do not make medical diagnoses, they evaluate pathoanatomic structures in making a physical therapy diagnosis. Identifying structural lesions beyond the physical therapy scope of practice (such as a fracture) allows the PT to refer patients to appropriate providers if needed quickly. MSK-US has been shown to be a cost-effective measure in diagnosing structural pathologies.<sup>9,10</sup>

For some MSK conditions ultrasound has been proven to be equal to or better than MRI for accurate diagnosis of meniscal injuries,<sup>11</sup> ACL and PCL injuries,<sup>12</sup> Achilles tendinopathy,<sup>13</sup> peripheral nerve injuries,<sup>14</sup> lateral epicondylitis,<sup>15</sup> thumb ulnar collateral ligament injuries,<sup>16-27</sup> identifying rotator cuff tears,<sup>16-27</sup> and supraspinatus lesions.<sup>28,29</sup> There are several types of MSK injuries that US may not be comparable to MRI that include distal biceps tendon avulsions,<sup>30</sup> plantar plates.<sup>31</sup> MSK-US has also been used for the evaluation of acute athletic injury.<sup>32,33</sup>

Interest is gaining in US's ability to view muscles both statically and dynamically.<sup>34-40</sup> Dynamic US protocols have been published by an international group of experts to help clinicians evaluate structures while recording video during real-time patient examination to improve their understanding of their diagnosis.<sup>41-44</sup> Dynamic ultrasound allows for real-time visualization of structures as they move in relation to other structures. For example, the movement of adjacent fascial layers can be evaluated during active muscle contraction to assess fascial mobility. Muscle architecture can be examined under contraction or relaxation for deficits.

One of the more unique properties of MSK-US that can be used to assess musculoskeletal pathology is use of Doppler imaging of blood flow. This utilizes the Doppler effect which describes the change in frequency of the sound wave that is seen as an object moves closer to (toward) or farther (away) from the transducer. The amount of movement can be seen as the Doppler shift that can be picked up on an US image using color enhancement. In diagnostic US this is usually used to determine the presence or absence of blood flow, seen with issues like deep venous thrombosis after musculoskeletal injury to the lower,<sup>45-48</sup> and upper extremities,<sup>49</sup> or even vascular supply to joints).<sup>50</sup> Color Doppler imaging is also useful in detecting effusions<sup>51</sup> and musculoskeletal inflammation such as soft tissue hyperemia.<sup>52,53</sup>

## REHABILITATIVE MSK ULTRASOUND

RUSI is used to provide real-time feedback for physical therapy patients. As mentioned previously, real-time US can be used for patient feedback in re-training activation of the transverse abdominus muscle in patients with lower back pain.<sup>5</sup> RUSI has been used to assess muscle function in screening athletes for injury risk (Hides 2016, 2017).<sup>54,55</sup> Other rehabilitation applications include pelvic health for urinary incontinence.<sup>56,57</sup>

## INTERVENTIONAL MSK ULTRASOUND

Physical therapists can integrate MSK-US into their interventions to guide treatment. Silveves et al.<sup>58</sup> reported a case of a runner with plantar fasciitis managed with MSK-US imaging to guide decision-making for optimal treatment location and progress. As dry needling has increased in popularity among PTs, the use of MSK-US to assist with needle placement has slowly grown<sup>59,60</sup>; however, the authors of one study suggested there is no additional benefit to using US-guided dry needling with PT in chronic neck pain patients.<sup>61</sup>

Typically, interventional MSK-US is performed by practitioners giving injections. While outside the scope of practice for most PTs, MSK-US provides for accurate placement of needles for injection of anti-inflammatory medication or during prolotherapy. Recently, the technique of "hydrodissection" has been introduced in musculoskeletal medicine.<sup>62-64</sup> During hydrodissection, MSK-US is used to guide hypodermic needles into muscle and fascia to inject saline while breaking-up adhesions and facilitating fascial mobility.

## RESEARCH MSK ULTRASOUND

MSK-US is also used as a measurement tool for soft tissues in research. In the past, instruments to measure muscle mass included bioelectrical impedance, dual X-ray absorptiometry, computed tomography, and magnetic resonance imaging. The use of MSK-US appears to be a simple, fast, safe, valid and reliable way to measure both muscle and tendon length and thickness.<sup>65-71</sup> In addition to length and thickness, MSK-US can also be utilized to assess fascicle or pennation angles.<sup>72</sup>

Muscle thickness can be quantified to represent muscle contraction. A systematic review in 2009<sup>73</sup> suggested that MSK-US was a valid measure of trunk muscle activation and size during submaximal isometric contractions. Recently, fascia muscle thickness has been measured with MSK-US.<sup>74-76</sup> Tissue stiffness can be measured as well, including tendon stiffness and overall tissue tension. Shear wave elastography, for example, has been shown to be a useful measure of quadriceps tendon and muscle stiffness.<sup>77-81</sup> Pressure applied with the transducer is compared to the movement of the tissue on the ultrasound, and the tissue stiffness is quantified with a color map.

As stated previously, MSK-US can be used to quantify blood flow in arteries and resultant hyperemia of tissues. Many physical therapy interventions purport to increase blood flow to the treated area. Arterial blood flow can be quantified with MSK-US by vessel diameter and pulse flow during exercise or after interventions.<sup>82,83</sup>

## MSK-US TECHNOLOGY

To perform musculoskeletal ultrasound, the therapist will require an ultrasound sonography device that includes an appropriate transducer. Generally, US transducers are classified as linear or curvilinear for superficial and deep tissue sonography, respectively. Some devices such as the Butterfly IQ (Burlington, MA) use a single transducer capable of both superficial and deep sonography. The transducer is the component that converts electrical energy into sound waves. Piezoelectric crystals within the transducer produce the piezoelectric effect that allows ultrasound waves to produce an image on the screen of the device. A soundwave is created that is sent to the tissue, which is returned to the transducer.

Various frequencies of sound waves are used depending on the depth of the tissue of interest. Most diagnostic US devices have pre-modulated settings depending on the target tissue. Musculoskeletal tissues are generally more superficial, thus using higher frequencies, while deeper structures, such as the abdominal organs require lower frequencies for best visualization. The sound waves are either reflected to the transducer, absorbed by the tissue, or refracted. Ultrasound waves that are reflected from tissue create an “echo” that returns to the transducer, where the echoes are electronically transformed into digital images at various shades of black and white. The level of reflection (and thus color) is known as “echogenicity”.

## ECOGENICITY

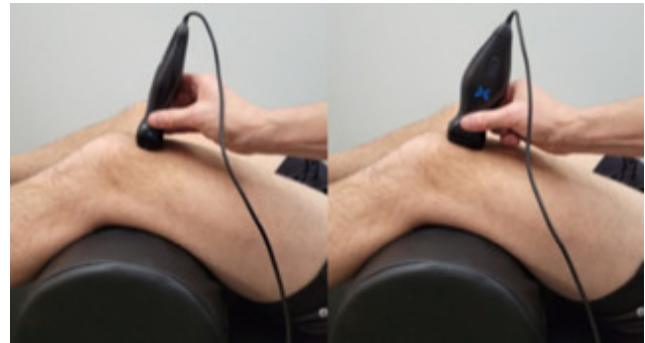
Ultrasonography measures the amount of echo from sound waves produced by the transducer at specific frequencies. Ultrasound “echogenicity” is defined as how bright musculoskeletal structures appear on an ultrasound image relative to other structures. Musculoskeletal tissues viewed on US will be either normal or pathologic tissues, and each displays a varying level of echogenicity. Structures run the gamut from hyperechoic (brighter) or hypoechoic (less bright) on imaging. Structures that are viewed as hyperechoic or echogenic are high in collagen content such as bones, normal healthy tendons, or certain calcifications in soft tissues. Nerves are hyperechoic and appear as a ‘starry night’ pattern on cross-section. A hypoechoic structure is one where the viewed structures appear darker (less white than hyperechoic structures). These structures could include fat, masses, cysts, or inflammation. A structure that is totally black is termed anechoic and usually represents fluid. For example, blood vessels appear as round, black circles in cross-section. Lastly, a structure is termed isoechoic when used to describe similar echogenicity of surrounding tissue. [Table 1](#) provides an ‘echogenicity’ scale of tissues

and [Figure 1](#) is a general schematic of different layers of tissue viewed with ultrasound.

## SONOGRAPHY TECHNIQUE

Generally, a gel is used to promote transmission of sound waves to and from the tissues. This is done to couple the transducer with the body part so that air is not located between the skin and device. When air is introduced between the patient and the transducer the sound waves are more easily reflected away from the structures of importance resulting in a poorer image. Ultrasound gel pads can also be used as an interface between the transducer and bony prominences to minimize artifact.

Clinicians must have a keen knowledge of regional anatomy and palpation skills to ensure proper position of the transducer over the target tissue. The transducer should be held perpendicular to the skin with the indicator directed proximal and/or lateral; this standard positioning orients the examiner with the image. Most commonly, MS-US views can be viewed in either a short axis (transverse) or long axis (longitudinal). The short axis (SAX) is performed through the transverse plane of the intended tissue, while the long axis (LAX) is performed along the longitudinal length of the tissue (See [Figure 2](#)). When possible, it is best to visualize both to get an accurate representation of the entire tissue.




**Figure 2. Ultrasound transducer position in the transverse short axis (left image) and in the longitudinal long axis (right image)**

Proper technique and adequate technology are essential for an accurate diagnosis. Improper technique can lead to artifacts, which can lead to an inaccurate diagnosis. A unique artifact in MSK-US is “anisotropy” where tissues of fibrillar structure, such as tendons and ligaments, have reduced ecogenicity based on the angle of the transducer. This can result in mistaken interpretation of pathological defects.

## EDUCATION & TRAINING

Although access to diagnostic ultrasound equipment has improved in cost and convenience, the ability to perform and interpret MSK-US requires training and experience. The use of MSK-US in PT practice is supported by the Amer-



**Figure 1. Schematic representation of echogenicity of various structures with musculoskeletal ultrasound.**

1. Skin
2. Subcutaneous fat
3. Superficial fascia
4. Deep muscular fascia
5. Muscle
6. Deep muscular fascia
7. Nerve
8. Vein (smaller) and Artery
9. Tendon
10. Ligament
11. Bone
12. Hyaline cartilage
13. Articular cartilage / joint space

ican Physical Therapy Association (APTA) and is generally not prohibited by state regulations; however, reimbursement may be denied unless the PT is credentialed to perform diagnostic ultrasound as a certified and registered MSK sonography practitioner (RSMK-certified).

Several companies provide education and training on MSK-US including virtual and hands-on courses, while some manufacturers such as Butterfly IQ (Burlington, MA) provide instructional videos. SonoSim (Santa Monica, CA) provides an affordable and portable POCUS simulation that includes a 'dummy' transducer to provide both didactic and

psychomotor skills needed for MSK-US. Several excellent textbooks are available specific to MSK-US as well.<sup>84-86</sup>

## CONCLUSION

Physical therapists have an opportunity to embrace technology and integrate MSK-US into their practice. Emerging research continues to support its use in PT for a variety of patients, including diagnosis, treatment, and research.



This is an open-access article distributed under the terms of the Creative Commons Attribution 4.0 International License (CCBY-NC-4.0). View this license's legal deed at <https://creativecommons.org/licenses/by-nc/4.0> and legal code at <https://creativecommons.org/licenses/by-nc/4.0/legalcode> for more information.

**Table 1. Musculoskeletal ultrasound echogenicity spectrum**

Anechoic	Black	Fluid	Blood vessels or swelling/inflammation
		Hyaline Cartilage	At end of long bones, surrounded by bright white periosteum
Hypoechoic	Grayscale	Fat	Hazy streaks below skin
		Muscle	Fasciculated/ speckled hypoechoic with hyperechoic striations, encased by bright fascia
		Tendon	Linear striated hyperechoic at ends of muscle inserting into bone (fibrillated in long-axis)
Hyperechoic	White	Nerve	Hyperechoic “starry night” appearance
		Ligament	Linear Striated hyperechoic surrounding ends of bones at joints
		Cartilage	Articular cartilage at end of bones includes anechoic periosteum
		Fascia	Bright white, surrounding muscles
		Bone	Bright white line with acoustic shadow at bottom of image

## REFERENCES

- Young A, Hughes I, Russell P, Parker MJ, Nichols PJR. Measurement of quadriceps muscle wasting by ultrasonography. *Rheumatology*. 1980;19(3):141-148. [doi:10.1093/rheumatology/19.3.141](https://doi.org/10.1093/rheumatology/19.3.141)
- Stokes M, Young A. Measurement of quadriceps cross-sectional area by ultrasonography: a description of the technique and its applications in physiotherapy. *Physiother Pract*. 1986;2(1):31-36. [doi:10.3109/09593988609027039](https://doi.org/10.3109/09593988609027039)
- Hides JA, Stokes MJ, Saide M, Jull GA, Cooper DH. Evidence of lumbar multifidus muscle wasting ipsilateral to symptoms in patients with acute/subacute low back pain. *Spine*. 1994;19(2):165-172. [doi:10.1097/00007632-199401001-00009](https://doi.org/10.1097/00007632-199401001-00009)
- Hodges PW, Richardson CA. Delayed postural contraction of transversus abdominis in low back pain associated with movement of the lower limb. *J Spinal Disord*. 1998;11(1):46-56. [doi:10.1097/00002517-199802000-00008](https://doi.org/10.1097/00002517-199802000-00008)
- Hides JA, Richardson CA, Jull GA. Use of real-time ultrasound imaging for feedback in rehabilitation. *Man Ther*. 1998;3(3):125-131. [doi:10.1016/s1356-689x\(98\)80002-7](https://doi.org/10.1016/s1356-689x(98)80002-7)
- Duijn EAHD, Roy van S, Karel YHJM, Probyn S, Pouliart N. An interexaminer agreement and reliability study on cadavers with musculoskeletal ultrasound of the shoulder performed by physiotherapists and radiologists compared with dissection. *Musculoskelet Sci Pract*. 2022;60:102569. [doi:10.1016/j.msksp.2022.102569](https://doi.org/10.1016/j.msksp.2022.102569)
- Teyhen D. Rehabilitative Ultrasound Imaging Symposium San Antonio, TX, May 8-10, 2006. *J Orthop Sports Phys Ther*. 2006;36(8):A1-3. [doi:10.2519/jospt.2006.0301](https://doi.org/10.2519/jospt.2006.0301)
- Whittaker JL, Ellis R, Hodges PW, et al. Imaging with ultrasound in physical therapy: What is the PT's scope of practice? A competency-based educational model and training recommendations. *Br J Sports Med*. 2019;53(23):1447-1453. [doi:10.1136/bjsports-2018-100193](https://doi.org/10.1136/bjsports-2018-100193)
- Acebes C, Rubio L, Román A, Herrero A, Arcos J. Cost-effectiveness of on-site musculoskeletal ultrasound in an outpatient rheumatology clinic. *Rheumatology*. 2021;60(4):1832-1838. [doi:10.1093/rheumatology/keaa678](https://doi.org/10.1093/rheumatology/keaa678)
- Bureau NJ, Ziegler D. Economics of musculoskeletal ultrasound. *Curr Radiol Rep*. 2016;4(8):44. [doi:10.1007/s40134-016-0169-5](https://doi.org/10.1007/s40134-016-0169-5)
- Elshimy A, Osman AM, Awad MES, Abdel Aziz MM. Diagnostic accuracy of point-of-care knee ultrasound for evaluation of meniscus and collateral ligaments pathology in comparison with MRI. *Acta Radiol*. Published online December 1, 2021;2841851211058280. [doi:10.1177/02841851211058280](https://doi.org/10.1177/02841851211058280)
- Lee SH, Yun SJ. Efficiency of knee ultrasound for diagnosing anterior cruciate ligament and posterior cruciate ligament injuries: a systematic review and meta-analysis. *Skeletal Radiol*. 2019;48(10):1599-1610. [doi:10.1007/s00256-019-03225-w](https://doi.org/10.1007/s00256-019-03225-w)

13. Gatz M, Bode D, Betsch M, et al. Multimodal ultrasound versus mri for the diagnosis and monitoring of achilles tendinopathy: a prospective longitudinal study. *Orthop J Sports Med.* 2021;9(4):232596712111006824. doi:10.1177/232596712111006826
14. Nischal N, Gupta S, Lal K, Singh JP. Performance evaluation of high-resolution ultrasound versus magnetic resonance imaging in diagnosing peripheral nerve pathologies. *Indian J Radiol Imaging.* 2021;31(1):43-48. doi:10.1055/s-0041-1729130
15. Bachta A, Rowicki K, Kisiel B, et al. Ultrasonography versus magnetic resonance imaging in detecting and grading common extensor tendon tear in chronic lateral epicondylitis. *PloS One.* 2017;12(7):e0181828. doi:10.1371/journal.pone.0181828
16. Abd-ElGawad EA, Ibraheem MA, Fouly EH. Evaluation of supraspinatus muscle tears by ultrasonography and magnetic resonance imaging in comparison with surgical findings. *Egypt J Radiol Nucl Med.* 2013;44(4):829-834. doi:10.1016/j.ejnm.2013.08.001
17. Al-Shawi A, Badge R, Bunker T. The detection of full thickness rotator cuff tears using ultrasound. *J Bone Joint Surg Br.* 2008;90(7):889-892. doi:10.1302/301-620x.90b7.20481
18. Day M, Phil M, McCormack RA, Nayyar S, Jazrawi L. Physician training ultrasound and accuracy of diagnosis in rotator cuff tears. *Bull Hosp Jt Dis (2013).* 2016;74(3):207-211.
19. de Jesus JO, Parker L, Frangos AJ, Nazarian LN. Accuracy of MRI, MR arthrography, and ultrasound in the diagnosis of rotator cuff tears: a meta-analysis. *Am J Roentgenol.* 2009;192(6):1701-1707. doi:10.2214/ajr.08.1241
20. Farooqi AS, Lee A, Novikov D, et al. Diagnostic accuracy of ultrasonography for rotator cuff tears: a systematic review and meta-analysis. *Orthop J Sports Med.* 2021;9(10):232596712111035104. doi:10.1177/232596712111035106
21. Elmorsy A, Keightley A, Flannery M. Accuracy of ultrasonography (US) and magnetic resonance imaging (MRI) in detection of rotator cuff tears in district general hospital. *Pol J Radiol.* 2017;82:634-637. doi:10.12659/pjr.903004
22. Iannotti JP, Ciccone J, Buss DD, et al. Accuracy of office-based ultrasonography of the shoulder for the diagnosis of rotator cuff tears. *J Bone Joint Surg Am.* 2005;87(6):1305-1311. doi:10.2106/jbjs.d.02100
23. Okoroha KR, Mehran N, Duncan J, et al. Characterization of rotator cuff tears: Ultrasound versus magnetic resonance imaging. *Orthopedics.* 2017;40(1):e124-e130. doi:10.3928/01477447-20161013-04
24. Rutten MJCM, Spaargaren GJ, van Loon T, de Waal Malefijt MC, Kiemeny LALM, Jager GJ. Detection of rotator cuff tears: the value of MRI following ultrasound. *Eur Radiol.* 2010;20(2):450-457. doi:10.1007/s00330-009-1561-9
25. Sabharwal T, Khanduri S, Khan S, et al. A comparative assessment between high-resolution ultrasonography and field magnetic resonance imaging in supraspinatus tear cases and its arthroscopic correlation. *Cureus.* 2019;11(9):e5627. doi:10.7759/cureus.5627
26. Teefey SA, Rubin DA, Middleton WD, Hildebolt CF, Leibold RA, Yamaguchi K. Detection and quantification of rotator cuff tears. Comparison of ultrasonographic, magnetic resonance imaging, and arthroscopic findings in seventy-one consecutive cases. *J Bone Joint Surg Am.* 2004;86(4):708-716. doi:10.2106/00004623-200404000-00007
27. van Holsbeeck MT, Kolowich PA, Eyler WR, et al. US depiction of partial-thickness tear of the rotator cuff. *Radiology.* 1995;197(2):443-446. doi:10.1148/radiology.197.2.7480690
28. Yazigi Junior JA, Nicolao FA, Matsunaga FT, Archetti Netto N, Matsumoto MH, Tamaoki MJS. Sensitivity and specificity of ultrasonography in diagnosing supraspinatus lesions: a prospective accuracy diagnostic study. *Sao Paulo Med J.* 2018;136(4):292-297. doi:10.1590/1516-3180.2018.0069170418
29. Dinnes J, Loveman E, McIntyre L, Waugh N. The effectiveness of diagnostic tests for the assessment of shoulder pain due to soft tissue disorders: a systematic review. *Health Technol Assess.* 2003;7(29):iii,1-166. doi:10.3310/hta7290
30. Lynch J, Yu CC, Chen C, Muh S. Magnetic resonance imaging versus ultrasound in diagnosis of distal biceps tendon avulsion. *Orthop Traumatol Surg Res.* 2019;105(5):861-866. doi:10.1016/j.otsr.2019.01.021
31. Duan X, Li L, Wei DQ, et al. Role of magnetic resonance imaging versus ultrasound for detection of plantar plate tear. *J Orthop Surg Res.* 2017;12(1):14. doi:10.1186/s13018-016-0507-6
32. Bailowitz Z, Visco CJ, Christen K, Ahmad CS. Diagnostic musculoskeletal ultrasound for the acute evaluation and management of soccer players. *Curr Sports Med Rep.* 2021;20(10):525-530. doi:10.1249/jsr.0000000000000890

33. Robotti G, Draghi F, Bortolotto C, Canepa MG. Ultrasound of sports injuries of the musculoskeletal system: gender differences. *J Ultrasound*. 2020;23(3):279-285. doi:10.1007/s40477-020-00438-x
34. Flavell CA, Marshman LG, Gordon SJ. Measurement of transversus abdominis activation in chronic low back pain patients using a novel standardized real-time ultrasound imaging method. *Ultrasound*. 2019;27(1):31-37. doi:10.1177/1742271x18785403
35. Hodges PW, Pengel LHM, Herbert RD, Gandevia SC. Measurement of muscle contraction with ultrasound imaging. *Muscle Nerve*. 2003;27(6):682-692. doi:10.1002/mus.10375
36. Reeves ND, Maganaris CN, Narici MV. Ultrasonographic assessment of human skeletal muscle size. *Eur J Appl Physiol*. 2004;91(1):116-118. doi:10.1007/s00421-003-0961-9
37. Maganaris CN, Baltzopoulos V, Sargeant AJ. Human calf muscle responses during repeated isometric plantarflexions. *J Biomech*. 2006;39(7):1249-1255. doi:10.1016/j.jbiomech.2005.03.011
38. Sosnowska AJ, Vuckovic A, Gollee H. Automated semi-real-time detection of muscle activity with ultrasound imaging. *Med Biol Eng Comput*. 2021;59(9):1961-1971. doi:10.1007/s11517-021-02407-w
39. Zhou Y, Li JZ, Zhou G, Zheng YP. Dynamic measurement of pennation angle of gastrocnemius muscles during contractions based on ultrasound imaging. *Biomed Eng Online*. 2012;11(1):63. doi:10.1186/1475-925x-11-63
40. Zheng YP, Chan MMF, Shi J, Chen X, Huang QH. Sonomyography: monitoring morphological changes of forearm muscles in actions with the feasibility for the control of powered prosthesis. *Med Eng Phys*. 2006;28(5):405-415. doi:10.1016/j.medengphy.2005.07.012
41. Ricci V, Chang KV, Güvener O, et al. EURO-MUSCULUS/USPRM Dynamic ultrasound protocols for shoulder. *Am J Phys Med Rehabil*. 2022;101(3):e29-e36. doi:10.1097/phm.0000000000001833
42. Ricci V, Güvener O, Chang KV, et al. EURO-MUSCULUS/USPRM Dynamic ultrasound protocols for elbow. *Am J Phys Med Rehabil*. 2022;101(6):e83-e92. doi:10.1097/phm.0000000000001915
43. Mezian K, Ricci V, Güvener O, et al. EURO-MUSCULUS/USPRM Dynamic ultrasound protocols for (adult) hip. *Am J Phys Med Rehabil*. 2022;101(11):e162-e168. doi:10.1097/phm.0000000000002061
44. Mezian K, Ricci V, Güvener O, et al. EURO-MUSCULUS/USPRM Dynamic ultrasound protocols for wrist and hand. *Am J Phys Med Rehabil*. 2022;101(9):e132-e138. doi:10.1097/phm.0000000000002005
45. Garcia JVDC, Takata V, Diaz LEP, Dada Neto F, Santana MVF, Dobashi ET. Efficiency of deep venous thrombosis prevention in proximal femur fractures. *Acta Ortop Bras*. 2022;30(6):e256947. doi:10.1590/1413-785220223006e256947
46. Schafer K, Goldschmidt E, Oostra D, Kaminski B, Mattin M, Lurie F. Defining the role of risk stratification and duplex ultrasound in the diagnosis of acute lower extremity deep vein thrombosis. *J Vasc Surg Venous Lymphat Disord*. 2022;10(5):1021-1027. doi:10.1016/j.jvsv.2022.02.017
47. Yang W, Wang H, Wei Q, et al. Preoperative incidence and risk factors of deep vein thrombosis in patients with an isolated patellar fracture. *BMC Musculoskelet Disord*. 2022;23(1):204. doi:10.1186/s12891-022-05163-6
48. Xiong X, Cheng B. Preoperative risk factors for deep vein thrombosis in knee osteoarthritis patients undergoing total knee arthroplasty. *J Orthop Sci*. 2023;28(1):180-187. doi:10.1016/j.jos.2021.09.016
49. Tan G, Ng M. Emergency department point-of-care ultrasound for upper extremity deep venous thrombosis ED POCUS for upper extremity DVT. *Int J Emerg Med*. 2021;14(1):66. doi:10.1186/s12245-021-00391-4
50. Baksa G, Czeibert K, Sharp V, et al. Vascular supply of the metacarpophalangeal joint. *Front Med*. 2022;9:1015895. doi:10.3389/fmed.2022.1015895
51. Cushman DM, Ross B, Teramoto M, English J, Joyner JR, Bosley J. Identification of knee effusions with ultrasound: a comparison of three methods. *Clin J Sport Med*. 2022;32(1):e19-e22. doi:10.1097/jsm.0000000000000823
52. Newman JS, Adler RS, Bude RO, Rubin JM. Detection of soft-tissue hyperemia: value of power Doppler sonography. *Am J Roentgenol*. 1994;163(2):385-389. doi:10.2214/ajr.163.2.8037037



53. Bredahl WH, Newman JS, Taljanovic MS, Adler RS. Power Doppler sonography in the assessment of musculoskeletal fluid collections. *Am J Roentgenol*. 1996;166(6):1443-1446. doi:10.2214/ajr.166.6.8633460
54. Hides JA, Mendis MD, Franettovich Smith MM, Miokovic T, Cooper A, Low Choy N. Association between altered motor control of trunk muscles and head and neck injuries in elite footballers – An exploratory study. *Man Ther*. 2016;24:46-51. doi:10.1016/j.math.2016.05.001
55. Hides JA, Stanton WR. Predicting football injuries using size and ratio of the multifidus and quadratus lumborum muscles. *Scand J Med Sci Sports*. 2017;27(4):440-447. doi:10.1111/sms.12643
56. Dietz HP, Wilson PD, Clarke B. The use of perineal ultrasound to quantify levator activity and teach pelvic floor muscle exercises. *Int Urogynecol J*. 2001;12(3):166-168; discussion 168-169. doi:10.1007/s001920170059
57. Gu X, Yang M, Liu F, Liu D, Shi F. Effects of adding ultrasound biofeedback to individualized pelvic floor muscle training on extensibility of the pelvic floor muscle and anterior pelvic organ prolapse in postmenopausal women. *Contrast Media Mol Imaging*. 2022;2022:4818011. doi:10.1155/2022/4818011
58. Sillevs R, Shamus E, Mouttet B. The management of plantar fasciitis with a musculoskeletal ultrasound imaging guided approach for instrument assisted soft tissue mobilization in a runner: a case report. *Int J Sports Phys Ther*. 2020;15(2):274-286. doi:10.26603/ijsp20200274
59. Bağcıer F, Tufanoğlu FH. A new treatment modality in piriformis syndrome: Ultrasound guided dry needling treatment. *Agri J Turk Soc Algol*. 2020;32(3):175-176. doi:10.14744/agri.2019.92170
60. Vas L. Ultrasound guided dry needling: Relevance in chronic pain. *J Postgrad Med*. 2022;68(1):1-9. doi:10.4103/jpgm.jpgm\_710\_21
61. Stieven FF, Ferreira GE, Wiebusch M, de Araújo FX, da Rosa LHT, Silva MF. Dry needling combined with guideline-based physical therapy provides no added benefit in the management of chronic neck pain: a randomized controlled trial. *J Orthop Sports Phys Ther*. 2020;50(8):447-454. doi:10.2519/jospt.2020.9389
62. Courseault J, Kessler E, Moran A, Labbe A. Fascial hydrodissection for chronic hamstring injury. *Curr Sports Med Rep*. 2019;18(11):416-420. doi:10.1249/jsr.0000000000000650
63. Kaga M, Ueda T. Effectiveness of hydro-dissection of the piriformis muscle plus low-dose local anesthetic injection for piriformis syndrome: a report of 2 cases. *Am J Case Rep*. 2022;23:e935346. doi:10.12659/ajcr.935346
64. Kaga M. First case of occipital neuralgia treated by fascial hydrodissection. *Am J Case Rep*. 2022;23:e936475. doi:10.12659/ajcr.936475
65. Cronin K, Foley S, Cournane S, De Vito G, Delahunty E. Hamstring muscle architecture assessed sonographically using wide field of view: A reliability study. *PLoS One*. 2022;17(11):e0277400. doi:10.1371/journal.pone.0277400
66. Hammond K, Mampilly J, Laghi FA, et al. Validity and reliability of rectus femoris ultrasound measurements: Comparison of curved-array and linear-array transducers. *J Rehabil Res Dev*. 2014;51(7):1155-1164. doi:10.1682/jrrd.2013.08.0187
67. Hogenbirk RNM, Viddeleer AR, Hentzen JEK, et al. Thickness of biceps and quadriceps femoris muscle measured using point-of-care ultrasound as a representation of total skeletal muscle mass. *J Clin Med*. 2022;11(22):6606. doi:10.3390/jcm11226606
68. Madden KM, Feldman B, Arishenkoff S, Meneilly GS. A rapid point-of-care ultrasound marker for muscle mass and muscle strength in older adults. *Age Ageing*. 2021;50(2):505-510. doi:10.1093/ageing/afaa163
69. Nijholt W, Scafoglieri A, Jager-Wittenaar H, Hobbelen JSM, van der Schans CP. The reliability and validity of ultrasound to quantify muscles in older adults: a systematic review. *J Cachexia Sarcopenia Muscle*. 2017;8(5):702-712. doi:10.1002/jcsm.12210
70. Park J, Kim YH, Choi WJ, et al. The value of the peroneus brevis tendon cross-sectional area in early diagnosing of peroneus brevis tendinitis: The peroneus brevis tendon cross-sectional area. *Medicine (Baltimore)*. 2022;101(43):e31276. doi:10.1097/md.00000000000031276
71. Yoshimura A, Kunugi S, Hirono T, et al. Association of muscle strength with muscle thickness and motor unit firing pattern of vastus lateralis muscle in youth athletes. *Int J Sports Physiol Perform*. 2022;17(12):1725-1731. doi:10.1123/ijsp.2022-0094
72. Pinto MD, Pinto RS, Nosaka K, Blazevich AJ. Do intramuscular temperature and fascicle angle affect ultrasound echo intensity values? *Med Sci Sports Exerc*. Published online November 9, 2022. doi:10.1249/mss.0000000000003082

73. Koppenhaver SL, Hebert JJ, Parent EC, Fritz JM. Rehabilitative ultrasound imaging is a valid measure of trunk muscle size and activation during most isometric sub-maximal contractions: a systematic review. *Aust J Physiother.* 2009;55(3):153-169. doi:10.1016/s0004-9514(09)70076-5
74. Pirri C, Pirri N, Guidolin D, Macchi V, De Caro R, Stecco C. Ultrasound imaging of the superficial fascia in the upper limb: arm and forearm. *Diagnostics.* 2022;12(8):1884. doi:10.3390/diagnostics12081884
75. Pirri C, Guidolin D, Fede C, Macchi V, De Caro R, Stecco C. Ultrasound imaging of brachial and antebrachial fasciae. *Diagnostics.* 2021;11(12):2261. doi:10.3390/diagnostics11122261
76. Pirri C, Pirri N, Porzionato A, Boscolo-Berto R, De Caro R, Stecco C. Inter- and intra-rater reliability of ultrasound measurements of superficial and deep fasciae thickness in upper limb. *Diagnostics.* 2022;12(9):2195. doi:10.3390/diagnostics12092195
77. Coombes BK, Ziegenfuss B, David M, et al. Heterogeneity of passive elastic properties within the quadriceps femoris muscle–tendon unit. *Eur J Appl Physiol.* 2018;118(1):213-221. doi:10.1007/s00421-017-3763-1
78. Ebihara B, Mutsuzaki H, Fukaya T. Relationships between quadriceps tendon elasticity and knee flexion angle in young healthy adults. *Med Kaunas Lith.* 2019;55(2):53. doi:10.3390/medicina55020053
79. Mannarino P, Matta TT da, Oliveira LF de. An 8-week resistance training protocol is effective in adapting quadriceps but not patellar tendon shear modulus measured by Shear Wave Elastography. *PLoS One.* 2019;14(4):e0205782. doi:10.1371/journal.pone.0205782
80. Ozcan ANS, Tan S, Tangal NG, et al. Real-time sonoelastography of the patellar and quadriceps tendons: pattern description in professional athletes and healthy volunteers. *Med Ultrason.* 2016;18(3):299-304. doi:10.11152/mu.2013.2066.183.ays
81. Zardi EM, Franceschetti E, Giorgi C, Palumbo A, Franceschi F. Reliability of quantitative point shear-wave ultrasound elastography on vastus medialis muscle and quadriceps and patellar tendons. *Med Ultrason.* 2019;21(1):50-55. doi:10.11152/mu-1712
82. Li S, McDicken WN, Hoskins PR. Blood vessel diameter measurement by ultrasound. *Physiol Meas.* 1993;14(3):291-297. doi:10.1088/0967-3334/14/3/007
83. Rådegran G. Ultrasound Doppler estimates of femoral artery blood flow during dynamic knee extensor exercise in humans. *J Appl Physiol.* 1997;83(4):1383-1388. doi:10.1152/jappl.1997.83.4.1383
84. Bradley M, O'Donnell P. *Atlas of Musculoskeletal Ultrasound Anatomy.* 2nd ed. Cambridge University Press; 2010. doi:10.1017/cbo9780511691782
85. Rawat M. *Atlas of Musculoskeletal Ultrasound of the Extremities.* SLACK Incorporated; 2020.
86. Strakowski JA. *Introduction to Musculoskeletal Ultrasound: Getting Started.* Demos Medical; 2016. doi:10.1891/9781617052309