

Introducing a Removable Orthodontic Appliance and Its Effects on Dental Arch Dimensions

Yasaman Bozorgnia¹, Shahin Mafinezhad², Pardis Pilehvar³, Soheil Salari⁴

ABSTRACT

Introduction: Guiding anterior crossbite to a normal position is one of the most important responsibilities of a pediatric dentist or orthodontist to gain both esthetic and function. Crossbite with dental etiology can be treated by a variety of appliances. We describe a removable appliance with a different spring design for proclination of more than one incisor in mixed dentition.

Materials and methods: This study is an observational study that was performed on sixteen children, 7–11 years of age, who needed incisor proclination in more than one tooth. In this study, patients were followed until the end of their orthodontic therapy. The variables evaluated were the maxillary arch length, arch depth, intercanine distance, and intermolar distance in pre- and posttreatment. To assess intra-examiner reliability, 10 plaster models were randomly selected and re-measured.

Results: In all the cases, the newly designed removable appliance was used and in all showed a significant increase in arch length, arch depth, intercanine distance, and intermolar distance. The correction was achieved within 1–9 months depending on the patient's compliance.

Conclusion: There was a significant increase in all aspects of arch length and depth after using this appliance. The procedure is a simple and effective method that is recommended for compliant patients needing proclination of more than one anterior tooth; especially in dental class III, pseudo-class III patients, and the first phase of class II division 2 skeletal treatments.

Keywords: Anterior dental crossbite, Malocclusion, Mixed dentition.

International Journal of Clinical Pediatric Dentistry (2021): 10.5005/jp-journals-10005-2023

INTRODUCTION

Guiding anterior crossbite to a normal position is one of the most important responsibilities of a pediatric dentist or orthodontist to gain both esthetic and function.¹ American Association of Orthodontist defines crossbite as: An abnormal relationship of tooth or teeth to the opposing tooth or teeth in which normal buccolingual or labiolingual relationships are reversed.² Prevalence of anterior crossbite which becomes evident during the mixed dentition has been reported from 4.5 to 9.5%.^{3–6}

Anterior crossbite is categorized based on the nature of the crossbite into skeletal, dental, and functional entities.⁷ Skeletal anterior crossbite is influenced by genetics with a discrepancy in the size of the maxilla and mandible. The anterior segment of maxillary teeth is proclined but they are positioned behind the mandibular incisors. In a dental anterior crossbite, one or two teeth are often upright or retroclined without any significant skeletal discrepancy. In the functional-type crossbite, due to premature contact between the opposing tooth/teeth, there is a shift in the mandible to the sides or anterior, that can cause pseudo-class-III.⁸

Many factors may lead to the development of anterior crossbite. But with any etiology, treatment of the crossbite is always indicated. There are modalities of treatment for anterior crossbites depending on the etiology of the crossbite, patient's compliance, age and amount of teeth eruption, and space availability.⁷ The optimum age to treat anterior crossbite is between 8 and 11 years when the root is being formed and the tooth is in the active stage of eruption.⁹ Early treatment aims to decrease skeletal, dentoalveolar, and muscular problems by the end of permanent dentition. Successful correction of crossbite in mixed dentition occurred in 84–100% of cases.¹⁰ Relapse after gaining normal overjet/overbite relationship is usually unlikely.¹¹

¹Department of Orthodontics, North Khorasan University of Medical Sciences, Bojnurd, Iran

²Department of Pediatrics, North Khorasan University of Medical Sciences, Bojnurd, Iran

³Student Research Committee, Department of Orthodontics, North Khorasan University of Medical Sciences, Bojnurd, Iran

⁴Department of Orthodontics, Aja University of Medical Sciences, Tehran, Iran

Corresponding Author: Shahin Mafinezhad, Department of Pediatrics, North Khorasan University of Medical Sciences, Bojnurd, Iran, Phone: +98 9153101504, e-mail: shahinmaf@yahoo.com

How to cite this article: Bozorgnia Y, Mafinezhad S, Pilehvar P. Introducing a Removable Orthodontic Appliance and Its Effects on Dental Arch Dimensions. *Int J Clin Pediatr Dent* 2021;14(S-1):S39–S43.

Source of support: This work was supported by the North Khorasan University of Medical Sciences, Bojnurd, Iran (Grant No. 97/P/56).

Conflict of interest: None

Crossbite with dental etiology can be treated by a variety of appliances like Catlan's appliance, reversed stainless steel crowns, multiple sets of Essix-based appliances, fixed acrylic inclined planes, bonded resin-composite slopes, Bruckl appliance, tongue blades, removable appliances with z-springs or expansion screws or miniscrews, and short-span wire-fixed orthodontic appliances and for skeletal reasons we can use a facemask, chin cup, and Frankel III appliances.^{12–25} Removable appliances are easy to clean, tolerated well, and comfortable. Also, they are not expensive and do not cause any damage to the soft tissue.^{26,27}

This study presents a designed appliance (Yas appliance) to procline more than one tooth simultaneously. It can be used in

compliant patients that have anterior dental crossbite with more than one tooth, pseudo-class III or it can be used in the first phase of skeletal class II division 2 to make enough overjet, mild anterior crowding.

MATERIALS AND METHODS

Patients and Study Design

This study is an observational study that was performed on 16 children, 7–11 years of age, who needed incisor proclination in more than one tooth. The patients were selected from the Dental Clinic of the North Khorasan University of Bojnurd, and they were followed until the end of their orthodontic therapy.

The study protocol was approved by the ethics committee of Bojnurd University of Medical Sciences, Iran (code: IR.NKUMS REC.1397.054). All the patients were informed about the study and informed consent was obtained from their parents.

Sample Collection

The selection of the participants was from a large pool of subjects that were referred to North Khorasan Dental University in 2017. Inclusion criteria were defined as:

(1) Presence of the first permanent molar tooth, (2) cases who need proclination of more than one incisor tooth (same as pseudo-class 3 or anterior crossbite of more than one tooth, cases with class II division 2 and mild incisors crowding <2 mm), (3) healthy cases with normal physical examination, (4) non-skeletal class III malocclusion, (5) cases without history of previous orthodontics treatment, (6) an absence of oral disease, (7) the presence of casts before and after treatment. Complete records including cephalometric and panoramic radiographs with the use of the same cephalostat by the same operator; extraoral and intraoral photographs; and plaster models prepared from alginate impressions, were collected.

Measurements were made on the initial casts by the same clinician using a fine-tip digital caliper (MitutoyoDigimatic NTD12-6°C; Mitutoyo Corp., Tokyo, Japan).

In all the cases, a removable acrylic appliance with long span spring behind the retroclined teeth was used and it was continued until the acceptable arch alignment was obtained. All the children were motivated to maintain good oral hygiene. An incorporated spring in the appliance was made of 0.7-mm four-helix stainless

steel (Yas appliance) which was activated based on the tooth that was in contact with the spring (Fig. 1).

At the end of treatment, full records were taken. Changes in the arch perimeter, arch depth, intercanine, and intermolar widths were recorded from dental casts, which were taken before and after treatment. Measurements were included:

- *Intermolar width*—the distance between the mesiobuccal cusp tip points of the first permanent molars.
- *Intercanine width*—the distance between the tips of the cusp from canine to canine.
- *Arch length (depth)*—the distance from the line perpendicular to the mesiobuccal cusp tips of the first permanent molars to the midpoint between the mesioincisal points of the central incisors.
- *Arch perimeter*—the distance from mesial contact of a permanent molar on one side to the mesial contact of a permanent molar on the other side, with the line connecting the buccal/incisor tip points in the intervening teeth.

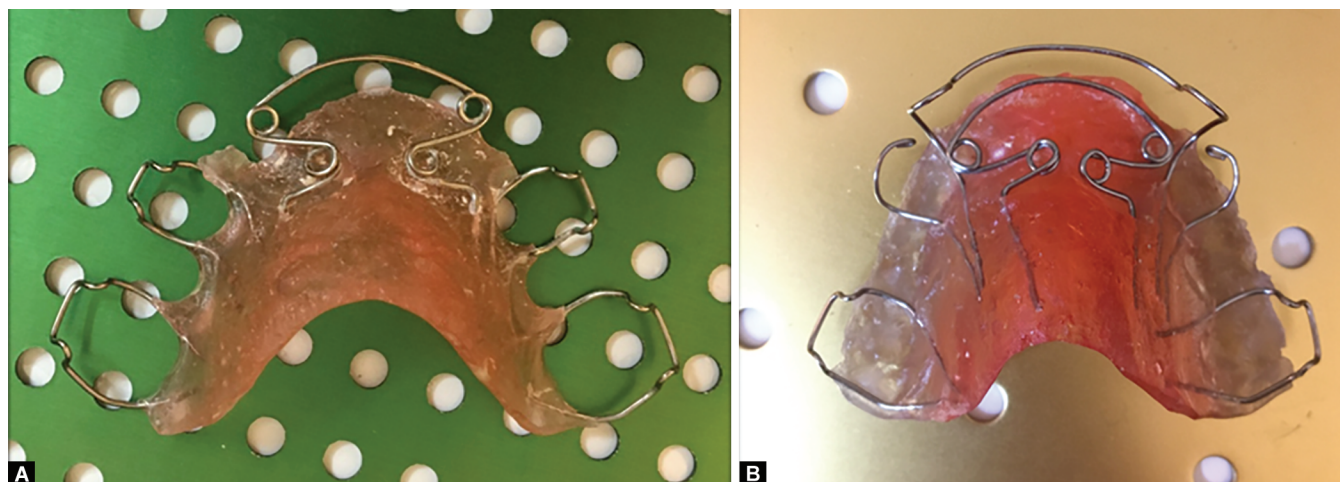
To assess intra-examiner reliability, 10 plaster models were randomly selected. The arch perimeter, arch depth, intercanine, and intermolar widths were re-measured on the dental casts. The reproducibility of the measurements was investigated with a paired *t*-test for each variable.

STATISTICAL ANALYSIS

Statistical analysis was conducted using the SPSS 25. The application of the Shapiro–Wilk test demonstrated that the data were normally distributed. Therefore, parametric tests were used. The analysis of the data included Student's *t*-test; paired *t*-test was used to evaluate the changes before treatment (T1) and after treatment (T2). *p* values of <0.05 were considered statistically significant.

RESULTS

The average age of the children in our study was 9.69 ± 0.946 years. Treatment duration was recorded 4.94 months (± 2.205) and all the cases completed their treatments. Comparisons between the pre- and posttreatment measures are displayed in Table 1. We found a significant increase in arch perimeter ($p < 0.001$), arch depth ($p < 0.001$), maxillary intercanine distance ($p = 0.006$), and intermolar distance ($p = 0.004$) before and after treatment.



Figs 1A and B: Yas appliance

In these 16 patients (12 girls and 4 boys), 3 had mild anterior crowding, 2 had retroclined teeth due to skeletal class II division 2, 5 patients had anterior crossbite more than one tooth, and 6 patients were pseudo-class III. The appliance was worn full time except while eating and brushing (Figs 2 and 3).

DISCUSSION

One of the main goals of pediatric dentistry is to keep arch integrity to allow the eruption of permanent teeth simultaneous with the prevention of malocclusion. Anterior dental crossbite is a rare condition that is of major esthetic and functional concern to children and parents that seldomly corrects itself.²⁸

Crossbite may also be corrected using a reversed prefabricated stainless steel crown, which is durable and has low cost, and does not need patient compliance. The main disadvantage with

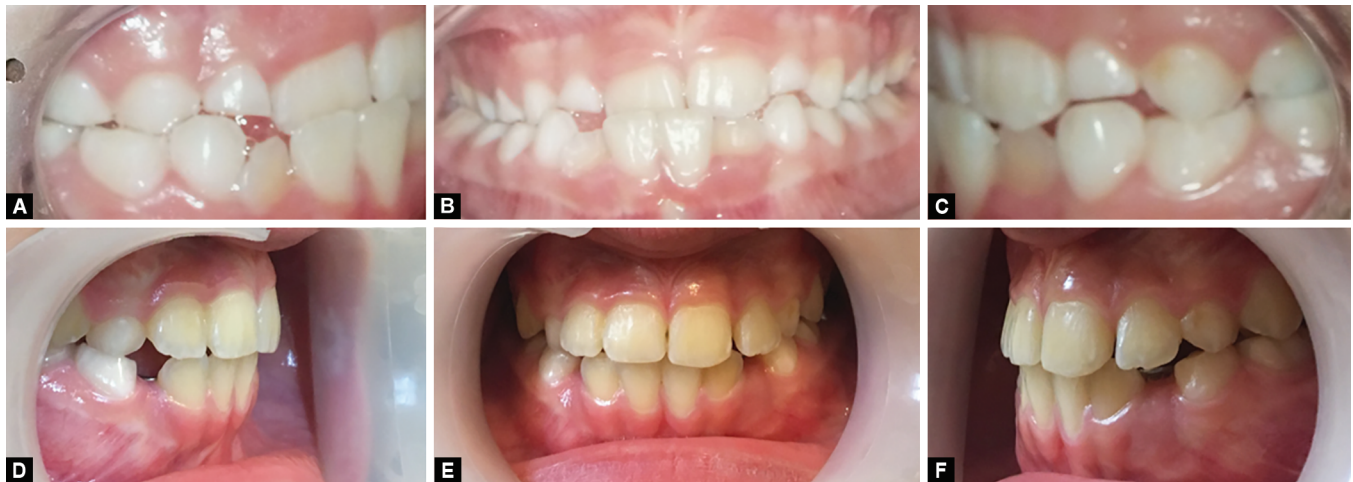this treatment is difficulty in adapting a preformed crown to fit the tooth in crossbite. The duration that the patients spend on the dental unit is long. Furthermore, because of its unaesthetic appearance, this form of treatment is often rejected by children and their relatives. This method was not chosen for our patients due to these disadvantages.²⁹

Also, composite inclined plane, which does not require laboratory procedures, does not cause pain, and is esthetically acceptable, was not used in our patients. These appliances are costly, the duration of the application may be long, it may affect patient's psychology negatively, it cannot be used in cases where the anterior crossbite involves more than one-third of the crown height, and it may lead to gum problems as well as tooth structure loss while removing from teeth at the end of the treatment.^{28,30}

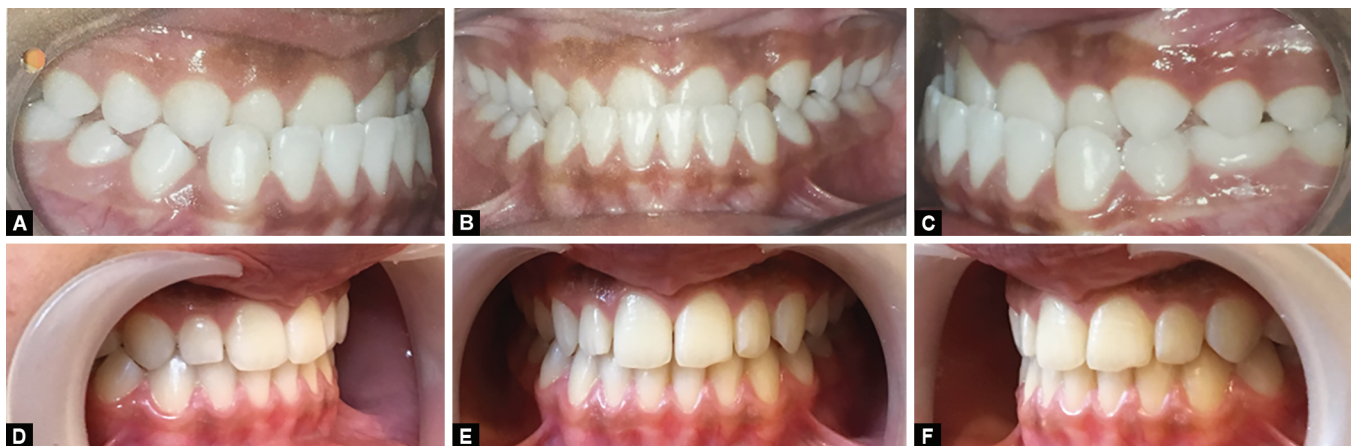In the Ulusoy study, a removable acrylic appliance with a bite plate incorporating a screw was used to correct the anterior dental crossbite and align the incisors. The subsequent eruption of the maxillary left lateral incisor on the palatal side was treated with a second acrylic plate incorporating a labiolingual spring. Ulusoy et al. studied 8-year-old cases and reported that teeth with crossbite were correctly positioned after 4 months. They believed that it is a highly effective, manageable, easily usable method that did not harm the soft tissues and was applied to children of early ages. They suggested that a removable appliance with a screw may be considered the first choice of treatment to correct anterior dental

Table 1: Dental arch dimensions pre- and posttreatment

	T1 (mean ± STD)	T2 (mean ± STD)	p value
Intermolar width	49.33 ± 2.03	49.6 ± 2.07	<0.006
Intercanine width	31.28 ± 2.03	21.21 ± 2.08	<0.004
Arch length (depth)	26.76 ± 1	28.54 ± 1	<0.001
Arch perimeter	77.48 ± 2.6	79.56 ± 2.9	<0.001



Figs 2A to F: Dental crossbite more than one tooth before and after treatment by Yas appliance



Figs 3A to F: Pseudo-class III patient; before and after treatment by Yas appliance

crossbite of more than one incisor, whereas a removable appliance with a labiolingual spring may be considered the first choice of treatment for correction of crossbite of one incisor tooth.³¹

One of the Yas appliance benefits is that with only one appliance you can correct centrals first and if the laterals erupt in a crossbite position, the spring can be pushed back and repositioned behind the laterals to correct the lateral crossbite as well. Therefore, the appliance needs only one-time fabrication in the laboratory which makes it less expensive and less time-consuming.

Also, in our study, we used springs that produce nearly optimum light continuous forces for proclining the incisor teeth, in contrast with the heavy rapidly decaying forces produced by a screw. The rapid reactivation of the appliance with a screw has the potential of damaging the teeth and if the force becomes too high, the appliance is likely to be displaced. Multiple z-springs also can be distorted and cause patient discomfort.

The duration of treatment in the individuals from the current study was between 2 and 9 months (mean 4.94, STD 2.205). Longer duration in some of our cases was due to less cooperation in using the appliance, but for the ones who were compliant, the duration was less.

It is well-known that when therapy with removable appliances is prescribed, patient compliance is a determining factor in the efficiency of treatment.³¹

Another advantage of Yas appliance is that it can be used as a retention appliance after the active treatment is completed. In cases where there is a premature loss of a primary tooth, it can be used as a removable partial denture by adding an acrylic tooth. Posterior bite plates can be added so they can be used for even 100% overbites.

Due to limitations of working on pediatric patients and the potential psychological problems that may arise from a fixed oral system, the Yas appliance was fitted with a designated spring to achieve labial movement of multiple teeth. The patients did not report any discomfort during the course of the treatment or oral hygiene achievement. Treatment resulted in a successful correction of the malocclusion, healthy gums, and an esthetic smile.

CONCLUSION

Yas appliance is a good option for compliant patients whose teeth need proclination of more than one anterior tooth, especially in pseudo-class III patients, anterior dental crossbites more than one tooth, and the first phase of class II division 2 skeletal treatments and mild anterior crowding. The appliance is tolerable, cost-effective, and corrects the teeth positions with a light continuous force.

ETHICAL APPROVAL

The present study has been approved by the Ethics Committee of North Khorasan University of Medical Sciences, Bojnurd, Iran (code: IR.NKUMS REC.1397.054).

AVAILABILITY OF DATA AND MATERIAL

The datasets used during the current study are available from the corresponding author on reasonable request.

AUTHORS' CONTRIBUTIONS

The author who conceived the study: Yasaman Bozorgnia. Authors who designed the study: Yasaman Bozorgnia, Authors who

performed the experiments: Yasaman Bozorgnia. Authors who performed statistical analyzes: Shahin Mafnezhad. Authors who prepared the manuscript: Shahin Mafnezhad, Pardis Pilehvar. All authors read and approved the final manuscript.

ACKNOWLEDGMENTS

We extend our gratitude to the clinic of orthodontics in North Khorasan University of medical science for cooperation in our study.

REFERENCES

1. Al-Sahaibany F, White G. A three dimensional clinical approach for anterior crossbite treatment in early mixed dentition using an ultrablock appliance: case report. *J Clin Pediatr Dent* 1998;23(1):1-7.
2. American Association of Orthodontists. 2012. https://www.aaoinfo.org/system/files/media/documents/2012_AAO_Glossary_0.doc.
3. Shalish M, Gal A, Brin I, et al. Prevalence of dental features that indicate a need for early orthodontic treatment. *Eur J Orthod* 2013;35(4):454-459. DOI: 10.1093/ejo/cjs011.
4. Reddy ER, Manjula M, Sreelakshmi N, et al. Prevalence of malocclusion among 6 to 10 year old Nalgonda school children. *J Int Oral Health* 2013;5(6):49-54.
5. Kaur H, Pavithra US, Abraham R. Prevalence of malocclusion among adolescents in South Indian population. *J Int Soc Prev Community Dent* 2013;3(2):97-102. DOI: 10.4103/2231-0762.122453.
6. Singh SP, Kumar V, Narboo P. Prevalence of malocclusion among children and adolescents in various school of Leh Region. *J Orth Endo* 2015;1:1-6.
7. Singh G. Management of crossbite. In: *Textbook of orthodontics*. New Delhi, India: Jaypee Publisher; 2015. pp. 655-670.
8. Ustun K, Sari Z, Orucoglu H, et al. Severe gingival recession caused by traumatic occlusion and mucogingival stress: a case report. *Eur J Dent* 2008;2(2):127-133. DOI: 10.1055/s-0039-1697367.
9. Kiyak HA. Patients' and parents' expectations from early treatment. *Am J Orthod Dentofacial Orthop* 2006;129(4 Suppl):50-54. DOI: 10.1016/j.ajodo.2005.09.018.
10. Thilander B, Lennartsson B. A study of children with unilateral posterior crossbite, treated and untreated, in the deciduous dentition. Occlusal and skeletal characteristics of significance in predicting the long-term outcome. *J Orofac Orthop* 2002;63(5):371-383. DOI: 10.1007/s00056-002-0210-6.
11. Croll TP. Fixed inclined plane correction of anterior crossbite of the primary dentition. *J Pedod* 1984;9(1):84-94.
12. Valentine F, Howitt JW. Implications of early anterior crossbite correction. *ASDC J Dent Child* 1970;37(5):420-427.
13. Olsen CB. Anterior crossbite correction in uncooperative or disabled children. *Case reports Aust Dent J* 1996;41(5):304-309. DOI: 10.1111/j.1834-7819.1996.tb03138.x.
14. Mckeown HF, Sandler J. The two by four appliance: a versatile appliance. *Dent Update* 2001;28(10):496-500. DOI: 10.12968/denu.2001.28.10.496.
15. Major PW, Glover K. Treatment of anterior cross-bites in the early mixed dentition. *J Can Dent Assoc* 1992;58(7):574-575.
16. Yaseen SM, Acharya R. Hexa helix: modified quad helix appliance to correct anterior and posterior crossbites in mixed dentition. *Case Rep Dent* 2012;2012:860385. DOI: 10.1155/2012/860385.
17. Ulusoy AT, Bodrumlu EH. Management of anterior dental crossbite with removable appliances. *Contemp Clin Dent* 2013;4(2):223-226. DOI: 10.4103/0976-237X.114855.
18. Jirgensone I, Liepa A, Abeltins A. Anterior crossbite correction in primary and mixed dentition with removable inclined plane (Bruckl appliance). *Stomatologija* 2008;10(4):140-144.
19. Bayrak S, Tunc ES. Treatment of anterior dental crossbite using bonded resin-composite slopes: case reports. *Eur J Dent* 2008;2(4):303-306. DOI: 10.1055/s-0039-1697397.

20. Prakash P, Durgesh BH. Anterior crossbite correction in early mixed dentition period using catlan's appliance: a case report. *ISRN Dent* 2011;2011:298931. DOI: 10.5402/2011/298931.
21. Abraham K, James A, Thenumkal E, et al. Correction of anterior crossbite using modified transparent aligners: an esthetic approach. *Contemp Clin Dentis* 2016;7(3):394–397. DOI: 10.4103/0976-237X.188577.
22. Dean JA. Managing the developing occlusion. In: McDonald and Avery's dentistry for the child and adolescent. St. Louis, Mo, USA: Elsevier Publication; 2016. p. 415–478.
23. Giancotti A, Mozzicato P, Mampieri G. An alternative technique in the treatment of anterior cross bite in a case of Nickel allergy: a case report. *Eur J Paediatr Dent* 2011;12(1):60–62.
24. Sunil MM, Zareena MA, Ratheesh MS, et al. Early orthodontic interception of anterior crossbite in mixed dentition. *JIOH* 2017;9:88–90.
25. Sockalingam SNMP, Khan KAM, Kuppusamy E. Interceptive correction of anterior crossbite using short-span wire-fixed orthodontic appliance: a report of three cases. *Case Rep Dent* 2018;2018:4323945. DOI: 10.1155/2018/4323945.
26. Park JH, Kim TW. Anterior crossbite correction with a series of clear removable appliances: a case report. *J Esthet Restor Dent* 2009;21(3):149–159. DOI: 10.1111/j.1708-8240.2009.00257.x.
27. Sari S, Gokalp H, Aras S. Correction of anterior dental crossbite with composite as an inclined plane. *Int J Paediatr Dent* 2001;11(3):201–208. DOI: 10.1046/j.1365-263x.2001.00256.x.
28. Croll TP. Correction of anterior tooth crossbite with bonded resin-composite slopes. *Quintessence Int* 1996;27(1):7–10.
29. Croll TP, Riesenberger RE. Anterior crossbite correction in the primary dentition using fixed inclined planes. II. Further examples and discussion. *Quintessence Int* 1988;19(1):45–51.
30. Borrie F, Bearn D. Early correction of anterior crossbites: a systematic review. *J Orthod* 2011;38(3):175–184. DOI: 10.1179/14653121141443.
31. Casutt C, Pancherz H, Gawora M, et al. Success rate and efficiency of activator treatment. *Eur J Orthod* 2007;29(6):614–621. DOI: 10.1093/ejo/cjm066.