

SYNOVIAL GIANT CELL TUMOR OF THE KNEE

Rene Jorge Abdalla¹, Moisés Cohen², Jezimar Nóbrega³, Andrea Forgas⁴

ABSTRACT

Synovial giant cell tumor is a benign neoplasm, rarely reported in the form of malignant metastasis. Synovial giant cell tumor most frequently occurs on the hand, and, most uncommon, on the ankle and knee. In the present study, the authors describe a rare case of synovial giant cell tumor on the knee as well as the treatment approach. Arthroscopy

has been shown, in this case, to be the optimal method for treating this kind of lesion, once it allowed a less aggressive approach, while providing good visualization of all compartments of knee joint and full tumor resection.

Keywords – *Knee; Giant cell tumor; Synovial; Neoplasm*

INTRODUCTION

Definition

Pigmented villonodular synovitis is a condition that only affects synovial joints. It can present in a diffuse or nodular (localized) form, resembling a neoplasm. It is not known if this disease is a true neoplasm or an illness of reactive origin, but the latest evidence of monoclonality suggest a neoplastic etiology⁽¹⁾.

The disease can occur in young adults and the elderly and most commonly presents with symptoms related to the intra-articular nature of the mass⁽²⁾.

The knee is the most commonly involved joint, but it can occur in any synovial joint, including the hip, ankle, shoulder, or elbow. A polyarticular form has also been reported in children^(1,3).

EXAMINATION

During the examination evidence of effusion or hemarthrosis can be found when minor trauma re-

sulting in bleeding. In the localized type, block is common due to the presence of an intra-articular mass, and in both the diffuse and localized form, there is a limited arc of movement. A palpable mass is usually not seen, unless there are extra-articular manifestations of the disease. More commonly, the extra-articular disease occurs in the popliteal fossa or in the intercondylar region. In advanced cases, degenerative arthritis is evident^(1,3,4).

IMAGE

In the initial stage of the disease, the findings of plain radiographs are normal or reveal a dislocated suprapatellar fatty plane due to joint effusion. The findings of magnetic resonance imaging are more significant. A soft tissue mass with alternating gap areas of light and dark signals on the T1 and T2 sequences represent the accumulation of fluid (light on T2) and fat (light on T1), and hemosiderin deposits in soft tissue (dark in both T1 and T2), respectively⁽³⁾.

1 – Doctor's degree in Traumatology and Orthopedics; Professor, Department of Orthopedics and Traumatology, UNIFESP/EPM, São Paulo, Brazil.

2 – Lecturer; Head, Division of Sports Traumatology, Department of Orthopedics and Traumatology, UNIFESP/EPM, São Paulo, Brazil.

3 – Orthopedist, Sports Orthopedics and Rehabilitation Center (Cecore), Hospital do Coração, São Paulo, Brazil.

4 – Post-graduate Student, Department of Orthopedics and Traumatology, School of Medicine, Universidade de São Paulo, São Paulo, Brazil.

Study conducted at the Center for Studies of the Sports Orthopedics and Rehabilitation Center, Hospital do Coração.

Correspondence: Andréa Forgas, Rua Abílio Soares, 227, cj. 31 – 04005-000 – São Paulo, SP, Brasil. E-mail: deaforgas@gmail.com

We declare no conflict of interest in this article

HISTOLOGY

Histologically, focal pigmented villonodular synovitis is indistinguishable from a giant cell tumor of the tendon sheath. A proliferation of rounded synovial cells is present with occasional multinucleated giant osteoclast cells, xanthomatous cells, and inflammatory cells interspersed throughout the lesion⁽²⁾.

TREATMENT

The main form of treatment is surgical excision, either open or arthroscopic. No conservative therapy is considered effective in eradicating the disease. If left untreated, some patients develop stable disease, but most require treatment for symptoms or to prevent progression to the eventual formation of an erosive periarticular cyst and the subsequent destruction of cartilaginous joint surface.

In about a third of cases, aggressive evolution can occur with multiple recurrences, despite surgical resection. In such cases, the use of radiation can be considered and administered, either through an external bundle of rays or synovectomy through intra-articular radiation. Once joint destruction has occurred, total knee arthroplasty is the treatment for the disabling symptoms; however, a synovectomy should still be performed, since recurrences after total knee arthroplasty have been described⁽⁵⁾.

CLINICAL CASE

The female patient RFM, 36 years of age, regularly exercising at the gym, reported during a consultation that six months before she was feeling fine when she insidiously began to experience occasional pain in her left knee during moderate exercise. The symptoms were accompanied by a popping feeling, locking episodes, and occasional cracking.

There were no palpable masses during the clinical examination; the range of motion was between 0° and 130°. Pain was present on palpation of the medial joint interline and there were no signs of instability.

Radiographic study and MRI of the knee were performed. The clinical examination revealed normal radiographs (Figure 1), and magnetic resonance imaging revealed a nodular image in the deep portion

of the Hoffa fat pad between the transverse ligament and the anterior cruciate ligament, measuring 1.8 x 1.3 cm (Figure 2A, 2B, and 2C).

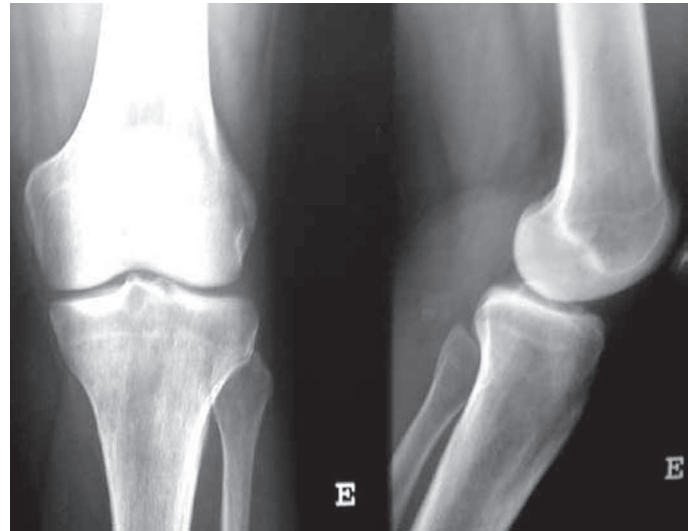

Figure 1 – Radiograph of the left knee showing no changes.

After evaluation of the clinical and imaging exams, the patient underwent arthroscopic resection of the nodule, using standard portals.

Some red-brown nodular synovial tissue fixed to the tibial plateau by a pedicle (Figure 3) was observed during arthroscopy. There were no other associated injuries.

A pressure dressing was maintained during the first few days, followed by exercises for range of motion. Immediate weight-bearing was allowed according to what could be tolerated.

Anatomopathological examination showed fibrous nodular proliferation with numerous giant cells interspersed, numerous histiocytes in the midst of dense fibrous tissue and focal deposits of fibrin and hemosiderin.

A supervised program of physical therapy was instituted after hospital discharge and the patient continued with a home program. There were no restrictions on weight-bearing or crutches used. Strengthening was started immediately with resistance exercises. After two months of physical therapy, the patient returned to her habitual activities, with regression of the pain and the sensation of instability. The locking episodes did not return.

After a period of six months, MRI was repeated, in which signs of local recurrence were not observed.

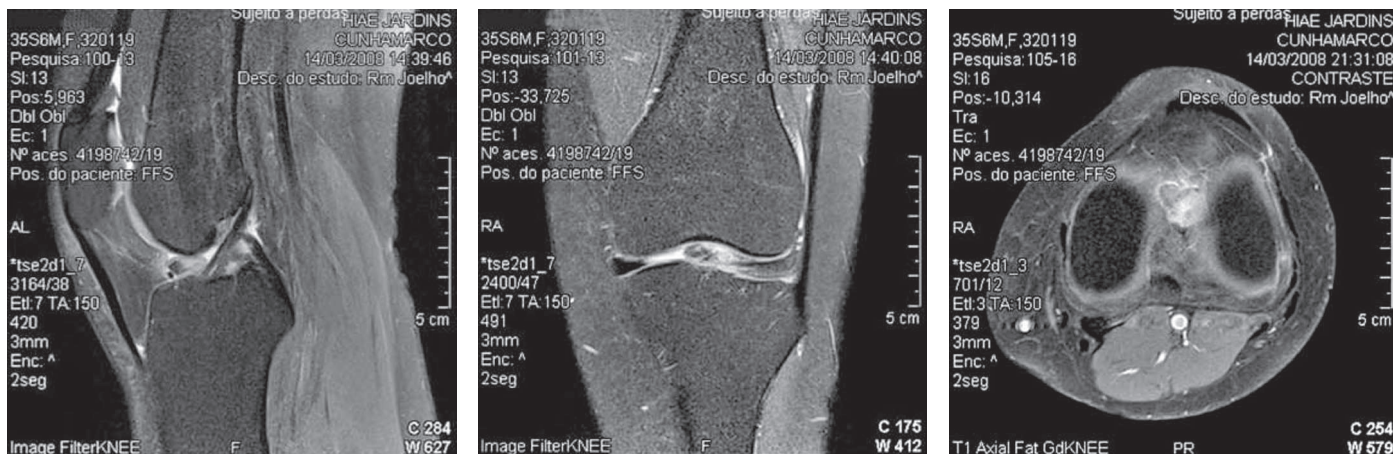

Figure 2A, B, and C – MRI of the left knee (T2-weighted images in sagittal, coronal and axial) – nodular lesion in the deep portion of the Hoffa fat pad posterior to the transverse ligament and anterior to the ACL, measuring 1.8 x 1.3 cm with low signal intensity on T2.

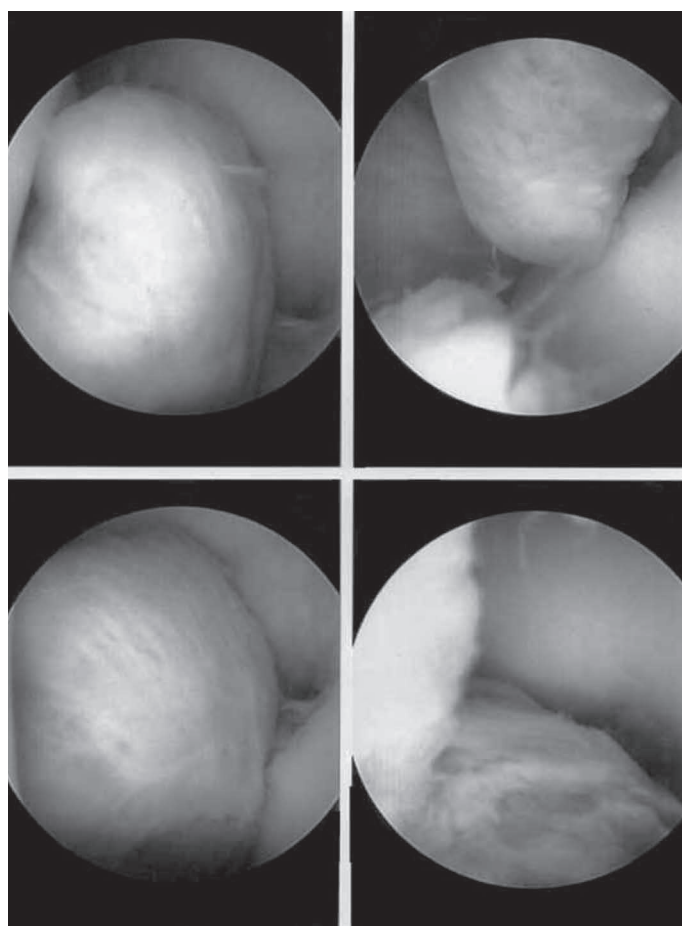


Figure 3 – Intraoperative macroscopic appearance of injury: nodular red-brown villous projection floating in the synovial fluid.

DISCUSSION

In the initial reports of synovial giant cell tumor of the knee, the terminology was confusing, since it was referred to as mieloxantoma, villous arthri-

tis, benign sinovioma, synovial endothelioma, and chronic hemorrhagic villous arthritis⁽¹⁾. In 1941, Jaffe *et al.* proposed the name “pigmented villonodular synovitis,” grouping lesions showing fibrous stroma, pigment deposition, histiocytic infiltration, and giant cells in the synovial tissues of joints, bursae, and tendon sheaths⁽²⁾.

The synovial giant cell tumor is typically a mono-articular disease, which affects mainly young adults, with the highest incidence occurring in the third and fourth decades of life. Its annual incidence is estimated to be 1.8 per million people, with equal gender distribution^(1,3).

The literature describes various etiological possibilities for the synovial giant cell tumor; however, its real etiology remains uncertain. Hiroshima encountered a high level of cholesterol in histiocytes and postulated that this condition was caused by a disturbance in lipid metabolism. The literature presents other possibilities, such as a benign neoplastic process, a reaction to an unknown stimulus, and a response to repeated episodes of trauma or hemarthrosis^(3,6).

Synovial tumors in the form of villonodular synovitis exist in two forms: the diffuse form, involving all of the synovial lining, and the localized form, more frequently at the meniscocapsular junction. Beguin *et al.* reported a mixed form, which would be a transition between the localized and the diffuse forms⁽⁷⁾.

The clinical manifestations of the diffuse form are pain, effusion, limitation of motion, which evolve

indolently. Diagnosis of the localized form is extremely difficult because the symptoms may mimic a meniscal lesion^(1,3,4).

Mechanical symptoms such as popping, effusion, and edema are usually present. The pain is found to be imprecise, however, and is rarely intense.

In the diffuse form of synovial giant cell tumor, we can find radiographic changes such as swelling and expansion of the suprapatellar bursa. Radiographic changes compatible with the disease are not found in the localized form. Magnetic resonance imaging is extremely useful in these cases, since it reveals the presence of a heterogeneous mass with low signal intensity on T1 and T2⁽³⁾.

The diagnosis of the case reported here was confirmed by histopathology, which showed proliferation of fibrous stroma with the infiltration of histiocytes, fibroblasts, and multinucleated giant cells.

The recommended treatment for localized pigmented villonodular synovitis is arthroscopic resection.

There is controversy regarding open versus arthroscopic synovectomy. With either technique, in the diffuse form, the recurrence rate varies from 8% to 50%.

The benefits of arthroscopy are more rapid rehabilitation and the avoidance of an arthrotomy. The disadvantages are related to performing intralesional debridement, the potential for the intra-articular spread of the disease, contaminating the portal sites, difficulty accessing the posterior and extra-articular locations, and difficulty in removing thickened synovial tissue⁽⁵⁾.

The advantages of an open synovectomy in relation to the arthroscopic technique are the ability to perform a marginal excision, the ability to perform a total synovectomy, and the efficient nature of an arthrotomy. However, an open procedure may result in postoperative adhesions⁽⁵⁾.

No prospective study has compared the two techniques; such research would be difficult to achieve due to the rarity of the disease. It is reasonable to choose the arthroscopic technique if the disease is focal nodular, and open when the disease is diffuse or extra-articular⁽⁵⁾.

Therefore, we believe that the arthroscopic resection of the synovial giant cell tumor in its localized form is an effective way of treatment.

REFERENCES

1. Asik M, Erlap L, Altinel L, Cetic O. Localized pigmented villonodular synovitis of the knee. *Arthroscopy*. 2001;17(6):1-6.
2. Jaffe HL, Lichtenstein L, Sutro CJ. Pigmented villonodular synovitis. *Arch Pathol Lab Med*. 1941;31:731-65.
3. Kim SJ, Shin SJ, Choi NH, Choo ET. Arthroscopic treatment for localized pigmented synovitis of the knee. *Clin Orthop Relat Res*. 2000;(379):224-30.
4. Muscolo DL, Makino A, Costa-paz M, Ayerza M. Magnetic resonance imaging and arthroscopic resection of localized pigmented villonodular synovitis of the knee. *Orthopedics*. 2000;23(4):367-9.
5. Peterson L. Chondrocyte transplantation. In: Douglas WJ. *Reconstructive knee surgery-master techniques in orthopaedic surgery*. New York: Lippincott Williams and Wilkins;2005. p.427-39
6. Ogilvie-harris DJ, McLean J, Zarnett ME. Pigmented villonodular synovitis of the knee, and arthroscopic local excision. *J Bone Joint Surg Am*. 1992;74(6):952.
7. Beguin J, Locker B, Vielpeau C. Pigmented villonodular synovitis of the knee results from 13 cases. *Arthroscopy*. 1989;5(1):62-4.