

Contents lists available at [ScienceDirect](http://www.sciencedirect.com)

International Journal of Surgery Case Reports

journal homepage: www.casereports.com

BioGlue for traumatic liver laceration



Edward Daniele*, Sharmila Dissanaiké

Texas Tech University Health Sciences Center, 3601 4th Street, Lubbock, TX 79416, United States

ARTICLE INFO

Article history:

Received 4 December 2015

Received in revised form 22 March 2016

Accepted 28 March 2016

Available online 6 April 2016

Keywords:

Trauma

Liver laceration

BioGlue

Bile leak

Endoscopic stenting

Biloma

ABSTRACT

INTRODUCTION: Advances in diagnostic imaging and monitoring have led to a shift towards primary non-operative management for most blunt liver injuries. Hemostatic biologic agents are a potential adjunct in the treatment of bile leak, especially in patients requiring surgery for drainage of a biloma.

PRESENTATION OF CASE: We present a 31 year old woman who presented to the hospital after a motor vehicle accident. She was found to have a Grade 4 liver injury causing hemoperitoneum. The patient was taken immediately for an exploratory laparotomy where the laceration was packed with an absorbable hemostatic mesh. On clinic follow-up one week after discharge, the patient was found to have a bile leak. An ERCP was performed and a stent was placed over the location of the leak. The patient underwent laparotomy the following day for evacuation of her bilomas. The liver laceration was identified and remained at the same depth. CryoLife Bioglue was used to seal the laceration.

DISCUSSION: Given the high volume biloma, it is unlikely this patient would have been successfully treated without laparotomy. As such, this was an ideal opportunity to utilize Bioglue as an adjunct to seal the liver laceration, and thus potentially the area of bile extravasation. The diversion of drainage using ERCP was likely to have reduced the volume of bile leak substantially, which would also have helped increase the efficacy of the procedure.

CONCLUSION: The case presented demonstrates a novel and safe option for the delayed repair of traumatic lacerations.

© 2016 The Authors. Published by Elsevier Ltd. on behalf of IJS Publishing Group Ltd. This is an open access article under the CC BY-NC-ND license (<http://creativecommons.org/licenses/by-nc-nd/4.0/>).

1. Introduction

The liver is the organ most commonly injured in blunt abdominal trauma, with motor vehicle collisions being the most common traumatic etiology [1]. Advances in diagnostic imaging and monitoring have led to a shift towards primary non-operative management for most blunt liver injuries. In patients initially managed non-operatively, surgical intervention is indicated if there is persistent bleeding or hemodynamic instability, continued systemic inflammatory response, or late complications. This includes major bile duct leaks resulting in bilomas, which have a reported incidence ranging from 0.5% to 21% [2–4].

Even in patients who have undergone surgery for the control of bleeding, bile leak remains a potential late complication. Although ERCP with stenting has become the mainstay of treatment for major bile duct leaks in the trauma patient, there remain a cohort of patients who have refractory bile leak and may require surgical exploration, washout, drainage and potentially hepatectomy for definitive treatment.

Hemostatic and adhesive biologic agents are a potential adjunct in the treatment of bile leak, especially in patients requiring surgery for drainage of biloma, associated abscess or other com-

plications. We report a case where a bovine serum albumin and glutaraldehyde adhesive (Bioglue, CryoLife, 1984 Atlanta, GA) was successfully used as an adjunct in a large volume bile leak following major liver trauma.

2. Case report

The patient is a 31 year old woman who presented to the hospital as a level one trauma activation after she was the unrestrained rear seat passenger in a motor vehicle accident. There was also noted to be a death on the scene of the accident. The patient was intubated in the field due to rapid, shallow breathing. On trauma evaluation the patient was hemodynamically stable but was found to have free fluid in the abdomen during FAST examination. She was then taken for a CT scan of her chest, abdomen, and pelvis with contrast. Her injuries identified through CT scan were multiple bilateral rib fractures, a Grade 4 liver injury (Fig. 1) and a grade 3 splenic injury, causing hemoperitoneum.

The patient was taken immediately for an exploratory laparotomy where a 5 cm long, 4 cm deep liver laceration was found just below the falciform ligament which was mobilized. The liver laceration was packed with an absorbable hemostatic mesh composed of an oxidized cellulose polymer, polyanhydroglucuronic acid (SURGICEL, 1949 Ethicon, Somerville, NJ). She was monitored in the ICU for one day and subsequently transferred to the wards, and was discharged on post operative day five.

* Corresponding author.

E-mail address: Edward.daniele@ttuhsc.edu (E. Daniele).

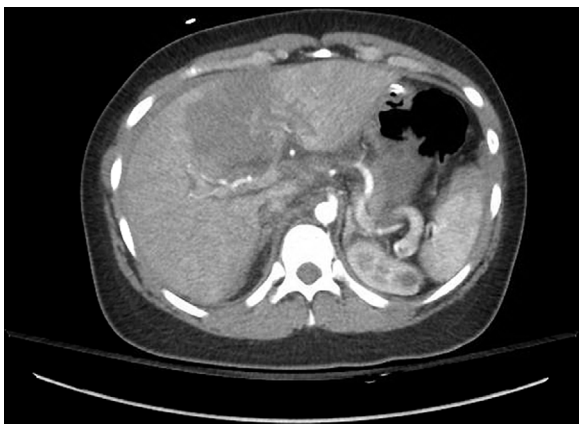

Fig. 1. CT abdomen with 6.8 cm liver laceration.

She returned the following day through the emergency room with worsening abdominal pain, mild distention, shortness of breath, and drainage from her laparotomy incision. She was diagnosed with an ileus and treated with bowel rest and intravenous hydration. She was monitored in the hospital for four days until her abdominal pain and distention decreased and she began to have regular bowel movements.

On clinic follow up one week later, the patient's pain and distention had returned. She reported not having bowel movements or passing gas for three days. On examination she was noted to have significant abdominal distention consistent with intra-peritoneal fluid and was jaundiced with scleral icterus. CT scan confirmed the diagnosis of bile leak and biloma with several loculated hypodense fluid collections in the subhepatic region (Fig. 2). A HIDA scan performed the same day showed a centrally located bile leak. The gastroenterology team was consulted at this time and performed an ERCP to identify the location of the bile leak. Contrast was observed to extravasate over the hepatic bifurcation and right main hepatic duct. A 10F by 5 cm plastic stent was placed over the location of the leak with no post-procedure bleeding noted.

The patient underwent laparotomy the following day for evacuation of the multiple bilomas. During the procedure three liters of bile were evacuated from the abdomen. The bile was brown and did not appear to have been infected, however it was present in multiple loculated collections between loops of bowel, thus confirming that it would not have been amenable to complete drainage percutaneously. The liver laceration was identified and

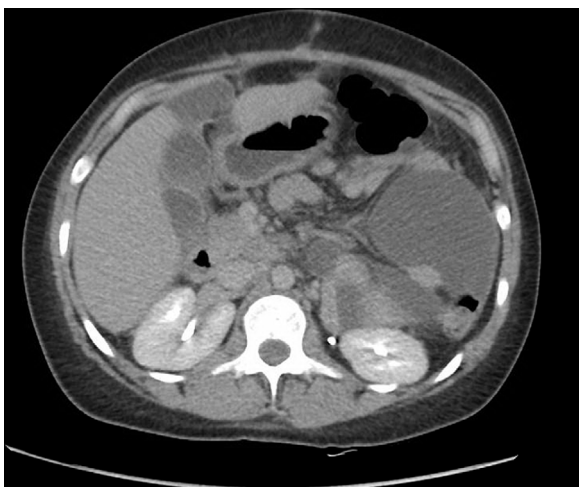


Fig. 2. CT Abdomen showing biloma formation.

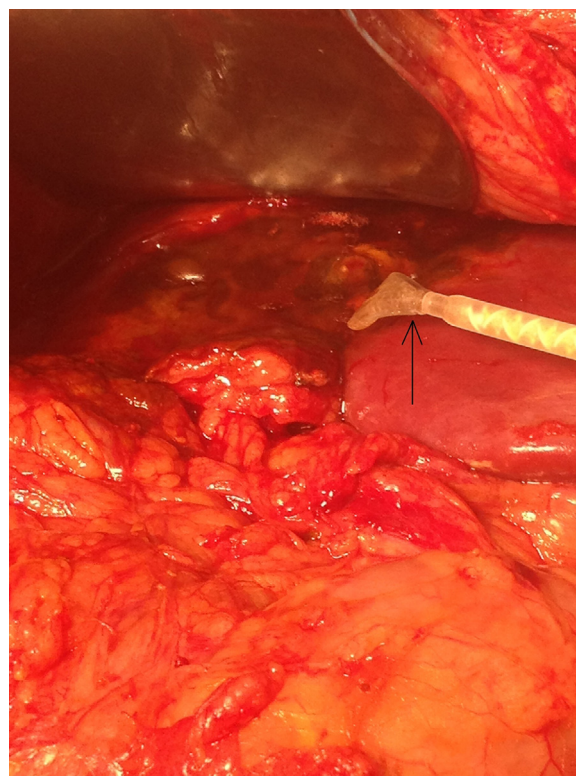


Fig. 3. Liver laceration sealed with CryoLife BioGlue.

remained at the same depth as initially noted, with bile staining throughout however no focal point of extravasation could be noted intra-operatively. CryoLife's BioGlue was used to seal the laceration (Fig. 3).

The patient did well post operatively with early return of bowel function. CT scan performed 2 and a half months later showed no further fluid collections or bilomas, and she remains clinically asymptomatic.

3. Discussion

In patients with high grade, centrally located liver injuries, a high rate of complications was observed in a number of studies [5]. Biliary complications were frequently observed with both operative and non-operative approaches to therapy [6]. Literature describing operative intervention and hepatic resection for blunt hepatic trauma and bile leaks shows significant morbidity including coagulopathy, sepsis, and respiratory insufficiency [7]. One study in 2014 investigated the success of non-surgical management for bile duct injury. "Non-surgical management" in this study was defined as only endoscopic or percutaneous intervention. There was a 94% success rate of non-operative management when dealing exclusively with a leak. When stricture along with leak was present, surgical intervention was the preferred method with improved outcomes (only 30% success rate with non-surgical treatment) [8]. As described in that study and in other literature regarding bile leaks, endoscopic drainage procedures and stenting across areas of injury have slowly emerged as a safer, alternative method to surgical bile leak repair.

Regardless, there is still some conflicting data regarding non-operative management versus internal drainage procedures. When to utilize one method over the other is still not clearly defined, with ERCP still being reserved only for major bile leaks. One single center prospective study examined 412 patients with liver trauma and divided patients into major versus minor bile duct leaks. Major

leaks were defined as greater than 400cc/day or drainage for greater than 14 days. It was determined that most bile duct injuries were minor and careful observation had the same septic complication rate and hospital/ICU length of stay as with ERCP and internal drainage [9]. The role of ERCP in minor bile duct leaks remains ambiguous. Anand et al. described bile leak control in all of the patients who underwent ERCP with stent placement [10]. The study however only followed 26 patients, 14 of which suffered from blunt trauma.

In the case described, the patient required laparotomy for evacuation of the multiple bilomas. Given the high volume, it is unlikely this would have been appropriately treated in any other manner. As such, this was an ideal opportunity to utilize an adjunct to seal the liver laceration and potentially the area of bile extravasation. The diversion of drainage using ERCP was likely to have reduced the volume of bile leak substantially, which would also have helped increase the efficacy of the procedure. Due to the lack of data regarding BioGlue usage in this setting, it is difficult to determine if stenting with peritoneal lavage alone would have been sufficient treatment. By adding BioGlue following ERCP with stenting, her post operative course was expedited. In one case series, ERCP with stenting alone showed resolution of biliary leak and discharge from the hospital on an average of 8.5 days post intervention [11]. In the presented case the addition of BioGlue allowed for resolution of the leak and discharge from the hospital on day six. By reducing the number of hospital days, this proves a cost effective method for managing high grade bile leaks.

CryoLife's "BioGlue" was first introduced in 1998 as a novel surgical adhesive in cardiovascular surgery. It has been used in procedures such as aortic valve replacements and carotid endarterectomy surgery for years with FDA approval for hemostasis and open repair of large vessels. It has two main components: bovine serum albumin and glutaraldehyde. The two chemicals are dispensed simultaneously, forming a flexible seal when mixed together. The BioGlue seals within twenty seconds, forming its full mechanical barrier at two minutes. There have been many case reports and research papers regarding its applications, ranging from aortic dissections to rectovaginal fistulas, to spinal operations. In the setting of trauma, it has been used successfully in splenic injuries as well as penetrating cardiac trauma. Following penetrating cardiac injury, Bioglue was used both as a primary mean and adjunct to suture repair to control hemorrhage. In both cases there were no cardiac complications during the follow-up [12,13]. BioGlue has also been marketed to reinforce damaged parenchyma in various abdominal tissues, however, this is the first case report describing its efficacy in sealing high grade liver lacerations. The case presented here demonstrates a novel, safe, and easy option for the delayed repair of traumatic lacerations to treat bile leak.

Conflicts of interest

None.

Funding

None.

Ethical approval

Consent obtained.

Open Access

This article is published Open Access at sciendo.com. It is distributed under the [IJSCR Supplemental terms and conditions](http://creativecommons.org/licenses/by/4.0/), which permits unrestricted non commercial use, distribution, and reproduction in any medium, provided the original authors and source are credited.

Consent

Written informed consent was obtained from the patient for publication of this case report and accompanying images. A copy of the written consent is available for review by the Editor-in-Chief of this journal on request.

Author contribution

Edward Daniele M.D.—writing and organization of paper, data collection.

Sharmila Dissanaik M.D.—writing and organization of paper, data collection.

Guarantor

Edward Daniele M.D., Sharmila Dissanaik M.D.

Registration of research studies

Registered at: <http://www.researchregistry.com>.
UIN: researchregistry767.

References

- [1] G. Tinkoff, T.J. Esposito, J. Reed, P. Kilgo, J. Fildes, M. Pasquale, J.W. Meredith, American Association for the Surgery of Trauma Organ Injury Scale I: spleen, liver, and kidney, validation based on the National Trauma Data Bank, *J. Am. Coll. Surg.* 207 (November (5)) (2008) 646–655.
- [2] J.A. Asensio, D. Demetriades, S. Chahwan, H. Gomez, D. Hanpeter, G. Velmahos, J. Murray, W. Shoemaker, T.V. Berne, Approach to the management of complex hepatic injuries, *J. Trauma* 48 (1) (2000) 66.
- [3] V. Singh, K.L. Narasimhan, G.R. Verma, G. Singh, Endoscopic management of traumatic hepatobiliary injuries, *J. Gastroenterol. Hepatol.* 22 (8) (2007) 1205.
- [4] W.L. Wahl, M.M. Brandt, M.R. Hemmila, S. Arabi, Diagnosis and management of bile leaks after blunt liver injury, *Surgery* 138 (October (4)) (2005) 742–748 (discussion 747–8).
- [5] Kuo-Ching Yuan, Yon-Cheong Wong, Chih-Yuan Fu, Chee-Jen Chang, Shih-Ching Kang, Yu-Pao Hsu, Screening and management of major bile leak after blunt liver trauma: a retrospective single center study, *Scand. J. Trauma Resusc. Emerg. Med.* 15 (22) (2014) 26, <http://dx.doi.org/10.1186/1757-7241-22-26>.
- [6] M. Bala, S.A. Gazalla, M. Feroja, A.I. Bloom, G. Zamir, A.I. Rivkind, G. Almogy, Complications of high grade liver injuries: management and outcome with focus on bile leaks, *Scand. J. Trauma Resusc. Emerg. Med.* 20 (March) (2012) 20, <http://dx.doi.org/10.1186/1757-7241-20-20>.
- [7] M.J. Hollands, J.M. Little, The role of hepatic resection in the management of blunt liver trauma, *World J. Surg.* 14 (July/August (4)) (1990) 478–482.
- [8] Y.O. Eum, J.K. Park, J. Chun, S.H. Lee, J.K. Ryu, Y.T. Kim, Y.B. Yoon, C.J. Yoon, H.S. Han, J.H. Hwang, Non-surgical treatment of post-surgical bile duct injury: clinical implications and outcomes, *World J. Gastroenterol.* 20 (June (22)) (2014) 6924–6931, <http://dx.doi.org/10.3748/wjg.v20.i22.6924>.
- [9] M. Hommes, A.J. Nicol, P.H. Navsaria, E. Reinders Folmer, S. Edu, J.E. Krige, Management of biliary complications in 412 patients with liver injuries, *J. Trauma Acute Care Surg.* 77 (September (3)) (2014) 448–451, <http://dx.doi.org/10.1097/TA.0000000000000335>;
- [10] M. Miscusi, F.M. Polli, S. Forcato, M.A. Coman, L. Ricciardi, A. Ramieri, A. Raco, The use of surgical sealants in the repair of dural tears during non-instrumented spinal surgery, *Eur Spine J.* 23 (August (8)) (2014) 1761–1766, <http://dx.doi.org/10.1007/s00586-013-3138-1>, Epub 2014 Jan 3.
- [11] R.J. Anand, P.A. Ferrada, P.E. Darwin, G.V. Bochicchio, T.M. Scalea, Endoscopic retrograde cholangiopancreatography is an effective treatment for bile leak after severe liver trauma, *J. Trauma* 71 (August (2)) (2011) 480–485.
- [12] Matthew P. Spinn, Mihir K. Patel, Bryan A. Cotton, Frank J. Lukens, Successful endoscopic therapy of traumatic bile leaks, *Case Rep. Gastroenterol.* 7 (January–April (1)) (2013) 56–62.
- [13] E.L. Jones, C.C. Burlew, E.E. Moore, BioGlue hemostasis of penetrating cardiac wounds in proximity to the left anterior descending coronary artery, *J. Trauma Acute Care Surg.* 72 (March (3)) (2012) 796–798.
- [14] Grace Biggs, Jason Hafron, Joseph Feliciano, David M. Hoenig, Treatment of splenic injury during laparoscopic nephrectomy with BioGlue, a surgical adhesive, *J. Urol.* (2005), 04.054.