

Case of fatal heart failure with biventricular noncompaction, genital skeletal abnormalities and mental retardation

Halil Ataş, Fuad Samadov¹, İbrahim Sarı, Kenan Delil*
 Departments of Cardiology and *Genetic, Marmara University Training and Research Hospital; Istanbul-Turkey
¹Department of Cardiology, Educational-Therapeutic Clinic of Azerbaijan University; Bakü-Azerbaijan

Introduction

Noncompaction cardiomyopathy (NC) is rare a genetic disorder. Although it is generally associated with additional cardiac and extra-cardiac disorders (1), cases with genital anomalies are extremely rare. Here we report a 48-year-old female with biventricular noncompaction, mental retardation, ovarian dysgenesis, uterine aplasia, bilateral amazia, and skeletal anomalies.

Case Report

A 48-year-old female was admitted to the intensive care unit with severe respiratory distress. On admission, her blood pressure was 90/55 mm Hg, heart rate was 124 bpm, respiratory rate was 30 per minute, and oxygen saturation was 80% on room air. Auscultation revealed S3 gallop and bilateral inspiratory crackles to the middle zones of the lungs. The ECG at admission showed sinus tachycardia with rate of 120/min and left ventricular (LV) hypertrophy with secondary ST-segment changes. The clinical scenario was compatible with acute pulmonary edema. Noninvasive mechanical ventilatory support was given to decrease the work of breathing, and following aggressive medical treatment, including intravenous furosemide and inotropes, pulmonary edema resolved within 24 hours. After stabilization of the patient, a detailed medical history was obtained from the patient and her sister. The past medical and surgical history was unremarkable except for primary amenorrhea. She did not smoke or drink alcohol and was not exposed to toxins. There was consanguineous marriage (fourth-degree) between the parents of the patient. She had three healthy brothers and a sister, but two sisters and a brother had died in childhood from unknown reasons. Inspection of the patient revealed macrocephaly, acromegaloid facial appearance, arachnodactyly, pectus carinatum, bilateral amazia, and mild scoliosis (Fig. 1). Transthoracic echocardiography revealed dilatation of all heart chambers, globally impaired systolic function (EF: 35%), mild pericardial effusion in all localizations, and mild mitral and tricuspid regurgitation. There were prominent trabeculations and intertrabecular recesses in the lateral wall, septum and apex of the left and right ventricles (Fig. 2, Video 1-4). Multiple intertrabecular recesses in communication with the ventricular cavity were demonstrated by forward and reverse flow of blood on color flow mapping. Cardiac MRI confirmed the diagnosis of biventricular noncompaction (Fig. 3, Video 5). Coronary angiography showed normal coronary arteries. In respect to her past medical history, she was referred to the departments of gynecology, endocrinology, and medical genetics. Laboratory investigations revealed hypergonadotropic hypogonadism, and a pelvic MRI demonstrated the absence of ovaries, uterus, or prostate. Cytogenetic analysis showed a 46, XX karyotype without any

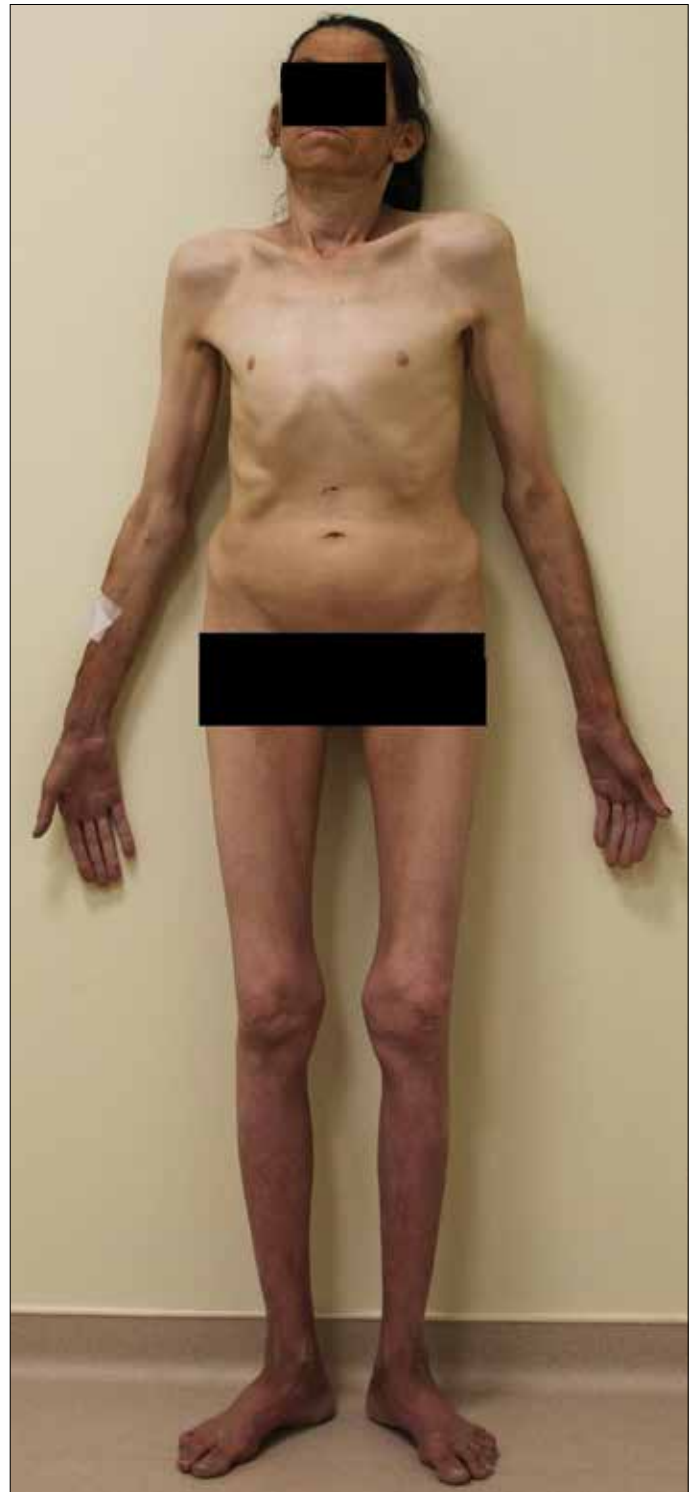

Figure 1. Gross appearance of the patient revealing macrocephaly, acromegaloid facial appearance, arachnodactyly, pectus carinatum, bilateral amazia, and mild scoliosis

chromosomal abnormalities. All 12 exons of the LMNA gene were screened for mutations by direct sequencing, but no mutations were detected. The patient was discharged on the fifth day of hospitalization. Due to non-adherence to the medical treatment, there were recurrent hospitalizations with heart failure decompensation, and she died 4 months after diagnosis.

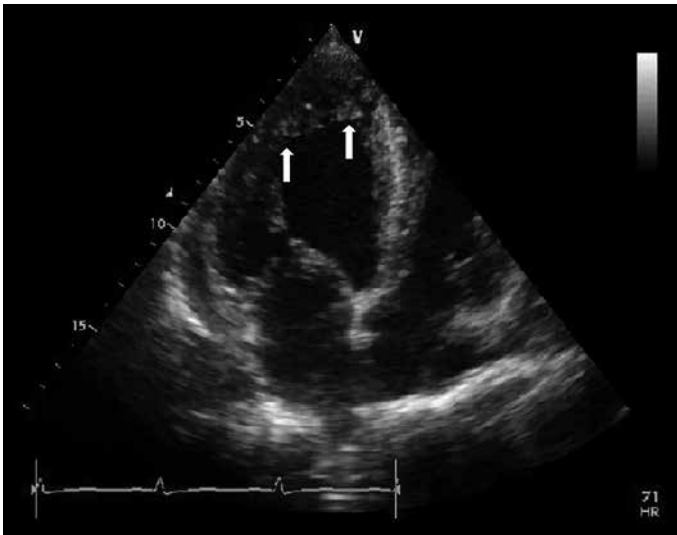

Figure 2. Transthoracic echocardiography of the patient revealing prominent trabeculations and intertrabecular recesses in the left ventricle

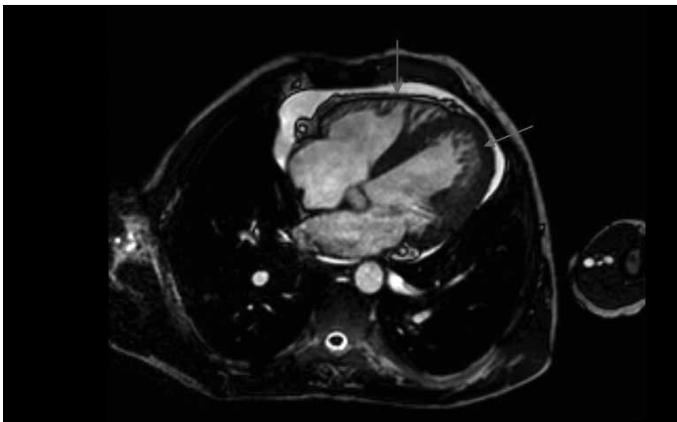


Figure 3. Cardiac magnetic resonance imaging of the patient confirming the findings of transthoracic echocardiography

Discussion

Noncompaction cardiomyopathy is a rare genetic disorder with a reported prevalence of 0.05% (2); however, the true measure is believed to be higher. Noncompaction can be an isolated cardiomyopathy or associated with cardiac or extracardiac, particularly neuromuscular disorders. But, the coexistence of NC with genital anomalies is very rare, and we could find only two recently reported cases (3, 4). Both of them were male patients. Our case had genital and skeletal anomalies, in addition to NC. Coexistence of hypergonadotropic hypogonadism with dilated cardiomyopathy was first reported 1973 by Najjar et al. (5), and since that time, only 15-20 similar cases have been reported in the English literature. Since this condition is known to be caused by mutations in the LMNA gene, we screened this gene for mutations but found nothing. The common features of these cases are dilated cardiomyopathy, hypoplastic genitalia, and hypergonadotropic hypogonadism. Although cardiac involvement in our case is distinct from these reports, the extracardiac manifestations are very similar, especially to the case reported by Narahara (6). It is possible that at least some of these cases were noncompaction cardiomyopathy but not dilated cardiomyopathy, because at that time, NC was not yet reported or was not well known.

Conclusion

In conclusion, this is the first case with NC and female genital anomalies. Coexistence of biventricular NC, genital and skeletal anomalies, and mental retardation leads one to consider the presence of a syndrome, but we have not been able to find a similar combination of symptoms in the literature. Although our case is isolated, the unexplained death of the patient's siblings supports the inheritance.

Video 1. Transthoracic parasternal short-axis view, showing mild pericardial effusion and global hypokinesia of the left ventricle

Video 2-3. Transthoracic apical four-chambers views, showing hypertrabeculations on the lateral wall and apex of the left ventricle

Video 4. Multiple intertrabecular recesses in communication with the ventricular cavity demonstrated by forward and reverse flow of blood on color flow Doppler

Video 5. Cardiac MRI, confirming biventricular hypertrabeculations, suggesting noncompaction cardiomyopathy

References

1. Nakashima K, Kusakawa I, Yamamoto T, Hirabayashi S, Hosoya R, Shimizu W, et al. A left ventricular noncompaction in a patient with long QT syndrome caused by a KCNQ1 mutation: a case report. *Heart Vessels* 2013; 28: 126-9. [CrossRef]
2. Ritter M, Oechslin E, Sütsch G, Attenhofer C, Schneider J, Jenni R. Isolated noncompaction of the myocardium in adults. *Mayo Clin Proc* 1997; 72: 26-31. [CrossRef]
3. Ojala T, Polinati P, Manninen T, Hiippala A, Rajantie J, Karikoski R, et al. New mutation of mitochondrial DNAJC19 causing dilated and noncompaction cardiomyopathy, anemia, ataxia, and male genital anomalies. *Pediatr Res* 2012; 72: 432-7. [CrossRef]
4. Özcan KS, Osmonov D, Altay S, Güngör B, Eren M. Fertile eunuch syndrome in association with biventricular noncompaction, bicuspid aortic valve, severe aortic stenosis, and talipes equinovarus. *Tex Heart Inst J* 2013; 40: 204-6.
5. Najjar SS, Kaloustian VM der, Nassif SI. Genital anomaly, mental retardation, and cardiomyopathy: a new syndrome? *J Pediatr* 1973; 83: 286-8. [CrossRef]
6. Narahara K, Kamada M, Takahashi Y, Tsuji K, Yokoyama Y, Ninomiya S, et al. Case of ovarian dysgenesis and dilated cardiomyopathy supports existence of Malouf Syndrome. *Am J Med Genet* 1992; 144: 369-73. [CrossRef]

Address for Correspondence: Dr. Halil Ataş,
Marmara Üniversitesi Eğitim ve Araştırma Hastanesi,
Pendik, İstanbul-Türkiye

Phone: +90 532 546 25 35

Fax: +90 216 657 09 65

E-mail: dratashalil@gmail.com

Available Online Date: 25.12.2014

©Copyright 2015 by Turkish Society of Cardiology - Available online at www.anakarder.com

DOI:10.5152/akd.2014.5722

