

## Giant Lumbar Dumbbell Extradural Schwannoma in a Child

### Abstract

Completely giant lumbar extradural spinal Schwannomas are a rare subgroup of spinal nerve sheath tumors in the pediatric age group. Single stage, single approach, complete, and safe surgical removal while preserving the spinal stability is the mainstay of treatment of giant lumbar extradural Schwannomas. In the present case, we report a case of a 9-year-old male child studying in 2<sup>nd</sup> standard presented with pain in both thighs and legs for 3 months. Magnetic resonance imaging lumbosacral spine showed lobulated dumbbell-shaped lesion extending from L4 superior endplate to inferior endplate of L5 in intraspinal space displacing the nerve roots. The patient underwent a posterior midline approach, L4 and L5 laminectomy and complete excision of the tumor. Histopathological confirmed the diagnosis of benign extradural dumbbell Schwannoma. Postoperatively, the child was showing gradual improvement in motor power, but his pain was significantly relieved.

**Keywords:** *Cauda equine, complete excision, giant Schwannoma, pediatric spine*

### Introduction

Completely giant lumbar extradural spinal Schwannomas are rare subgroup of spinal nerve sheath tumors with an incidence of 0.7%–4.2% of all spinal extradural Schwannomas.<sup>[1-4]</sup> These lesions are typically present in adults and children these are rarer<sup>[5,6]</sup> and often occur in children with neurofibromatosis type 2.<sup>[1,7-9]</sup> In the present case, we report a case of giant lumbar dumbbell extradural Schwannoma and discuss the surgical approach adopted in this child.

### Case Report

A 9-year-old male child studying in 2<sup>nd</sup> standard presented with pain in both thighs and legs for 3 months. The pain was gradual in onset, progressive and because of pain; he was not able to walk. The pain was relieved temporally by medication. The parents also noticed that the child was limping while walking and he used to bend his knees while walking. Here, bowel and bladder habits were normal. On neurological examination, his higher mental functions, cranial nerves, and upper limbs were normal. On examination of the lower limbs, it was noticed that the child was lying down with right hip flexed and right knee semi-flexed, left hip flexed, and externally rotated and left foot was in plantar flexion.

This is an open access journal, and articles are distributed under the terms of the Creative Commons Attribution-NonCommercial-ShareAlike 4.0 License, which allows others to remix, tweak, and build upon the work non-commercially, as long as appropriate credit is given and the new creations are licensed under the identical terms.

For reprints contact: reprints@medknow.com

Power in lower limbs was 4/5 at hip and 3/5 at knee and ankle muscle groups. Left knee and ankle jerks were absent. Sensory examination was normal. Bilateral planters were not elicitable. The child had wide-based gait and was flexing knees and hips while walking. Local examination of the spine revealed tenderness over lower lumbar and sacral region. There were no neurocutaneous markers. Magnetic resonance imaging (MRI) was performed on GE 750W discovery machine which showed lobulated dumbbell-shaped lesion in intradural space displacing the nerve roots; the lesion was extending from L4 superior endplate to inferior endplate of L5. The lesion was extending into paravertebral space through the neural foramina, the lesion was hypointense on T1, T2, and hyperintense on short tau inversion recovery on contrast images lesion was showing intense homogeneous enhancement [Figures 1 and 2]. The patient underwent a posterior midline approach, L4 and L5 laminectomy and complete excision of the tumor was performed. There was widened and thinned out L4 neural foramen on the left side which was further widened (by doing partial facetectomy) to gain exposure to avoid pressure on the nerve roots and to allow safe excision of the tumor [Figure 3]. Histopathological confirmed the diagnosis of benign extradural dumbbell Schwannoma. Postoperatively, the

**How to cite this article:** Agrawal A, Reddy VU, Santhi V, Sandeep Y. Giant lumbar dumbbell extradural schwannoma in a child. *Asian J Neurosurg* 2019;14:535-7.

**Amit Agrawal,  
Venati  
Umamaheswara  
Reddy<sup>1</sup>,  
Vissa Santhi<sup>2</sup>,  
Yashawant Sandeep**

*Departments of Neurosurgery,  
1Radiology and 2Pathology,  
Narayana Medical  
College Hospital, Nellore,  
Andhra Pradesh, India*

### Address for correspondence:

*Dr. Amit Agrawal,  
Department of Neurosurgery,  
Narayana Medical College  
Hospital, Chinthareddypalem,  
Nellore - 524 003,  
Andhra Pradesh, India.  
E-mail: dramitagrawal@gmail.  
com*

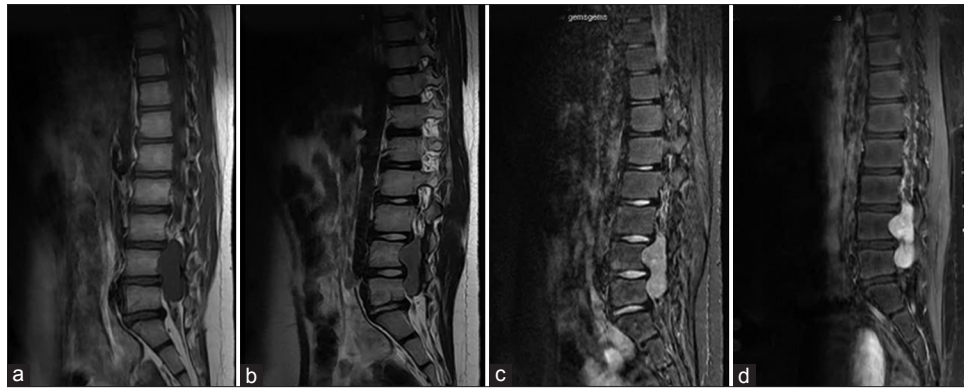
### Access this article online

**Website:** www.asianjns.org

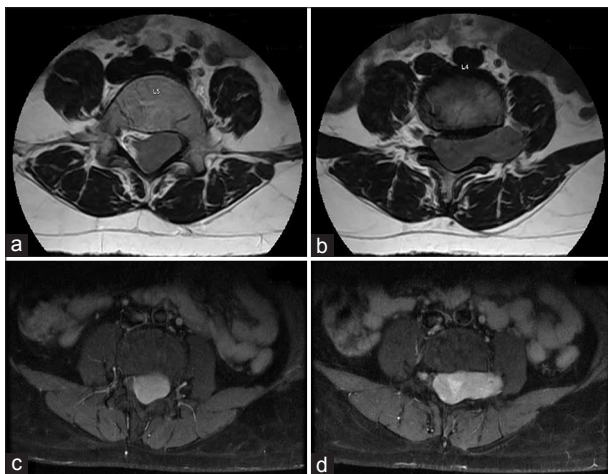
**DOI:** 10.4103/ajns.AJNS\_132\_18

### Quick Response Code:





**Figure 1:** T1 sagittal, T2 sagittal images (a and b) showing well-defined hypointense lobulated lesion at L4, L5 vertebral levels causing neural foraminal widening, on sagittal short tau inversion recovery images the lesion is hyperintense (c) and on postcontrast T1 images (d) Lesion is showing homogeneous intense enhancement



**Figure 2:** Axial T2-weighted images (a and b) at L4, L5 vertebral level showing an intradural hypointense lesion displacing the cauda equina and is exiting through the neural foramina giving characteristic dumbbell shape. On contrast, administration lesion is showing homogeneous enhancement (c and d)

child was showing gradual improvement in motor power, but his pain was significantly relieved.

## Discussion

According to their dimension and location, these lesions can be categorized as contiguous intraspinal, foraminal, extraforaminal, and intraosseous components (dumbbell appearance can be attributed to hourglass shape because of bony constriction at the foramen).<sup>[10,11]</sup> Sridhar *et al.* proposed that giant spinal Schwannomas can be classified as Type II tumors that extend over more than two vertebral levels, Type IVb tumors (giant dumbbell type)-extraspinal extension of >25 mm, and type V (giant invasive tumors) tumors eroding the vertebral bodies with posterior and lateral extension into the myofascial planes.<sup>[1]</sup> The majority of giant spinal Schwannomas have typical pathological appearance, and usually, Ki-67 index is <3%.<sup>[1]</sup> Contrast-enhanced MRI images of the spine will delineate most of the details of the tumor and its relationship to the surrounding structures including neural

elements.<sup>[1,9,12-15]</sup> Radiographs and computed tomography scan with bone window will further provide greater details of any bony erosion or destruction and thus potential to develop spinal stability.<sup>[1,14,15]</sup> In addition, those patients whose imaging showed considerable vertebral erosion are at greater risk for spinal instability and may need spinal instrumentation to address the instability.<sup>[16-18]</sup>

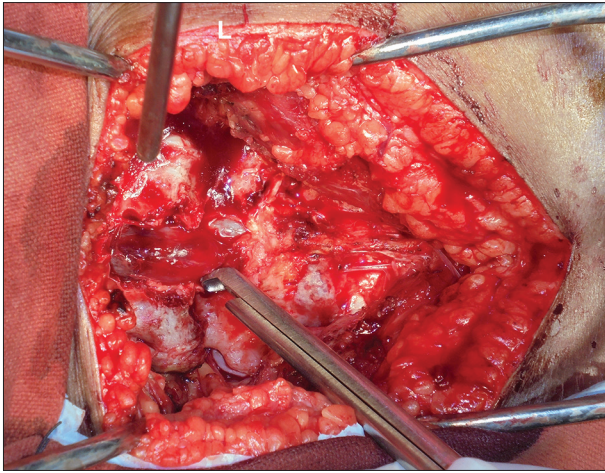
Single stage, single approach, complete, and safe surgical removal while preserving the spinal stability is the mainstay of treatment of giant lumbar extradural Schwannomas.<sup>[2,9,15,19-21]</sup> However, patients with larger lesions may require multiple approaches in multiple stages.<sup>[9,15,22]</sup> While planning for the surgical approach, a number of factors need to be considered to avoid postoperative instability. The traditional approach to resect these lesions is an open and extensive laminectomy with ipsilateral complete facetectomy (to allow good exposure without undue pressure on neural structures).<sup>[1,2,4,11,23,24]</sup> Following a classical approach (multilevel laminectomy and radical facetectomy), postlaminectomy instability and deformity can be a major concern.<sup>[25-27]</sup> To avoid this and as we have adopted, a more conservative surgical approach to excise these giant tumors include restricted hemilaminectomy and medial facetectomy (up to one-third resection of the medial facet joint).<sup>[28,29]</sup> In the selected subgroup of patients, a minimally invasive approach using the nonexpandable tubular retractor has been described to resect giant lumbar Schwannomas.<sup>[4,30]</sup> With the use of minimally invasive approach, it is reported that the need for facetectomy or subsequent spinal fusion can be avoided.<sup>[4,30,31]</sup>

## Conclusion

Giant lumbar dumbbell Schwannomas are rare lesions in children with sporadic case reports in literature. Complete surgical excision while avoiding damage to nerve roots and maintaining the spinal stability is the mainstay of treatment.

## Declaration of patient consent

The authors certify that they have obtained all appropriate patient consent forms. In the form the patient(s) has/have given his/her/their consent for his/her/their images and



**Figure 3:** Intraoperative photograph showing extradural location of the tumor on the left side with widening of the left L4 neural foramina. Note the partial derroofing of the foramina to avoid undue pressure on the nerve roots during manipulation of the tumor

other clinical information to be reported in the journal. The patients understand that their names and initials will not be published and due efforts will be made to conceal their identity, but anonymity cannot be guaranteed.

#### Financial support and sponsorship

Nil.

#### Conflicts of interest

There are no conflicts of interest.

#### References

- Sridhar K, Ramamurthi R, Vasudevan MC, Ramamurthi B. Giant invasive spinal schwannomas: Definition and surgical management. *J Neurosurg* 2001;94:210-5.
- Celli P, Trillò G, Ferrante L. Spinal extradural schwannoma. *J Neurosurg Spine* 2005;2:447-56.
- Nittner K. Spinal meningiomas, neurinomas and neurofibromas and hourglass tumors. *Handbook of Clinical Neurology*. Vol. 20. Amsterdam: North-Holland Publishing Co; 1976. p. 177-322.
- Weil AG, Obaid S, Shehadeh M, Shedid D. Minimally invasive removal of a giant extradural lumbar foraminal schwannoma. *Surg Neurol Int* 2011;2:186.
- Ozawa H, Kokubun S, Aizawa T, Hoshikawa T, Kawahara C. Spinal dumbbell tumors: An analysis of a series of 118 cases. *J Neurosurg Spine* 2007;7:587-93.
- Tarik Tihan M. Schwannoma. *Atlas of Pediatric Brain Tumors*. New York: Springer; 2010. p. 145-52.
- Choudry Q, Younis F, Smith RB. Intraosseous schwannoma of D12 thoracic vertebra: Diagnosis and surgical management with 5-year follow-up. *Eur Spine J* 2007;16 Suppl 3:283-6.
- Inaoka T, Takahashi K, Hanaoka H, Aburano R, Tokusashi Y, Matsuno T, et al. Paravertebral neurinoma associated with aggressive intravertebral extension. *Skeletal Radiol* 2001;30:286-9.
- Yu NH, Lee SE, Jahng TA, Chung CK. Giant invasive spinal schwannoma: Its clinical features and surgical management. *Neurosurgery* 2012;71:58-66.
- Asazuma T, Toyama Y, Maruiwa H, Fujimura Y, Hirabayashi K. Surgical strategy for cervical dumbbell tumors based on a three-dimensional classification. *Spine (Phila Pa 1976)* 2004;29:E10-4.
- Park SC, Chung SK, Choe G, Kim HJ. Spinal intraosseous schwannoma: A case report and review. *J Korean Neurosurg Soc* 2009;46:403-8.
- Parmar HA, Ibrahim M, Castillo M, Mukherji SK. Pictorial essay: Diverse imaging features of spinal schwannomas. *J Comput Assist Tomogr* 2007;31:329-34.
- Popuri R, Davies AM. MR imaging features of giant pre-sacral schwannomas: A report of four cases. *Eur Radiol* 2002;12:2365-9.
- Satake K, Matsuyama Y, Yoshihara H, Yanase M, Miura Y. Three-dimensional images for surgical plan of giant sacral schwannoma. *Spinal Cord* 2004;42:368-70.
- Vadivelu S, Prasad P, Adesina AM, Kim E, Luerssen TG, Jea A, et al. Giant invasive spinal schwannoma in children: A case report and review of the literature. *J Med Case Rep* 2013;7:289.
- Osborn RE, DeWitt JD. Giant cauda equina schwannoma: CT appearance. *AJNR Am J Neuroradiol* 1985;6:835-6.
- Hung CH, Tsai TH, Lieu AS, Lin CL, Lee KS, Hwang SL, et al. Giant invasive schwannoma of cauda equina with minimal neurologic deficit: A case report and literature review. *Kaohsiung J Med Sci* 2008;24:212-7.
- Kagaya H, Abe E, Sato K, Shimada Y, Kimura A. Giant cauda equina schwannoma. A case report. *Spine (Phila Pa 1976)* 2000;25:268-72.
- Seppälä MT, Haltia MJ, Sankila RJ, Jääskeläinen JE, Heiskanen O. Long-term outcome after removal of spinal schwannoma: A clinicopathological study of 187 cases. *J Neurosurg* 1995;83:621-6.
- Ghani AR, Ariff AR, Romzi AR, Sayuthi S, Hasnan J, Kaur G, et al. Giant nerve sheath tumour: Report of six cases. *Clin Neurol Neurosurg* 2005;107:318-24.
- Iwasaki M, Nakamura K, Takeshita K, Kawaguchi H, Akune T, Hoshino Y, et al. Surgical management of giant schwannoma in the lumbosacral region. *J Spinal Disord* 1998;11:444-7.
- Kataria R, Kurmi DJ, Mehta J, Sinha VD. Giant lumbosacral schwannoma in a child. *J Pediatr Neurosci* 2012;7:126-8.
- Lu DC, Dhall SS, Mummaneni PV. Mini-open removal of extradural foraminal tumors of the lumbar spine. *J Neurosurg Spine* 2009;10:46-50.
- McCormick PC. Surgical management of dumbbell tumors of the cervical spine. *Neurosurgery* 1996;38:294-300.
- Papagelopoulos PJ, Peterson HA, Ebersold MJ, Emmanuel PR, Choudhury SN, Quast LM, et al. Spinal column deformity and instability after lumbar or thoracolumbar laminectomy for intraspinal tumors in children and young adults. *Spine (Phila Pa 1976)* 1997;22:442-51.
- Sridhar K, Ramamurthi R, Vasudevan MC, Ramamurthi B. Limited unilateral approach for extramedullary spinal tumours. *Br J Neurosurg* 1998;12:430-3.
- Yasuoka S, Peterson HA, MacCarty CS. Incidence of spinal column deformity after multilevel laminectomy in children and adults. *J Neurosurg* 1982;57:441-5.
- Chiou SM, Eggert HR, Laborde G, Seeger W. Microsurgical unilateral approaches for spinal tumour surgery: Eight years' experience in 256 primary operated patients. *Acta Neurochir (Wien)* 1989;100:127-33.
- Yaşargil MG, Tranmer BI, Adamson TE, Roth P. Unilateral partial hemi-laminectomy for the removal of extra- and intramedullary tumours and AVMs. *Adv Tech Stand Neurosurg* 1991;18:113-32.
- Nzokou A, Weil AG, Shedid D. Minimally invasive removal of thoracic and lumbar spinal tumors using a nonexpandable tubular retractor. *J Neurosurg Spine* 2013;19:708-15.
- Lu DC, Chou D, Mummaneni PV. A comparison of mini-open and open approaches for resection of thoracolumbar intradural spinal tumors. *J Neurosurg Spine* 2011;14:758-64.