

Biceps Tenodesis: Anatomic Tensioning



Matthew A. Tao, M.D., Jacob G. Calcei, M.D., and Samuel A. Taylor, M.D.

Abstract: Biceps tenodesis is a commonly employed surgical intervention for refractory symptoms related to the biceps-labral complex, those intra-articular and those within the extra-articular bicipital tunnel. While a litany of surgical techniques exists, the optimal method for ensuring an anatomic length-tension relationship during tenodesis remains elusive. Appropriate tensioning may limit undesirable outcomes such as cramping or cosmetic deformity. We describe herein our technique as a simple and efficient means to establish patient-specific, anatomic tensioning of the long head of the biceps during tenodesis.

The long head of the biceps brachii tendon and the biceps-labral complex (BLC) may be a significant source of pain in the shoulder. Surgical management for persistent symptoms may include biceps tenotomy or tenodesis.¹⁻³

Determining the most appropriate surgical intervention for refractory biceps-labral complex disease must take into account the presence or absence of pathology within the extra-articular bicipital tunnel. Our group recently reported on the diagnostic power of the “3-pack exam” (Fig 1).^{4,5} Specifically, we found that the active compression test (O’Brien sign) and tenderness to palpation of the bicipital tunnel held very high negative predictive values for extra-articular disease. When both of these tests are positive, we recommend a bicipital tunnel decompressing tenodesis technique⁵ such as subdeltoid transfer^{6,7} to the conjoint tendon or open subpectoral biceps tenodesis.⁸

Regardless of the tenodesis technique, determining a reproducible method to establish anatomic tensioning of the long head of the biceps tendon remains a source of debate. Failure to reestablish a patient’s normal length-tension relationship can lead to cramping, fatigue, and cosmetic (Popeye) deformity^{9,10} in the setting of

undertensioning or placing increased stress on the fixation device and muscle if overtensioned. Attempts have been made to identify reliable landmarks based on the location of the musculotendinous junction,^{11,12} calculations of anatomic position based on humeral length,¹³ and the use of a consistent arthroscopic location and bone tunnel size.¹⁴

Given individual variability, however, we believe such efforts may still fall short in setting patient-specific length-tension relationship. The purpose of this report is to describe a simple and efficient means by which a patient’s anatomic length-tension relationship can be set during open subpectoral biceps tenodesis.

Technique

Our approach, described below, is accompanied by [Video 1](#).

Positioning

The patient is placed in beach chair position following regional anesthesia. An examination under anesthesia is followed by a thorough diagnostic arthroscopy. Supplies necessary to apply our technique are provided in [Table 1](#).

Diagnostic Examination

A standard posterior portal is established, and then an anterior working portal is made through the rotator interval under spinal needle localization. Diagnostic arthroscopy is performed starting with a 30° arthroscope. Although we believe the decision to perform a biceps tenodesis should generally be made preoperatively, the biceps tendon is inspected both statically and dynamically under arthroscopic visualization.⁴ Arthroscopy also allows for a detailed evaluation of

From the Sports Medicine and Shoulder Surgery, Hospital for Special Surgery, New York, New York, U.S.A.

The authors report that they have no conflicts of interest in the authorship and publication of this article.

Received February 9, 2017; accepted March 30, 2017.

Address correspondence to Samuel A. Taylor, M.D., Sports Medicine and Shoulder Surgery, Hospital for Special Surgery, 535 E 70th Street, New York, NY 10021, U.S.A. E-mail: taylors@hss.edu

© 2017 by the Arthroscopy Association of North America
2212-6287/17167/\$36.00

<http://dx.doi.org/10.1016/j.eats.2017.03.033>

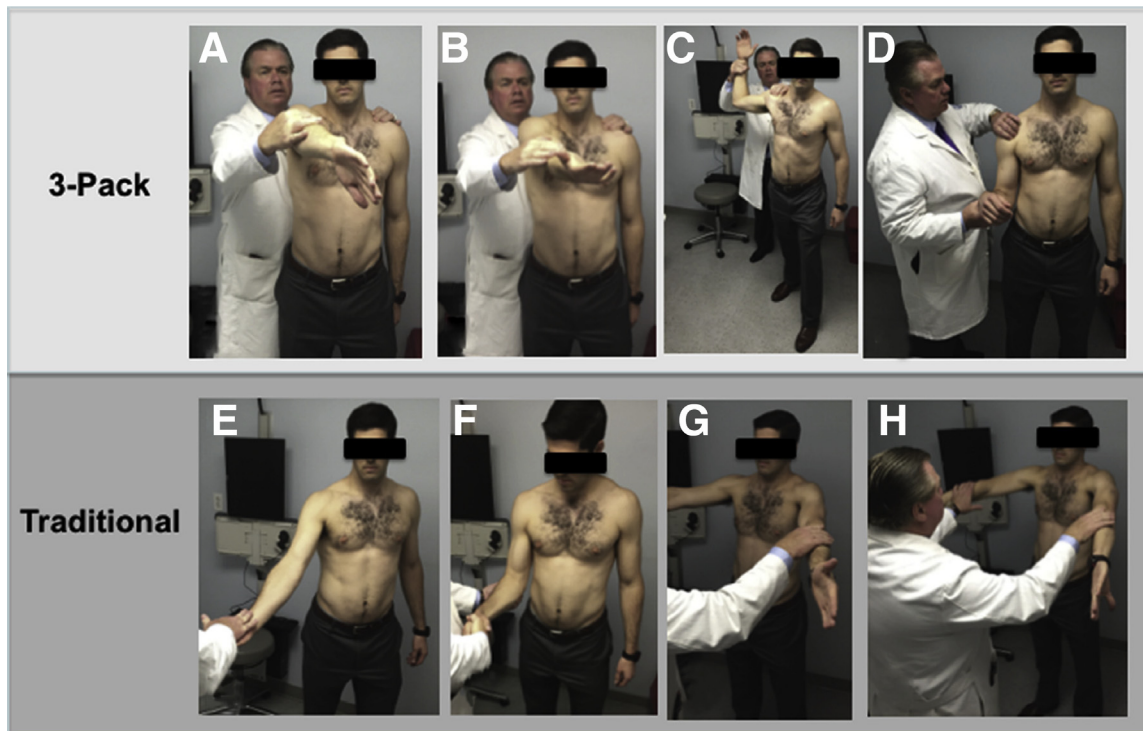


Fig 1. The 3-pack examination includes the active compression test (A, B), the throwing test (C), and palpation of the bicipital tunnel (D). Traditional physical examination maneuvers include Speed (E), Yergason (F), full can (G), and empty can (H). Reproduced with permission from Taylor et al.⁴

the remainder of the glenohumeral joint and enables concomitant pathology to be addressed.

Securing the Biceps

With the biceps resting in its natural position and with the upper extremity in neutral (arm at side, elbow flexed to 90°, and neutral forearm rotation), 2 18-gauge spinal needles are placed percutaneously through both rotator interval tissue and long head biceps tendon to capture the tendon in this anatomic position (Fig 2A). Care is taken to avoid injuring the articular surface of the humeral head. The needles are placed approximately 1 cm apart within the central portion of the tendon. The central trocar from each needle is removed, and individual strands of 0 PDS suture (Ethicon, Somerville, NJ) are placed through each needle and brought out through the anterior working portal with the use of a grasper (Fig 2B). The spinal needles are then removed leaving both PDS sutures in place. Slip knots are placed into both strands of the PDS, and each limb of a no. 2 Orthocord suture (Depuy Mitek, Raynham, MA) is securely tied down to the PDS suture. Simultaneously, both free PDS suture ends (from the percutaneous placed position) are pulled, shuttling the Orthocord suture into the glenohumeral joint and through the biceps tendon in horizontal mattress fashion with the suture loop on its undersurface (Fig 2C). Pulling on both ends of the Orthocord

serves to capture the biceps in its anatomic position, which in turn maintains natural length-tension relationship (Fig 2D). A snap is placed on the suture to prevent it from pulling out of the tendon. Tenotomy is then performed proximal to these securing sutures along the tendon's labral attachment. Following tenotomy, the tendon does not retract due to the suture in place (Fig 2E) and can easily be anatomically repositioned by pulling on both limbs of the sutures. Pearls and pitfalls of our technique are listed in Table 2.

Tenodesis

The surgeon can then proceed with standard open subpectoral tenodesis. The extra-articular long head of the biceps tendon has been identified within zone 3 of the bicipital tunnel (subpectoral region) and exposed without withdrawing the tendon from the tunnel. The location of intended osseous fixation is identified, and a pilot hole is drilled with a spade-tipped guidewire. The

Table 1. Supplies Necessary for Anatomic Tensioning Technique

30° arthroscope
One anterior working portal
2 18-gauge spinal needles
2 0 PDS sutures
One no. 2 high-strength suture
Arthroscopic grasper
Instrument to complete tenotomy

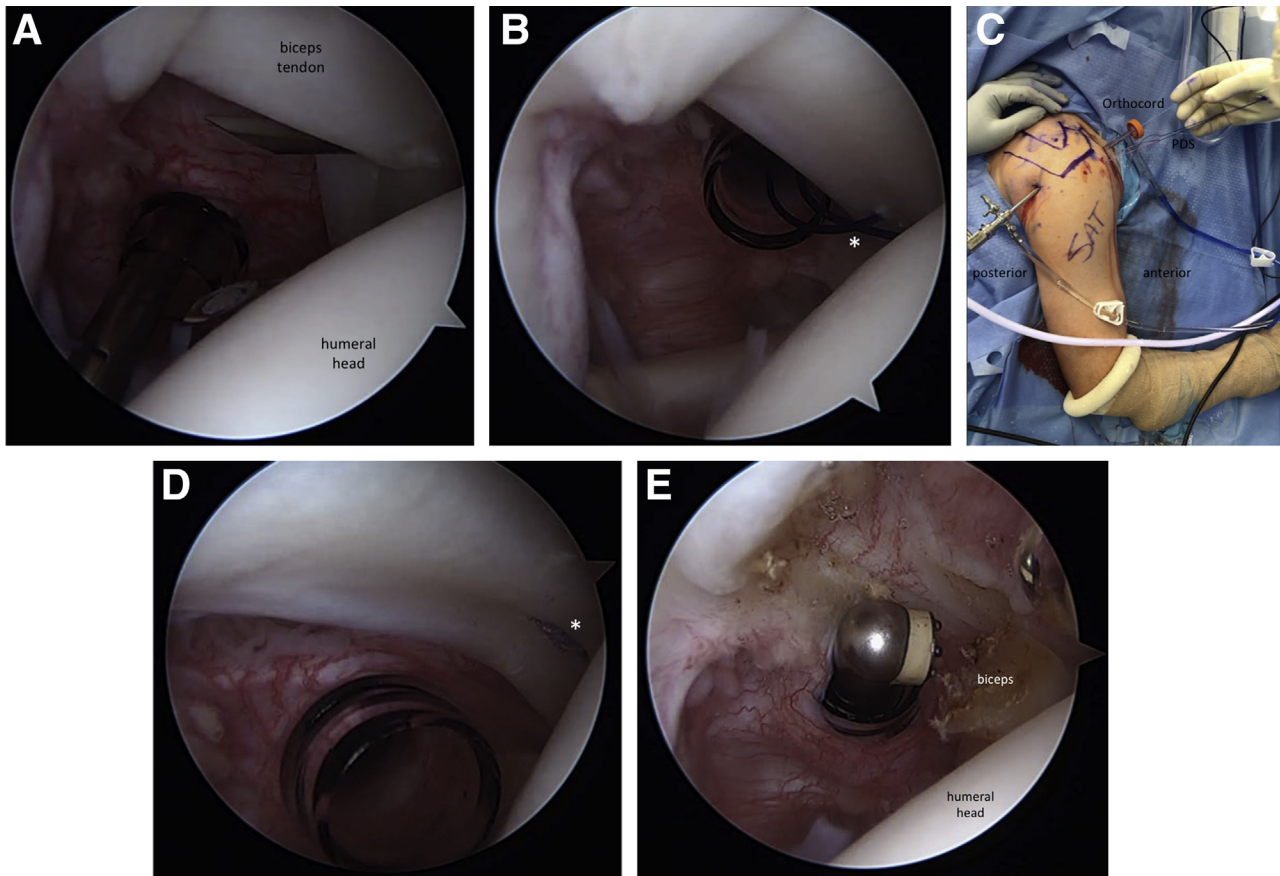


Fig 2. Temporary fixation of the biceps tendon in anatomic position prior to tenodesis. (A) Right shoulder in beach chair position viewed arthroscopically from the posterior portal with a cannula in the anterior (rotator interval) portal. Two 18-gauge spinal needles are used to capture the tendon and overlying rotator interval tissue. (B) Individual strands of 0 PDS (*) are placed through each needle and shuttled out an anterior working portal. (C) Slip knots are tied in each PDS suture and used to shuttle a single no. 2 high-strength suture into the joint such that it (D) captures the tendon in horizontal mattress fashion with the loop on the undersurface of the tendon (*). (E) Following tenotomy, the biceps is maintained in its anatomic position.

guidewire is left in place. Tension is then pulled on the percutaneously placed sutures proximally to reestablish the patient's anatomic length-tension relationship. The long head of the biceps tendon is marked at the location corresponding with the site of osseous fixation. The tendon is then retrieved into the wound. The proximal tension sutures are removed, and the tendon is secured with a whip stitch such that the 2 free ends of the suture emerge from the tendon at the previously

marked location of osseous fixation. Excess tendon is removed, and the sutures are passed through a tenodesis button (Arthrex, Naples, FL), which is subsequently passed, flipped uncortically, and then secured by tying down sutures.

Discussion

Regardless of the tenodesis technique, appropriate tensioning of the biceps tendon remains critical. Biceps

Table 2. Pearls and Pitfalls

Pearls	Pitfalls
Physical exam and injection into the biceps sheath are key to an accurate diagnosis.	Avoid pulling the stylette from the spinal needle until it is in the appropriate position as tissue caught in the tip may block sutures from entering.
Place both spinal needles prior to shuttling in the PDS suture.	A tissue bridge can be avoided with the use of a cannula through the anterior working portal.
Use high-strength suture to avoid breakage out prior to tenodesis. Place a clamp on the suture ends to avoid accidental suture removal. The percutaneously placed sutures also identify the leading edge of the supraspinatus if an examination of the bursal side of the rotator cuff is anticipated.	

Table 3. Advantages of the Presented Anatomic Tensioning Technique

Quick: typically <5 minutes
Efficient: requires minimal setup and no calculations
Cost-effective: uses inexpensive supplies typically already stocked in standard operating rooms
Anatomic: individualized treatment to maintain each patient's natural length-tension relationship

tenotomy alone, while still a viable option for certain patients, has demonstrated a significant rate of undesirable effects: up to 75% of men will develop a Popeye deformity, half of all patients have decreased elbow flexion strength, and almost 10% complain of significant cramping pain.⁹ Undoubtedly, these complications are related to a lack of tension on the biceps tendon; accordingly, we feel that maintaining a patient-specific length-tension relationship is a vital aspect to successful tenodesis, and we describe a simple and reproducible technique to do so.

Several authors have sought to determine the relationship of specific anatomic landmarks in order to help guide the surgeon on the issue of length-tension relationship. Table 3 details specific advantages of our technique. The musculotendinous junction (MTJ) of the long head of the biceps tendon may be an important landmark during fixation. Several cadaveric studies have examined this relationship. LaFrance et al. evaluated 10 cadaveric specimens and reported that the MTJ began 32 mm distal to the most proximal aspect of the pectoralis major tendon footprint, although there was wide variability (12 to 57 mm), with a standard deviation of 14 mm.¹¹ A similar study of 12 cadaveric upper extremities revealed a mean of distance of 22 mm from the superior border of the pectoralis major tendon to the MTJ but also noted a wide confidence interval of 12 to 31 mm.¹² The same group quantified the distance from the lesser tuberosity to the MTJ as 54 mm (confidence interval, 42 to 66 mm). Anatomic-based calculations have also been cited to serve as guides for varying tunnel size for either supra- or subpectoral tenodesis, but these are again based on cadaveric averages as opposed to a personalized, anatomic approach.¹⁴

Hussain and colleagues used cadaveric dissections to develop a predictive formula relating the position of the biceps to humeral length in an attempt to account for anatomic variability, but it is limited by the need for additional imaging and mathematical calculation.¹³

David and Schildhorn described a technique that stabilizes the biceps tendon in its native position proximally through the use of a spinal needle.¹⁵ While similar in concept to our technique, we feel the use of sutures ensures that the point of fixation is not compromised by inadvertent manipulation of the fixating spinal needle and does not hinder shoulder positioning while addressing other concomitant

shoulder pathology such as rotator cuff tears, impingement, or acromioclavicular arthrosis. Our technique also has the added advantage of marking the leading edge of the supraspinatus to facilitate bursal-sided interrogation of the rotator cuff. Furthermore, the proximal suture placement allows this tensioning technique to be used during both suprapectoral and subpectoral tenodesis techniques. We have been very satisfied with this technique and feel that it adds minimal time (less than 5 minutes) to the case yet yields great clinical benefit.

In conclusion, proper tensioning of the biceps tendon is important during tenodesis and may be improved by employing the simple technique described herein. In situ temporary proximal suture fixation enables patient-specific anatomic biceps tensioning without reliance on varied anatomic landmarks, additional imaging, or mathematical calculations.

References

1. Slenker NR, Lawson K, Ciccotti MG, Dodson CC, Cohen SB. Biceps tenotomy versus tenodesis: clinical outcomes. *Arthroscopy* 2012;28:576-582.
2. Hsu AR, Ghodadra NS, Provencher CMT, Lewis PB, Bach BR. Biceps tenotomy versus tenodesis: a review of clinical outcomes and biomechanical results. *J Shoulder Elbow Surg* 2011;20:326-332.
3. Patel KV, Bravman J, Vidal A, Chrisman A, McCarty E. Biceps tenotomy versus tenodesis. *Clin Sports Med* 2016;35:93-111.
4. Taylor SA, Newman AM, Dawson C, et al. The "3-pack" examination is critical for comprehensive evaluation of the biceps-labrum complex and the bicipital tunnel: a prospective study. *Arthroscopy* 2017;33:28-38.
5. Taylor SA, Ramkumar PN, Fabricant PD, et al. The clinical impact of bicipital tunnel decompression during long head of the biceps tendon surgery: a systematic review and meta-analysis. *Arthroscopy* 2016;32:1155-1164.
6. Taylor SA, Fabricant PD, Baret NJ, et al. Midterm clinical outcomes for arthroscopic subdeltoid transfer of the long head of the biceps tendon to the conjoint tendon. *Arthroscopy* 2014;30:1574-1581.
7. Drakos MC, Verma NN, Gulotta LV, et al. Arthroscopic transfer of the long head of the biceps tendon: functional outcome and clinical results. *Arthroscopy* 2008;24:217-223.
8. Provencher MT, LeClere LE, Romeo AA. Subpectoral biceps tenodesis. *Sports Med Arthroscopy Rev* 2008;16:170-176.
9. Lim TK, Moon ES, Koh KH, Yoo JC. Patient-related factors and complications after arthroscopic tenotomy of the long head of the biceps tendon. *Am J Sports Med* 2011;39:783-789.
10. Kelly AM, Drakos MC, Fealy S, Taylor SA, O'Brien SJ. Arthroscopic release of the long head of the biceps tendon functional outcome and clinical results. *Am J Sports Med* 2005;33:208-213.
11. LaFrance R, Madsen W, Yaseen Z, Giordano B, Maloney M, Voloshin I. Relevant anatomic landmarks and measurements for biceps tenodesis. *Am J Sports Med* 2013;41:1395-1399.

12. Jarrett CD, McClelland WB, Xerogeanes JW. Minimally invasive proximal biceps tenodesis: an anatomical study for optimal placement and safe surgical technique. *J Shoulder Elbow Surg* 2011;20:477-480.
13. Hussain WM, Reddy D, Atanda A, Jones M, Schickendantz M, Terry MA. The longitudinal anatomy of the long head of the biceps tendon and implications on tenodesis. *Knee Surg Sports Traumatol Arthrosc* 2015;23:1518-1523.
14. Denard PJ, Dai X, Hanypsiak BT, Burkhart SS. Anatomy of the biceps tendon: implications for restoring physiological length-tension relation during biceps tenodesis with interference screw fixation. *Arthroscopy* 2012;28:1352-1358.
15. David TS, Schildhorn JC. Arthroscopic suprapectoral tenodesis of the long head biceps: reproducing an anatomic length-tension relationship. *Arthrosc Techn* 2012;1:e127-e132.