

Knuckle Pads Successfully Treated with 2% Crisaborole Ointment Combined with Triamcinolone Acetonide and Neomycin Plaster: A Case Report

Yimin Liang*, Jingyao Liang*, Qiongxiao Huang , Xin Tian , Lei Shao, Manqi Xia, Yumei Liu

Institute of Dermatology, Guangzhou Medical University, Department of Dermatology, Guangzhou Institute of Dermatology, Guangzhou, People's Republic of China

*These authors contributed equally to this work

Correspondence: Yumei Liu, Department of Dermatology, Guangzhou Institute of Dermatology, 56 HengFu Road, Guangzhou, 510095, People's Republic of China, Tel +86-13660403350, Email liuyumei1109@163.com

Abstract: Knuckle pads (KPs) are benign hyperkeratotic fibrous thickening skin disorder characterized by nodules or plaques located on the extensor surface of the joints. However, there are no specific treatments for KPs so far. Here, we reported a case of KPs successfully treated with 2% crisaborole ointment combined with triamcinolone acetonide and neomycin plaster. This combined therapy might be a new therapeutic option for KPs.

Keywords: knuckle pads, crisaborole, PDE-4 inhibitors, primary, emerging therapy

Introduction

Knuckle pads (KPs) are usually presented with nodules or plaques located on the extensor surface of the joint, which are caused by fibrous thickening of the skin.^{1,2} The diagnosis of knuckle pads mainly depends on clinical presentation, and it can be confirmed by ultrasound imaging, thus limiting the risk of misdiagnosis.¹⁻³ Histopathologically, patients usually present with acanthosis with hyperkeratosis, connective tissue hyperplasia, and collagen fiber hypertrophy.^{2,4} The benign skin lesions do not affect joint movement with no particular symptoms and generally do not require treatment. However, in many patients KPs are badly tolerated due to cosmetic reasons, and unfortunately many of the conventional treatments including intralesional corticosteroid injection and surgery are usually ineffective as well as bring a series of traumatic problems and side effects.⁵⁻⁷ Despite this, some new potential therapies are emerging.^{2,7-10} Here, we reported a case of KPs successfully treated with 2% crisaborole ointment combined with triamcinolone acetonide and neomycin plaster.

Case Report

A 45-year-old man presented to our hospital with a six-year history of asymptomatic thick plaques on the extensor aspect of both knuckles and ankles (Figures 1A, 2A and B) that had been histopathologically diagnosed as knuckle pads (Figure 3), denying any repetitive scratching, rubbing to this area or a family history. He had previously undergone intralesional steroid injections several times and received ultrahigh potency topical corticosteroid like clobetasol and flumethasone for three years but with poor efficacy. Several depigmentary rings were seen around the plaques due to long-term use of the glucocorticoid (Figure 1A). Given the poor efficacy of the previous treatments, the patient agreed to receive a new treatment option. He was treated with triamcinolone acetonide and neomycin plaster quaque nocte, removed the plaster on another day then applied 2% crisaborole ointment twice daily. After two-week treatment, we could observe a remarkable improvement – the skin lesions became significantly thinner, and there were no adverse

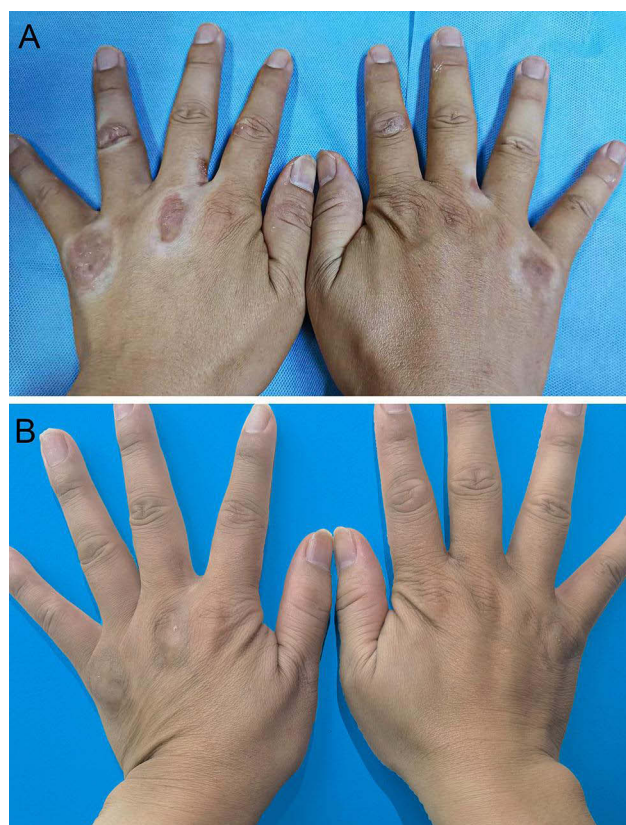


Figure 1 Plaques in extensor interphalangeal joints of both hands before and after treatment. **(A)** Plaques in extensor interphalangeal joints of both hands before treatment. **(B)** Two months after treatment.

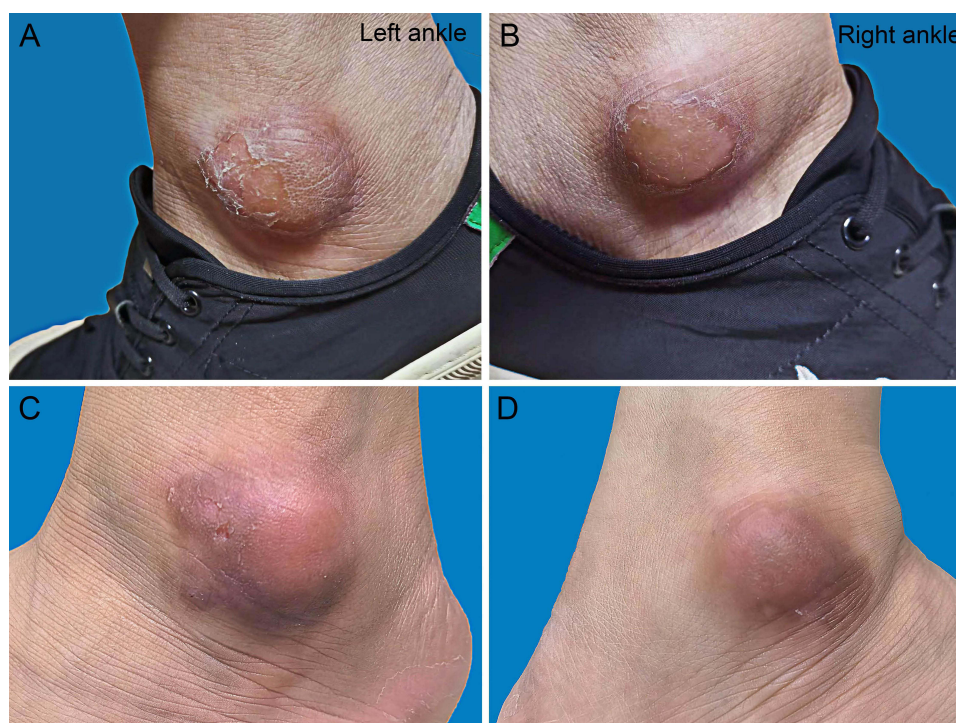

Figure 2 Plaques on both ankles before and after treatment. **(A and B)** Plaques on both ankles before treatment. **(C and D)** Two months after treatment.

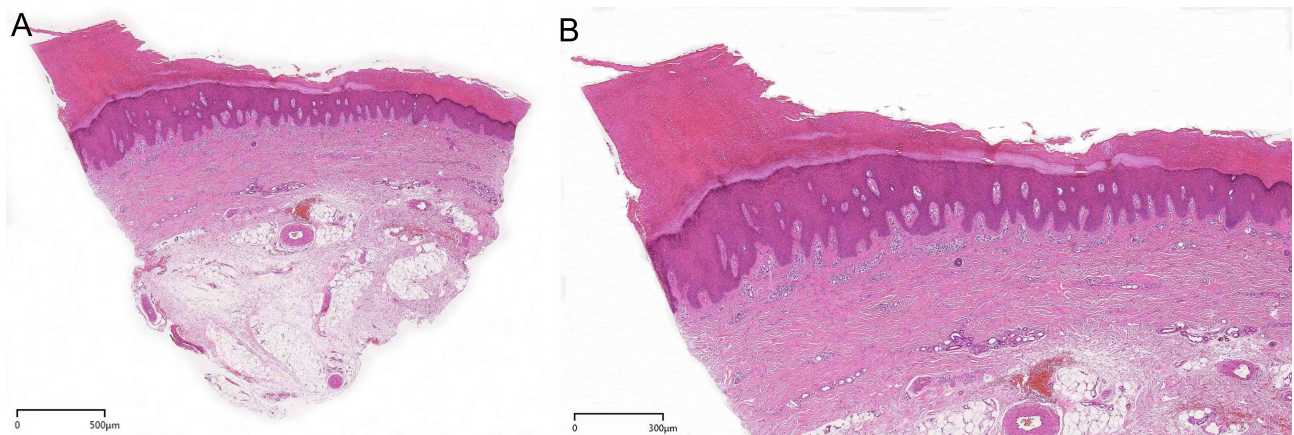


Figure 3 Histopathology of a plaque on the hand knuckle. **(A)** Hematoxylin-eosin (H&E) staining shows compact hyperkeratosis, epidermal hyperplasia, elongation of rete ridges and subdermal fibrous tissue hyperplasia (original magnification: 20×). **(B)** H&E, at a higher magnification of Figure 3A (original magnification: 40×).

effects. Improvement was sustained at 2-month follow-up with enhanced repigmentation of the depigmentary rings around the plaques (Figures 1B, 2C and D).

Discussion

Although most Knuckle pads (KPs) do not require treatment, some patients desire intervention for cosmetic purposes.² Traditional therapies such as topical corticosteroids, keratolytics, and intralesional corticosteroid injection have a limited impact. Some reports have indicated successful application of intralesional 5-fluorouracil injection but it shows toxicity including gastrointestinal discomfort and bone marrow suppression.⁸ Recently, some treatments such as laser, high-dose salicylic acid combined with 40% urea cream and the combination of topical cantharidin-podophylotoxin-salicylic acid showed a successful therapeutic strategy for KPs.^{2,7,9} However, the invasive nature of laser therapy and the drug-induced skin irritation cannot be avoided. Non-traumatic and low-side effect treatment for KPs are eagerly developed. In addition, a recent study mentioned that a medical silicone gel sheet has been used to effectively treat a case of pseudo-knuckle pads.¹⁰ The therapeutic method is simple, non-invasive and is more receptive for patients. Nonetheless, it needs to be applied to the lesion for most of the day, which may cause the peeling of silicone gel patch owing to daily joint movement.

Crisaborole, a topical phosphodiesterase-4 (PDE-4) inhibitor, shows an anti-inflammatory effect by reducing cyclic adenosine monophosphate (cAMP) degradations.¹¹ However, it is currently only approved for the treatment of mild-to-moderate atopic dermatitis in adults and children greater than two years of age in China.¹² Several studies have indicated that crisaborole has good therapeutic effects on some other inflammatory dermatoses such as psoriasis and vitiligo¹³ as well as hypertrophic lesions like neurodermatitis.¹⁴ Therefore, crisaborole may have a great potential for other hypertrophic lesions. Previous studies showed that PDE-4 inhibitors could block keratinocyte proliferation as well as fibroblast chemotaxis by up-regulating cAMP,¹⁵ which controls cell proliferation, differentiation, and migration.¹⁶ Crisaborole is a boron-containing tiny molecule ointment that can effectively penetrate the skin and it also contains vaseline which can soften the corneum. Based on the possible mechanisms of PDE-4 inhibitors and the special drug structure of crisaborole itself, we speculated that crisaborole may treat KPs well through inhibiting hyperkeratosis and fibroblast chemotaxis.

Among triamcinolone acetonide and neomycin plaster, triamcinolone acetonide has a strong anti-inflammatory effect.¹⁷ The plaster is often used as a patch that can offer an occlusive environment, softening the skin lesion, and improve medication permeability.¹⁸

In this case, we observed a remarkable therapeutic effect and crisaborole was well tolerated in KP lesions. The combination with the plaster can simultaneously relieve skin depigmentation and may significantly shorten the time of the high potency corticosteroid use in the subsequent maintenance therapy. It is convenient and simple, avoiding the risk of traumatic and painful caused by local injection and surgery, and may be a beneficial therapeutic option for patients

who wish to minimize medication side effects, but this still requires controlled trials with a larger sample size and to set up single medication regimens to further evaluate the efficacy of crisaborole as a treatment for KPs.

Conclusion

Knuckle pads (KPs) are benign skin disorder with only cosmetic concerns but for which no specific therapeutic approach exists so far. Two percent crisaborole ointment combined with triamcinolone acetonide and neomycin plaster may be expected to be a novel treatment option for KPs that shows convenience and good tolerance.

Consent Statement

The patient had given written informed consent for the publication of the clinical details and accompanying images. Institutional approval was not required to publish the case details.

Funding

This study was supported by the Guangzhou Health Science and Technology Project (grant number 20211A011067) and the Science and Technology Planning Project of Guangzhou (grant number 201904010082).

Disclosure

Yimin Liang and Jingyao Liang are co-first authors for this study. The authors report no conflicts of interest in this work.

References

1. Tamborrini G, Gengenbacher M, Bianchi S. Knuckle pads - a rare finding. *J Ultrason*. 2012;12(51):493–498. doi:10.15557/JoU.2012.0037
2. Sogliani D, Mura C, Tamborrini G. Successful treatment of idiopathic knuckle pads with a combination of high-dose salicylic acid and urea topical keratolytics: a case report. *Dermatol Rep*. 2021;13(1):9072. doi:10.4081/dr.2021.9072
3. De Keersmaecker A, Vanhoenacker F. Imaging features of knuckle pads. *J Belg Soc Radiol*. 2016;100(1):67. doi:10.5334/jbr-btr.1096
4. Lubner AJ, Bienenfeld AR, Clark CM, et al. Characterization of knuckle (Garrod) pads using optical coherence tomography in vivo. *Cutis*. 2015;96(3):E10–1.
5. Paller AS, Hebert AA. Knuckle pads in children. *Am J Dis Child*. 1986;140(9):915–917. doi:10.1001/archpedi.1986.02140230085039
6. Caroli A, Zanasi S, Marcuzzi A, et al. Epidemiological and structural findings supporting the fibromatous origin of dorsal knuckle pads. *J Hand Surg Br*. 1991;16(3):258–262. doi:10.1016/0266-7681(91)90049-t
7. Herold M, Russe-Wilflingseder K. Knuckle pads—a common problem but good to treat by laser. *AIP Conf Proc*. 2010;1226(1):179–183. doi:10.1063/1.3453778
8. Weiss E, Amini S. A novel treatment for knuckle pads with intralesional Fluorouracil. *Arch Dermatol*. 2007;143(11):1458–1460. doi:10.1001/archderm.143.11.1458
9. Hasbún C, Sandoval M, Curi M. A novel treatment for idiopathic knuckle pads with cantharidin-podophyloxytoxin-salicylic acid. *Pediatr Dermatol*. 2019;36(4):544–545. doi:10.1111/pde.13803
10. Sławińska M, Nowicki RJ, Sobjanek M. Silicone gel sheets in treatment of pseudo-knuckle pads: a case report. *Dermatol Ther*. 2022;35(4):e15325. doi:10.1111/dth.15325
11. Hoy SM. Crisaborole ointment 2%: a review in mild to moderate atopic dermatitis. *Am J Clin Dermatol*. 2017;18(6):837–843. doi:10.1007/s40257-017-0327-4
12. Paller AS, Tom WL, Lebwohl MG, et al. Efficacy and safety of crisaborole ointment, a novel, nonsteroidal phosphodiesterase 4 (PDE4) inhibitor for the topical treatment of atopic dermatitis (AD) in children and adults. *J Am Acad Dermatol*. 2016;75(3):494–503.e6. doi:10.1016/j.jaad.2016.05.046
13. Makins C, Sanghera R, Grewal PS. Off-label therapeutic potential of crisaborole. *J Cutan Med Surg*. 2020;24(3):292–296. doi:10.1177/1203475420909794
14. Wei G, Rodriguez-Waitkus P, Soylu L. A rare case of lichen simplex chronicus in an adolescent female successfully managed with Crisaborole. *Dermatol Ther*. 2021;34(2):e14752. doi:10.1111/dth.14752
15. Nakajima K, Nakajima R, Morisaka H, et al. Beneficial impact of apremilast on palmoplantar keratoderms. *Acta Derm Venereol*. 2021;101(4):adv00437. doi:10.2340/00015555-3805
16. Kohyama T, Liu X, Wen FQ, et al. PDE4 inhibitors attenuate fibroblast chemotaxis and contraction of native collagen gels. *Am J Respir Cell Mol Biol*. 2002;26(6):694–701. doi:10.1165/ajrcmb.26.6.4743
17. Pellanda C, Strub C, Figueiredo V, et al. Topical bioavailability of triamcinolone acetonide: effect of occlusion. *Skin Pharmacol Physiol*. 2007;20(1):50–56. doi:10.1159/000096172
18. Ly S, Amici JM. Role of betamethasone valerate 2.250 mg medicated plaster in the treatment of psoriasis and other dermatological pathologies: a review. *Drugs Context*. 2018;7:212539. doi:10.7573/dic.212539

Clinical, Cosmetic and Investigational Dermatology

Dovepress

Publish your work in this journal

Clinical, Cosmetic and Investigational Dermatology is an international, peer-reviewed, open access, online journal that focuses on the latest clinical and experimental research in all aspects of skin disease and cosmetic interventions. This journal is indexed on CAS. The manuscript management system is completely online and includes a very quick and fair peer-review system, which is all easy to use. Visit <http://www.dovepress.com/testimonials.php> to read real quotes from published authors.

Submit your manuscript here: <https://www.dovepress.com/clinical-cosmetic-and-investigational-dermatology-journal>