



Association between femoroacetabular impingement syndrome and limited lateral hip rotation in young athletes: A case–control study

Zoran Šarčević^{1,2} , and Andreja Tepavčević^{3,4}

Abstract

Purpose: Hip pain is very common in athletes. One of the main disorders causing hip pain is femoroacetabular impingement syndrome. This study aimed to identify a new etiological risk factor for femoroacetabular impingement in the hip.

Methods: This case–control study included 88 young athletes, 34 with pains in the hip (supposedly with femoroacetabular impingement) and 54 controls. Femoroacetabular impingement was diagnosed with a flexion, adduction, internal, and rotation test and a particular type of hip pain during sports activities. The medial (internal) and lateral (external) hip ranges of rotation have been measured with an inclinometer. The data were analyzed using a *t*-test, the Wilcoxon test, the Mann–Whitney *U* test, and logistic regression.

Results: There is a statistically significant difference in the external hip rotation range between the athletes with hip pain and controls. Logistic regression analysis showed that external hip range of motion is significantly associated with femoroacetabular impingement.

Conclusion: Limited external hip range of motion was found to be significantly associated with the diagnosis of femoroacetabular impingement in young athletes. A biomechanical explanation of the hypothesis that limited external hip rotation can predict femoroacetabular impingement is given. Based on our results, the hip's lateral range of motion screening can be advised within the regular screening of young athletes. Kinesiotherapeutic procedures for stretching the muscles of the medial hip rotors can be advised to prevent the lateral hip rotation restriction and lower the risk of femoroacetabular impingement in case the limited rotation is due to muscular restriction.

Level of evidence: level III—case–control study.

Keywords: Femoroacetabular impingement, hip pain, hip injury, medial hip range of motion, lateral hip range of motion

Introduction

Hip pain is very common in athletes. One of the main disorders causing hip pain is femoroacetabular impingement (FAI) syndrome.¹ FAI is a condition of abnormal contact between the proximal femur and the acetabulum which do not come into contact in the normal physiological range.² The causes of FAI are either abnormal bony morphology or excessive range of motion (ROM).³ There are two major sub-groups of FAI: pincer- and cam-type deformity, with 50%–70% of patients having both forms of impingement.⁴

Cam-type FAI is non-spherical osseous prominence of the proximal femoral neck or head–neck junction. Pincer-type FAI is excessive acetabular coverage over the femoral head, which can occur owing to several morphologic variants.⁵

The characteristic of FAI syndrome is a pain in the hip or groin (possibly in the back, buttock, or thigh), typically motion-related or position-related, with symptoms occurring during or after sports activity (e.g. football), or with a supraphysiological ROM (e.g. dance, gymnastics).¹ FAI is

¹Sports Medicine Centre, Novi Sad Health Care Centre, Novi Sad, Serbia

²Faculty of Medicine, University of Novi Sad, Novi Sad, Serbia

³Faculty of Sciences, University of Novi Sad, Novi Sad, Serbia

⁴Mathematical Institute SANU, Belgrade, Serbia

Date Received: 10 March 2022; accepted: 10 May 2022

Corresponding Author:

Zoran Šarčević, Sports Medicine Centre, Novi Sad Health Care Centre, Branka Radicevica 51, Novi Sad 21000, Serbia.

Email: sarceviczoranat@gmail.com

regarded as an etiological risk factor for the development of early osteoarthritis in non-dysplastic hips.⁶ High activity level in young athletes is closely related to the development of FAI (cam-type is more often seen in children).^{7,8}

An international multidisciplinary agreement on the diagnosis, treatment principles, and key terminology relating to FAI syndrome (the Warwick Agreement on FAI syndrome) was made in 2016.⁹ FAI syndrome is defined as a motion-related clinical disorder of the hip with a triad of symptoms, clinical signs, and imaging findings, which represents symptomatic premature contact between the proximal femur and the acetabulum.⁹

FAI has been recognized recently as a health condition that is an important contributor to hip pain and the number of patients being treated for FAI has risen sharply in many countries^{9,10} (among others in the United States,^{11,12} the United Kingdom,¹³ and Turkey¹⁴). FAI was found to be very common in an asymptomatic population: a study on 1076 asymptomatic patients showed that the prevalence of radiological FAI findings in the adult population was 29.6% in Turkey.¹⁴

The athletes with symptomatic FAI are at a great performance disadvantage compared with healthy competitors. A study¹⁵ indicated that arthroscopic correction (including labral repair) in athletes with symptomatic FAI restored athletic performance within 1 year. Meta-analysis¹⁶ aiming to compare the outcomes of patients with FAI syndrome treated with hip arthroscopy with those treated with physical therapy alone showed that patients treated with hip arthroscopy had statistically superior hip-related outcomes in the short term compared with those treated with physical therapy alone.

Another article¹⁷ highlighted that young active individuals with FAI syndrome should be primarily treated with physiotherapist-led interventions and as a secondary option, surgical interventions. The physiotherapist-led interventions suggested were hip and trunk muscle strengthening, functional and plyometric retraining, and optimization of ROMs.¹⁷

The type of pain in FAI syndrome is typical; the most commonly used test, flexion, adduction, internal, and rotation (FADIR), is sensitive but not specific.¹⁸ A recent study¹⁹ aimed to evaluate the inter-rater agreement and diagnostic accuracy of clinical tests to detect patients with FAI syndrome. The conclusion was that the clinical tests for FAI (among which FADIR test) in combination with a hip ROM test may be used to accurately identify patients who potentially have FAI syndrome.¹⁹

This study aimed to discover factors that are correlated with the FAI syndrome in young athletes. Factors considered were the medial and lateral hip rotation ROMs. In this study, limited lateral hip rotation ROM was found to be significantly associated with the diagnosis of FAI in young athletes. Another factor, medial hip rotation did not seem to be related to the FAI syndrome.

Material and methods

The results of a case-control study, level of evidence 3b are presented here.

Participants were 88 children athletes that trained in soccer, basketball, volleyball, handball, ballet, and other sports, 63 males and 25 females aged 8–17 years. The case group consisted of 34 children diagnosed with FAI syndrome. The control group consisted of 54 children of similar age that come to the Sports medicine center for the control checkup.

Since four children had symptoms of FAI on both sides, there were 38 sides with the symptoms of FAI (cases) and 138 healthy sides (controls). Thirty children were having the symptoms of FAI on one side, most of them on the left side. All children were examined at a regular checkup by a sports physician at Novi Sad Health Care Centre, Sports Medicine Center in the period from 1 February 2018 to 1 June 2018.

The inclusion criteria for all study participants were aged between 8 and 17 years, that they regularly trained and were not absent from the training in the previous 6 months, and willingness of children and their parents to provide informed consent.

The exclusion criteria for all participants were muscle injuries of the legs, gluteal, abdominal, and lumbar regions, positive tests for lumbar radiculopathy, painful torso movements, urinary tract infections, hyperlaxity, or any systemic disorder that may result in joint hypermobility (like Ehlers-Danlos syndrome). The case group consisted of the children with FAI syndrome diagnosed by two of three elements of the triad (symptoms and clinical signs). The inclusion criteria for the control group were that they are athletes of the same age, same sports, and the similar number of training hours as children in the case group, but without symptoms and clinical signs of the FAI syndrome.

The factors were chosen by measuring the anthropometric characteristics of patients in everyday practice and knowing the basic mechanical principles. The case group had two positive segments of the triad of the FAI syndrome: the positive FADIR test and the characteristics of hip pain connected to sports activities.^{9,19}

In all cases, FADIR tests were by a single experienced physician. Hip medial (internal) and lateral (external) ROMs were measured in degrees by the baseline bubble inclinometer Fabrication Enterprises, Inc using the method described in book²⁰ (Figures 1 and 2).

Hip external rotation is defined as the lateral rotary movement of the femur in the transverse plane around its longitudinal axis away from the midline; it is also called lateral rotation. Hip internal rotation is defined as the medial rotary movement of the femur in the transverse plane around its longitudinal axis toward the midline; it is also called medial rotation.²¹

Started position for both measurements was seated, with hip and knee flexed to 90 degrees and a folded towel

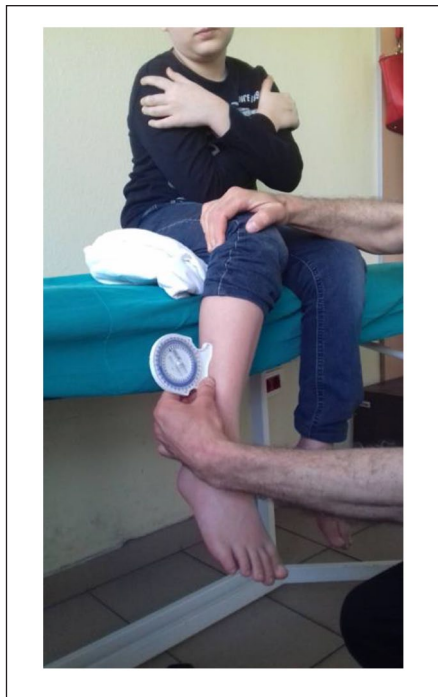


Figure 1. Measuring hip medial rotation.

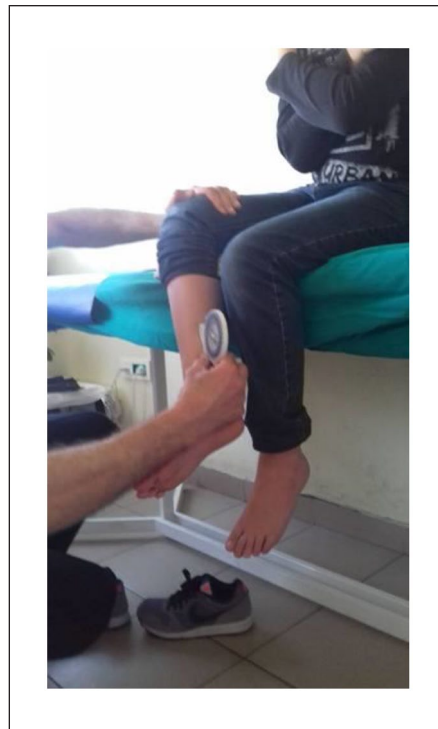


Figure 2. Measuring hip lateral rotation.

under the thigh. Weight was equally distributed over both ischial tuberosities. After instructing the patient in the motion desired, the patient's hip was medially (or laterally) rotated through the available ROM by keeping the thigh stationary and moving the leg, foot, and ankle laterally (or medially) (Figures 1 and 2). During measurement, examiner's hand stabilized the thigh against the table. The inclinometer was placed as in Figures 1 and 2 and the angles at maximal ROMs were recorded.

A single experienced sports physician took all the measurements by inclinometer in all children. To prevent bias, at the moment of measurement, he did not have information on which children had pains in the hip.

After the measurement with the inclinometer, the child was asked whether he or she had the pain in the hip and to explain the type of the pain and the FADIR test was done by the same examiner. The examiner had an extensive clinical experience (more than 15 years) in the assessment and treatment of people with hip and groin pain.

Statistical analysis was performed using Dell Inc. (2016) Dell Statistica (data analysis software system), version 13 (Round Rock, TX, USA; software.dell.com) and MedCalc Statistical Software version 18.2.1 (MedCalc Software bvba, Ostend, Belgium; <http://www.medcalc.org>; 2018).

Descriptive analysis was first conducted. Furthermore, the data were analyzed using *t*-tests, the Mann–Whitney *U* test, the Wilcoxon matched-pair test, and binary logistic regression.

By *t*-test for dependent samples and the Wilcoxon matched-pair test, the medial and lateral hip ROMs were

compared in the affected and non-affected sides in 30 children who had FAI only on one side. By *t*-test for independent samples and Mann–Whitney *U* test, the medial and lateral hip ROMs were compared in all affected sides (38) with the medial and lateral hip ROMs in all non-affected sides (all sides in the control group and non-affected sides of the case group, 138 altogether).

A binary logistic regression was performed with independent variables: lateral hip ROM and medial hip ROM and a dependent variable representing the presence (or absence) of FAI. A logistic regression model was made, and a receiver operating characteristics (ROCs) curve was then calculated.

Post hoc sample size calculation was done in the MedCalc Statistical Software considering correlation coefficients obtained, Type I error rate alpha 0.05, and power 0.95. In the results reported the sample sizes were adequate for the required rates of Type I error and power. The records with missing data were excluded from the study.

The study was approved by the Ethical committee of Novi Sad Health Care Centre (no. 21/44-1). The subjects and their parents provided their informed consent to participate in the study. Experiments reported in the manuscript were performed by the ethical standards of the Helsinki Declaration.

Results

Participants were 88 children athletes (soccer, basketball, volleyball, handball, ballet, and others) (63 males and 25

females) aged 8–17 years (mean \pm standard deviation (SD)=11.83 \pm 2.04). The case group consisted of 34 children diagnosed with FAI syndrome aged (mean \pm SD)=11.71 \pm 2.04. The control group consisted of 54 children aged (mean \pm SD)=11.91 \pm 2.06. The numbers of training hours per week were 4–6, median 5, same in the case as well as in the control group.

By the D'Agostino–Pearson test for normal distribution of logarithmic transformation of differences (between affected and non-affected sides in 30 persons who had FAI only on one side) of the external hip rotation ROM, we can accept the assumption of normality ($p=0.1263$). The difference in the logarithmic transformation of the average external hip rotation ROM (between affected and non-affected sides in 30 persons who had FAI only on one side) was found to be statistically significant by t -test for dependent samples ($t=6.79$, $p<0.0001$). Since there was a relatively small number of cases, the result was confirmed by Wilcoxon matched-pair test ($Z=4.35$, $p<0.0001$). By the D'Agostino–Pearson test for normal distribution of differences (between affected and non-affected sides in 30 persons who had FAI only on one side) of the internal hip ROM, we can accept the assumption of normality ($p=0.4690$).

The difference in the internal hip ROM in affected and non-affected sides of cases with FAI (by t -test for dependent samples) was not found to be statistically different ($t=0.358$, $p=0.7229$). Since there was a relatively small number of cases, the result was confirmed by the Wilcoxon matched-pair test ($Z=0.11$, $p=0.91$). The external and internal hip rotation ROMs were further compared in all affected sides (38) with the external and internal hip rotations in all non-affected sides (all sides in the control group and non-affected sides of the case group, 138 altogether).

The average external rotation ROM in all affected sides was (mean \pm SD)=34.39° \pm 3.78°, 95% confidence interval=(33.15°,35.64°). The average external rotation ROM in all non-affected sides was (mean \pm SD)=45.20° \pm 6.98°, 95% confidence interval=(44.03°,46.38°). The average external rotation ROMs were found to be statistically different ($t=9.17$, $p<0.0001$) comparing all affected and all non-affected sides.

The average internal rotation ROM in all non-affected sides was (mean \pm SD)=42.84° \pm 4.59°, 95% confidence interval (41.33°,44.35°). The average internal rotation ROM in all non-affected sides was (mean \pm SD)=43.96° \pm 7.06°, 95% confidence interval=(42.77°,45.15°). Since the assumptions of normality and homoscedasticity were violated, the Mann–Whitney U test was used for comparison of the external and internal hip rotation ROMs in all affected sides with the corresponding ROMs in all non-affected sides.

The statistical significance of the difference in the average external rotation ROM in all affected sides compared with the same ROM in all non-affected sides was

confirmed by the Mann–Whitney U test ($Z=7.70$, $p<0.0001$). By the Mann–Whitney U test ($Z=1.07$, $p=0.28$), it was confirmed that the difference in average internal rotation ROMs between all affected and all non-affected sides was not statistically significant.

Logistic regression analyses showed that the limited external rotation ROM was a good predictor of the presence of FAI 85.23%. The limited external rotation range was significantly associated with the probability of the presence of FAI ($p<0.0001$, Wald's test). The variance explained in the final model by Nagelkerke R^2 was 0.535.

By logistic regression, coefficients -0.3 and 10.8 were obtained; hence, the probability that a person with a value x of the variable representing a range of external rotation would have FAI is given by formula (1)

$$P(x) = \frac{1}{(1 + \exp(-0.3x + 10.8))} \quad (1)$$

Using this formula, the value x for cut-off value 0.5 was calculated

$$P(x) = \frac{1}{(1 + \exp(-0.3x + 10.8))} = 0.5$$

The solution to this equation is 36°. If the angle of external rotation is less than 36°, one can conclude that a person might have FAI syndrome. The discrimination ability of the ROC curve according to the value of the area under the curve (0.908) is excellent.

Discussion

To the authors' knowledge, this study is the first one that points out the association between insufficient limited lateral rotation and FAI in young active sportspersons.

Statistical analysis showed a statistically significant difference in lateral rotation ROM in the case group compared with the control group. Logistic regression showed that the variable representing the lateral rotation ROM is a good predictor of the presence of FAI.

The results of this study showed that the diagnosis of FAI and the limited lateral rotation ROM was in a strong correlation. Future studies are needed to establish some further causal relationships between these two variables. However, we hypothesize that the limited external rotation ROM can predict FAI appearance on the same side, and this is explained biomechanically. Reduced external rotation of the hip is caused by the internal hip rotator muscle shortening. Shortening of the internal hip rotators and reduced external rotation ROM is frequently present in some sports and some types of training.^{22,23} There is accumulated evidence that some types of intensive training cause shortening of the internal rotators of the hip.

For example, in the case of soccer, at the moment of the player's kicking the ball, internal rotation of the hip of the support leg occurs (in other words, the contraction of the muscles of the internal rotators of the hip happens).

Moreover, shifting and rotating the upper body are common elements of a soccer game that also influence the shortening of the hip rotators. According to a study,²⁴ hip ROM decreases gradually with each year of soccer playing.

After intensive football training, as a consequence, the muscles of the hamstrings, quadriceps femoris, and the internal rotators of the hip that support the foot are shortened, which causes a limited range of external rotation. Consequently, external rotation of the hip is not in the physiological range that is necessary for specific movements in sports. We suppose that in case of reduced external rotation, to make some movements, compensatory retroversion of the hip takes place to maintain necessary mobility. In this way, a larger surface of the contact between the acetabulum and the head of the femur is obtained. This contact causes repetitive microtrauma that could finally lead to FAI. Acetabular retroversion is a malorientation of the acetabulum in the sagittal plane, and it is associated with changes in load transmission across the hip. The pathophysiological basis of acetabular retroversion is an anterior acetabular hyper-coverage and an overall pelvic rotation.²⁵ Our hypothesis is that attempt to produce some movements in the case of reduced external rotation produces slight acetabular retroversion, which finally leads to FAI due to repetitive microtrauma.

A confirmation of this hypothesis would also be the fact that a high percentage of soccer players have reduced external rotation of the hip, and at the same time, a high percentage of them have initial changes in the hip. In retroversion of the hip, a contact of the acetabulum and the femur occurs, which is today accepted by the consensus as a condition for the occurrence of changes in the hip. This can be confirmed by radiography or magnetic resonance imaging (MRI) records in the case of FAI syndrome.

Some participants of the study, young soccer players had pain in the backside of the groin of the support leg during running. The pain stopped after the running ended. All of them had a positive FADIR test on that leg and also, they had a limited range of the external rotation of the hip. As already mentioned, the biomechanical explanation is that at the moment of kicking the ball, the internal rotation of the hip of the support leg occurs (in other words, the contraction of the muscles of the internal rotators of the hip happens). Consequently, after intensive football training, the muscles of the hamstrings, quadriceps femoris, are shortened, and the internal rotators of the hip support foot are shortened which might cause a limited range of external rotation and FAI syndrome.

Some of the cases in the study were young ballet dancers. In ballet, if the external rotation of the hip is limited, according to the data from the literature, a compensatory lumbar hyperlordosis leading to retroversion of the hip can happen.²⁶ In the retroversion of the hip, a contact of the acetabulum and femur occurs, which is today accepted by the consensus as a condition for the occurrence of changes in the hip. This is also seen on the RTG or MRI records in the case of FAI syndrome.

There are published studies that indirectly support our results. There is strong evidence that lower total hip ROM of both hips is a risk factor for the development of groin pain.^{27,28}

The studies that are compatible with our results are those indicating that there is a high percentage of FAI in young athletes.^{29,30} Another study determined evidence of radiographic hip abnormality in 72% of male and 50% of female elite soccer players. In particular, acetabular retroversion is determined by the presence of a crossover or ischial spine sign in 10% of female and 27% of male soccer players.³¹ A study²⁴ indicated decreased hip rotation ROM in soccer players hypothesizing that this is due to compensatory musculoskeletal changes occurring in response to long-standing soccer practice since childhood.

Some studies concluded that decreased hip ROM is a common finding in patients with FAI and precedes athletic chronic groin injury.³² However, studies up to now connected FAI with the limited *internal* rotation^{33,34} and not with limited *external* rotation. Conclusions in a study³⁴ were that 8% of asymptomatic teenagers had limited internal rotation of the hip and 68% of these had radiographic findings suggestive of FAI. More than two-thirds of these participants had evidence of asymptomatic hip pathological lesions on MRI. In a study,³⁵ the impact of long-term high-intensity training in different sports on hip joint anatomic parameters in athletes (trampolinists and weightlifters) has been determined.

In a recent systematic review,²⁷ it is concluded that screening for the hip ROM is unlikely to correctly identify an athlete at risk because of the small ROM differences found, which were lower than the known measurement errors. A systematic review with meta-analysis³⁶ stated that no relationships between sports-related groin pain were found with hip internal or external rotation ranges of movement.

Limitations of the study

The main limitation of this study is that the FAI syndrome diagnosis has been done by two elements of the triad (pains in sports activities and positive FADIR test), the MRI was not performed.

Another limitation is that in this study we supposed that the cause of limited external rotation is muscular. Although the patients with visible femoral anteversion were excluded, the femoral anteversion may be present to some extent.

Finally, in this study, we measured the hip rotation ROM seated with the hip in flexion. In some studies, the hip rotation ROM is measured also in two additional positions: the dorsal decubitus (supine) and ventral decubitus (prone) with the hip in extension. It is indicated that the hip rotation ROM can be measured in the three positions with no significant difference, and with satisfactory interobserver reproducibility for each.³⁷ In other studies, it was concluded that the measures in different positions were different.^{38,39} However, it was noted that a moderate degree of association exists between measurements of the hip ROM in the prone versus seated position.³⁹ Measures of the external hip ROM are different due to gravitation, in the case of a sitting position the gravitation is against, and in the case of a prone position, gravitation helps the movement.³⁸

Future studies can be performed with the group in which FAI diagnostics is also confirmed by MRI or RTG. Further investigation toward non-athletic individuals and/or older individuals with FAI, concerning the association with a limited lateral rotation ROM, is also needed.

Conclusion

The results of this case-control study demonstrated that the diagnosis of FAI and the limited lateral rotation ROM is in a strong association in young athletes.

Since there is a strong association between the FAI and the limited external hip rotation at the side of the painful hip, the screening of the lateral ROM of the hip is advised within the regular screening of the young athletes. In the case of limited external rotation, before starting exercises that are to increase it, a radiograph of the hip joints should be performed to make sure that we are not dealing with diminished anteversion of the femoral neck, coxa protrusa or other bone pathology within the hip joint.

Author contributions

Z.S. and A.T. jointly conceived and designed the research, Z.S. did the practical research, and A.T. analyzed the data. Both authors contributed to the drafting of the manuscript, and both authors reviewed and approved the final version.

Declaration of conflicting interests

The author(s) declared no potential conflicts of interest with respect to the research, authorship, and/or publication of this article.

Funding

The author(s) received no financial support for the research, authorship, and/or publication of this article.

Ethical approval

The study was approved by the Ethical committee of the Novi Sad Health Care Center (no. 21/44-1). Experiments reported in

the manuscript were performed by the ethical standards of the Helsinki Declaration.

Informed consent

The subjects (and their parents) provided their informed consent to participate in the study.

ORCID iD

Zoran Šarčević  <https://orcid.org/0000-0001-8115-1430>

References

1. Trigg SD, Schroeder JD and Hulsopple C. Femoroacetabular impingement syndrome. *Curr Sports Med Rep* 2020; 19(9): 360–366.
2. Matar HE, Rajpura A and Board TN. Femoroacetabular impingement in young adults: assessment and management. *Br J Hosp Med (Lond)* 2019; 280(10): 584–588.
3. Thomas GE, Palmer AJ, Andrade AJ, et al. Diagnosis and management of femoroacetabular impingement. *Br J Gen Pract* 2013; 63(612): e513–e515.
4. de Silva V, Swain M, Broderick C, et al. Does high-level youth sports participation increase the risk of femoroacetabular impingement? A review of the current literature. *Pediatr Rheumatol Online J* 2016; 14: 16.
5. Zhang C, Li L, Forster B, et al. Femoroacetabular impingement and osteoarthritis of the hip. *Can Fam Physician* 2015; 61(12): 1055–1060.
6. Ganz R, Parvizi J, Beck M, et al. Femoroacetabular impingement: a cause for osteoarthritis of the hip. *Clin Orthop Relat Res* 2003; 417: 112–120.
7. Czuppon S, Prather H, Hunt DM, et al. Gender-dependent differences in hip range of motion and impingement testing in asymptomatic college freshman athletes. *PM R* 2017; 9(7): 660–667.
8. Reiman M, Goode A, Hegedus E, et al. Diagnostic accuracy of clinical tests of the hip: a systematic review with meta-analysis. *Br J Sports Med* 2013; 47(14): 893–902.
9. Griffin DR, Dickenson EJ, O'Donnell J, et al. The Warwick Agreement on femoroacetabular impingement syndrome (FAI syndrome): an international consensus statement. *Br J Sports Med* 2016; 50(19): 1169–1176.
10. Tang F, Dai WB, Li XL, et al. Publication trends and hot spots in femoroacetabular impingement research: a 20-year bibliometric analysis. *J Arthroplasty* 2021; 36(8): 2698–2707.
11. Bozic KJ, Chan V, Valone FH, et al. Trends in hip arthroscopy utilization in the United States. *J Arthroplasty* 2013; 28(8 Suppl.): 140–143.
12. Maradit Kremers H, Schilz SR, Van Houten HK, et al. Trends in utilization and outcomes of hip arthroscopy in the United States between 2005 and 2013. *J Arthroplasty* 2017; 32(3): 750–755.
13. Palmer AJ, Malak TT, Broomfield J, et al. Past and projected temporal trends in arthroscopic hip surgery in England between 2002 and 2013. *BMJ Open Sport Exerc Med* 2016; 2(1): e000082.
14. Polat G, Ažahin K, Arzu U, et al. Prevalence of asymptomatic femoroacetabular impingement in Turkey; cross

- sectional study. *Acta Orthop Traumatol Turc* 2018; 52(1): 49–53.
15. Mullins K, Hanlon M and Carton P. Arthroscopic correction of femoroacetabular impingement improves athletic performance in male athletes. *Knee Surg Sports Traumatol Arthrosc* 2020; 28(7): 2285–2294.
 16. Dwyer T, Whelan D, Shah PS, et al. Operative versus non-operative treatment of femoroacetabular impingement syndrome: a meta-analysis of short-term outcomes. *Arthroscopy* 2020; 36(1): 263–273.
 17. Kemp J, Grimaldi A, Heerey J, et al. Current trends in sport and exercise hip conditions: intra-articular and extra-articular hip pain, with detailed focus on femoroacetabular impingement (FAI) syndrome. *Best Pract Res Clin Rheumatol* 2019; 33(1): 66–87.
 18. Casartelli NC, Brunner R, Maffiuletti NA, et al. The FADIR test accuracy for screening cam and pincer morphology in youth ice hockey players. *J Sci Med Sport* 2018; 21(2): 134–138.
 19. Pålsson A, Kostogiannis I and Ageberg E. Combining results from hip impingement and range of motion tests can increase diagnostic accuracy in patients with FAI syndrome. *Knee Surg Sports Traumatol Arthrosc* 2020; 28(10): 3382–3392.
 20. Bandy WD and BerryMann Reese N. *Joint range of motion and muscle length testing*. 2nd ed. New York: Elsevier, 2009.
 21. Floyd RT. *Manual of structural kinesiology*. 19th ed. Livingston, AL: McGraw-Hill Education, 2015.
 22. Brophy RH, Chiaia TA, Maschi R, et al. The core and hip in soccer athletes compared by gender. *Int J Sports Med* 2009; 30(9): 663–667.
 23. Chiaia TA, Maschi RA, Stuhr RM, et al. A musculoskeletal profile of elite female soccer players. *HSS J* 2009; 5(2): 186–195.
 24. de Castro JV, Machado KC, Scaramussa K, et al. Incidence of decreased hip range of motion in youth soccer players and response to a stretching program: a randomized clinical trial. *J Sport Rehabil* 2013; 22(2): 100–107.
 25. Direito-Santos B, França G, Nunes J, et al. Acetabular retroversion. Diagnosis and treatment. *EFORT Open Rev* 2018; 3(11): 595–603.
 26. Turner R, O’Sullivan E and Edelstein J. Hip dysplasia and the performing arts: is there a correlation? *Curr Rev Musculoskelet Med* 2012; 5(1): 39–45.
 27. Tak I, Pope D, Engelaar L, et al. Is lower hip range of motion a risk factor for groin pain in athletes? A systematic review with clinical applications. *Br J Sports Med* 2017; 51(22): 1611–1621.
 28. Tak I, Glasgow P, Langhout R, et al. Hip range of motion is lower in professional soccer players with hip and groin symptoms or previous injuries, independent of cam deformities. *Am J Sports Med* 2016; 44(3): 682–688.
 29. Agricola R, Bessems JH, Ginai AZ, et al. The development of cam-type deformity in adolescent and young male soccer players. *Am J Sports Med* 2012; 40(5): 1099–1106.
 30. Agricola R, Heijboer MP, Ginai AZ, et al. A cam deformity is gradually acquired during skeletal maturation in adolescent and young male soccer players: a prospective study with minimum 2-year follow-up. *Am J Sports Med* 2014; 42(4): 798–806.
 31. Gerhardt M, Romero A, Silvers H, et al. The prevalence of radiographic hip abnormalities in elite soccer players. *Am J Sports Med* 2012; 40(3): 584–588.
 32. Verrall GM, Slavotinek JP, Barnes PG, et al. Hip joint range of motion restriction precedes athletic chronic groin injury. *J Sci Med Sport* 2007; 10(6): 463–466.
 33. Reiman MP and Matheson JW. Restricted hip mobility: clinical suggestions for self mobilization and muscle re-education. *Int J Sports Phys Ther* 2013; 8(5): 729–740.
 34. Yuan BJ, Bartelt RB, Levy BA, et al. Decreased range of motion is associated with structural hip deformity in asymptomatic adolescent athletes. *Am J Sports Med* 2013; 41(7): 1519–1525.
 35. Song Y, Zhang X and Rong K. Effects of long-term high-load exercise on the anatomy of the hip joints: a preliminary report. *J Pediatr Orthop B* 2018; 27(3): 231–235.
 36. Kloskowska P, Morrissey D, Small C, et al. Movement patterns and muscular function before and after onset of sports-related groin pain: a systematic review with meta-analysis. *Sports Med* 2016; 46(12): 1847–1867.
 37. Kouyoumdjian P, Coulomb R, Sanchez T, et al. Clinical evaluation of hip joint rotation range of motion in adults. *Orthop Traumatol Surg Res* 2012; 98(1): 17–23.
 38. Han H, Kubo A, Kurosawa K, et al. Hip rotation range of motion in sitting and prone positions in healthy Japanese adults. *J Phys Ther Sci* 2015; 27(2): 441–445.
 39. Simoneau GG, Hoenig KJ, Lepley JE, et al. Influence of hip position and gender on active hip internal and external rotation. *J Orthop Sports Phys Ther* 1998; 28(3): 158–164.