

CASE REPORT

Intrathymic ectopic parathyroid adenoma caused primary hyperparathyroidism with vitamin D deficiency several years after bariatric surgery

Francesco Sellitri¹, Alessandro Tamburrini¹, Federico Tacconi¹, Patrizio Bollero², Andrea Ortensi¹ & Tommaso Claudio Mineo¹

1 Thoracic Surgery Division, Tor Vergata University, Rome, Italy

2 Department of Special Diseases in Odontostomatology, Tor Vergata University, Rome, Italy

Keywords

Hypercalcemia; parathyroid adenoma; thymic hyperplasia; vitamin D deficiency.

Correspondence

Tommaso Claudio Mineo, Department of Thoracic Surgery, Tor Vergata University, Viale Oxford 81, 00133, Floor 7A, Rome, Italy.

Tel: +39 06 20902880

Fax: +39 06 20902881

Email: mineo@uniroma2.it

Received: 21 March 2014;

accepted 27 April 2014.

doi: 10.1111/1759-7714.12132

Thoracic Cancer 6 (2015) 101–104

Introduction

Parathyroid adenoma is a significant cause of primary hyperparathyroidism (PHPT). Ectopic mediastinal parathyroid adenomas are not rare, accounting for up to 25% of PHPT, but they can be life threatening and still constitute a diagnostic challenge.¹ Vitamin D deficiency (VDD) is a frequent condition worldwide, most likely caused by inadequate intake, gastrointestinal malabsorption, avoidance of ultraviolet B (UVB) sunlight, and an increasingly elderly population.² Obese individuals undergoing bariatric surgery are at a heightened risk for VDD and secondary hyperparathyroidism has been classically observed in these patients.³ However, the concurrence of PHPT and VDD is quite uncommon, and their association is complex and not fully understood.⁴ Herein we report the unusual case of a woman with an intrathymic ectopic parathyroid adenoma, PHPT, and severe VDD twenty years after bariatric surgery, with normal bone mineral density (BMD).

Case report

A 45-year-old woman was referred to our institution with a mass of the anterior superior mediastinum, and complaining

Abstract

Up to 25% of patients with primary hyperparathyroidism have ectopic parathyroid adenoma. A 45-year-old formerly obese woman underwent extended thymectomy for a parathyroid adenoma located in hyperplastic thymic tissue, associated with primary hyperparathyroidism and severe vitamin D deficiency, but normal bone mineral density. At nine months follow-up, all laboratory test results were within normal limits and she presented no symptoms and no recurrence of disease. In this case, autonomous growth of a parathyroid adenoma was reasonably secondary to chronic calcium and vitamin D malabsorption, which often occurs after bariatric surgery for pathologic obesity.

of bone pain and muscular weakness. Twenty years earlier she had undergone jejunoileal bypass for morbid obesity, without receiving regular vitamin D supplementation. In the past five years she had also suffered from gallbladder stones, one episode of pancreatitis, and recurrent nephrolithiasis. Laboratory findings showed that her calcium serum level was 13.50 mg/dl, serum phosphate was 1.80 mg/dl, parathyroid hormone (PTH) was 546.50 pg/mL, and serum vitamin D level was 21.1 ng/mL. Hypercalciuria and hypophosphaturia were also present, proving a case of PHPT, associated with a severe vitamin D deficiency (Table 1). A technetium-99m-sestamibi scan (99mTc-MIBI) showed an intense uptake in the superior mediastinum, while chest computed tomography (CT) and magnetic resonance imaging (MRI) detected a 3 cm solid nodule within the residual, hyperplastic thymus (Fig. 1).

Hypercalcemia was successfully treated with saline rehydration and furosemide calciuresis, and the patient was scheduled for surgery.

An extended thymectomy was performed through a partial sternotomy. Histology revealed an ectopic parathyroid adenoma (EPA) within an hypertrophic thymus, enclosed in a thin capsule composed predominantly of oxyphil cells without atypia (Fig. 2).

Table 1 Biochemical changes

| Test items | Normal | (a) | (b) | (c) | (d) | (e) | (f) | (g) |
|-------------------------------|------------|----------------|-----------------|----------------|-------------|-------------|-----------|-------------|
| Serum intact-PTH (pg/mL) | 14–72 | 546.50 | <2.50 | 7.80 | 37.70 | 17.60 | 17.8 | 76.4 |
| Serum calcium (mg/dl) | 8.40–10.20 | 13.50 | 9.6 | 9.00 | 7.80 | 8.90 | 9.00 | 9.2 |
| Serum phosphate (mg/dl) | 2.70–4.50 | 1.80 | 3.50 | 2.20 | 3.60 | 2.80 | 3.00 | 2.60 |
| Urine calcium (mg/24 hours) | 42–350 | 475 | — | 170.80 | — | — | — | — |
| Urine phosphate (mg/24 hours) | 400–1300 | <400 | — | <400 | — | — | — | — |
| Serum vitamin D (ng/mL) | 75–100 | 12.1 | — | 12.3 | 13.3 | — | — | 17 |
| Magnesium (mg/dl) | 1.58–2.55 | 1.60 | 1.50 | 1.43 | 1.35 | 1.47 | 1.72 | 1.90 |
| Serum albumin (gr/dl) | 3.40–4.80 | 3.70 | — | — | — | — | — | — |
| Hemoglobin (g/dL) | 12–16 | 10.7 | 10.3 | 10 | — | — | 10 | 10.2 |
| Ferritin (ng/mL) | 10–291 | 2.90 | — | — | — | — | 9 | 11 |
| Serum iron (µg/dl) | 50–155 | 17.70 | — | — | — | — | — | — |

Note: (a) Before surgery, (b) one day after surgery, (c) two days after surgery, (d) four days after surgery, (e) discharge, (f) twenty days after surgery, (g) forty after surgery. PTH, parathyroid hormone. **Bold** text denotes results of laboratory tests that are not in the normal range.

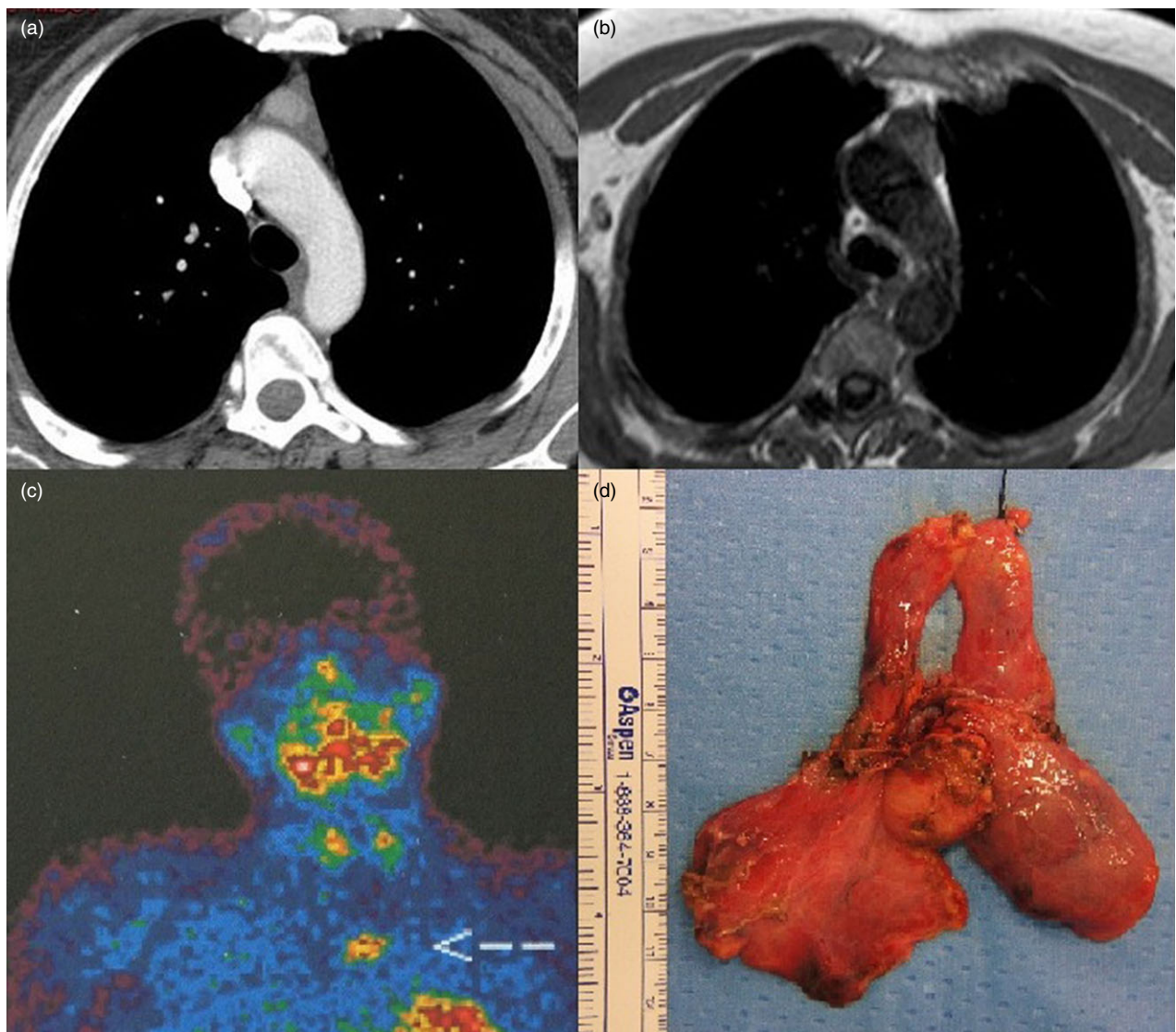


Figure 1 (a) Technetium-99m sestamibi scan; (b) chest computed tomography scan; (c) magnetic resonance imaging; and (d) intraoperative specimen showing the mediastinal ectopic parathyroid adenoma inside the hyperplastic thymus.

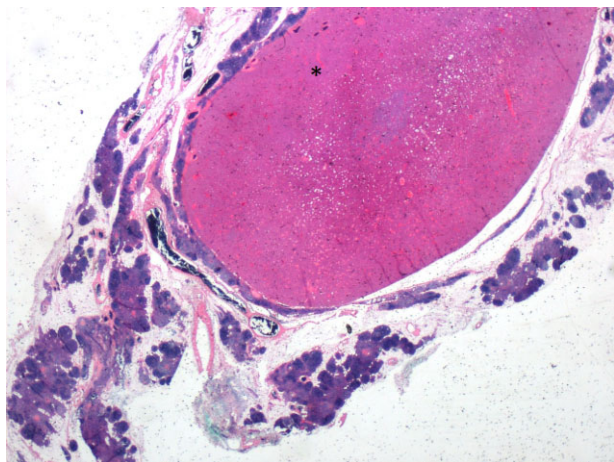


Figure 2 Histological section of the specimen. Hematoxylin-eosin staining, magnification 4 \times . The capsulated parathyroid adenoma (*) is seen within a hyperplastic thymic tissue.

Postoperatively, the laboratory tests gradually returned within normal limits, with a single episode of hypocalcemia (Table 1) occurring four days after surgery, which was successfully treated with a calcium gluconate drip. The patient was discharged on post-operative day six and at a nine month follow-up is asymptomatic with no evidence of recurrence.

Discussion

The development of thymus and parathyroid glands is intimately linked. The superior parathyroid glands originate from the fourth pharyngeal pouch and are relatively constant in their location, as they have a much shorter migration distance. In contrast, the inferior parathyroid glands are extremely variable, being derived from the third branchial pouch along with thymus, and descending in the neck, crossing the path of the superior glands, to eventually lie in an anteroinferior position below the thyroid lobe or within the thyrothymic tract. The reported incidence of normal inferior parathyroid glands lying entirely within the substance of the thymus varies from 12% to 39%.⁵

Ectopic hyperfunctioning mediastinal parathyroid adenomas are found in 11% to 25% of patients with PHPT; most of these patients are asymptomatic and the disease is detected by an incidental finding of hypercalcemia.

In our case, the patient had undergone jejunioileal bypass and had recently suffered from pancreatitis and recurrent episodes of nephrolithiasis. At the time of admission to our department, both symptoms of hypercalcemia and laboratory findings contributed to the diagnosis of PHPT with severe vitamin D deficiency. Elevated PTH levels resulting from secondary hyperparathyroidism are quite common after bariatric surgery, as malabsorption often results in

calcium and vitamin D deficiencies that can trigger an upregulation in PTH levels.⁶ This is of concern because calcium and vitamin D deficiency, along with PTH, may have a long-term impact on bone integrity, potentially leading to osteopenia and osteoporosis. It has also been reported that vitamin D deficiency could induce parathyroid hyperplasia and adenoma growth, and aggravate skeletal changes. In our particular case, chronic vitamin D and calcium deficiency may have resulted in early autonomous and accelerated growth of a parathyroid adenoma located within the thymus.⁷ Moreover, our patient also underwent dual-energy X-ray absorptiometry to determine BMD, which was within normal limits. This finding is quite exceptional, as both primary and secondary hyperparathyroidism are often associated with skeletal changes and osteoporosis.² Vitamin D deficiency is a major risk factor for osteoporosis⁸ and its correlation with low BMD at different skeletal sites has been well documented.⁹ However, there are studies that have not found any association between vitamin D status and BMD,^{10,11} even in PHPT patients.¹² In addition, because sex hormones are also very important regulators of bone metabolism in adults, the influence of vitamin D deficiency and PTH in adults may be of less importance, compared to postmenopausal women.¹¹ In our case, the younger age of the patient may have significantly contributed to the absence of evident skeletal changes and bone disease.

Surgical resection is the only curative option for patients with PHPT, and thymectomy is a significant component of the surgeon's technical armamentarium because of the common intrathymic location of ectopic parathyroid adenoma.

In this case, both the CT-scan and MRI showed a 3 cm adenoma within a considerably voluminous residual thymic tissue. The sternal split allowed us to perform complete resection and manual palpation of eventual additional nodules, provided good cosmetic results, and did not expose the patient to significant risks of sternal dehiscence, which could have resulted from the altered calcium metabolism.

In conclusion, this is a rare case of symptomatic PHPT following bariatric surgery, caused by an intrathymic ectopic parathyroid adenoma, accompanied by severe VDD, but normal bone mineral density.

Disclosure

No authors report any conflict of interest.

References

- 1 Tcherveniakov P, Menon A, Milton R, Papagiannopoulos K, Lansdown M, Thorpe JA. Video-assisted mediastinoscopy (VAM) for surgical resection of ectopic parathyroid adenoma. *J Cardiothorac Surg* 2007; 2: 41.

- 2 Weaver S, Doherty DB, Jimenez C, Perrier ND. Peer-reviewed, evidence-based analysis of vitamin D and primary hyperparathyroidism. *World J Surg* 2009; **33**: 2292–302.
- 3 Signori C, Zalesin KC, Franklin B, Miller WL, McCullough PA. Effect of gastric bypass on vitamin D and secondary hyperparathyroidism. *Obes Surg* 2010; **20**: 949–52.
- 4 Nordenström E, Sitges-Serra A, Sancho JJ, Thier M, Almquist M. Vitamin D status in patients operated for primary hyperparathyroidism: comparison of patients from Southern and Northern Europe. *Int J Endocrinol* 2013; **2013**: 164939.
- 5 Stalberg P, Grodski S, Sidhu S, Sywak M, Delbridge L. Cervical thymectomy for intrathyroid parathyroid adenomas during minimally invasive parathyroidectomy. *Surgery* 2007; **141**: 626–9.
- 6 Jin J, Stellato TA, Hallowell PT, Schuster M, Graf K, Wilhelm S. Utilization of preoperative patient factors to predict postoperative vitamin D deficiency for patients undergoing gastric bypass. *J Gastrointest Surg* 2009; **13**: 1052–7.
- 7 Moosgaard B, Vestergaard P, Heickendorff L, Melsen F, Christiansen P, Mosekilde L. Vitamin D status, seasonal variations, parathyroid adenoma weight and bone mineral density in primary hyperparathyroidism. *Clin Endocrinol* 2005; **63**: 506–13.
- 8 Lips P. Vitamin D deficiency and secondary hyperparathyroidism in the elderly: consequences for bone loss and fractures and therapeutic implications. *Endocr Rev* 2001; **22**: 477–501.
- 9 Moosgaard B, Christensen SE, Vestergaard P, Heickendorff L, Christiansen P, Mosekilde L. Vitamin D metabolites and skeletal consequences in primary hyperparathyroidism. *Clin Endocrinol* 2008; **68**: 707–15.
- 10 Holick MF, Siris ES, Binkley N *et al.* Prevalence of vitamin D inadequacy among postmenopausal North American women receiving osteoporosis therapy. *J Clin Endocrinol Metab* 2005; **90**: 3215–24.
- 11 Lamberg-Allardt CJE, Outila TA, Kärkkäinen MUM, Rita HJ, Valsta LM. Vitamin D deficiency and bone health in healthy adults in Finland: could this be a concern in other parts of Europe? *J Bone Miner Res* 2001; **16**: 2066–73.
- 12 Yamashita H, Noguchi S, Uchino S *et al.* Vitamin D status in Japanese patients with hyperparathyroidism: seasonal changes and effect on clinical presentation. *World J Surg* 2002; **26**: 937–41.