

# Pulmonary Hypertension in Mitral Regurgitation

Harsh Patel, MD; Milind Desai, MD; E. Murat Tuzcu, MD; Brian Griffin, MD; Samir Kapadia, MD

**M**itral regurgitation (MR) is the most common valvular lesion in the United States and the second-most common valvular lesion requiring surgery in Europe.<sup>1,2</sup> In the United States, over 2.5 million people are estimated to have moderate-to-severe MR, and this number is expected to double by 2030.<sup>1</sup> Over the past several decades, improvements in our ability to diagnose and quantify MR, coupled with a better understanding of its natural history and the adverse prognostic features, has led to the refinement of indications for mitral valve surgery. Pulmonary hypertension (defined as a systolic pressure >50 mm Hg at rest or >60 mm Hg with exercise) is one such adverse prognostic indicator, the presence of which in patients with asymptomatic MR translates to a class IIA indication for mitral valve surgery according to the latest American College of Cardiology/American Heart Association (ACC/AHA) and European Society of Cardiology (ESC) guidelines.<sup>3,4</sup> Pulmonary hypertension has long been known to be a serious complication of mitral valve disease (MVD). Yet, its precise role in the natural history and management of patients with MR remains scantily investigated, as exemplified by a level of evidence C associated with the above-mentioned recommendation for surgery.

Pulmonary hypertension associated with MVD was originally reported in patients with rheumatic mitral stenosis, both in isolation and in combination with MR. Early case series of such patients reported a dismal prognosis without surgical intervention as well as high operative mortality with mitral valve replacement.<sup>5</sup> While it was recognized that pulmonary hypertension may also complicate chronic isolated MR,<sup>6,7</sup> the initial perception was that it was much more common in mitral stenosis.<sup>8</sup> Yet, Alexopoulos et al., in a small single-center study, reported that a variable degree of pulmonary hypertension was present on right heart catheterization in

76% of patients with chronic isolated severe MR with normal left ventricular (LV) function (LVF).<sup>9</sup> Unfortunately, most of the early studies of pulmonary hypertension in MR are limited by having small sample sizes and including patients with varying degrees of MR and pulmonary hypertension. More recently, Barbieri et al. showed, in a multicenter long-term international study, that significant pulmonary hypertension (defined as pulmonary artery systolic pressure [PASP] >50 mm Hg) was present in 23% of patients with severe degenerative MR.<sup>10</sup> Pulmonary hypertension can also frequently complicate the course of patients with chronic functional MR as a result of both systolic and diastolic LV dysfunction.<sup>11,12</sup> Therefore, the true prevalence of pulmonary hypertension in such patients is not really known.

## Pathogenesis of Pulmonary Hypertension in MR

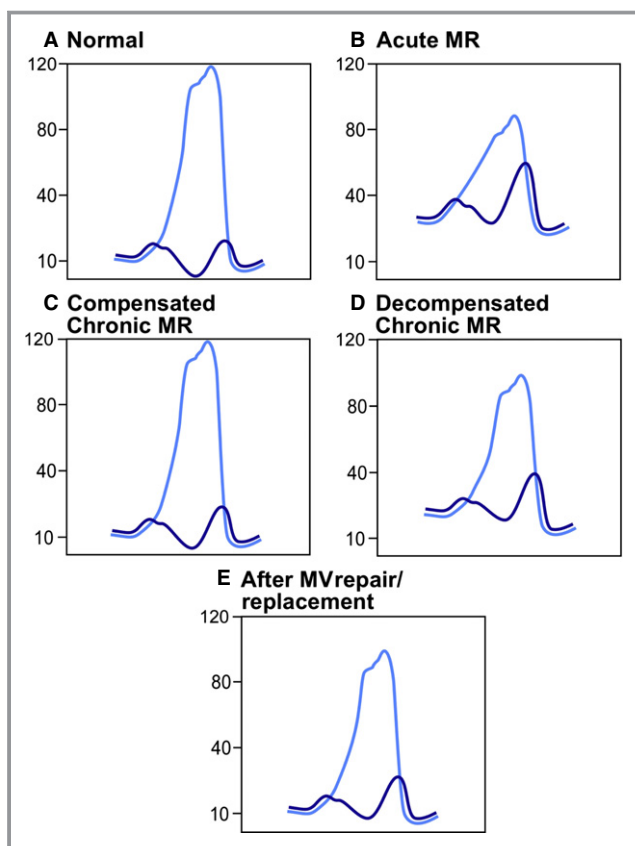
The natural history of chronic severe MR can be divided into three separate phases based on the clinical and hemodynamic profile.<sup>13</sup> During the initial compensated phase, the left ventricle undergoes eccentric hypertrophy as a result of volume overload and develops into a large compliant chamber capable of producing a larger total stroke volume. The left atrium also enlarges and is able to accommodate a large regurgitant volume without significant elevation in mean left atrial pressure (LAP).<sup>7</sup> LV contractile function and pulmonary arterial pressures are normal and the patient remains asymptomatic during this phase. By contrast, the final decompensated phase of chronic MR is characterized by symptoms of heart failure (HF) associated with progressive decline in LV contractile function, maladaptive increase in LV dimensions with resulting increase in systolic wall stress, elevation of left-sided filling pressures, and worsening pulmonary hypertension.

Whereas the compensated and decompensated stages have distinct clinical and hemodynamic features (see Figure 1), the intervening transitional period remains a poorly defined phase in the natural history of chronic MR. Even though the precise factors that determine evolution into the transitional phase remain elusive, it is clear that LV contractile function initially begins to deteriorate during this phase. Ejection fraction (EF) and other load-dependent indices of contractile function may

From the Cleveland Clinic Foundation, Cleveland, OH.

**Correspondence to:** Samir Kapadia, MD, The Cleveland Clinic Foundation, 9500 Euclid Ave, Desk: J2-3, Cleveland, OH 44195. E-mail: kapadis@ccf.org  
*J Am Heart Assoc.* 2014;3:e000748 doi: 10.1161/JAHA.113.000748.

© 2014 The Authors. Published on behalf of the American Heart Association, Inc., by Wiley Blackwell. This is an open access article under the terms of the Creative Commons Attribution-NonCommercial License, which permits use, distribution and reproduction in any medium, provided the original work is properly cited and is not used for commercial purposes.



**Figure 1.** Left ventricular and left atrial hemodynamics under various conditions. A, In the normal condition, mean left atrial pressure measurements are low. B, Acute severe MR is generally associated with large atrial V waves, severely elevated LVEDP, and low peak LV systolic pressure, often with low forward cardiac output and cardiogenic shock. C, With progressive LV and LA dilation in compensated chronic MR, peak atrial V wave and LVEDP remain relatively low. D, As the LV systolic function deteriorates and LA compliance decreases in decompensated chronic MR, there is an increase in peak atrial V waves and LVEDP. E, After mitral valve surgery, there is generally a significant decrease in peak atrial V waves and mean atrial pressures. LA indicates left atrial; LV, left ventricle; LVEDP, left ventricular end diastolic pressure; MR, mitral regurgitation; MV, mitral valve.

remain normal or decrease minimally, masking the underlying contractile dysfunction. LAP, which is not substantially elevated in the compensated phase, despite significant regurgitation, may begin to rise as a result of occult LV systolic or diastolic dysfunction and decline in left atrial compliance.<sup>7</sup> As a result, pulmonary hypertension may also begin to develop during this phase.

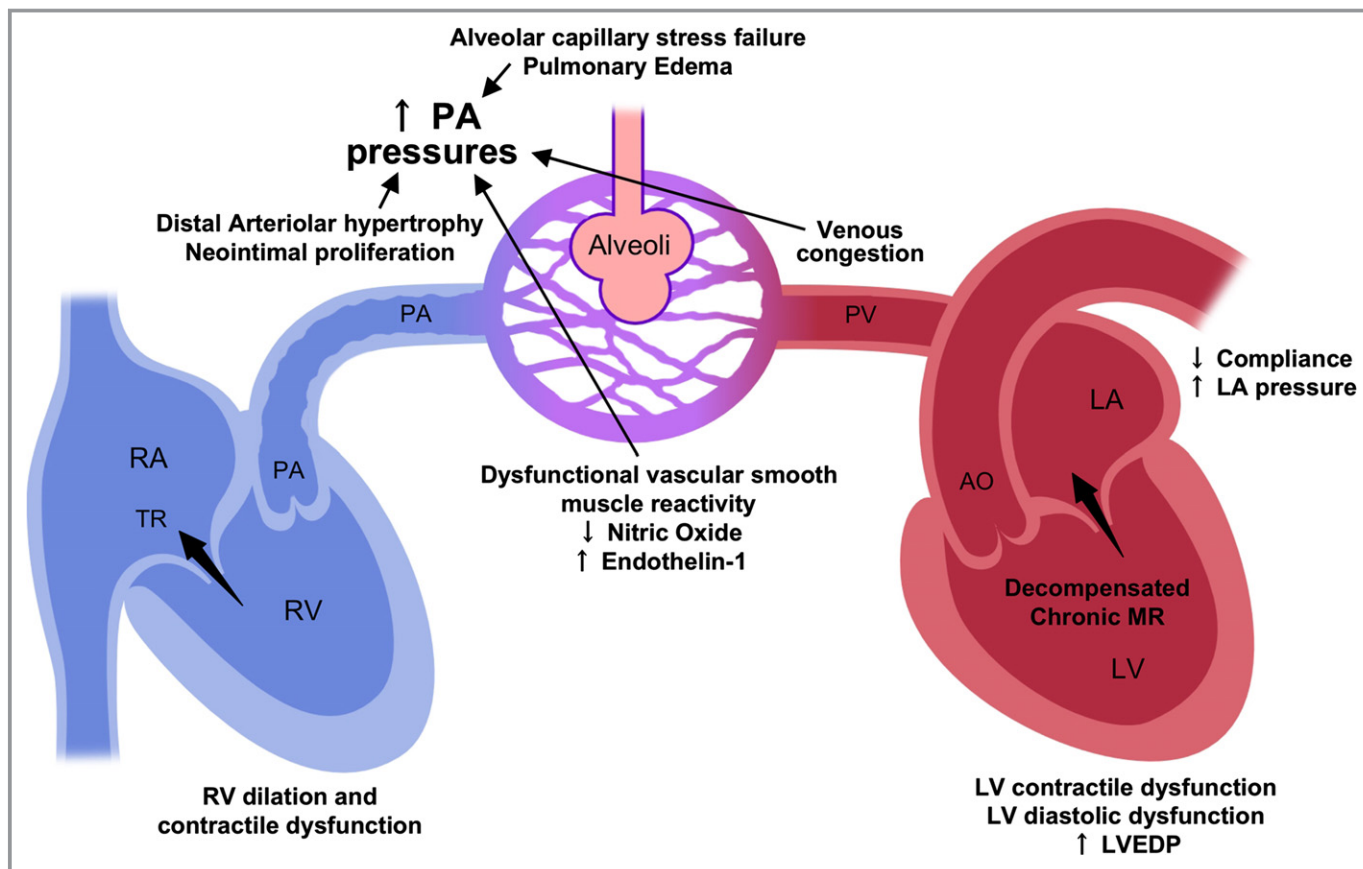
The processes that govern the development of pulmonary hypertension in MR are multifactorial (see Figure 2) and are not yet fully understood. Elevation of LAP, which occurs not only in acute MR,<sup>14</sup> but also in the transitional and decompensated phases of chronic MR,<sup>9</sup> is believed to be the

initiating factor in the pathogenesis of pulmonary hypertension. Sustained elevation of LAP, which is passively transmitted backward into the pulmonary veins, can lead to disruption of the delicate alveolar-capillary complex in a process known as alveolar capillary stress failure, with resulting capillary leakage and pulmonary edema.<sup>15</sup> In the initial phases, this lesion is reversible.<sup>16</sup> However, with long-standing pulmonary venous hypertension (PVH), the alveolar-capillary unit may be irreversibly altered by a remodeling process characterized by excessive type IV collagen deposition,<sup>17</sup> leading to a reduction in alveolar diffusion capacity.<sup>18</sup>

Persistent passive elevation of pulmonary venous pressures can also induce histological changes in the pulmonary vasculature, such as arteriolar muscularization and formation of neointima and hypertrophy of the distal pulmonary arteries.<sup>19,20</sup> It is important to note that these ultrastructural abnormalities of the pulmonary vessels that develop in chronic MR and other causes of left heart disease-associated pulmonary hypertension are distinctly different from those observed in pulmonary arterial (group 1) hypertension (PAH).<sup>19</sup>

In addition to the histological changes, significant functional abnormalities in the pulmonary vasculature result from endothelial injury in the setting of PVH. Impairment and imbalance in endothelial production of nitric oxide (NO) and endothelin-1 (ET-1), key vasoactive mediators of pulmonary vascular resistance (PVR), leads to dysfunctional smooth muscle reactivity.<sup>21,22</sup> Several studies have demonstrated the significance of NO and ET-1 levels in determining not only pulmonary vascular tone, but also overall prognosis in patients with pulmonary hypertension.<sup>21,23</sup>

The final magnitude of pulmonary hypertension in patients with MR is determined by combination of a “passive” component resulting from PVH and a “precapillary” component driven by the extent of structural and functional changes in the pulmonary arterial vessels. Hemodynamic evaluation of patients with group 2 (left heart disease-associated) pulmonary hypertension reveals an “early” stage during which elevation of pulmonary arterial pressure (PAP) is primarily a result of high LAP. This stage is characterized by normal PVR and transpulmonary pressure gradient and is generally reversible.<sup>24</sup> After a variable duration, the development of the above-mentioned progressive vascular changes leads to a “reactive” stage of pulmonary hypertension during which PAP increases disproportionately to increase in LAP. PVR is elevated during this stage, which may be either reversible or permanent. Even at this later stage of pulmonary hypertension, near-normalization of PAPs and PVR may be observed in many patients after successful mitral valve surgery.<sup>25–27</sup> However long-term studies regarding the changes in pulmonary pressure after surgery are very limited. Persistence of significant pulmonary hypertension after surgery may be the result of residual MR,



**Figure 2.** Pathogenesis of pulmonary hypertension in mitral regurgitation. Chronic severe mitral regurgitation induces compensatory LV and LA dilation in the initial phase, but over time, leads to LV systolic and diastolic dysfunction, reduced LA compliance, and elevated LA pressure in the decompensated phase. Backward transmission of elevated left atrial pressures can cause disruption of the alveolar capillary complex with resultant pulmonary edema. Long-standing passive pulmonary hypertension resulting from venous congestion can lead to structural changes in the distal arterioles and endothelial injury with vascular functional abnormalities, which can then cause elevation in transpulmonary gradient and reactive pulmonary hypertension. Chronic right ventricular pressure overload resulting from pulmonary hypertension ultimately leads to cavity dilation and contractile dysfunction. AO indicates aorta; LA, left atrial; LV, left ventricle; LVEDP, left ventricular end diastolic pressure; PA, pulmonary artery; PV, pulmonary vascular; RA, right atrium; RV, right ventricle; TR, tricuspid regurgitant.

relative mitral stenosis resulting from reduced mitral valve orifice area, prosthetic valve dysfunction, or persistent microvascular changes. Ultimately, the severity of pulmonary vascular pathology in MR and the rate of its progression and regression are also likely to be influenced by patient-related genetic susceptibility factors that are not yet fully understood. This is supported by the observation that many patients with long-standing, severe MR do not develop any elevation of PAP or PVR. However, no specific genetic linkages to group 2 pulmonary hypertension have been identified, unlike the association of polymorphisms in genes encoding bone morphogenetic protein receptor 2, activin receptor-like kinase type 1, and endoglin with group 1 pulmonary hypertension.<sup>24</sup>

The pulmonary vasculature is normally a low-pressure, low-impedance system, which creates a low afterload on the right ventricle. Advanced or “reactive” pulmonary hypertension significantly increases right ventricular afterload and thus has a major effect on its function. In comparison to the left

ventricle, the right ventricle is much more sensitive to prolonged pressure overload than volume overload as a result, in part, of certain morphologic features, such as myofiber orientation and differences in excitation-contraction coupling.<sup>28</sup> Sustained elevation of afterload causes compensatory right ventricular (RV) myocardial hypertrophy in the initial phases, but can ultimately lead to maladaptive wall thinning, cavity dilation, tricuspid regurgitation, and reduction in contractility.<sup>29</sup> Impairment of RV function and the resulting increase in right atrial pressure (RAP) can further exacerbate the HF syndrome by causing increase in release of brain natriuretic peptide and renal dysfunction as a result of venous congestion. The resulting expansion of intravascular volume lends to a vicious cycle of worsening MR, pulmonary venous congestion, and pulmonary hypertension. Several studies have demonstrated the key significance of RV dysfunction in determining the natural history and prognosis of patients with chronic MR and pulmonary hypertension.<sup>30,31</sup>

## Diagnostic Evaluation

### Echocardiography

Echocardiography has become established as the primary tool not only for evaluating the severity and etiology of MR, but also for the screening and monitoring of sequelae such as pulmonary hypertension (Table). Estimation of the PASP using Doppler-derived RV systolic pressure (RVSP) is the most commonly used noninvasive test for the diagnosis of pulmonary hypertension.<sup>32</sup> Transthoracic Doppler echocardiography allows for measurement of the peak tricuspid regurgitant velocity (TRV), which is used to calculate the systolic pressure gradient between the RV and right atrium using the modified Bernoulli's equation. The value of this pressure gradient is then added to a noninvasive estimation of the mean RAP using inferior vena cava diameter at end-expiration to calculate the RVSP. Because the systolic pressure gradient across the pulmonary valve is generally negligible, the RVSP is considered an acceptable surrogate for the PASP. Whereas initial studies showed adequate correlation between Doppler-derived RVSP and invasively measured PASP,<sup>33</sup> others have shown a significant lack of correlation in certain clinical situations.<sup>34,35</sup> For example, in

the presence of significant tricuspid regurgitation, the modified Bernoulli's equation cannot be properly applied and the TRV underestimates the RVSP. Incomplete Doppler envelope resulting from eccentric or trace tricuspid regurgitation is another common cause of underestimation of RVSP. Thus, over-reliance on Doppler-derived RVSP for the diagnosis of pulmonary hypertension can lead to misclassification of its severity or even failure to identify it.<sup>32</sup> Furthermore, even when RVSP is appropriately measured, it may belie the true severity of pulmonary hypertension in the presence of significant RV contractile dysfunction or low cardiac output.

When TRV measurement appears unreliable, the modified Bernoulli's equation can be applied using the pulmonary regurgitant velocity (PRV) in early diastole and end diastole to calculate mean PAP and pulmonary artery diastolic pressure, respectively. However, PRV measurement often itself may be unreliable when a parallel Doppler intercept angle cannot be achieved. Other echocardiographic indices, such as RV outflow tract (RVOT) acceleration time and noninvasively estimated PVR may also be used to screen for pulmonary hypertension, but studies show variable degrees of correlation with invasively measured parameters.<sup>34,36</sup>

**Table.** Echocardiographic Evaluation in Patients With Pulmonary Hypertension Resulting From Severe Mitral Regurgitation

View	Measurements	Normal Range	Pulmonary Hypertension
Long-axis view of LV	LV end-diastolic diameter, cm	4.2 to 5.9 (males); 3.9 to 5.3 (females)	↑
	LV end-systolic diameter, cm	2.1 to 4.0 (males); 2.4 to 4.0 (females)	↑
Long-axis view of the RV inflow tract	Basal diameter of RV, cm	3.7 to 5.4	↑
	Tricuspid annulus, cm	1.3 to 2.8	↑
	Tricuspid regurgitant velocity, m/s	<2.6	↑
Long- and short-axis views of RVOT	RVOT, cm	1.7 to 2.3	↑
	Main pulmonary trunk, cm	1.5 to 2.1	↑
	RV outflow acceleration time, ms	>110	↓
	Pulmonary regurgitant velocity (beginning of diastole), m/s	<1	↑
	Pulmonary regurgitant velocity (end diastole), m/s	<1	↑
Apical 4-chamber view (2D echo)	Basal diameter of RV, cm	2.0 to 2.8	↑
	RV end-diastolic area, cm <sup>2</sup>	11 to 28	↑
	RV end-systolic area, cm <sup>2</sup>	7.5 to 16	↑
	Right atrial area (end-systole), cm <sup>2</sup>	13.5±2	↑
	RA volume index, mL/m <sup>2</sup>	≤34 (males); ≤27 (females)	↑
	Tricuspid annulus, cm	1.3 to 2.8	↑
	Right ventricular fractional area change, %	32 to 60	↓
	LV end-diastolic volume, cm <sup>3</sup>	67 to 155 (males); 56 to 104 (females)	↑
	LV end-systolic volume, cm <sup>3</sup>	22 to 58 (males); 19 to 49 (females)	↑
	Left atrial area (end-systole), cm <sup>2</sup>	<20	↑
LA volume index, mL/m <sup>2</sup>	<29	↑	
Apical 4-chamber view (Doppler echo)	Tricuspid regurgitant velocity, m/s	<2.6	↑
	Deceleration time–tricuspid inflow, ms	144 to 244	↑
	RV MPI (Tei index)	<0.28	↑
	TAPSE, mm	≥20	↓
	IVRT (TDI RV free wall), ms	<75	↑

↑ indicates increased in pulmonary hypertension; ↓, decreased in pulmonary hypertension; IVRT, isovolumic relaxation time; LA, left atrial; LV, left ventricle; MPI, myocardial performance index; RA, right atrium; RV, right ventricle; RVOT, right ventricular outflow tract; TAPSE, tricuspid annular plane systolic excursion; TDI, tissue Doppler imaging. Reproduced with permission of the European Respiratory Society from Howard et al.<sup>32</sup>

Assessment of RV structure and function is an important part of the echocardiographic evaluation of patients with pulmonary hypertension resulting from MR because of its added prognostic significance. Tissue Doppler measurement of the tricuspid annular plane systolic excursion (TAPSE) provides a quantitative index of RV systolic function and has been shown to be predictive of perioperative and long-term mortality risk.<sup>30,37</sup> The presence of significant tricuspid regurgitation (3+ or greater) and elevated indexed right atrial area are also associated with increased risk of perioperative mortality.<sup>37</sup> RV eccentricity index, a quantitative measure of RV remodeling, has been shown to predict long-term mortality in patients with PAH, but its value in patients with MR has not been studied.<sup>38</sup>

Exercise echocardiography can also provide valuable information in the evaluation of patients with MR. Because of the adverse effect of resting pulmonary hypertension and manifest left ventricular dysfunction (LVD) on operative mortality, there is increased emphasis on early detection of patients at risk of developing these sequelae of chronic MR. Exercise-induced increase in PASP and MR has been shown to be associated with occult LVD<sup>39</sup> and reduced symptom-free survival.<sup>40</sup> Other indices of LVF during exercise, such as end-systolic volume (ESV) and contractile reserve (exercise-induced increase in EF or longitudinal strain) appear to predict postoperative ventricular function more accurately than resting indices.<sup>41–43</sup> Thus, in addition to providing an objective assessment of functional capacity, exercise echocardiography may help identify asymptomatic patients with severe MR and apparently normal resting LVF in the transitional phase who would benefit from immediate referral to mitral valve surgery.

### Invasive Hemodynamic Measurements

Invasive measurement of PAPs through right heart catheterization is essential to confirm the diagnosis and severity of pulmonary hypertension. Consensus guidelines define pulmonary hypertension as a mean PAP >25 mm Hg.<sup>24</sup> Pulmonary hypertension resulting from left heart diseases (pulmonary hypertension-LHD or group 2 pulmonary hypertension) such as MR is distinguished from PAH (group 1 pulmonary hypertension) by the presence of pulmonary capillary wedge pressure (PCWP) >15 mm Hg. PCWP is widely considered to be a surrogate measure of LV end diastolic pressure (LVEDP), but data supporting this assumption in patients with pulmonary hypertension are scant. In a large study of over 4000 patients with pulmonary hypertension, almost 50% of patients with normal PCWP were found to have elevated LVEDP.<sup>44</sup> Thus, if PCWP is found to be <15 mm Hg, despite high clinical suspicion of elevated left-sided filling pressures, confirmation of LVEDP through left

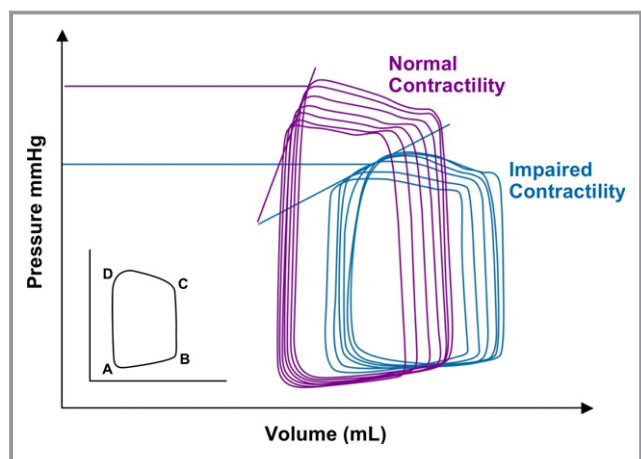
heart catheterization may be required. Volume or exercise challenges during right heart catheterization may be used to unmask postcapillary pulmonary hypertension in patients with borderline PCWP or LVEDP (13 to 18 mm Hg) at rest resulting from aggressive preload reduction with diuretic therapy. If PCWP or LVEDP is found to be normal, despite thorough evaluation in a patient with severe MR, a search for alternate causes of pulmonary hypertension should be performed. Right heart catheterization also allows for differentiation of “passive” and “reactive” pulmonary hypertension by calculation of the transpulmonary gradient (TPG), which is defined as the difference between mean PAP and mean PCWP. In passive pulmonary hypertension, the TPG is normal (<12 mm Hg), but is elevated (>12 mm Hg) in those with reactive or out-of-proportion pulmonary hypertension.

Vasoreactivity testing to evaluate for reduction in mean PAP with agents, such as NO or nitroprusside, is an integral part of the assessment of patients with PAH (group 1 pulmonary hypertension). However, its value in preoperative assessment of patients with pulmonary hypertension resulting from MR is unclear. Vasoreactivity testing in such patients is not recommended because of concern for increase in left-sided filling pressures and precipitation of pulmonary edema. Patients with pulmonary hypertension resulting from MR were excluded from studies that led to U.S. Food and Drug Administration approval of several pulmonary vasodilators for use in PAH. However recent studies have shown that inhaled prostacyclins and inhaled NO can be used to reduce PAPs, PVR, and improve cardiac output in patients with pulmonary hypertension resulting from MVD after surgery.<sup>45,46</sup> Though short-term use of these pulmonary vasodilators in the postoperative period appears safe, careful monitoring of PCWP is necessary during administration to avoid development of pulmonary edema.

### Advanced Hemodynamic Assessment of Ventricular Function

As discussed in more detail below, there is an increasing emphasis on referral of patients for surgical correction of severe MR before the development of sequelae such as pulmonary hypertension and ventricular dysfunction to reduce perioperative morbidity and mortality. Unfortunately, the standard methods of measuring LVF, such as EF, fractional shortening, and so on, are highly load dependent. Thus, in the presence of increased preload and reduced afterload, such as in the compensated phase of MR, monitoring these indices of ventricular function may not allow detection of early, subclinical LV contractile dysfunction before development of overt, irreversible systolic dysfunction and pulmonary hypertension.

By contrast, the end-systolic pressure-volume relationship (ESPVR) has been shown to be a load-independent measure of



**Figure 3.** PV loops generated using conductance catheters. A, Mitral valve opens; B, mitral valve closes (end-diastole); C, aortic valve opens; and D, aortic valve closes (end-systole). The end-systolic pressure volume relationship (ESPVR) is described by the line that connects the end-systolic points (D) on several PV loops measured under variable loading conditions. The end-systolic elastance (ESS), which is described by the slope of this line, is considered a powerful load-independent indicator of myocardial contractility. In this patient with severe MR, the ESS (LV contractility) decreases on follow-up without an appreciable change in ejection fraction. LV indicates left ventricle; MR, mitral regurgitation; PV, pulmonary vascular.

ventricular contractile state. The end-systolic elastance (ESS), which is defined as the slope of the line that estimates the end-systolic points on pressure-volume loops obtained under variable loading conditions, is considered a powerful indicator of myocardial contractility.<sup>47</sup> However, the accurate determination of pressure-volume loops is difficult because it requires simultaneous acquisition of ventricular pressure and volume measurements throughout the entire cardiac cycle (see Figure 3). Though invasive pressure measurements have been routinely obtained during cardiac catheterization for a long time, the development of technology for real-time invasive measurement of ventricular volume has been more challenging.<sup>48–50</sup> Because of the high cost of the equipment required to obtain invasive pressure-volume loops, use of this technology is currently limited to research studies and has not yet entered mainstream practice. However, proof-of-concept studies have demonstrated that the measurement of end-systolic elastance to detect latent LVD in patients with severe asymptomatic MR may be feasible.<sup>51</sup>

## Implications for Management

The negative prognostic significance of pulmonary hypertension in patients with MR is well known, but incompletely studied. The 1998 ACC/AHA Valve Disease guidelines specified the presence of pulmonary hypertension (defined as

systolic pressure >50 mm Hg at rest or >60 mm Hg with exercise) as an indication (class IIA) for surgery in patients with asymptomatic severe MR based on only one small study, which showed that mild pulmonary hypertension (mean PAP >20 mm Hg) was associated with increased postoperative LV enlargement.<sup>52,53</sup> The 2006 guideline update continued this recommendation, but did not provide additional support. Recently, however, several studies have demonstrated the negative implications of pulmonary hypertension in MR not only in terms of natural history, but also in terms of perioperative outcomes. Yang et al. demonstrated that preoperative pulmonary hypertension (PASP >30 mm Hg) is associated with significant reduction in postoperative left ventricular ejection fraction (LVEF) in patients with degenerative MR and normal preoperative LVEF.<sup>54</sup> Of note, the severity of pulmonary hypertension was shown to correlate with degree of reduction in postoperative LVEF. Le Tourneau et al. showed that, in patients with chronic degenerative MR, pulmonary hypertension (PASP >50 mm Hg) was associated with lower postoperative LVEF and higher risk of persistence of pulmonary hypertension as well as symptoms after mitral valve surgery.<sup>55</sup> Kainuma et al. showed that, in patients with functional MR undergoing restrictive mitral annuloplasty, pulmonary hypertension was associated with increased rates of long-term mortality and readmission for HF.<sup>56</sup> In a large, single-center study, Ghoreishi et al. showed that, in patients with degenerative MR and pulmonary hypertension (PASP >40 mm Hg) undergoing mitral valve surgery (98% underwent mitral valve repair), even mildly elevated preoperative PASP correlated with increased operative mortality, postoperative LVD, as well as long-term mortality.<sup>57</sup> Similarly, another large, multicenter, international study also demonstrated that pulmonary hypertension in patients with MR approximately doubles the risk of HF and death after diagnosis and that surgery does not completely abolish the risk of adverse events once pulmonary hypertension is established.<sup>10</sup>

The recent evidence of the negative prognostic implications of pulmonary hypertension in MR has rekindled the debate of whether asymptomatic patients with repairable valves should be referred to surgery in the early stages of pulmonary hypertension (PASP 40 to 50 mm Hg) or even before development of pulmonary hypertension. Improvements in surgical technology and technique over the past several decades have led to high rates of successful outcome with low mortality risk in patients undergoing mitral valve repair, especially at high-volume surgical centers in the absence of comorbidities, such as LVD, pulmonary hypertension, or atrial fibrillation. Kang et al. showed that, in patients with asymptomatic severe MR and normal LVEF, early mitral valve repair was associated with reduced long-term mortality and HF hospitalization, compared to conservative management.<sup>58</sup>

The effect of pulmonary hypertension on perioperative morbidity and mortality also inspires consideration of the associated factors that are predictive of the highest risk of adverse perioperative outcomes, which would make surgery prohibitively hazardous. Corciova et al. showed that pulmonary hypertension increased perioperative mortality in patients with MR undergoing mitral valve surgery and receiver operative characteristic curves identified PASP >65 mm Hg to have the highest sensitivity and specificity for risk of perioperative death.<sup>37</sup> Similar thresholds of RV and LV systolic dysfunction and dimensions that define the highest risk for adverse perioperative outcome need to be defined. The perioperative risk of morbidity and mortality is also significantly influenced by the type of mitral valve surgery in patients with pulmonary hypertension. Yang et al showed that mitral valve replacement was associated with greater reduction in postoperative LVEF than mitral valve repair.<sup>54</sup> Le Tourneau et al showed that mitral valve replacement was associated with higher immediate postoperative mortality than mitral valve repair (6.4% versus 1%), though intraoperative mortality was not significantly different.<sup>55</sup> Several studies have clearly established that mitral valve replacement without chordal preservation leads to alteration of LV geometry and reduction of systolic function and therefore should be avoided in patients with pulmonary hypertension, especially when severe.

The role of percutaneous mitral valve repair in patients with MR is still being defined. At present, there are 2 main percutaneous approaches to correct mitral regurgitation. The edge-to-edge repair using a percutaneously implanted clip (ie, MitraClip™) is the approach with the largest clinical and research experience. Coronary sinus annuloplasty (ie, Viking device) is another approach being studied in patients with functional MR. Recently, investigators of the EVEREST II trial, which randomized patients with MR to percutaneous repair (using MitraClip) or conventional mitral surgery, showed that percutaneous repair was associated with reduced rate of adverse periprocedural events and similar improvements in clinical outcomes, compared to surgery, albeit with lower efficacy in reducing MR.<sup>59</sup> Percutaneous mitral valve repair may thus be an attractive option in patients with MR who are deemed to have a prohibitively high risk for adverse events with conventional surgery, such as some with severe pulmonary hypertension. The EVEREST II trial, however, did not evaluate outcomes based on preoperative PAPs, and thus further research is needed to define the role of percutaneous mitral valve repair in patients with pulmonary hypertension.

In summary, pulmonary hypertension is a well-known, but incompletely studied, complication of severe MR. The pathogenesis of pulmonary hypertension in patients with severe MR has a passive component resulting from elevation in LAPs as well as a reactive component resulting from structural and

functional vascular changes. Individual genetic and constitutional risk factors likely play a significant role in the development of pulmonary hypertension, but are poorly understood at present. Though many patients experience improvement in pulmonary pressures after surgery, there is a paucity of data regarding the long-term evolution of pulmonary vascular changes. Echocardiography is essential to not only diagnose pulmonary hypertension, but also to provide prognostic information, such as RV structure and function. Recent evidence shows that pulmonary hypertension is not only a poor prognostic indicator under conservative management, but also portends adverse perioperative outcomes. Further research is needed to identify risk factors associated with poor outcomes after surgery in patients with pulmonary hypertension resulting from severe mitral regurgitation.

## Disclosures

None.

## References

1. Nkomo VT, Gardin JM, Skelton TN, Gottdiener JS, Scott CG, Enriquez-Sarano M. Burden of valvular heart diseases: a population-based study. *Lancet*. 2006;368:1005–1011.
2. Iung B, Baron G, Butchart EG, Delahaye F, Gohlke-Barwolf C, Levang OW, Tornos P, Vanoverschelde JL, Vermer F, Boersma E, Ravaut P, Vahanian A. A prospective survey of patients with valvular heart disease in Europe: the Euro Heart Survey on Valvular Heart Disease. *Eur Heart J*. 2003;24:1231–1243.
3. Bonow RO, Carabello BA, Kanu C, de Leon AC Jr, Faxon DP, Freed MD, Gaasch WH, Lytle BW, Nishimura RA, O’Gara PT, O’Rourke RA, Otto CM, Shah PM, Shanewise JS, Smith SC Jr, Jacobs AK, Adams CD, Anderson JL, Antman EM, Fuster V, Halperin JL, Hiratzka LF, Hunt SA, Nishimura R, Page RL, Riegel B. ACC/AHA 2006 guidelines for the management of patients with valvular heart disease: a report of the American College of Cardiology/American Heart Association Task Force on Practice Guidelines (writing committee to revise the 1998 guidelines for the management of patients with valvular heart disease): developed in collaboration with the Society of Cardiovascular Anesthesiologists: endorsed by the Society for Cardiovascular Angiography and Interventions and the Society of Thoracic Surgeons. *Circulation*. 2006;114:e84–e231.
4. Vahanian A, Baumgartner H, Bax J, Butchart E, Dion R, Filippatos G, Flachskampf F, Hall R, Iung B, Kasprzak J, Nataf P, Tornos P, Torracca L, Wenink A. Guidelines on the management of valvular heart disease: the Task Force on the Management of Valvular Heart Disease of the European Society of Cardiology. *Eur Heart J*. 2007;28:230–268.
5. Ward C, Hancock BW. Extreme pulmonary hypertension caused by mitral valve disease—natural history and results of surgery. *Br Heart J*. 1975;37:74–78.
6. Bentivoglio L, Uricchio JF, Likoff W. The paradox of right ventricular enlargement in mitral insufficiency. *Am J Med*. 1958;4:193.
7. Ross J Jr, Braunwald E, Morrow AG. Clinical and hemodynamic observations in pure mitral insufficiency. *Am J Cardiol*. 1958;2:11–23.
8. Brandenburg RO, Fuster V, Giuliani ER, McGoon DC. *Cardiology: Fundamentals and Practice*. Chicago, London: Year Book Medical Publishers, Inc; 1987; 13:8–9.
9. Alexopoulos D, Lazzam C, Borricio S, Fiedler E, Ambrose J. Isolated chronic mitral regurgitation with preserved systolic left ventricular function and severe pulmonary hypertension. *J Am Coll Cardiol*. 1989;14:319–322.
10. Barbieri A, Bursi F, Grigioni F, Avierinos JF, Michelena HI, Rusinaru D, Szymansky C, Russo A, Suri R, Bacchi Reggiani ML, Branzi A, Modena MG, Enriquez-Sarano M; MIDA Investigators. Prognostic and therapeutic implications of pulmonary hypertension complicating degenerative mitral regurgitation due to flail leaflet: a multicenter long-term international study. *Eur Heart J*. 2011;32:751–759.
11. Enriquez-Sarano M, Rossi A, Seward JB, Bailey KR, Tajik AJ. Determinants of pulmonary hypertension in left ventricular dysfunction. *JAMA*. 1997;29: 153–159.

12. Marechaux S, Neicu D, Braun S, Richardson M, Delsart P, Bouabdallaoui N, Banfi C, Gautier C, Graux P, Asseman P, Pibarot P, Le Jemtel TH, Ennezat PV; Lille HFpEF Study Group. Functional mitral regurgitation: a link to pulmonary hypertension in heart failure with preserved ejection fraction. *J Cardiac Fail.* 2011;17:806–812.
13. Gaasch WH, Meyer TE. Left ventricular response to mitral regurgitation: implications for management. *Circulation.* 2008;118:2298–2303.
14. Braunwald E. Mitral regurgitation: physiologic, clinical and surgical considerations. *N Engl J Med.* 1969;281:425–433.
15. West JB, Mathieu-Costello O. Vulnerability of pulmonary capillaries in heart disease. *Circulation.* 1995;92:622–631.
16. Tsukimoto K, Mathieu-Costello O, Prediletto R, Elliott AR, West JB. Ultrastructural appearances of pulmonary capillaries at high transmural pressures. *J Appl Physiol.* 1991;71:573–582.
17. Townsley MI, Fu Z, Mathieu-Costello O, West JB. Pulmonary microvascular permeability. Responses to high vascular pressure after induction of pacing-induced heart failure in dogs. *Circ Res.* 1995;77:317–325.
18. Guazzi M. Alveolar gas diffusion abnormalities in heart failure. *J Card Fail.* 2008;14:695–702.
19. Rich S, Rabinovitch M. Diagnosis and treatment of secondary (non-category 1) pulmonary hypertension. *Circulation.* 2008;118:2190–2199.
20. Wagenvoort C, Wagenvoort N. *Pathology of Pulmonary Hypertension.* 2nd ed. New York, NY: John Wiley & Sons; 1977.
21. Ooi H, Colucci WS, Givertz MM. Endothelin mediates increased pulmonary vascular tone in patients with heart failure: demonstration by direct intrapulmonary infusion of sitaxsentan. *Circulation.* 2002;106:1618–1621.
22. Cooper CJ, Jevnikar FW, Walsh T, Dickinson J, Mouhaffel A, Selwyn AP. The influence of basal nitric oxide activity on pulmonary vascular resistance in patients with congestive heart failure. *Am J Cardiol.* 1998;82:609–614.
23. Cody RJ, Haas GJ, Binkley PF, Capers Q, Kelley R. Plasma endothelin correlates with the extent of pulmonary hypertension in patients with chronic congestive heart failure. *Circulation.* 1992;85:504–509.
24. Galie` N, Hoeper MM, Humbert M, Torbicki A, Vachiery JL, Barbera JA, Beghetti M, Corris P, Gaine S, Gibbs JS, Gomez-Sanchez MA, Jondeau G, Klepetko W, Opitz C, Peacock A, Rubin L, Zellweger M, Simonneau G; ESC Committee for Practice Guidelines (CPG). Guidelines for the diagnosis and treatment of pulmonary hypertension: the Task Force for the Diagnosis and Treatment of Pulmonary Hypertension of the European Society of Cardiology (ESC) and the European Respiratory Society (ERS), endorsed by the International Society of Heart and Lung Transplantation (ISHLT). *Eur Heart J.* 2009;30:2493–2537.
25. Foltz BD, Hessel EA II, Ivey TD. The early course of pulmonary artery hypertension in patients undergoing mitral valve replacement with cardioplegic arrest. *J Thorac Cardiovasc Surg.* 1984;88:238–247.
26. Morrow AG, Oldham HN, Elkins RS, Braunwald E. Prosthetic replacement of mitral valve. Preoperative and postoperative clinical and hemodynamic assessments in 100 patients. *Circulation.* 1967;35:962–979.
27. Tempe DK, Hasija S, Datt V, Tomar AS, Virmani S, Banerjee A, Pande B. Evaluation and comparison of early hemodynamic changes after elective mitral valve replacement in patients with severe and mild pulmonary arterial hypertension. *J Cardiothorac Vasc Anesth.* 2009;23:298–305.
28. Kondo RP, Dederko DA, Teutsch C, Christ J, Catalucci D, Chien KR, Giles WR. Comparison of contraction and calcium handling between right and left ventricular myocytes from adult mouse heart: a role for repolarization waveform. *J Physiol.* 2006;571:131–146.
29. Champion HC, Michelakis ED, Hassoun PM. Comprehensive invasive and noninvasive approach to the right ventricle-pulmonary circulation unit: state of the art and clinical and research implications. *Circulation.* 2009;120:992–1007.
30. Dini FL, Conti U, Fontanive P, Andreini D, Banti S, Braccini L, De Tommassi SM. Right ventricular dysfunction is a major predictor of outcome in patients with moderate to severe mitral regurgitation and left ventricular dysfunction. *Am Heart J.* 2007;154:172–179.
31. Ghio S, Gavazzi A, Campana C, Inserra C, Klersy C, Sebastiani R, Arbustini E, Recusani F, Tavazzi L. Independent and additive prognostic value of right ventricular systolic function and pulmonary artery pressure in patients with chronic heart failure. *J Am Coll Cardiol.* 2001;37:183–188.
32. Howard LS, Grapsa J, Dawson D, Bellamy M, Chambers JB, Masani ND, Nihoyannopoulos P, Simon R, Gibbs J. Echocardiographic assessment of pulmonary hypertension: standard operating procedure. *Eur Respir Rev.* 2012;21:239–248.
33. Currie PJ, Seward JB, Chan KL, Fyfe DA, Hagler DJ, Mair DD, Reeder GS, Nishimura RA, Tajik AJ. Continuous wave Doppler determination of right ventricular pressure: a simultaneous Doppler-catheterization study in 127 patients. *J Am Coll Cardiol.* 1985;6:750–756.
34. Fisher MR, Forfia PR, Chamera E, Houston-Harris T, Champion HC, Gargis RE, Corretti MC, Hassoun PM. Accuracy of Doppler echocardiography in the hemodynamic assessment of pulmonary hypertension. *Am J Respir Crit Care Med.* 2009;179:615–621.
35. Fisher MR, Criner GJ, Fishman AP, Hassoun PM, Minai OA, Scharf SM, Fessler AH. Estimating pulmonary artery pressures by echocardiography in patients with emphysema. *Eur Respir J.* 2007;30:914–921.
36. Granstam SO, Bjorklund E, Wikstrom G, Roos MW. Use of echocardiographic pulmonary acceleration time and estimated vascular resistance for the evaluation of possible pulmonary hypertension. *Cardiovasc Ultrasound.* 2013;11:7.
37. Corciova FC, Corciova C, Georgescu CA, Enache M, Anghel D, Bartos O, Tinica G. Echocardiographic predictors of adverse short-term outcomes after heart surgery in patients with mitral regurgitation and pulmonary hypertension. *Heart Surg Forum.* 2012;15:E127–E132.
38. Ghio S, Klersy C, Magrini G, D'Armini AM, Scelsi L, Raineri C, Pasotti M, Serio A, Campana C, Vigano M. Prognostic relevance of the echocardiographic assessment of right ventricular function in patients with idiopathic pulmonary arterial hypertension. *Int J Cardiol.* 2010;140:272–278.
39. Schiller NB. Exercise Doppler echocardiography in valvular and noncoronary myocardial disease. Interventional echocardiography: transesophageal, pharmacologic and intravascular. *ACC Learn Cent Highlights* 8.1994.
40. Magne J, Lancellotti P, Pierard LA. Exercise pulmonary hypertension in asymptomatic degenerative mitral regurgitation. *Circulation.* 2010;122:33–41.
41. Leung DY, Griffin BP, Stewart WJ, Cosgrove DM III, Thomas JD, Marwick TH. Left ventricular function after valve repair for chronic mitral regurgitation: predictive value of preoperative assessment of contractile reserve by exercise echocardiography. *J Am Coll Cardiol.* 1996;28:1198–1205.
42. Lancellotti P, Cosyns B, Zacharakis D, Attena E, Van Camp G, Gach O, Radermecker M, Pierard LA. Importance of left ventricular longitudinal function and functional reserve in patients with degenerative mitral regurgitation: assessment by two-dimensional speckle tracking. *J Am Soc Echocardiogr.* 2008;21:1331–1336.
43. Magne J, Mahjoub H, Dulgheru R, Pibarot P, Pierard L, Lancellotti P. Left ventricular contractile reserve in asymptomatic primary mitral regurgitation. *Eur Heart J.* 2013;35:1608–1616.
44. Halpern SD, Taichman DB. Misclassification of pulmonary hypertension due to reliance on pulmonary capillary wedge pressure rather than left ventricular end-diastolic pressure. *Chest.* 2009;136:37–43.
45. Healy DG, Veerasingam D, McHale J, Luke D. Successful perioperative utilisation on inhaled nitric oxide in mitral valve surgery. *J Cardiovasc Surg.* 2006;47:217–220.
46. Yurtseven N, Karaca P, Uysal G, Ozkul V, Cimen S, Tuygun AK, Yuksek A, Canik S. A comparison of the acute hemodynamic effects of inhaled nitroglycerin and iloprost in patients with pulmonary hypertension undergoing mitral valve surgery. *Ann Thorac Cardiovasc Surg.* 2006;12:319–323.
47. Suga H, Sagawa K. Instantaneous pressure-volume relationships and their ratio in the excised, supported canine left ventricle. *Circ Res.* 1974;35:117–126.
48. Cassidy SC, Teitel DF. The conductance volume catheter technique for measurement of left ventricular volume in young piglets. *Pediatr Res.* 1992;31:85–90.
49. Baan J, van der Velde ET, de Bruin HG, Smeenk GJ, Koops J, van Dijk AD, Temmerman D, Senden J, Buis B. Continuous measurement of left ventricular volume in animals and humans by conductance catheter. *Circulation.* 1984;70:812–823.
50. Lim DS, Gutgesell HP, Rocchini AP. Left ventricular function by pressure-volume loop analysis before and after percutaneous repair of large atrial septal defects. *Catheter Cardiovasc Interv.* 2006;67:788–838.
51. Kim YJ, Jones M, Greenberg NL, Popovic ZB, Sitges M, Bauer F, Thomas JD, Shiota T. Evaluation of left ventricular contractile function using noninvasively determined single-beat end-systolic elastance in mitral regurgitation: experimental validation and clinical application. *J Am Soc Echocardiogr.* 2007;20:1086–1092.
52. Bonow RO, Carabello B, de Leon AC Jr, Edmunds LH Jr, Fedderly BJ, Freed MD, Gaasch WH, McKay CR, Nishimura RA, O'Gara PT, O'Rourke A, Rahimtoola SH, Ritchie JL, Cheitlin MD, Eagle KA, Gardner TJ, Garson A Jr, Gibbons RJ, Russell RO, Ryan TJ, Smith SC Jr. Guidelines for the management of patients with valvular heart disease: executive summary. A report of the American College of Cardiology/American Heart Association Task Force on Practice Guidelines (Committee on Management of Patients with Valvular Heart Disease). *Circulation.* 1998;98:1949–1984.



53. Crawford MH, Soucek J, Oprian CA, Miller DC, Rahimtoola S, Giacomini JC, Sethi G, Hammermeister KE. Determinants of survival and left ventricular performance after mitral valve replacement. Department of Veterans Affairs Cooperative Study on Valvular Heart Disease. *Circulation*. 1990;81:1173–1181.
54. Yang H, Davidson WR Jr, Chambers CE, Pae WE, Sun B, Champbell DB, Pu M. Preoperative pulmonary hypertension is associated with postoperative left ventricular dysfunction in chronic organic mitral regurgitation: an echocardiographic and hemodynamic study. *J Am Soc Echocardiogr*. 2006;19:1051–1055.
55. Le Tourneau T, Richardson M, Juthier F, Modine T, Fayad G, Polge AS, Ennezat PV, Bauters C, Vincentelli A, Deklunder G. Echocardiography predictors and prognostic value of pulmonary artery systolic pressure in chronic organic mitral regurgitation. *Heart*. 2010;96:1311–1317.
56. Kainuma S, Taniguchi K, Toda K, Funatsu T, Kondoh H, Nishino M, Daimon T, Sawa Y. Pulmonary hypertension predicts adverse cardiac events after restrictive mitral annuloplasty for severe functional mitral regurgitation. *J Thorac Cardiovasc Surg*. 2011;142:783–792.
57. Ghoreishi M, Evans CF, Defilippi CR, Hobbs G, Young CA, Griffith BP, Gammie JS. Pulmonary hypertension adversely affects short- and long-term survival after mitral valve operation for mitral regurgitation: implications for timing of surgery. *J Thorac Cardiovasc Surg*. 2011;142:1439–1452.
58. Kang DH, Kim JH, Rim JH, Kim MJ, Yun SC, Song JM, Song H, Choi KJ, Song JK, Lee JW. Comparison of early surgery versus conventional treatment in asymptomatic severe mitral regurgitation. *Circulation*. 2009;119:797–804.
59. Feldman T, Foster E, Glower DD, Kar S, Rinaldi MJ, Fail PS, Smalling RW, Siegel R, Rose GA, Engeron E, Loghin C, Trento A, Skipper ER, Fudge T, Letsou GV, Massaro JM, Mauri L; EVEREST II Investigators. Percutaneous repair or surgery for mitral regurgitation. *N Engl J Med*. 2011;364:1395–1406.

---

**Key Words:** mitral regurgitation • mitral valve regurgitation • pulmonary hypertension