

# Resectability of the pancreatic adenocarcinoma: A study from Iran

Mahmud Baghbanian, Hasan Salmanroghani, Ali Baghbanian<sup>1</sup>, Mohsen Bakhtpour<sup>2</sup>, Bijan Shabazkhani<sup>3</sup>

Department of Gastroenterology, Yazd Shaheed Sadoughi University of Medical Sciences, Yazd, <sup>1</sup>Departments of Psychiatry, and <sup>3</sup>Gastroenterology, Tehran University of Medical Sciences, Tehran, <sup>2</sup>Department of Nursing, Esfahan University of Medical Sciences, Esfahan, Iran

## Abstract

**Background:** Definite treatment of pancreatic adenocarcinoma is surgical resection. Absence of early symptoms in most patients leads to late diagnosis and treatment. This study aims to evaluate resectability of the pancreatic adenocarcinoma at the time of the diagnosis in Iran.

**Materials and Methods:** The present study which is of a descriptive, prospective and case series nature, has been studying the resectability of the pancreatic adenocarcinoma by multi-detector computerized tomography, endoscopic ultrasonography, laparoscopy and/or laparotomy in 157 patients for the duration of 2 years since November 2009.

**Results:** A total of 157 patients were enrolled in this study. Majority of them (68%) were male. The mean age was 67 years. Final diagnosis obtained 1-12 ( $2.7 \pm 1.6$ ) months after beginning of the symptoms. The lesion situated in the head of the pancreas in 127 cases (81%). Vascular invasion, lymphadenopathy, liver metastasis and peritoneal involvement were seen in 88%, 57%, 43% and 19% of the patients, respectively. According to imaging, tumor was resectable in 10 (6%) patients but laparoscopy and/or laparotomy revealed that only five cases (3%) were actually resectable. After 24 months, only 8 patients were alive; 5 cases of them had been treated by Whipple surgery and other 3 cases were under the chemotherapy. At 1 and 2 year survival rate of the patients was 11% and 5%, respectively.

**Conclusion:** Majority (97%) of the pancreatic adenocarcinomas are unresectable at the time of diagnosis. Thus, meticulous preoperative assessment of patients is essential in patients to avoid major surgery in unresectable cases.

**Key Words:** Adenocarcinoma, advanced cancer, pancreas

### Address for correspondence:

Dr. Mahmud Baghbanian, GI Endoscopy Ward, Sadoughi Hospital, Yazd University of Medical Science, Yazd, Iran.

E-mail: baghbanian1352@gmail.com

Received: 28.04.2013, Accepted: 15.02.2014

Access this article online	
Quick Response Code:	Website: www.advbiores.net
	DOI: 10.4103/2277-9175.148246

## INTRODUCTION

Adenocarcinoma that accounts up to 90% of pancreatic tumors carries an unfavorable prognosis. At 1- and 5-year survival rates of this malignancy are 24% and 5%, respectively.<sup>[1]</sup> Definite treatment of pancreatic adenocarcinoma is surgical resection.<sup>[2]</sup> However, absence of early symptoms in most patients leads to

Copyright: © 2014 Baghbanian. This is an open-access article distributed under the terms of the Creative Commons Attribution License, which permits unrestricted use, distribution, and reproduction in any medium, provided the original author and source are credited.

**How to cite this article:** Baghbanian M, Salmanroghani H, Baghbanian A, Bakhtpour M, Shabazkhani B. Resectability of the pancreatic adenocarcinoma: A study from Iran. Adv Biomed Res 2014;3:265.

late diagnosis and treatment. Therefore majority of pancreatic adenocarcinomas are unresectable at the time of diagnosis.

Extrapancreatic extension into the retroperitoneal tissues including portal vein and superior mesenteric vessels is usually present at the time of diagnosis. In patients with advanced disease, metastases to the lymph nodes, liver and peritoneum are common.<sup>[3]</sup> Unresectability criteria of the pancreatic adenocarcinoma in helical pancreatic protocol multi-detector computerized tomography (MDCT) scan and/or endoscopic ultrasonography (EUS) are: (1) Distant metastasis (liver, peritoneum), (2) arterial encasement of the celiac axis or superior mesenteric artery (SMA) and/or (3) occlusion of the portal vein or superior mesenteric vein.<sup>[4-6]</sup>

The most common causes of unresectability are small peritoneal or liver tumor implants and vascular involvement. Helical pancreatic protocol MDCT scan and EUS have improved the preoperative determination of surgical resectability of the tumor, particularly in vessel invasion.<sup>[7-9]</sup> EUS is more accurate than computerized tomography (CT) in assessing vascular invasion and predicting tumor resectability. Other advantages of EUS include accurate assessment of peripancreatic nodal disease and allowance of tumor biopsy by fine-needle aspiration (FNA).<sup>[10,11]</sup> However ductal adenocarcinomas can elicit a strong desmoplastic reaction in some cases that is responsible for hard consistency of the tumor and sampling error in EUS-FNA.

About 20% of pancreatic adenocarcinomas are resectable in the world-wide reports.<sup>[12]</sup> However, we frequently encounter with relapse of pancreatic adenocarcinoma after surgery in our experience. This study aims at evaluating the true resectability rate of pancreatic adenocarcinomas at the time of diagnosis in the center of Iran.

## MATERIALS AND METHODS

The present study, which is of a descriptive, prospective and case series nature, has studied the clinical course, resectability and 2 years outcome of the 157 pancreatic adenocarcinoma cases in the center of Iran (Tehran and Yazd provinces) for the duration of 2 years since November 2009. This study is approved by Yazd University of Medical Sciences ethic comity.

Patients with pathologically approved adenocarcinoma of the pancreas presenting as solid tumor included in the study. Cystic or solid cystic lesions are excluded from study. All patients gave informed consent to participate in the study.

Histopathologic diagnosis was achieved by EUS-FNA in 136 patients (87%), by surgery in 11 ones, by cytology of the peritoneal fluid in 5 cases and by CT guided biopsy in 5 cases.

EUS and/or helical pancreatic protocol MDCT scan were done for all of the patients; those without any evidence of vascular invasion or extrapancreatic disease in imaging were evaluated by laparoscopy. Only patients that seemed to have resectable tumor in laparoscopy underwent pancreaticoduodenectomy. Tumors with distant metastasis (liver, peritoneum), arterial encasement of the celiac axis or SMA and/or occlusion of the portal vein or superior mesenteric vein have been considered unresectable. For evaluating the reliability of preoperative imaging and laparoscopy in determining the tumor resectability, findings were matched with surgical pathology in patients that underwent pancreaticoduodenectomy. After Whipple surgery, the patients have been followed by periodic physical exam, laboratory test such as tumor marker carbohydrate antigen 19-9 (CA 19-9) and MDCT scan for 2 years.

EUS procedures were carried out by two endosonographer. We accepted EUS-FNA pathologic diagnosis of malignancy as definite diagnosis. EUS-FNA is an expensive method and we repeated EUS-FNA only in 5 cases with non-diagnostic primary FNA. For these reasons we could not measure inter-observer reliability for our endosonographies. The echoendoscope used was curved linear array (Olympus GF-UC 24OP-AL5 Tokyo, Japan.) with Aloka Prosound SSD-5000 (Aloka, Tokyo and Japan) processor. In author's experience, approximately 500 EUS procedures/year are carried out from 7 years ago.

Continuous variables were expressed as mean and standard deviation or median (range) values and categorical variables were expressed as frequency (percentages) with 95% confidence intervals where appropriate. All statistical calculations were performed using SPSS version 17.

## RESULTS

Demographic and clinical characteristics of the patients and imaging characteristics of the patients are in Tables 1 and 2. Vascular invasion was detected in 138 cases (88%); by EUS in 136 patients, by MDCT in 121 ones, by laparotomy/surgical pathology in 2 patients and by laparoscopy in any case. Peripancreatic lymphadenopathy was detected in 89 cases (57%); by EUS in 87 patients, by MDCT in

77 ones, by laparotomy/surgical pathology in 1 patient and by laparoscopy in any case. Liver metastasis was detected in 67 cases (43%); by MDCT in 63 patients, by EUS in 21 cases, by laparoscopy in 2 patients and by laparotomy in any case. Peritoneal involvement was detected in 30 cases (19%); by EUS in 5 patients, by MDCT in 27 ones, by laparoscopy in 1 patient and by laparotomy/surgical pathology in any case [Table 3].

Pancreaticoduodenectomy was done for 8 patients that found to have resectable tumor at imaging and laparoscopy. Laparotomy and pathologic assessment of surgical specimen revealed that pancreatic tumor has been resected completely in 6 cases, but two patients had residual tumor; one case had SMA encasement with tumoral tissue and another patient had both lymph node involvement and port invasion. Surgical pathology and periodic clinical examination (every 3 months), serial serum CA 19-9 level (every 3 months) and CT scan (every 6 months), in the next 2 years revealed that only 5 ones (3%) of our studied patients were resectable really. Among the 6 patients that underwent curative pancreaticoduodenectomy and were resectable at both laparotomy and surgical pathology one patient experienced tumor relapse as liver metastasis and para-aortic lymphadenopathy 8 months after surgery. According to imaging, pancreatic tumor was resectable in 10 patients but laparoscopy and/or laparotomy revealed that only 5 cases (3%) were resectable really.

Among these 157 patients, 140 cases (89%) died with evidence of malignant progression of their disease in 12 month follow-up. After 24 months, only 8 patients were alive; five cases of them had been treated by Whipple surgery and other three cases were on the chemotherapy. After 1 and 2 years, 11% and 5% of the patients were alive respectively.

**DISCUSSION**

Over the recent decades, the incidence of pancreatic cancer has increased. Prognosis of this malignancy is poor despite rapid improvements in imaging methods and therapeutic modalities. Early detection, accurate preoperative staging and better treatment options remain a challenge. Curative treatment (complete surgical resection) is dependent on early diagnosis but as in our cases, the most patients with pancreatic cancer experience symptoms late in the course of disease.

Tumoral lesions in head of the pancreas produce symptoms earlier in the course of disease. In contrast, neoplasm of the body and especially tail have silent presentation, with physical findings appearing only

**Table 1: Demographic and clinical characteristics of the patients enrolled in the study**

Variable	Value (%)
Age (year)	
Range	50-80
Mean	66±7.5
Sex (male/female)	107/50
Smoking	94 (60)
Alcoholism	2
Cholecystectomy	16 (10)
DM (%)	42 (27)
Family history of pancreatic cancer	0
Clinical sign	
Abdominal pain	144 (92)
Weight loss	129 (82.5)
Jaundice	102 (65)
Back pain	75 (48)
Nausea vomiting	63 (40)
Time of symptom (month)	
Range	1-12
Mean	2.7±1.7

DM: Diabetes mellitus

**Table 2: Imaging characteristics of the patients enrolled in the study**

Variable	Value (%)
Tumor location	
Head	127 (81)
Body	22 (14)
Tail	8 (5)
Tumor size (mm)	
Range	26-70
Mean	41±15
Distant metastasis	67 (43)
Vascular invasion	138 (88)
Lymphadenopathy	89 (57)
Malignant ascites	30 (19)

**Table 3: Detecting vascular invasion, peripancreatic lymphadenopathy, liver metastasis and peritoneal involvement by EUS, MDCT, laparoscopy and laparotomy in 157 studied patients with solid pancreatic adenocarcinoma**

Extra pancreas tumoral involvement (%)	EUS (%)	MDCT (%)	Laparoscopy (%)	Laparotomy (%)	Total
Vascular invasion	136 (96)	121 (88)	0	2 (1.4)	138
Peripancreatic lymphadenopathy	87 (98)	77 (87)	0	1 (1.1)	89
Liver metastasis	21 (31)	63 (94)	2 (3)	0	67
Peritoneal involvement	5 (17)	27 (90)	1 (3)	0	30

EUS: Endoscopic ultrasonography, MDCT: Multi detector computerized tomography

after extensive local growth or widely metastatic disease has developed. Tumors of the tail of the pancreas do not cause biliary obstruction and jaundice. However, in our practice, both pancreatic adenocarcinomas located in body/tail and head were diagnosed late. Perhaps

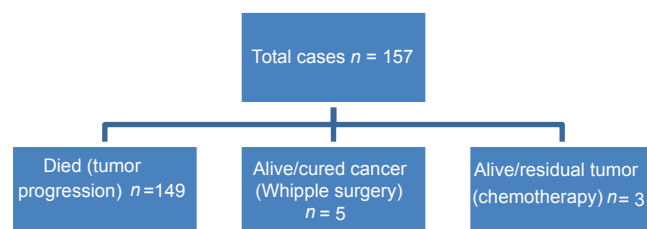
non-specific clinical presentation is the major etiology for these unpromising results.

According to the MDCT scan and EUS findings in our study, tumor was resectable in 10 patients (6%) but two had peritoneal involvement in laparoscopy. Eight patients with resectable tumor in laparoscopy underwent curative Whipple surgery. After 2 years follow-up, five were tumor free and three were on the chemotherapy for residual disease. These results indicate not only MDCT/EUS but also laparoscopy is not reliable for predicting resectability.

MDCT is almost 100% accurate in predicting unresectability.<sup>[4]</sup> However, 25-50% of patients predicted to have resectable disease according to the MDCT, are found to have unresectable lesions at laparotomy.<sup>[4-6]</sup> Furthermore, in our experience 50% of patients predicted to have resectable cancer according to the MDCT/EUS and 37.5% of cases predicted to have resectable disease according to the laparoscopy, were found to have unresectable lesions at laparotomy or next 2 years follow-up.

Figure 1 shows outcome of the studied patients after 2 years follow-up; only 8 cases were alive and only 5 cases (3%) were tumor free. As mentioned in Figure 1, only five cases (3%) that were tumor free 2 years after curative Whipple surgery were really resectable at the time of diagnosis. Cancer resectability rate in our patients was only 3% but in some regions is about 20%.<sup>[13]</sup> This shows that pancreatic cancer in our experience discovered late in advanced phases. This delay in diagnosis may be due to lateness of tumor symptoms onset, inattention to non-specific clinical symptoms (both by patient and by clinician) and/or low accuracy of imaging modality that are used in our country.

Some of our patients including those with tumor located in pancreatic head and those with body/tail tumor did not present with typical symptom(s) or sign(s) of pancreas malignancy such as abdominal pain, weight loss and icter. These patients had mild symptom(s) including dyspepsia or abdominal discomfort for a long duration, e.g. 12 months. This



**Figure 1:** Two years follow up of studied patients

unusual clinical presentation of tumor in our patients is one of the causes leading to pancreatic cancer misdiagnosis and subsequently less resectability. Therefore, clinician should be alert to the non-specific clinical symptoms and signs that are subtle in early stage of this malignancy.

In old aged patients with dyspepsia or upper abdomen discomfort with normal upper endoscopy, attention to this malignancy is wisdom; careful and detailed review of the clinical symptoms and early implement of pancreas protocol MDCT and/or EUS may be useful for better diagnosis specially if there is new onset diabetes mellitus and/or elevated serum CA 19-9 level.

### CONCLUSION

Majority (97%) of the pancreatic adenocarcinoma cases are unresectable at time of the diagnosis. Thus, meticulous preoperative assessment of resectability needed for avoiding a major surgery in unresectable cases.

Not only in the patients with typical clinical setting but also in approach to the non-specific upper abdominal discomfort in old aged patients with normal transabdominal ultrasound and normal endoscopy, attention to this malignancy and early implement of pancreas protocol MDCT and/or EUS is wisdom for early diagnosis.

### REFERENCES

1. Feldman M, Friedman S, Brandt J. Sleisenger and Fordtran's Gastrointestinal and Liver Disease. 9<sup>th</sup> ed. Philadelphia: Frank Polizzano; 2010.
2. Hruban RH, Pitman MB, Klimstra DS. AFIP Atlas of Tumor Pathology. Tumors of the Pancreas. Washington, D.C.: American Registry of Pathology; 2007. p. 111-64.
3. Solcia E, Capella C, Kloppel G Tumors of the Pancreas. Washington, D.C.: Armed Forces Institute of Pathology; 1997. p. 31-144.
4. Coley SC, Strickland NH, Walker JD, Williamson RC. Spiral CT and the pre-operative assessment of pancreatic adenocarcinoma. Clin Radiol 1997;52:24-30.
5. Freeny PC, Traverso LW, Ryan JA. Diagnosis and staging of pancreatic adenocarcinoma with dynamic computed tomography. Am J Surg 1993;165:600-6.
6. Megibow AJ, Zhou XH, Rotterdam H, Francis IR, Zerhouni EA, Balfe DM, *et al.* Pancreatic adenocarcinoma: CT versus MR imaging in the evaluation of resectability – Report of the Radiology Diagnostic Oncology Group. Radiology 1995;195:327-32.
7. Lu DS, Reber HA, Krasny RM, Kadell BM, Sayre J. Local staging of pancreatic cancer: Criteria for unresectability of major vessels as revealed by pancreatic-phase, thin-section helical CT. AJR Am J Roentgenol 1997;168:1439-43.
8. O'Malley ME, Boland GW, Wood BJ, Fernandez-del Castillo C, Warshaw AL, Mueller PR. Adenocarcinoma of the head of the pancreas: Determination of surgical unresectability with thin-section pancreatic-phase helical CT. AJR Am J Roentgenol 1999;173:1513-8.
9. Raptopoulos V, Steer ML, Sheiman RG, Vrachliotis TG, Gougoutas CA,

- Movson JS. The use of helical CT and CT angiography to predict vascular involvement from pancreatic cancer: Correlation with findings at surgery. *AJR Am J Roentgenol* 1997;168:971-7.
10. Gress F, Gottlieb K, Sherman S, Lehman G. Endoscopic ultrasonography-guided fine-needle aspiration biopsy of suspected pancreatic cancer. *Ann Intern Med* 2001;134:459-64.
  11. Baghbanian M, Shabazkhani B, Ghofrani H, Forutan H, Dariani N, Farahvash M, *et al.* Efficacy of endoscopic ultrasound guided fine needle aspiration in patients with solid pancreatic neoplasms. *Saudi J Gastroenterol* 2012;18:358-63.
  12. Li D, Xie K, Wolff R, Abbruzzese JL. Pancreatic cancer. *Lancet* 2004;363:1049-57.
  13. Sohn TA, Lillemoe KD, Cameron JL, Huang JJ, Pitt HA, Yeo CJ. Surgical palliation of unresectable periampullary adenocarcinoma in the 1990s. *J Am Coll Surg* 1999;188:658-66.

**Source of Support:** Nil, **Conflict of Interest:** None declared.