

# Scleral buckling in phakic uncomplicated primary rhegmatogenous retinal detachment: long-term outcomes

Claudia Quijano<sup>1,2</sup>, Micol Alkabes<sup>1,3</sup>, Maria Gómez-Resca<sup>1</sup>, Andrea Oleñik<sup>1</sup>, Edoardo Villani<sup>4</sup>, Borja Corcóstegui<sup>1</sup>

<sup>1</sup>Institute of Ocular Microsurgery (IMO), Barcelona - Spain

<sup>2</sup>Western Eye Hospital, London - UK

<sup>3</sup>IRCCS MultiMedica, San Giuseppe Hospital University Eye Clinic, Milan - Italy

<sup>4</sup>Department of Clinical Sciences and Community Health, University of Milan, Milan - Italy

## ABSTRACT

**Purpose:** Scleral buckling (SB) is a surgical technique that has been used successfully to treat retinal detachments for the last 6 decades. The aim of this study was to report the long-term anatomical and functional outcomes of SB surgery in phakic patients with uncomplicated primary rhegmatogenous retinal detachment (PRRD). This article also outlines the benefits of SB compared to pars plana vitrectomy, such as reducing the risk of developing cataract, high intraocular pressure, and glaucoma, in addition to reducing surgical cost.

**Methods:** We retrospectively reviewed the clinical notes of 90 phakic eyes with PRRD treated with SB surgery that had a minimum of 5 years follow-up. Preoperative and postoperative characteristics were recorded. Main outcome measures were reattachment rate, best-corrected visual acuity (BCVA) improvement, and complications.

**Results:** A total of 90 eyes (88 patients) with phakic PRRD repaired through SB surgery were included. Mean age was  $49.2 \pm 14.6$  years (range 20-80). Primary and final anatomic success was 96.7% and 100%, respectively. Mean preoperative BCVA was  $0.3 \pm 0.31$  logMAR (6/12) and mean postoperative BCVA  $0.1 \pm 0.2$  logMAR ( $p < 0.001$ ) (6/7.5). There were no cataract or primary open-angle glaucoma cases after 1 year of follow-up. Mean follow-up was  $8.5 \pm 2.6$  years (range 5-13).

**Conclusions:** We report a high single operation success rate over time in phakic PRRD, repaired through SB surgery. Functional and anatomical success was maintained throughout the follow-up without complications. Therefore, the authors recommend the use of this technique in selected cases in order to reduce morbidity and the incidence of reoperations.

**Keywords:** Long-term outcomes retinal surgery, Primary phakic rhegmatogenous retinal detachment, Retinal detachment surgery, Scleral buckling

## Introduction

Primary rhegmatogenous retinal detachment (PRRD) treatment has evolved since Gonin (1) described the principle for sustained surgical success as finding and closing the break, in addition to subretinal fluid (SRF) drainage. Subsequently, Custodis (2) reported the first segmental scleral sponge explant surgery, followed by Schepens et al (3) describing an encircling scleral buckle (SB) procedure. It is well-known that

placement of the SB is technically demanding: prolonged surgical time and complications can eventually appear. However, these rare complications may be justified by the benefits of SB surgery, such as the low risk of glaucoma (4) and cataract development, the reduction in surgery cost (5), and superior or similar outcomes when compared with pars plana vitrectomy (PPV) (6).

Although new techniques and devices have been developed to improve the reattachment rate and functional outcomes, debate concerning what is best practice for treating phakic PRRD continues. Even though the development of multiple new techniques has improved the success rate, we still need to identify the optimal approach to provide successful long-term anatomical and functional outcomes that would be cost-effective and avoid development of cataract or the rise in intraocular pressure (IOP) that can lead to glaucoma (7).

There are numerous surgical options for reattaching the retina in retinal detachment (RD); one of the most important factors for a successful outcome is the correct selection of the

Accepted: November 13, 2016

Published online: December 31, 2016

### Corresponding author:

Dr. Claudia Quijano  
Western Eye Hospital  
153-173 Marylebone Rd.  
NW1 5QH London, UK  
claudiaquijano@hotmail.com



patient, in addition to the characteristics of the RD (8) and the retinal surgeon's expertise. However, in most cases, it is the surgeon who chooses a particular technique based on his or her ability. There is increasing evidence that the use of PPV to treat PRRD is on the rise (9). However, some of these cases can be safely managed with SB without the need of PPV; the single operation successful rates are similar, and PPV may hold a risk of proliferative vitreoretinopathy (PVR), in addition to a 2.5-fold risk of reoperation (10).

The aim of this study was to research whether SB procedure for phakic patients with PRRD is an effective approach and should lead to a good long-term result, reducing the risk of developing cataract, high IOP, or glaucoma, in addition to reducing surgical cost (5).

## Methods

A retrospective review of 100 consecutive medical files of all the phakic patients who presented with PRRD treated with SB between January 1999 and December 2005 was undertaken. All surgeries were performed by the same surgeon (B.C.) at the Instituto de Microcirugía Ocular Barcelona. Only patients with a minimum of 5 years follow-up were included. The inclusion criteria included PRRD and phakic eye. Exclusion criteria included previous RD surgery, exudative or tractional RD, posttraumatic RD, and PVR B or more advanced state. After the selection, 90 eyes of 88 patients were studied. This study was approved by the institutional review board and followed the ethical standards of the Declaration of Helsinki.

The information reviewed from the records was codified in an Excel table and divided into 4 groups: (1) demographic and ophthalmic preoperative data: age, sex, eye, clinical symptoms and duration, best-corrected visual acuity (BCVA), lens status, IOP, spherical equivalent (SE), previous treatments (refractive surgery, cryotherapy, or laser photocoagulation), and status of the fellow eye; (2) features of the RD: number, type, and distribution of the retinal breaks, extent of the peripheral detachment measured in clock hours, posterior extent (macula on-off), and presence of posterior vitreous detachment; (3) data on surgery: type of buckle (segmental or 360° encircling buckle) and size, SRF drainage, cryotherapy or laser photocoagulation, use of tamponade, and intraoperative complications; and (4) postoperative data: primary and final reattachment, postoperative BCVA, final lens status, associated complications, additional procedures if needed, and follow-up. Preoperative and postoperative BCVA was measured using a decimal chart acuity. When the patient was not able to read a number on the chart, we used counting fingers, hand movement, and light perception. Refraction was performed on each patient by an expert optometrist. Each patient underwent slit-lamp and thorough indirect ophthalmoscopy examination. The indirect ophthalmoscopy examination was documented in the clinical notes with a schematic drawing of the retinal breaks, lattice degeneration, PVR, and extension of the RD.

## Surgical technique

The surgery was performed on the same day or on the day after the diagnosis and under retrobulbar anesthesia for

all cases. The technique included grades of conjunctival peritomy according to the planning of 360° encircling or segmental buckle. The surgery aimed to include all breaks with a single buckle, or a combination of a segmental with a 360° encircling buckle when required. Transpupillary identification of retinal hole, tear, or break was assisted by indirect ophthalmoscopy. Transpupillary diode laser photocoagulation or transscleral cryotherapy was applied to surround the breaks, in addition to transscleral SRF drainage or intravitreal gas injection if necessary. All eyes were evaluated the day after, at day 7, 1 month, 3 months, 6 months, and annually thereafter.

## Statistical methods

The BCVA achieved by each patient after 5 years of follow-up was considered to be the primary functional outcome. For statistical analysis, BCVA was converted to logMAR (SPSS for Windows, version 12.0; SPSS, Chicago, IL, USA). Quantitative parameters were expressed as mean  $\pm$  SD. Preoperative and postoperative data were compared by paired samples *t* test. Both preoperative and postoperative BCVA were further compared between 2 or more subgroups of patients using independent samples *t* test or analysis of variance with least significant difference post hoc test, respectively. The Spearman rank coefficient was calculated to assess correlations between preoperative and postoperative quantitative variables and a chi-square test was used to evaluate the associations between qualitative parameters. A *p* value <0.05 was considered statistically significant.

## Results

### Demographic and ophthalmic preoperative data

We reviewed a total of 90 eyes (88 patients), 53% men and 47% women, with a mean age of  $49.2 \pm 14.6$  years (range 20-80); 57% were right eyes. The most common symptom was blurred vision (32%), followed by scotoma (27%) and floaters (20%); 21% were asymptomatic. The patients presented to the clinic after a mean of  $4.5 \pm 6.1$  days (range 0-30) after the initial symptom. Demographic details are presented in Table I.

TABLE I - Demographic features

Demographic features	No.	%
Sex		
Female	46	53
Male	42	47
Eye		
Right	50	57
Left	38	43
Symptoms		
Blurred vision	28	32
Scotoma	24	27
Floaters	18	20
Asymptomatic	18	21

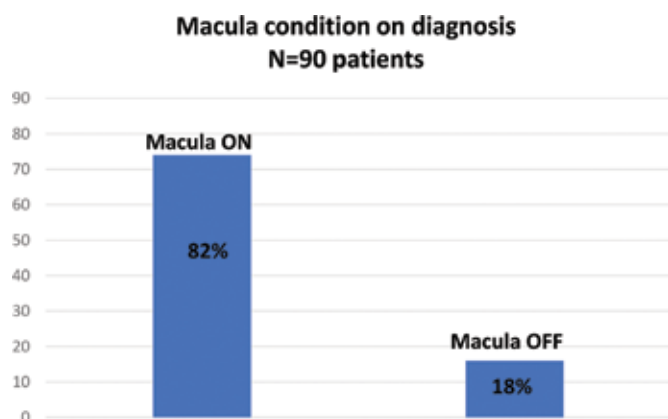


Fig. 1 - Macular condition on diagnosis.

The mean preoperative BCVA was  $0.3 \pm 0.31$  logMAR (range 1-0.01). Three patients had previous refractive surgery (laser-assisted in situ keratomileusis), and in another 3 the affected eye was amblyopic. Mean preoperative SE was  $-4.2 \pm 4.3$  D (range +6.00 to -18.00 D). The mean preoperative IOP was  $15.2 \pm 3.3$  mm/Hg (range 8-26 mm/Hg). Only one patient had a previous diagnosis of primary open angle glaucoma (POAG). Indirect ophthalmoscopy showed that 16% of the eyes that had RD were treated in the past (11% treated with only laser, 2% had laser treatment combined with cryotherapy) and 23% had lattice degeneration. With regard to the fellow eye, 6% had lattice degeneration and 37% had RD treatment such as RD surgery (28%) and laser retinopexy (18%).

### Features of RD

Only one break was found in 56.7% of the eyes (mean  $1.9 \pm 1.2$ , range 1-6 holes). Overall, we found 56.7% (51 eyes) retinal holes, 34.4% (31 eyes) retinal tears, 5.6% (5 eyes) retinal dialysis, and 3.3% (3 eyes) retinal hole and tear. The most common location of the breaks was inferior, 42.2% (38 eyes), and superior, 37.8% (24 eyes). The most common location of RD was superotemporal, 42.2% (38 eyes); inferior, 35.6% (32 eyes); and superior, 21.1% (19 eyes). The mean extent of RD was  $4.9 \pm 1.8$  clock hours (range 2-12 clock hours), with a mean compromise of 2 quadrants. There was only one total RD. Posterior vitreous detachment was present in 42.2% of the cases, PVR grade A in 3.4%, and mild vitreous hemorrhage (VH) in 1%. The macula was on in 82% of the cases and off in 18% (Fig. 1).

### Surgical data

All cases were treated with only SB. The most frequent treatment was segmental SB (59%), where the segmental circumferential SB was 56% (50 eyes) and the segmental radial was 3% (3 eyes). The 360° encircling SB was 41%, where 26% (23 eyes) had 2.5 mm SB and 15% (14 eyes) had 4 mm SB.

Each size was used according to the axial length of the eye. Subretinal fluid drainage was performed in 67.8% and anterior chamber paracentesis in 3%. Peripheral laser retinopexy was done in 91.1%, cryotherapy in 7.8%, and both in 1.1%. The great majority of cases (88.9%) did not require tampon-

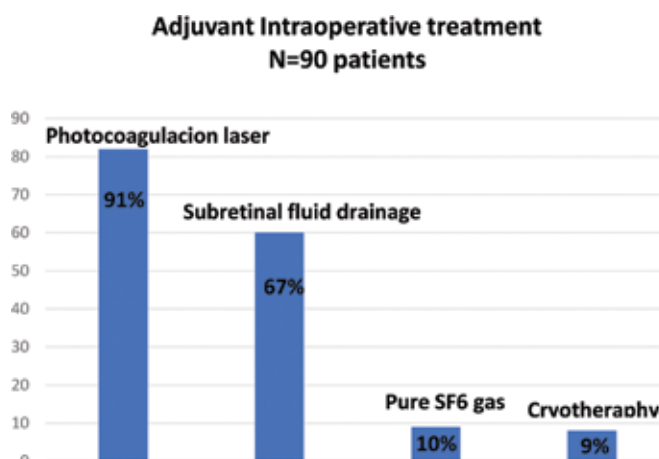


Fig. 2 - Adjuvant intraoperative treatment.

TABLE II - Results

Results	%
Data on surgery	
Subretinal fluid drainage	67.8
Peripheral laser	91.1
Cryotherapy	7.8
Success rate of scleral buckling surgery (n = 90)	
Primary	97
Secondary	100
Ocular complications in the first year (n = 90)	
None	92
Subretinal fluid	3
Cystoid macular edema	3
Subretinal hemorrhage	1
Explant extrusion	1

ade. In 10% (9 eyes), the surgeon used 0.2 mL SF<sub>6</sub> 100% and in 1 eye 0.4 mL of air (Fig. 2). There were no intraoperative complications reported.

### Postoperative data

The primary retinal reattachment rate was 96.7%. In 3.3% of the cases, additional procedures were performed to reattach the retina, and after surgery (range 1-3), all the cases had the retina reattached. Results are detailed in Table II.

Five patients (5.7%) in whom the retina was primarily attached had recurrent RD within 4 years (range 2-4 years). In all these cases, anatomical success was achieved with 1 to 3 additional surgeries, and the retina remained attached during the entire follow-up.

The final BCVA was  $0.10 \pm 0.17$  logMAR in macula-on RD and  $0.16 \pm 0.28$  logMAR in macula-off RD ( $p < 0.05$ , independent samples *t* test).

During the first year of follow-up, 92.2% did not develop ocular complications, 3.3% had subretinal hemorrhage (3 eyes), 2.2% had persistent SRF (2 eyes), 1.1% had cystoid

macular edema (CME) (1 eye), and 1.1% (1 eye) had VH. After 1 year, one SB was removed due to extrusion and another developed subretinal fibrosis. After 5 years, one eye developed a myopic choroidal neovascularization, which required intravitreal antiangiogenic therapy. The mean postoperative IOP was  $15.5 \pm 2.6$  mm/Hg (range 9-19 mm/Hg). Two patients developed open-angle glaucoma (OAG) during the follow-up; however, it was bilateral, and the finding was not related to the surgical procedure. In this group of patients, the mean follow-up time was  $8.5 \pm 2.6$  years (range 5-13 years).

## Discussion

Our research is a retrospective long-term study of consecutive SB surgery in phakic PRRD in one institution in Barcelona, Spain. The results showed a high anatomical and functional success rate, and no cases of cataract progression, glaucoma development, or endophthalmitis, in contrast to reports from PPV research papers (11). The patients presented here had sustained visual acuity (VA) rehabilitation.

We reviewed the literature on PRRD treatment reporting functional and anatomical outcomes and complications. In a study that compared the results of primary PPV and conventional SB procedures in uncomplicated forms of phakic RRD, the BCVA achieved after SB was statistically significant and sustained over the time, similar to our outcomes (12). The above conclusion, with regard to long-term stable BCVA, was supported by a 10-year visual function follow-up study on 205 patients after SB, which reported improved and sustained BCVA over this period of time (13). Also, a recent report from Wong et al (14) comparing visual outcomes between PPV with or without SB and SB alone in the management of macula-off PRRD showed that in the SB group 43.2% achieved functional success compared with 28% in the PPV±SB group.

In addition to these successful VA outcomes, our study achieved a primary reattachment success rate of 96.7%, vs the 64% to 93% success rate reported by the SPR study (15) comparing SB vs primary PPV in rhegmatogenous RD. Also, 100% of secondary reattachment success was achieved, in comparison to the 97% presented in the same SPR study.

In RD secondary to retinal dialysis (5.6%), SB with cryotherapy was an effective primary procedure. A retrospective study (16) of 28 patients treated with cryobuckle procedure for RD secondary to retinal dialysis reported a single operation anatomical success of 92.9%. Their most frequent postoperative complication was exposure of the cryobuckle under the conjunctiva in 67.9% of cases. We did not see this type of postoperative complication in our study patients; however, this may be due to the small number of RDs secondary to retinal dialysis in our sample.

Cryotherapy was applied as an intraoperative adjuvant treatment in 7.8% of patients. There was no reported postoperative inflammation or emergence of PVR. Conversely, Veckeneer et al (17) reported postoperative flare in patients receiving cryotherapy. The same authors concluded that VA after 10 weeks of treatment was not significantly different between cryotherapy and laser photocoagulation. Our cases treated with laser photocoagulation did not display any complications, in contrast with van Meurs et al (18), who reported

cases of postoperative PVR, but with encouraging anatomical results.

A state of the art study (19) researching SRF after rhegmatogenous RD surgery performed with different surgical techniques was published in 2012. The authors found that persistent SRF appears to occur more frequently in patients with longstanding detachments before the SB. This suggests that these specific cases may require further surgery to help drain the remaining fluid that in many cases can delay recovery and may affect final VA. Our study had just 2.2% SRF cases after SB surgery. We hypothesize that this low incidence of SRF might have been because all the RD cases were treated in a short period after presenting symptoms.

Another prospective research study carried out on 98 patients treated with SB surgery (20) found that persistent SRF occurred in 55% of the patients after 6 weeks. This persistent SRF disappeared around 10 months later, and was responsible for delayed visual recovery. The visual outcomes were favorable. In our research study, we did not use routine spectral-domain optical coherence tomography (SD-OCT) to assess all the patients postoperatively. We used it when we suspected SRF due to poor improvement of BCVA. This can be a reason for the difference in percentage in the SRF between the study by Benson et al (20) and ours. In our study, the persistence of SRF was resolved after 12 months without jeopardizing the long-term visual recovery.

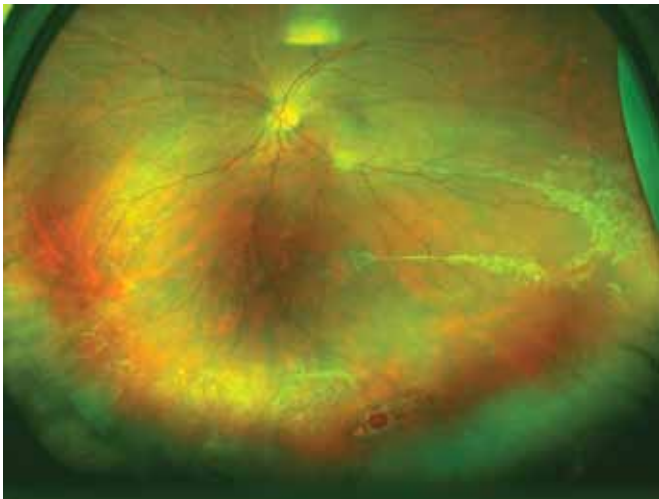
Peripheral SRF can be monitored more accurately with scanning laser ophthalmoscopy/SD-OCT; OCT also can confirm whether the holes have been closed and the retina is attached (21).

After 1 year of follow-up, 92% of the patients did not have any complications. In the other 8%, we observed the following: SRF (3%), CME (3%), explant extrusion (1%), and subretinal hemorrhage (1%). Every complication was resolved accordingly. Other complications after an SB surgery technique reported in different studies, such as double vision, squint, raised IOP, PVR, or epiretinal membrane (22), were not seen in our group of patients.

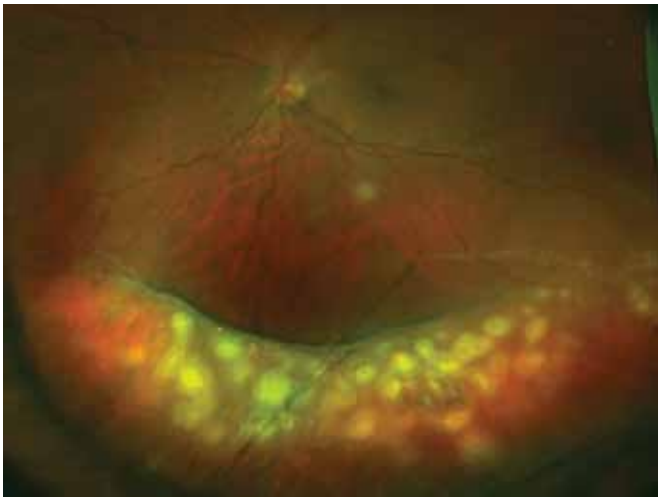After a mean follow up of 8.5 years (range 5-13 years), no patient developed OAG secondary to the SB procedure. Two patients were diagnosed with POAG during the follow-up, but it was bilateral and not related to the surgery. This supports the use of the SB technique vs PPV, which can introduce the risk of OAG, due to oxidative damage to the trabecular meshwork cells altering the drainage of aqueous fluid after PPV (4).

There were no cases of cataract development in our sample, in contrast with the progression of nuclear sclerosis and posterior subcapsular opacification of the lens after PPV described in a report of 193 cases treated with vitreoretinal surgery. This cataract formation was reported as common by Feng and Adelman (23) following PPV regardless of the gauge used. In addition, a meta-analysis of randomized controlled trials that analyzed SB vs PPV for uncomplicated PRD reported no cataract progression after SB, and for the PPV the major drawback was the high incidence of postoperative cataract formation (6).

A retrospective review of 45 patients who underwent SB for inferior RRD reported 80% anatomical success, in contrast with our group of inferior RD patients (Fig. 3), who all had



**Fig. 3** - Inferior retinal detachment with 2 quadrants compromised and multiple inferior holes.



**Fig. 4** - Peripheral segmental indentation and retinal laser scars (images taken with Optomap®; Optos plc, Dunfermline, Scotland).

retinal reattachment after inferior SB (Fig. 4). The authors argued that this specific group of patients with inferior RD consulted late and were mostly myopic (24). They concluded that the buckle has to be positioned according to the location of the breaks in order to reattach the retina successfully, supporting our study findings.

Our study has shown that SB is effective in closing a tear, hole, or break in any of the 4 quadrants with successful anatomical outcome. However, account should be taken of the bias in our research, such as single-center data, a single surgeon operating, and retrospective data.

### Disclosures

Financial support: No financial support was received for this submission.

Conflict of interest: None of the authors has conflict of interest with this submission.

### References

1. Gonin J. The Evolution of Ideas Concerning retinal detachment within the last five years. *Br J Ophthalmol.* 1933;17(12): 726-740.
2. Custodis E. [Treatment of retinal detachment by circumscribed diathermal coagulation and by scleral depression in the area of tear caused by imbedding of a plastic implant]. *Klin Monbl Augenheilkd Augenarztl Fortbild.* 1956;129(4):476-495.
3. Schepens CL, Okamura ID, Brockhurst RJ. The scleral buckling procedures. I. Surgical techniques and management. *AMA Arch Ophthalmol.* 1957;58(6):797-811.
4. Chang S. LXII Edward Jackson lecture: open angle glaucoma after vitrectomy. *Am J Ophthalmol.* 2006;141(6):1033-1043.
5. Seider MI, Naseri A, Stewart JM. Cost comparison of scleral buckle versus vitrectomy for rhegmatogenous retinal detachment repair. *Am J Ophthalmol.* 2013;156(4):661-666.
6. Sun Q, Sun T, Xu Y, et al. Primary vitrectomy versus scleral buckling for the treatment of rhegmatogenous retinal detachment: a meta-analysis of randomized controlled clinical trials. *Curr Eye Res.* 2012;37(6):492-499.
7. Koreen L, Yoshida N, Escariao P, et al. Incidence of, risk factors for, and combined mechanism of late-onset open-angle glaucoma after vitrectomy. *Retina.* 2012;32(1):160-167.
8. Heussen N, Feltgen N, Walter P, Hoerauf H, Hilgers RD, Heimann H; SPR Study Group. Scleral buckling versus primary vitrectomy in rhegmatogenous retinal detachment study (SPR Study): predictive factors for functional outcome. Study report no. 6. *Graefes Arch Clin Exp Ophthalmol.* 2011;249(8): 1129-1136.
9. Schwartz SG, Flynn HW. Pars plana vitrectomy for primary rhegmatogenous retinal detachment. *Clin Ophthalmol.* 2008;2(1):57-63.
10. Kreissig I. Surgical techniques for repair of primary retinal detachment: Part II. Comparison of present techniques in relation to morbidity. *Folia Med (Plovdiv).* 2010;52(1):5-11.
11. Azad RV, Chanana B, Sharma YR, Vohra R. Primary vitrectomy versus conventional retinal detachment surgery in phakic rhegmatogenous retinal detachment. *Acta Ophthalmol Scand.* 2007;85(5):540-545.
12. Heimann H, Bartz-Schmidt KU, Bornfeld N, Weiss C, Hilgers RD, Foerster MH; Scleral Buckling versus Primary Vitrectomy in Rhegmatogenous Retinal Detachment Study Group. Scleral buckling versus primary vitrectomy in rhegmatogenous retinal detachment: a prospective randomized multicenter clinical study. *Ophthalmology.* 2007;114(12):2142-2154.
13. Sasoh M, Ito Y, Wakitani Y, Matsubara H, Matsunaga K, Uji Y. 10-year follow-up of visual functions in patients who underwent scleral buckling. *Retina.* 2005;25(8):965-971.
14. Wong CW, Yeo IY, Loh BK, et al. Scleral Buckling versus Vitrectomy in the Management of Macula-off Primary Rhegmatogenous Retinal Detachment: A comparison of Visual outcomes. *Retina.* 2015;35(12):2552-2557.
15. Feltgen N, Heimann H, Hoerauf H, Walter P, Hilgers RD, Heussen N; Writing group for the SPR study investigators\*. Scleral buckling versus primary vitrectomy in rhegmatogenous retinal detachment study (SPR study): Risk assessment of anatomical outcome. SPR study report no. 7. *Acta Ophthalmol.* 2013;91(3):282-287.
16. James M, ODoherty M, Beatty S. Buckle-related complications following surgical repair of retinal dialysis. *Eye (Lond).* 2008;22(4):485-490.
17. Veckeneer M, Van Overdam K, Bouwens D, et al. Randomized clinical trial of cryotherapy versus laser photocoagulation for retinopexy in conventional retinal detachment surgery. *Am J Ophthalmol.* 2001;132(3):343-347.

18. van Meurs JC, Feron E, van Ruyven R, Mulder P, Veckeneer M. Postoperative laser coagulation as retinopexy in patients with rhegmatogenous retinal detachment treated with scleral buckling surgery: a prospective clinical study. *Retina*. 2002;22(6):733-739.
19. Veckeneer M, Derycke L, Lindstedt EW, et al. Persistent subretinal fluid after surgery for rhegmatogenous retinal detachment: hypothesis and review. *Graefes Arch Clin Exp Ophthalmol*. 2012;250(6):795-802.
20. Benson SE, Schlottmann PG, Bunce C, Xing W, Charteris DG. Optical coherence tomography analysis of the macula after scleral buckle surgery for retinal detachment. *Ophthalmology*. 2007;114(1):108-112.
21. Oster SF, Mojana F, Freeman WR. Spectral-domain optical coherence tomography imaging of postoperative scleral buckles. *Retina*. 2011;31(8):1493-1499.
22. Shankar V, Lim LT, Ah-Kee EY, Hammer H. Outcome of rhegmatogenous retinal detachment repair by scleral buckling: The experience of a tertiary referral center in Scotland. *Oman J Ophthalmol*. 2014;7(3):130-134.
23. Feng H, Adelman RA. Cataract formation following vitreoretinal procedures. *Clin Ophthalmol*. 2014;8(8):1957-1965.
24. Abdellaoui M, Chraibi F, Benatiya Andaloussi I, Tahri H. [Scleral buckling for inferior rhegmatogenous retinal detachments]. *J Fr Ophtalmol*. 2014;37(8):623-628.