

Available online at [www.sciencedirect.com](http://www.sciencedirect.com)

ScienceDirect

journal homepage: [www.elsevier.com/locate/radcr](http://www.elsevier.com/locate/radcr)

## Case Report

# MRI-guided conservative management of a left segmental testicular infarction ☆☆☆

Sat Prasad Nepal, MBBS\*, Takeshi Shichijo, MD, PhD, Yoshio Ogawa, MD, PhD, Takehiko Nakasato, MD, PhD, Yoshihiro Nakagami, MD, PhD, Jun Morita, MD, PhD, Kazuhiko Oshinomi, MD, Ph.D, Yoshiko Maeda, MD, PhD, Tsutomu Unoki, MD, PhD, Tatsuki Inoue, MD, Ryosuke Kato, MD, Satoshi Amano, MD, Moyuru Mizunuma, MD

Department of Urology, Showa University School of Medicine, 1-5-8 Hatanodai, Shinagawa-Ku, Tokyo, 142-8555, Japan

## ARTICLE INFO

## Article history:

Received 12 January 2021

Revised 28 January 2021

Accepted 28 January 2021

## Keywords:

Segmental testicular infarction

MRI

Conservative treatment

## ABSTRACT

Segmental testicular infarction is a rare condition. Patients present with clinical features similar to torsion and testicular tumors, with most undergoing surgery. A 55-year-old male patient presented with left scrotal pain. We did a Doppler ultrasonogram and magnetic resonance imaging to diagnose his condition and rule out testicular torsion and tumor. We decided not to operate and asked the patient for follow-up. There was no pain in the left testis, and magnetic resonance imaging showed a reduction in the left testicular lesion after 4 months.

© 2021 The Authors. Published by Elsevier Inc. on behalf of University of Washington.

This is an open access article under the CC BY-NC-ND license

(<http://creativecommons.org/licenses/by-nc-nd/4.0/>)

## Introduction

Partial testicular infarction is a unique condition that is mostly idiopathic in nature [1–3]. Clinically, it resembles torsion and testicular tumors, thus making it difficult for urologists to observe or perform surgery [1–4]. In this case report, we illustrate how radiological investigations can allow the patient to be safely monitored without intervention.

## Case report

A 55-year-old man presented with pain in the lower abdominal region and medial side of the thigh at a local clinic. There was no history of nausea, diarrhea, fever, vomiting, or testicular trauma. He had a history of overactive bladder managed with mirabegron. Plain computed tomography scan of the scrotum was normal, and the patient was sent home.

☆ Funding: None.

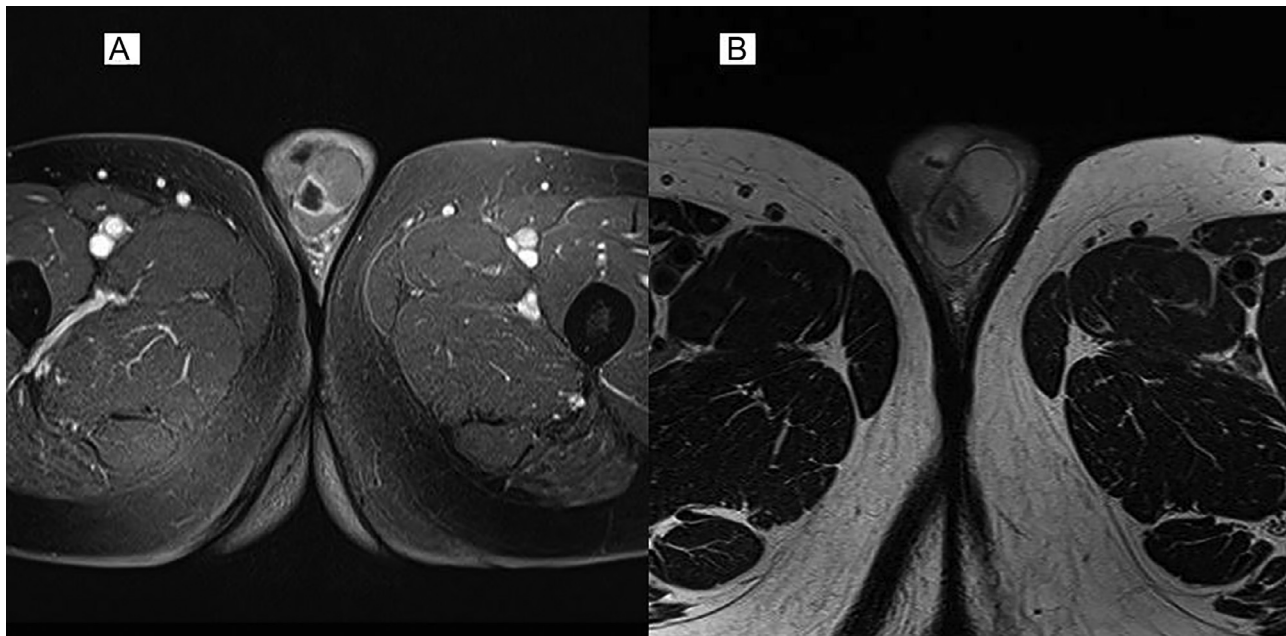
☆☆ Competing Interest: No conflict of interest exists.

\* Corresponding author.

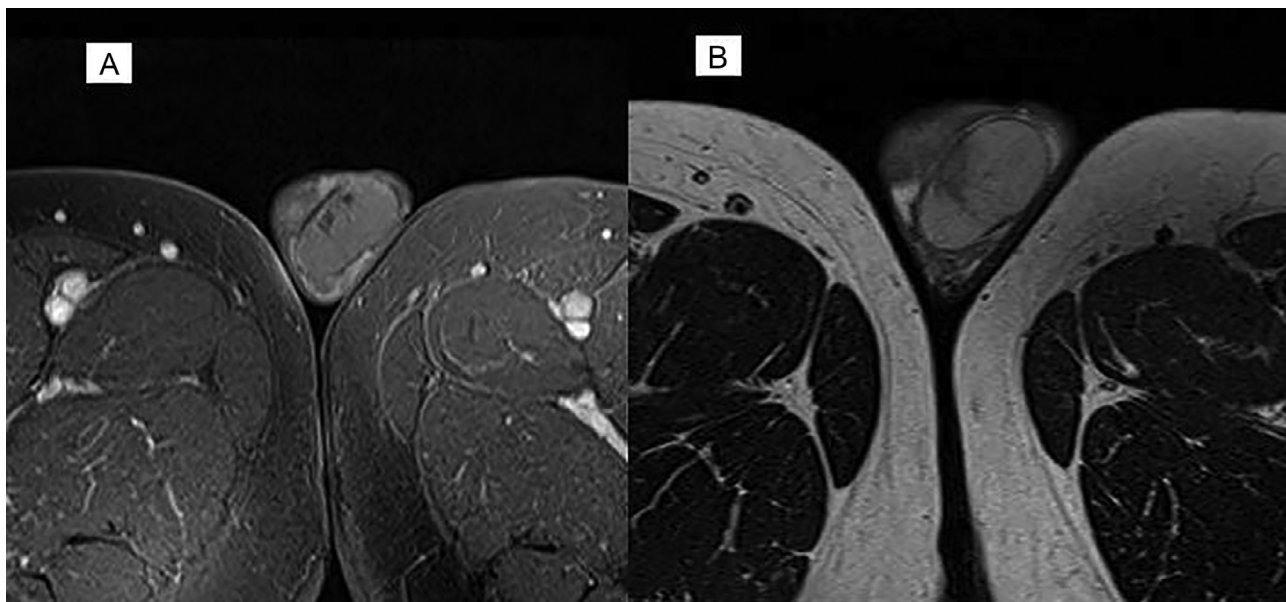
E-mail addresses: [satprasad1@cmed.showa-u.ac.jp](mailto:satprasad1@cmed.showa-u.ac.jp) (S.P. Nepal), [shichijo@med.showa-u.ac.jp](mailto:shichijo@med.showa-u.ac.jp) (T. Shichijo), [ogawayos@med.showa-u.ac.jp](mailto:ogawayos@med.showa-u.ac.jp) (Y. Ogawa), [nakasato@med.showa-u.ac.jp](mailto:nakasato@med.showa-u.ac.jp) (T. Nakasato), [yo\\_nakagami@med.showa-u.ac.jp](mailto:yo_nakagami@med.showa-u.ac.jp) (Y. Nakagami), [moritajun@med.showa-u.ac.jp](mailto:moritajun@med.showa-u.ac.jp) (J. Morita), [oshikazu@med.showa-u.ac.jp](mailto:oshikazu@med.showa-u.ac.jp) (K. Oshinomi), [ymaeda@med.showa-u.ac.jp](mailto:ymaeda@med.showa-u.ac.jp) (Y. Maeda), [t-unoki@med.showa-u.ac.jp](mailto:t-unoki@med.showa-u.ac.jp) (T. Unoki), [tatsuki22@med.showa-u.ac.jp](mailto:tatsuki22@med.showa-u.ac.jp) (T. Inoue), [katoryosuke@med.showa-u.ac.jp](mailto:katoryosuke@med.showa-u.ac.jp) (R. Kato), [satoshi\\_aman@med.showa-u.ac.jp](mailto:satoshi_aman@med.showa-u.ac.jp) (S. Amano), [mmizunuma@med.showa-u.ac.jp](mailto:mmizunuma@med.showa-u.ac.jp) (M. Mizunuma).

<https://doi.org/10.1016/j.radcr.2021.01.050>

1930-0433/© 2021 The Authors. Published by Elsevier Inc. on behalf of University of Washington. This is an open access article under the CC BY-NC-ND license (<http://creativecommons.org/licenses/by-nc-nd/4.0/>)



**Fig. 1 – (A) Axial postgadolinium fat suppressed T1 MRI with enhanced boundaries around the infarction, and (B) axial T2 MRI with low signal intensity lesions with clear borders.**



**Fig. 2 – (A) Axial postgadolinium fat suppressed T1 MRI and (B) axial T2 MRI showing reduction in lesion compared with that in Fig. 1.**

After 4-5 hours, he felt continuous nonradiating left testicular pain for which he came to our outpatient department. The patient reported no history of penile discharge, dysuria, fever, vomiting, or sleep disturbance. On physical examination, there was tenderness on the left scrotal region. There was no enlargement, hardness of testis, discoloration of the left scrotum, or inguinal or abdominal swellings. The cremasteric reflex was present.

Ultrasonography of the left scrotal region showed an isoechoic left testicular lesion. To confirm the lesion we recommended MRI, on T2 magnetic resonance imaging (MRI), a wedge-shaped low intensity signal was seen in the superior lobe of the left testis. On T1 contrast MRI, a marginal contrast effect was seen with a low signal area. The findings gave an impression of left segmental testicular infarction (STI) according to the Radiology Department (Figs. 1A and B).

Patient had elevated cholesterol (246 mg/dL), low-density lipoprotein (184 mg/dL), and non-high-density lipoprotein (192 mg/dL), for which he was referred to the Department of Medicine. All other blood parameters were normal.

On follow-up after 4 months, patient felt no pain in the left testis. T1 and T2 MRI showed a reduction in the wedge-shaped lesion (Figs. 2A and B).

---

## Discussion

STI is uncommon in patients over 50 years; this typically occurs in 20- to 40-year-olds [1,2]. Patients generally present with pain in the scrotal region [4].

Although STI is idiopathic in nature, it is associated with epididymo-orchitis, sickle cell anemia, vasculitis, hypercoagulable states such as antithrombin III or protein S deficiency, venous thrombosis, folate metabolism disorder, homocysteine elevation, surgery of inguinal hernia, and varicocele [1–3].

Perez et al. found that >80% of patients with STI had lesions in the superior lobe of the testis due to lack of collaterals and unreliable blood supply from the internal testicular artery or superior centripetal arteries [2].

Because of their similar presentation, testicular torsion and cancer must be ruled out. Focal hemorrhages in testicular tumors can also result in localized pain similar to that in STI.

Color Doppler sonography will typically show a wedge-shaped localized hypoechoic avascular region with reduced blood flow [2–4]. In our case, however, we were able to find isoechoic lesions via Ultrasonography.

On T2 MRI, a wedge-shaped lesion with clear boundaries of the avascular portions in the testis is seen, whereas enhanced T1 MRI shows an enhanced rim around the defect [2,4]. Although we utilized MRI in our case for diagnosis and follow-up, it may not be available in all hospital settings and may not be useful for ruling out tumors in all cases.

Surgery is done on the suspicion of torsion or tumors to avoid medicolegal complications, as the symptoms of STI, torsion, and testicular tumors are sometimes similar. In surgery, vascularity is checked and the testis is fixed to prevent torsion. We did conservative management based on the radiological findings. There are few reports that have managed this condition conservatively.

In conclusion, we have discussed a rare case of left segmental infarction of testis presenting in the fifth decade of life, managed conservatively after an MRI assessment. On follow-up after 4 months, the patient had no complaints, and MRI showed a decrement in the lesion size.

---

## Patient Consent Statement

Written, informed consent for publication of the case was obtained from the patient.

---

## REFERENCES

- [1] Palmisano F, Serrago M, Gallioli A, Lorusso V, Gadda F, Spinelli MG, et al. Segmental testicular infarction: Case series and brief literature review of a great mime. *Urol Ann* 2019;11(3):334–7. doi:10.4103/UA.UA\_125\_18.
- [2] Fernández-Pérez GC, Tardáguila FM, Velasco M, Rivas C, Santos JD, Cambroner J, et al. Radiologic findings of segmental testicular infarction. *AJR Am J Roentgenol* 2005;184:1587–93. doi:10.2214/ajr.184.5.01841587.
- [3] Gianfrilli D, Isidori AM, Lenzi A. Segmental testicular ischaemia: presentation, management and follow-up. *Int J Androl* 2009;32(5):524–31. doi:10.1111/j.1365-2605.2008.00891.x.
- [4] Bak-Ipsen CB, Degn S, Blichert-Refsgaard LS, Nielsen TK, List H, Graumann O. Segmental testicular infarction - Is conservative management feasible? *Ultrasound Int Open* 2020;6(2):E50–2. doi:10.1055/a-1270-7795.