

## Endoscopic Balloon Dilatation of Esophageal Strictures in 9 Horses

J.S.W. Prutton, S.L. Marks, and M. Aleman

**Background:** Medical treatment of esophageal strictures in horses is limited and the use of balloon dilatation is described in few cases. Long-term follow up after balloon dilatation and the use of intralesional corticosteroids has not been evaluated.

**Objectives:** To describe the use of endoscopic guided, esophageal balloon dilatation in horses for cervical and thoracic esophageal strictures and administration of intralesional corticosteroids at the time of dilatation.

**Animals:** Nine horses from the hospital population with benign esophageal strictures.

**Methods:** Retrospective study: Medical records were reviewed from horses presented to the William R. Pritchard, Veterinary Medical Teaching Hospital at UC Davis from 2002 to 2013. Records were searched using the key words: equine, horse, balloon dilatation, bougienage, and esophageal stricture.

**Results:** Nine horses with esophageal strictures were treated with esophageal balloon dilatation. Five horses survived (survival at writing ranged from 2 to 11 years after discharge) and all nonsurvivors were <1 year of age and presented with concurrent problems or developed complications including megaesophagus, unresolved esophageal obstruction requiring esophagostomy, or severe aspiration pneumonia. Four horses were treated with intralesional corticosteroids with no adverse effects noted in the survivors (n = 3). Four horses available for long-term follow up were alive at 2, 5, 6, and 11 years after presentation and 3 of these horses were being fed a hay-based diet.

**Conclusions:** Resolution of esophageal strictures in the horse can be performed successfully, safely, and under standing sedation using balloon dilatation. Intralesional corticosteroids might reduce the incidence of recurrent strictures.

**Key words:** Bougienage; Choke; Esophagus; Horse.

Esophageal strictures in horses can occur after esophageal obstruction, nasogastric intubation, external trauma, congenital defects, or as a complication of esophageal surgery.<sup>1–3</sup> Esophageal impaction is often cited as the cause of strictures in horses<sup>4</sup> and the esophageal damage is dependent on the duration and the material present in the obstruction. Prolonged esophageal impaction can cause pressure necrosis with concurrent erosions or ulcerations of the esophageal mucosa, and/or muscularis, leading to esophageal fibrosis.<sup>2</sup> Esophageal strictures occur when fibrosis is associated with thickening of the esophageal wall. The strictures can be classified into 3 types based on the esophageal wall layers affected: type I lesions involve the adventitia and tunica muscularis; type II lesions involve only the mucosa and submucosa; and type III lesions involve all 4 layers of the esophageal wall.<sup>2,5</sup>

Surgical treatment of esophageal strictures in horses is limited because of the high rate of complications.<sup>1,2,6</sup> Balloon dilatation and bougienage offer alternative treatments for strictures and have shown good results in small animals<sup>7–10</sup> as well as in a small number of horses.<sup>11–13</sup> Complications of esophageal dilatation include bleeding, mucosal tearing, perforation, diverticulum formation, infection, aspiration pneumonia, and stricture recurrence.<sup>14</sup> Recurrence has been attributed to ongoing inflammatory processes and collagen formation.<sup>14</sup> The use of intralesional corticosteroids has been advocated as a treatment for recurrent strictures in humans to minimize stricture reformation;<sup>15</sup> however, corticosteroid administration carries a possible risk of laminitis in horses.<sup>16</sup>

The aim of this study was to describe the use of endoscopic balloon dilatation for cervical and thoracic esophageal strictures and report long-term outcome in 9 horses. Furthermore, the use of intralesional corticosteroid administration at the time of dilatation was also described.

### Materials and Methods

Medical records from horses presented to The William R. Pritchard Veterinary Medical Teaching Hospital at UC Davis from 2002 to 2013 were retrospectively reviewed. Records were searched for the key words: equine, horse, balloon dilatation, bougienage, and esophageal stricture. Cases were eligible for inclusion in this study if an esophageal stricture was confirmed during clinical examination and it was treated with balloon dilatation with, or without, intralesional corticosteroids. Descriptive data are presented as mean, median, and range unless otherwise stipulated.

Nine cases were retrieved and the following information (when recorded) was obtained from each medical record: signalment, clinical signs and their duration, diet before presentation, dental history, suspected cause of stricture, physical examination and clinical laboratory findings, diagnostic modalities used, number, size and location of strictures, mucosal damage before and after dilatation, balloon size utilized, use of intralesional steroid ther-

From The William R. Pritchard Veterinary Medical Teaching Hospital, (Prutton); and the Department of Medicine and Epidemiology, School of Veterinary Medicine, University of California, Davis, CA (Marks, Aleman).

This work was performed at The William R. Pritchard Veterinary Medical Teaching Hospital, University of California, Davis, CA 95616.

Corresponding author: Dr J.S.W. Prutton, The William R. Pritchard Veterinary Medical Teaching Hospital, School of Veterinary Medicine, University of California, One Shields Avenue, Davis CA 95616; e-mail: j\_prutton@hotmail.com.

Submitted February 22, 2015; Revised April 17, 2015; Accepted May 14, 2015.

Copyright © 2015 The Authors. Journal of Veterinary Internal Medicine published by Wiley Periodicals, Inc. on behalf of the American College of Veterinary Internal Medicine.

This is an open access article under the terms of the Creative Commons Attribution-NonCommercial License, which permits use, distribution and reproduction in any medium, provided the original work is properly cited and is not used for commercial purposes.

DOI: 10.1111/jvim.13572

apy, postdilatation treatment including feeding, clinical response, and follow up. The diameter of the stricture (when noted) was estimated based on the size of the endoscope used. The location, and in some cases the length, of the stricture was measured from the nares to the orad border of the stricture.

## Results

### *Case Signalment and Clinical Findings*

The 9 cases comprised 1 gelding, 3 stallions, 2 colts, and 3 mares. Breeds included: American Miniature Horse (n = 2), Quarter Horse (n = 2), Thoroughbred (n = 1), Pony of the Americas (n = 1), Shetland Pony (n = 1), Gypsy Cobb (n = 1), and Friesian (n = 1). Ages ranged from 2 days to 28 years (mean 6.6 years, median 1 year).

Two cases had intermittent esophageal obstruction of 1 week and 5 months duration, respectively. Both cases had spontaneous resolution of their episodes until referred for persistent obstruction of approximately 24 hours. The acute duration of esophageal obstruction was known in 6/7 of the remaining horses and ranged from 1 hour to 3 days (mean 33.6 hours, median 24 hours). The total number of esophageal obstruction episodes ranged from a single episode in 5 horses, 1–5 episodes in 1 horse, 5–10 episodes in 1 horse and >20 episodes in 2 horses.

On presentation all horses had nasal discharge of green, mucopurulent material, or feed material. Abnormal physical examination findings included pyrexia in 2/9 horses of 102.8 and 101.8°F (mean 100.5°F, median 100.1°F), tachycardia in 8/9 horses (mean 56 bpm, median 52 bpm), and tachypnea in 5/9 horses (mean 30 bpm, median 24 bpm). Eight horses had abnormal respiratory sounds on auscultation including crackles and areas of undetectable breath sounds. Dental records were recorded for only 2 horses (both 24 years); one had severe wave mouth and the other was reported to have a normal dental evaluation 4 years previously. Other physical examination findings were within normal limits.

The diet before presentation varied dramatically and included grass and alfalfa hay (n = 4), milk with access to mare's feed (n = 4), and a complete pelleted feed (n = 1).

### *Laboratory Findings*

Complete blood cell counts and serum biochemistry panels were performed on all cases upon admission. The hematocrit was within normal limits for all horses with the exception of 2 horses that had microcytic, normochromic anemias of 25% (MCV 26.6 fL and MCHC 40.7 g/dL) and 27% (MCV 34 fL and MCHC 39.2 g/dL), respectively (MCV reference range 37–53 fL; MCHC reference range 36–41 g/dL). A neutrophilia was seen in 3 horses (11,934–18,181/ $\mu$ L; reference range 5,000–11,600/ $\mu$ L) all of which did not survive, while band neutrophils (122–622/ $\mu$ L; reference range: rare) were detected in 4 horses of which 1 did not survive. Slight toxicity of both the bands and the mature neutrophils was noted in the 3 surviving horses. Serum creatinine concentration was increased in 1 horse (2.6 mg/dL; reference range 0.9–2.0 mg/dL) and BUN concen-

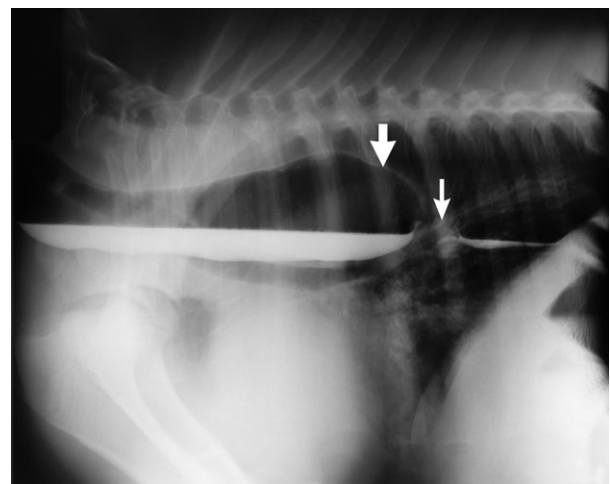
tration was increased in 2 horses (64 and 95 mg/dL; reference range 25–53 mg/dL) with the latter of the 2 horses also having an elevated creatinine. The horse with the elevated creatinine and BUN had shown clinical signs of esophageal obstruction for 72 hours, while the other horse had clinical signs for 24 hours. Hyperglycemia was documented in 3 horses (180–329 mg/dL; reference range 54–108 mg/dL); creatine kinase activity was increased in 4 horses (357–902 IU/L; reference range 119–287 IU/L); and serum triglyceride concentration was elevated in 4 horses (45–239 mmol/L; reference range 0–44 mmol/L). The hyperglycemia was monitored in all horses and resolved after resolution of the esophageal obstruction and fluid therapy.

### *Diagnostic Procedures*

Diagnostics procedures that confirmed the presence of a stricture included esophagoscopy (n = 9), esophagram (Fig 1; n = 2), video fluoroscopy with barium (n = 1), and computed tomography (n = 1). Pneumonia was diagnosed via auscultation (n = 8), survey radiographs of the thorax (n = 5), and ultrasonography of the thorax (n = 2). Cervical survey radiographs (n = 2) and cervical ultrasonography (n = 1) was also performed to further characterize the esophageal stricture.

Esophageal strictures were most frequently associated with an obstruction (n = 6). Other etiologies included trauma (n = 1), intramural cyst (n = 1), and unknown (n = 1). Abnormalities noted during sedated endoscopic examination included decreased esophageal motility associated with megaesophagus orad to the stricture (n = 1), megaesophagus caudal to the stricture (n = 1), and a dorsal pharyngeal recess rupture into the guttural pouch attributable to attempted naso-gastric intubation by the owner (n = 1).

Esophageal strictures were measured from the external nares to the orad border of the stricture, and were located at 35–70 cm (mean 46 cm, median 41 cm)



**Fig 1.** Esophagram of a 2-month filly with a thoracic esophageal stricture (small arrow) and megaesophagus (large arrow) orad to the stricture performed under standing sedation. Barium pooling can be noted orad and caudal to the stricture site.

within the cervical region in 8 horses, whereas one stricture in 1 horse was located at 90 cm in the thoracic region. Three horses had multiple strictures (exact number not recorded), whereas the remainder of the horses had a single stricture as diagnosed by esophagoscopy. Stricture lengths were recorded in 5 horses ranging from 1 to 10 cm (mean 4.4 cm, median 5 cm) and the length was not recorded for the remaining 4 horses. Six horses were noted to have circumferential mucosal sloughing and ulceration at the site of the stricture when first diagnosed and all 6 of these horses had presented with esophageal obstruction.

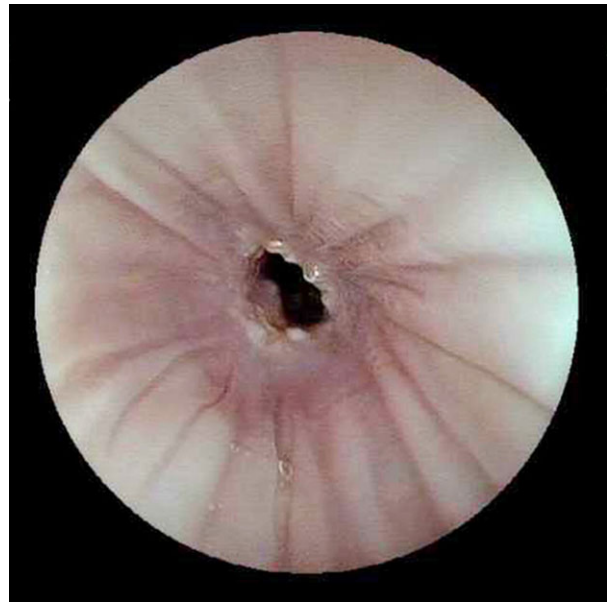
### Treatment and Outcome

Seven horses were administered isotonic fluids IV for rehydration and maintenance of fluid requirements. During balloon dilatation all horses were administered nonsteroidal anti-inflammatories (flunixin meglumine<sup>a</sup>) at 1.1 mg/kg, IV, q 12 h (n = 9) and phenylbutazone<sup>b</sup> at 2.2 mg/kg, PO, q 12 h (n = 1) with 1 horse receiving both drugs. Multimodal analgesia combined with NSAIDs was used in 6 horses and included 20 mL of 2% lidocaine hydrochloride<sup>c</sup> (n = 1) via the endoscope at the stricture site, butylscopolamine<sup>d</sup> 0.1–0.3 mg/kg IV once (n = 3), butylscopolamine<sup>d</sup> and butorphanol tartrate<sup>e</sup> 0.04 mg/kg IV once (n = 1), or butylscopolamine<sup>d</sup> and morphine<sup>f</sup> 0.1 mg/kg IM once (n = 1).

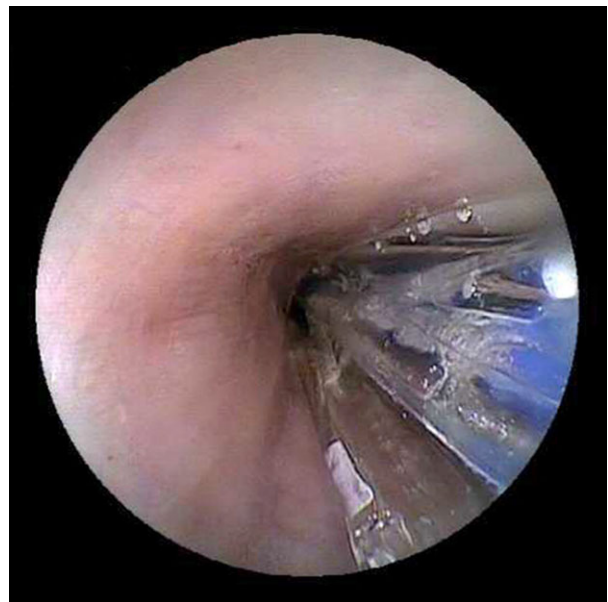
All horses received antibiotics including aminoglycosides (gentamicin<sup>g</sup> 6.6 mg/kg IV q 24 h [n = 4] or amikacin<sup>h</sup> 20 mg/kg IV q 24 h [n = 2]), penicillins (procaine penicillin G<sup>i</sup> 22,000 mg/kg IM q 12 h [n = 2] or ampicillin<sup>j</sup> 20 mg/kg IV q 8 h [n = 1]), ceftiofur sodium<sup>k</sup> 2.2 mg/kg IV q 12 h (n = 5), metronidazole<sup>l</sup> 20 mg/kg PO q 8 h (n = 2), trimethoprim sulfonamide<sup>m</sup> 30 mg/kg PO q 12 h (n = 1), or doxycycline<sup>n</sup> 10 mg/kg PO q 12 h (n = 1).

Gastroprotectants were used in 6 horses including omeprazole<sup>o</sup> 4 mg/kg PO q 24 h (n = 1), sucralfate<sup>p</sup> tablets reconstituted with water 20–40 mg/kg PO q 6–8 h (n = 2), omeprazole<sup>o</sup> and sucralfate<sup>p</sup> tablets (n = 2), or omeprazole<sup>o</sup>, sucralfate<sup>p</sup> tablets, and ranitidine<sup>q</sup> at 6.6 mg/kg PO q 8 h (n = 1).

Esophagoscopy of the entire esophagus was performed during initial examination in all horses after resolution of esophageal obstructions when present. After localization of the stricture (Fig 2), esophageal dilatation was performed using a controlled radial expansion wire-guided balloon catheter.<sup>r</sup> The balloon catheters used ranged in diameter from 6 to 20 mm and were 3–8 cm long. The diameter of the balloon dilator initially selected was based on the measured diameter of the stricture before dilatation. Specifically, the authors selected a balloon dilator with a maximal diameter of 25–50% greater than the diameter of the stricture and used varying filling pressures to incrementally reach the desired stricture diameter, as set out by manufacturer's instructions. A second balloon dilator with a slightly greater outer diameter than the first balloon was then introduced into the stricture using the same guidelines highlighted above. Each of the balloon dilators facili-



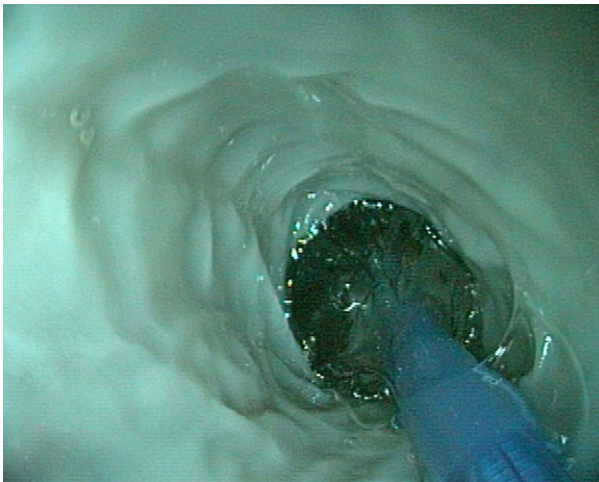
**Fig 2.** Severe esophageal stricture in a 24-year-old miniature horse gelding with a 0.8 cm diameter after esophageal impaction.



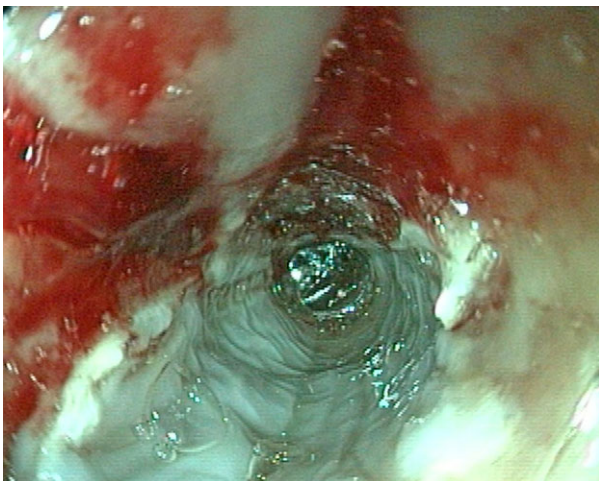
**Fig 3.** Location of balloon dilator before inflation for treatment of esophageal strictures under endoscopic guidance.

tated expansion of the esophageal stricture up to 3 mm beyond the balloons smallest diameter. The outer diameter of subsequent larger diameter balloon dilators overlapped with the outer diameter of previously used balloon dilators allowing for a gradual and progressive expansion of the stricture. For example, the smallest balloon dilator used had a range of inflated outer diameters of 6–8 mm, and subsequent balloon dilators had inflated outer diameters of 8–10 mm, 10–12 mm, 12–15 mm, 15–18 mm, and finally 18–20 mm. Accurate insufflation and pressure maintenance of the balloon with water was performed using a manometric pressure

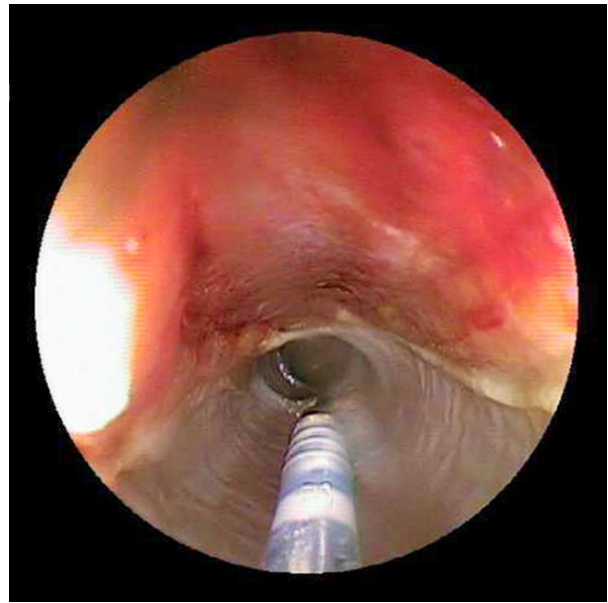
gauge.<sup>5</sup> Correct placement of the collapsed balloon was facilitated by endoscopic guidance (Fig 3). The balloon was positioned so that half of the balloon was passed distal to the stricture and the remaining half of the balloon was positioned proximal to the stricture (Fig 4). During each dilatation attempt, the balloon pressure was maintained for 90 seconds and the mucosa was closely observed for small tears and hemorrhage after deflation of the balloon (Fig 5). The goal of each dilatation attempt was to sequentially dilate the stricture in 1–2 mm increments without causing excessive tearing or bleeding. Triamcinolone or methylprednisolone were injected transendoscopically using a Wang transbronchial aspiration needle<sup>†</sup> into the submucosa using a 4-quadrant approach, located at positions 12, 3, 6, and 9 on a clock face (1.5 mg/quadrant, total 6 mg), at the fourth dilatation attempt (Fig 6). Confirmation of deposition of corticosteroids within the submucosa was by visualization of a bleb within the esophageal wall. Cor-



**Fig 4.** Location of balloon dilator during treatment for esophageal stricture under endoscopic guidance.



**Fig 5.** Postballoon dilatation of an esophageal stricture showing mucosal hemorrhage and erythema.



**Fig 6.** Insertion of a Wang needle into the esophageal submucosa under endoscopic guidance for the administration of corticosteroids after dilatation of an esophageal stricture.

ticosteroids were used in 4 cases and 3 of the animals survived. Euthanasia in the nonsurvivor was associated with dehiscence and secondary infection after esophagostomy to relieve the obstruction before balloon dilatation. Corticosteroids used included intralesional triamcinolone acetonide<sup>u</sup> 10 mg/mL (total dose: 6 mg or 18 mg [n = 2]) or methylprednisolone acetate<sup>v</sup> 40 mg/mL (total dose: 40 or 200 mg [n = 2]), and systemic dexamethasone SP<sup>w</sup> (4 mg/mL) 0.1 mg/kg IV q 24 h (n = 1). One horse received both intralesional methylprednisolone acetate and systemic dexamethasone SP. Intralesional triamcinolone acetonide was given once in 1 horse and 3 times in the other, whereas methylprednisolone was given once in both horses. In all instances some mucosal damage with a small amount of hemorrhage was noted.

Balloon dilatation was performed in all horses and the total number of dilatation procedures ranged from 1 to 6 (mean 3, median 2). During each procedure up to 4 dilations of the balloon were performed dependent on when mucosal damage was seen. The interval between repeated dilatation procedures ranged from 1 to 18 days (mean 5.5 days, median: 4 days). General inhalation anesthesia was undertaken in 2 of the cases because of the temperament of the horses and the remainder were performed under standing sedation.

Owners of all horses that survived were recommended to initially feed their horse a diet of moist to soupy pellets and dependent on progress move to dry pellets or short fiber grass hay.

### *Complications*

Eight horses had signs of aspiration pneumonia based on auscultation (n = 8), thoracic radiographs (n = 5),

and ultrasound ( $n = 2$ ). Esophagostomy was performed to remove an intramural cyst ( $n = 1$ ; survivor) or for unresolved esophageal obstruction ( $n = 1$ ; nonsurvivor). Esophageal ulceration was seen in 8 horses (Fig 7) and gastric ulceration was noted in 1 horse.

### Survival

Four horses, all less than 1 year of age, were euthanized because of concurrent disorders including megaesophagus ( $n = 2$ ), aspiration pneumonia ( $n = 1$ ), or complications after esophagostomy because of unresolved esophageal obstruction.

### Long-term follow up

Owners of 4 of the 5 surviving horses (1 lost to follow up) were contacted. Three horses had returned to a diet of grass hay or alfalfa with supplemental pellets and 1 horse was solely on pellets. At the time of writing, the 4 horses were alive for 2, 5, 6, and 11 years from presentation and were being used for various purposes: at pasture ( $n = 2$ ), breeding stallion ( $n = 1$ ), or breeding mare ( $n = 1$ ).

### Discussion

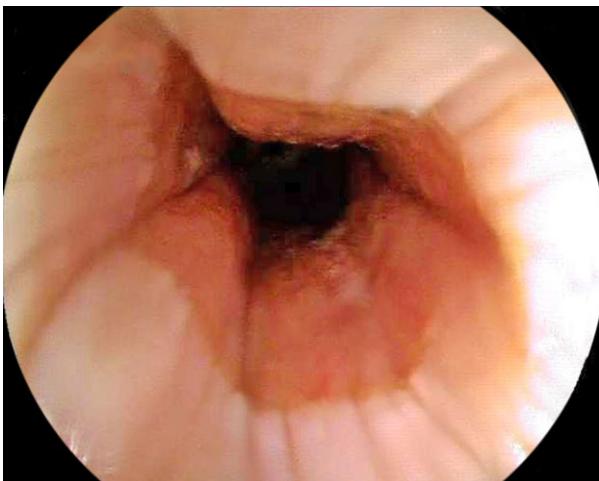
Balloon dilatation for the resolution of esophageal strictures in horses can be successfully performed under standing sedation or general anesthesia as demonstrated in this study. Long-term (up to 11 years) follow-up revealed that horses could return to a normal diet in some cases. Intralesional corticosteroids were used in 3 cases that survived. All nonsurvivors were horses under 1 year of age and presented with, or developed, concurrent problems including megaesophagus, unresolved esophageal obstruction requiring esophagostomy, or severe aspiration pneumonia.

Four of the cases were pony breeds, whereas the rest were horses of differing breeds. Although this case series

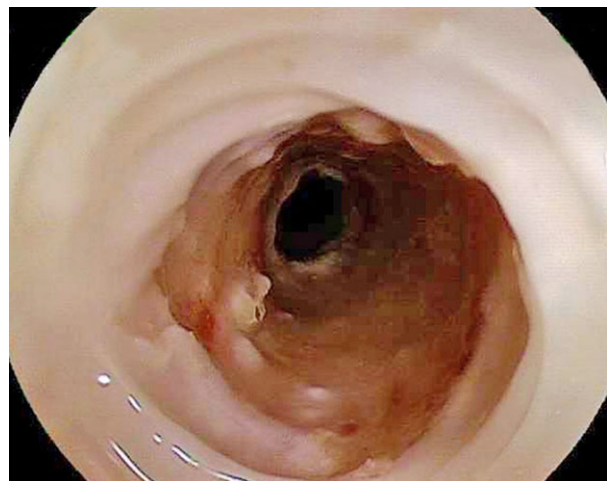represents a relatively small study group, there was no obvious breed predisposition. One horse was presented with a severe wave mouth that could have led to the esophageal obstruction as a result of lack of proper mastication. No other predisposing factors were identified in this case series.

Balloon dilatation has been reported as an effective method for treating esophageal strictures in horses in previous publications, one of which was a report of 2 cases<sup>12</sup> and 2 of which were individual case reports.<sup>11,13</sup> None of the larger studies addressed the use of balloon dilatation as a therapeutic modality for strictures.<sup>17-19</sup> Assessment of the strictures in this case series was often performed using endoscopy alone, as is frequently the case in humans.<sup>9</sup> Previous studies have stated the need for contrast radiographic evaluation with or without video fluoroscopy to assess stricture size<sup>12</sup>; however, this procedure is not always needed and carries the additional risk of aspiration pneumonia.

The technique of balloon dilatation of esophageal strictures is subjective in veterinary medicine, with many variables not defined by controlled studies. These include the sequence of dilatation, the optimal final dilatation diameter, use of corticosteroids, postdilatation drugs, postdilatation feeding regime, the elective use of percutaneous endoscopic gastrostomy tubes in small animals, and repeat elective dilatations (and at what interval). We used the same dilatation protocol as that used by our small animal internists and gastroenterologist (SLM) who have extensive experience in balloon dilatation of esophageal strictures in dogs and cats and as documented in the human literature.<sup>20</sup> The balloon dilators that we used facilitated expansion of the esophageal stricture up to 3 mm depending upon the filling pressure for each balloon dilator, and we selected an initial balloon dilator diameter that was 25-50% larger than the estimated diameter of the stricture for safety reasons (minimize likelihood of perforation) and because this allowed a gradual and incremental increase in the diameter of the stricture.



**Fig 7.** Severe circumferential mucosal sloughing after resolution of esophageal impaction.



**Fig 8.** Resolving esophageal stricture after balloon dilatation 2 days before re-examination.

The sequence of subsequent larger dilations was then determined by the degree of mucosal tearing at each procedure and subsequent healing before the next procedure (Fig 8).

Intralesional steroid injections have been utilized in humans and shown to significantly reduce the rate of stricture recurrence with only 18% of steroid treated humans requiring further treatment compared to 60% of sham treated humans.<sup>15</sup> In this study, triamcinolone or methylprednisolone was injected into each quadrant of the esophagus before, during, or after balloon dilatation. The variable dose used was clinician based and 6 mg of triamcinolone has been proposed by the authors as a safe amount for use in strictures based on studies demonstrating the use of up to 80 mg intramuscularly as safe in horses.<sup>21</sup> Intralesional corticosteroids injections were repeated in 1 horse, although it was not possible to determine whether the repeated administrations affected the outcome of the horse in light of the small number of horses injected. Although none of the 4 horses in this case series developed laminitis after corticosteroid administration; the risk of laminitis associated with these drugs must be discussed with the owner before administration. However, the risk of laminitis was reduced based on the low doses of steroids administered.

Antibiotic treatment in the case series varied among clinicians and was often prescribed based on personal preference. All antibiotic treatment was aimed at broad-spectrum coverage to reduce the risk of a mixed growth aspiration pneumonia. Seven horses received either penicillin-based drugs or cephalosporin combined with an aminoglycoside and 2 of the horses additionally received metronidazole. Three horses were switched to oral antibiotics to expedite discharge from the VMTH, whereas 2 horses were switched to other antibiotics (cephalosporin or a combination of penicillin and trimethoprim/sulfamethoxazole) because of a lack of resolution of clinical signs.

Complications of esophageal obstruction and strictures are well documented in horses. Aspiration pneumonia can affect 72% of horses, whereas other complications include esophageal mucosal ulceration, laryngeal hemiplegia, recurrent esophageal obstruction, laminitis secondary to steroid administration, megaesophagus, and death.<sup>17,22</sup> Previously described risk factors for complications associated with esophageal obstructions include age, general anesthesia, pony breeds, and intact males.<sup>4,18</sup> In a study of 109 equine cases with esophageal obstruction, 8 horses had strictures, 4 of which were foals with an unknown etiology for their strictures.<sup>4</sup> A survival rate of 33% in horses with strictures has been documented and those with chronic strictures were less likely to survive although that study did not address the use of balloon dilatation.<sup>17</sup> Those horses that received medical treatment (antibiotics, corticosteroids, nonsteroidal anti-inflammatories, and diet changes) had a poor survival rate, due mostly to recurrent esophageal obstruction and secondary aspiration pneumonia.<sup>17</sup> Congenital strictures are infrequently described in the equine literature and the prevalence is unknown.<sup>11,23</sup> In the current study only one

foal was noted to have an intramural cyst presumed to be a congenital defect.

Limitations of this study included its retrospective nature that precluded having identical examinations and treatments performed in every case. In addition, the small number of cases evaluated made statistical comparisons unfeasible.

As demonstrated in this study, endoscopic balloon dilatation of esophageal strictures in horses frequently has a successful outcome, and can be done safely under standing sedation. Long-term follow up indicates that a percentage of survivors can return to a normal hay diet. The use of intralesional steroids is well documented in the human field and was utilized in 3 of the 4 cases highlighted with no recurrence of strictures noted. The minimally invasive procedure offers an alternative to surgery for esophageal strictures and can have a good outcome in adult horses, ponies, and foals. Case selection is important because concurrent esophageal disease (megaesophagus, esophageal perforation, and aspiration pneumonia) adversely affects the prognosis.

---

## Footnotes

- <sup>a</sup> Flunixin meglumine, Merck Animal Health, Intervet Inc, Summit, NJ
- <sup>b</sup> Equi-Phar Phenylbutazone, Vedco Inc, St Joseph, MO
- <sup>c</sup> Lidocaine hydrochloride 2%, VetOne, Boise, ID
- <sup>d</sup> Buscopan, Boehringer Ingelheim, St Joseph, MO
- <sup>e</sup> Torbugesic, Zoetis, Fort Dodge, IA
- <sup>f</sup> Morphine, West-Ward, Eatontown, NJ
- <sup>g</sup> Gentamicin sulfate, VetOne, Boise, ID
- <sup>h</sup> Amikacin, TEVA, Sellersville, PA
- <sup>i</sup> PenOne Pro, VetOne, Boise, ID
- <sup>j</sup> Ampicillin, Auromedics, Dayton, NJ
- <sup>k</sup> Naxcel, Zoetis, Kalamazoo, MI
- <sup>l</sup> Metronidazole, TEVA, Sellersville, PA
- <sup>m</sup> Trimethoprim and sulfamethoxazole, Amneal Pharmaceuticals, Hauppauge, NY
- <sup>n</sup> Doxycycline Hyclate, TEVA, Sellersville, PA
- <sup>o</sup> Gastrogard, Merial Limited, Duluth, GA
- <sup>p</sup> Sucralfate, Actavis Inc, Parsippany, NJ
- <sup>q</sup> Ranitidine, Amneal Pharmaceuticals, Hauppauge, NY
- <sup>r</sup> CRE wire-guided balloon dilator, Boston Scientific, Marlborough, MA
- <sup>s</sup> Alliance II 60 mL Syringe/Gauge Assembly, Boston Scientific, Marlborough, MA
- <sup>t</sup> Wang Transbronchial Aspiration Needle, ConMed, Utica, NY
- <sup>u</sup> Kenalog-10, Bristol-Myers Squibb, Princeton, NJ
- <sup>v</sup> Methylprednisolone, Pfizer, New York, NY
- <sup>w</sup> Dexamethasone-SP, VetOne, Meridian, ID

---

## Acknowledgments

No financial support was provided for this study.

*Conflict of Interest Declaration:* Authors disclose no conflict of interest.

*Off-label Antimicrobial Declaration:* Authors declare no off-label use of antimicrobials.

## References

1. Freeman D. Surgery for obstruction of the equine oesophagus and trachea. *Equine Vet Educ* 2005;17:135–141.
2. Borchers-Collyer P, Wong D, Sponseller B, et al. Esophageal strictures. *Comp Equine Edition* 2007;3:144–156.
3. Hillyer M. Management of oesophageal obstruction ('choke') in horses. *In Practice* 1995;17:450–457.
4. Chiavaccini L, Hassel DM. Clinical features and prognostic variables in 109 horses with esophageal obstruction (1992–2009). *J Vet Intern Med* 2010;24:1147–1152.
5. Waguespack RW, Bolt DM, Hubert JD. Esophageal strictures and diverticula. *Comp Equine Edition* 2007;4:194–207.
6. Knottenbelt D, Harrison L, Peacock P. Conservative treatment of oesophageal stricture in five foals. *Vet Rec* 1992;131:27–30.
7. Bissett SA, Davis J, Subler K, et al. Risk factors and outcome of bougienage for treatment of benign esophageal strictures in dogs and cats: 28 cases (1995–2004). *J Am Vet Med Assoc* 2009;235:844–850.
8. Leib MS, Dinnel H, Ward DL, et al. Endoscopic balloon dilation of benign esophageal strictures in dogs and cats. *J Vet Intern Med* 2001;15:547–552.
9. Riley SA, Attwood SEA. Guidelines on the use of oesophageal dilatation in clinical practice. *Gut* 2004;53:1–6.
10. Zoran D. Esophageal foreign bodies and strictures. *Stand Care Emerg Crit Care Med* 2005;7:1–6.
11. Berlin D, Shaabon K, Peery D. Congenital oesophageal stricture in an Arabian filly treated by balloon dilation. *Equine Vet Educ* 2014;27:230–236. doi:10.1111/eve.12229.
12. Reichelt U, Hamann J, Lischer C. Balloon dilation of oesophageal strictures in two horses. *Equine Vet Educ* 2012;24:379–384.
13. Tillotson K, Traub-Dargatz JL, Twedt D. Balloon dilation of an oesophageal stricture in a one-month-old Appaloosa colt. *Equine Vet Educ* 2003;15:67–71.
14. Fraune C, Gaschen F, Ryan K. Intralesional corticosteroid injection in addition to endoscopic balloon dilation in a dog with benign oesophageal strictures. *J Small Anim Pract* 2009;50:550–553.
15. Ramage JI Jr, Rumalla A, Baron TH, et al. A prospective, randomized, double-blind, placebo-controlled trial of endoscopic steroid injection therapy for recalcitrant esophageal peptic strictures. *Am J Gastroenterol* 2005;100:2419–2425.
16. Bailey SR. Corticosteroid-associated laminitis. *Vet Clin North Am Equine Pract* 2010;26:277–285.
17. Craig DR, Shivy DR, Pankowski RL, et al. Esophageal Disorders in 61 Horses: Results of Nonsurgical and Surgical Management. *Vet Surg* 1990;18:432–438.
18. Duncanson G. Equine oesophageal obstruction: A long term study of 60 cases. *Equine Vet Educ* 2006;18:262–265.
19. Feige K, Schwarzwald C, Fürst A, et al. Esophageal obstruction in horses: A retrospective study of 34 cases. *Can Vet J* 2000;41:207.
20. Taylor JR, Elta GH. Benign strictures. In: Ginsberg GG, Kochman ML, Norton ID, Gostout CJ, eds. *Clinical Gastrointestinal Endoscopy*, 2nd ed. Missouri: Elsevier Health Sciences; 2011:205–212.
21. McCluskey MJ, Kavenagh PB. Clinical use of triamcinolone acetonide in the horse (205 cases) and the incidence of glucocorticoid-induced laminitis associated with its use. *Equine Vet Educ* 2004;16:86–89.
22. Broekman LE, Kuiper D. Megaesophagus in the horse. A short review of the literature and 18 own cases. *Vet Q* 2002;24:199–202.
23. Bezdekova B, Skoric M, Pekarkova M. Congenital triple oesophageal stricture and megaesophagus in a neonatal colt. *Equine Vet Educ* 2014;27:277–229. doi:10.1111/eve.12180.