

# Dynamics in myocardial deformation as an indirect marker of myocardial involvement in acute myocarditis due to HIV infection: a case report

Stephan Stöbe <sup>1\*</sup>, Bhupendar Tayal <sup>2</sup>, Adrienn Tünnemann-Tarr<sup>1</sup>, and Andreas Hagendorff<sup>1</sup>

<sup>1</sup>Department of Cardiology, University Hospital of Leipzig, Liebigstraße 20, 04103 Leipzig, Germany; and <sup>2</sup>Department of Cardiology, Aalborg University Hospital, Hobrovej 18-22, 9100 Aalborg, Denmark

Received 27 May 2020; first decision 7 July 2020; accepted 24 November 2020

## Background

The diagnosis of acute myocarditis (AM) is often challenging and mainly performed by cardiac magnetic resonance (CMR).

## Case summary

The present case describes echocardiographic findings of a 38-year-old male patient with exertional dyspnoea probably due to myocardial involvement of previously undiagnosed acute human immunodeficiency virus (HIV) infection. Myocardial deformation imaging might be helpful to detect early stages of myocardial dysfunction in patients with AM and/or systemic infectious diseases by documentation of patchy abnormalities of longitudinal, circumferential and rotational left ventricular (LV) deformation.

## Discussion

CMR still represents the gold standard to diagnose AM, which has been confirmed by myocardial oedema and hyperaemia in the present case. However, speckle tracking echocardiography seems to be useful to detect myocardial involvement in HIV infection by dynamic alterations of different components of LV deformation. This was documented by comparing echocardiographic findings at the acute stage of HIV infection to findings at follow-ups during antiviral treatment. The diagnostic option to detect myocardial involvement by deformation imaging in a patient with HIV infection is described for the first time.

## Keywords

Case report • Myocarditis • HIV infection • Echocardiography • Deformation imaging • Layer strain

## Introduction

Myocardial inflammation is the most common cause of human immunodeficiency virus (HIV)-associated cardiovascular diseases. The aetiology seems to be multifactorial and the pathophysiology is still

not completely understood.<sup>1</sup> The majority of patients with HIV infection show left ventricular (LV) systolic dysfunction or HIV-associated cardiomyopathy.<sup>2</sup>

Two-dimensional transthoracic echocardiography (TTE) and myocardial biomarkers are recommended in patients with HIV and

\* Corresponding author. Tel: +49 341 97 12464, Fax: +49 341 97 12659, Email: [stephan.stoebe@medizin.uni-leipzig.de](mailto:stephan.stoebe@medizin.uni-leipzig.de)

Handling Editor: Flavio D'Ascenzi

Peer-reviewers: Rami Riziq Yousef Abumualeq; Marcelo Haertel Miglioranza

Compliance Editor: Abdelrahman Ibrahim Abushouk

Supplementary Material Editor: Ross Thomson

© The Author(s) 2021. Published by Oxford University Press on behalf of the European Society of Cardiology.

This is an Open Access article distributed under the terms of the Creative Commons Attribution Non-Commercial License (<http://creativecommons.org/licenses/by-nc/4.0/>), which permits non-commercial re-use, distribution, and reproduction in any medium, provided the original work is properly cited. For commercial re-use, please contact [journals.permissions@oup.com](mailto:journals.permissions@oup.com)

## Learning points

- In systemic infectious diseases, e.g. human immunodeficiency virus, myocardial involvement can be detected by speckle tracking echocardiography.
- Stress echocardiography should be performed—especially in outpatient care of patients with history of recent infections—after inspection of laboratory results to avoid stress testing in (acute) myocarditis.
- The analysis of left ventricular (LV) circumferential strain and rotation might be superior to conventional echocardiographic parameters and longitudinal strain to detect myocardial involvement.
- The wide availability of deformation imaging highlights the diagnostic importance of echocardiography in patients with (acute) myocarditis.
- The analysis of LV deformation requires an advanced level of skills and expertise.

suspected myocardial involvement. Cardiac magnet resonance (CMR) represents the gold standard to detect myocardial oedema by T2 weighted imaging and/or myocardial injury by delayed enhancement. LV systolic function is often only described by LV ejection fraction (LVEF). In contrast, speckle tracking echocardiography can be used to detect LV dysfunction by myocardial deformation—especially by longitudinal, radial, and circumferential strain as well as LV rotation—more precisely and at earlier stages.

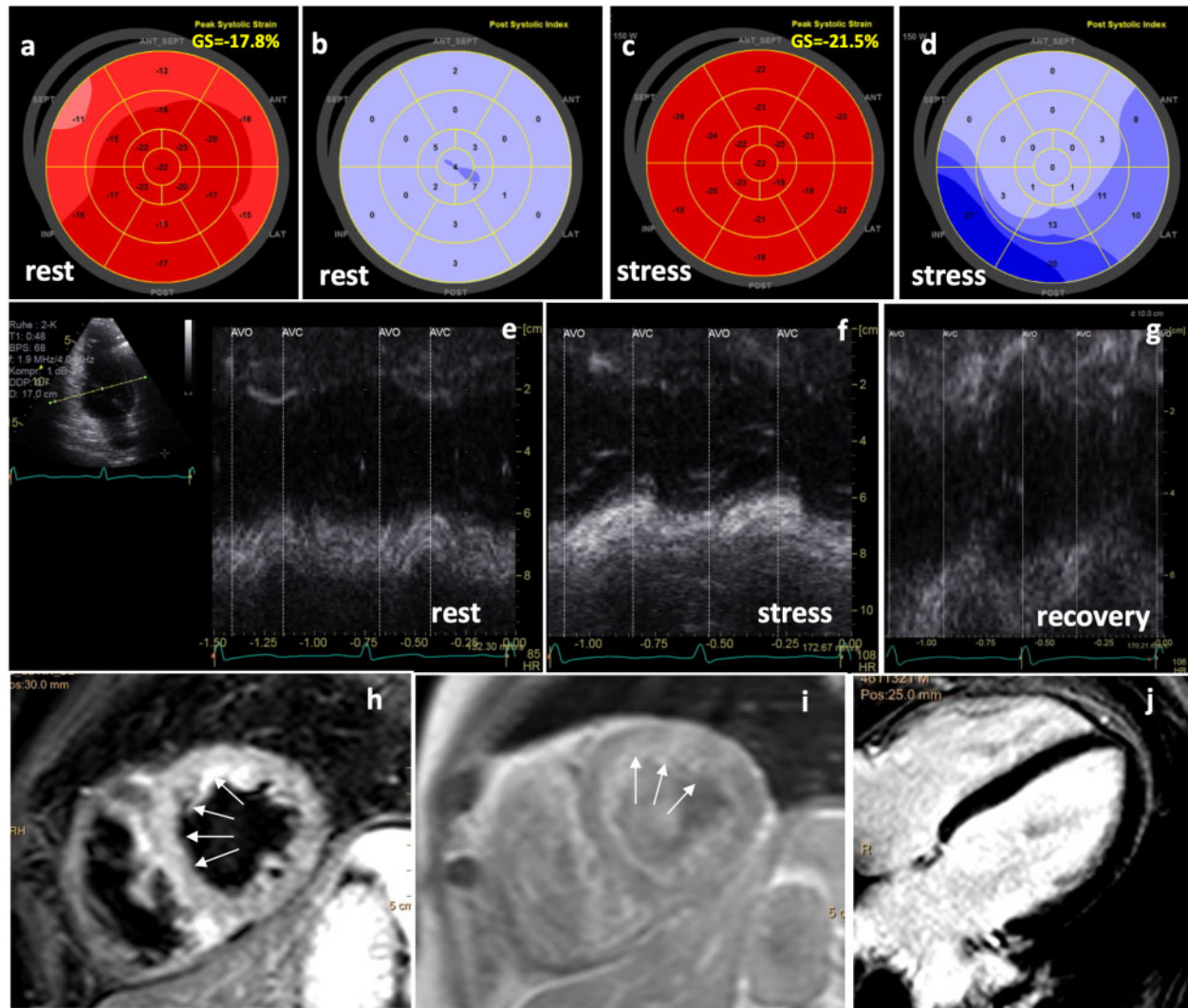
In general, the inflammatory process of patients with acute myocarditis (AM) is often observed in the subepicardial layers.<sup>3–5</sup> Thus,

circumferential strain and LV rotational are predominantly impaired, because the outer subepicardial layers do mainly consist of circumferential fibres.<sup>6</sup> In contrast, longitudinal LV deformation is mainly impaired in patients with ischaemic heart diseases, because the inner subendocardial layers do mainly consist of longitudinal fibres.<sup>7,8</sup>

In patients with systemic retroviral diseases, e.g. HIV, it can be hypothesized that all components of LV deformation will be impaired, because all myocardial layers are involved. This case report focuses on the detection of myocardial involvement by speckle tracking echocardiography in a patient with acute HIV infection.

## Timeline

Stepwise diagnostic map	Diagnostic methods	Results
Admission to hospital at the department of cardiology Day 1	Anamnesis Clinical examination Routine blood sampling Electrocardiogram at rest Transthoracic echocardiography	Suspected coronary artery disease—scheduling for dynamic stress-test (echocardiography). Retrospectively analysis of left ventricular (LV) deformation: <ul style="list-style-type: none"> <li>• reduced basal septal and anterior longitudinal strain and apical post-systolic shortening at rest</li> <li>• abnormal subepicardial basal inferior and posterior circumferential layer strain</li> <li>• abnormal apical rotation</li> <li>• abnormal twist-/untwisting</li> </ul>
Second hospital visit at the department of cardiology Day 2	Stress echocardiography Interpretation of laboratory findings Additional blood sampling for blood serum analysis	No significant signs of ischaemia-induced wall motion abnormalities Thrombocytopenia, leucocytopenia, elevated Troponin-T values
Visits at the department of infectious diseases Days 3–5	Virologic testing Initiation of drug treatment	Confirmation of acute human immunodeficiency virus infection Starting antiviral treatment
Third hospital visit at the department of cardiology Day 7	Cardiac magnetic resonance	Detection of myocardial oedema, unspecific findings of hyperaemia and no late enhancement
Visits at the department of infectious diseases Fourth visit at the department of cardiology Month 6	Monitoring including repetitive blood serum analysis Transthoracic echocardiography (follow-up)	Documentation of effective antiviral treatment Analysis of LV deformation: <ul style="list-style-type: none"> <li>• abnormal longitudinal strain basal septal and anterior with normalization basal inferior;</li> <li>• global radial strain (GRS) was significantly increased;</li> <li>• abnormal circumferential strain apical inferior and posterior as well as basal inferoseptal;</li> <li>• abnormal twist-/untwisting</li> </ul>
Fifth visit at the department of cardiology Month 12	Transthoracic echocardiography (follow-up)	Analysis of LV deformation: <ul style="list-style-type: none"> <li>• normal longitudinal deformation</li> <li>• no relevant changes of GRS;</li> <li>• still slightly abnormal circumferential strain apical inferior and posterior as well as basal inferoseptal;</li> <li>• abnormal twist-/untwisting</li> </ul>



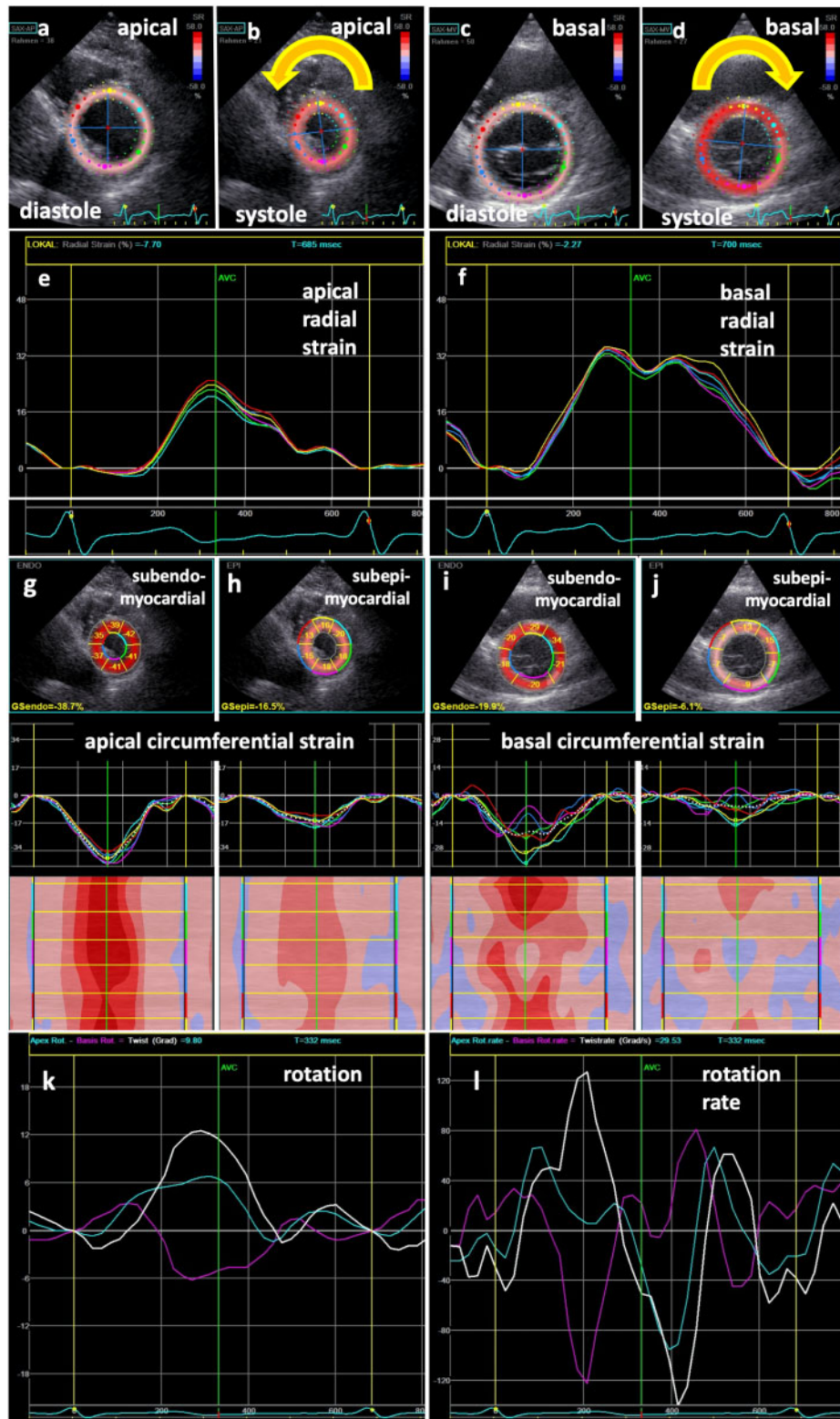
**Figure 1** Echocardiographic findings in acute HIV infection: 2D speckle tracking bull's eye patterns of global longitudinal strain (GLS) (A, C) and post-systolic shortening (B, D) at rest (A, B) and peak stress (C, D) document basal septal hypokinesia at rest as well as slightly increased GLS and abnormal basal inferior and posterior post-systolic shortening at stress. Basal inferior radial post-systolic shortening at stress—illustrated by comparison of anatomical M-modes of the inferior wall at rest (E), 125 Watts (F) and during recovery phase (G)—is shown. Cardiac magnetic resonance findings: ubiquitous oedema by T2-STIR sequences in a mid-short axis view (h)—predominantly in the septal and anterior LV segments (→); focal hyperaemia by patchy early enhancement—predominantly anterior (→) in T1-TFE sequences in a mid-short axis view (i); absence of significant late enhancement in T1-scar sequences in four-chamber view (j).

## Case presentation

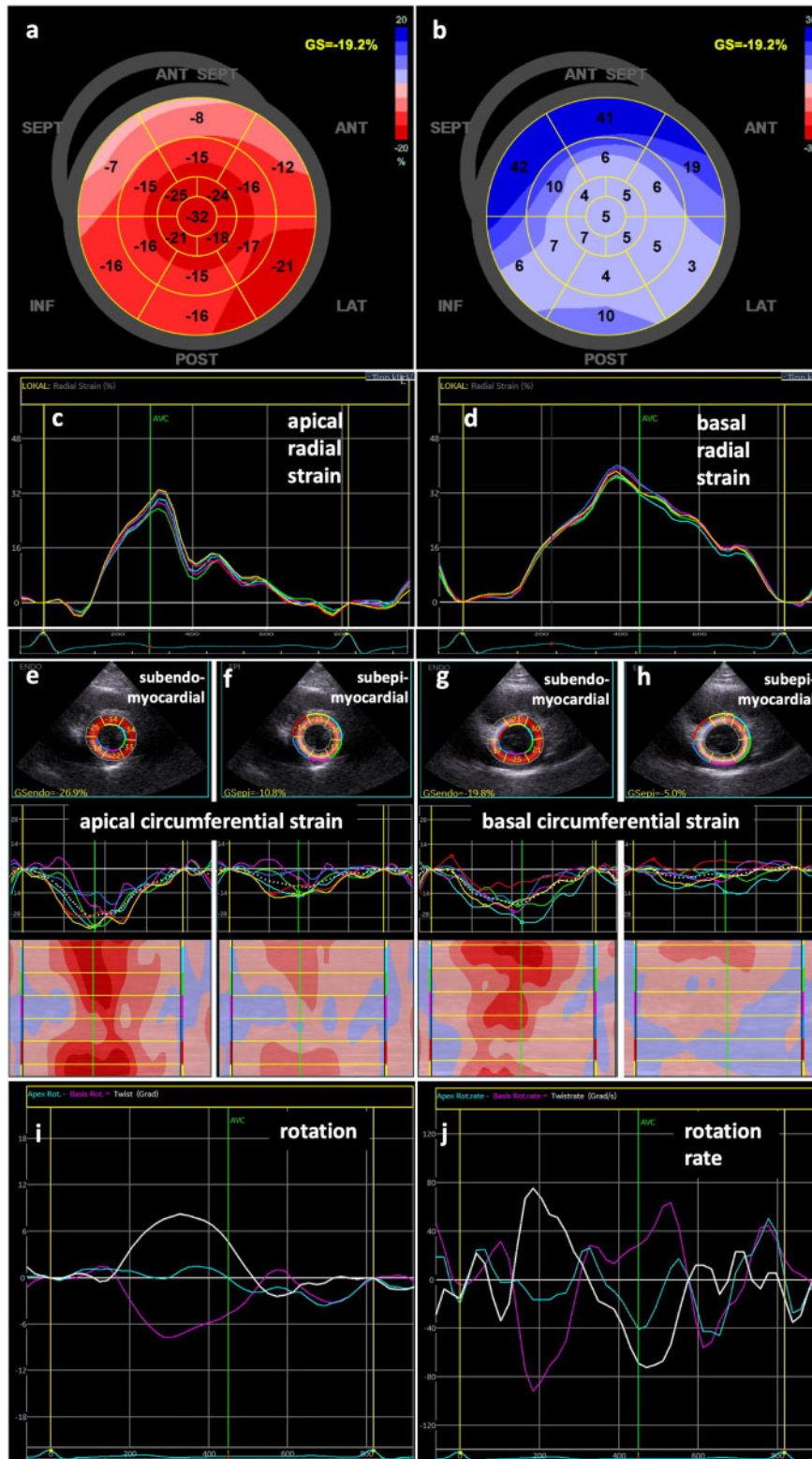
A 38-year-old male patient (blood pressure: 138/78 mmHg, heart rate: 76 b.p.m., temperature: 37.4°C, SpO<sub>2</sub>: 96%) was admitted to hospital with slightly progressive exertional dyspnoea NYHA II with insidious onset of symptoms three weeks ago, consecutive performance dip, and unspecific chest pain with history of dyslipidaemia, hypertension, smoking, and respiratory infection 4 weeks ago. There was no past medical history.

At the first visit, the patient was stable without any complaints at rest. Physical examination, ECG, and chest X-ray showed normal findings. Conventional TTE showed normal LVEF without any

significant valvular lesions but an unspecific decrease of basal septal and anterior longitudinal strain and apical post-systolic shortening at rest. Due to risk factors for coronary heart disease (CHD) stress echocardiography was performed showing slightly improved global longitudinal strain (-22% vs. -18% at rest) and post-systolic shortening of the basal inferior and lateral wall being non-specific for CHD (Figure 1). Furthermore, LV deformation was analysed and revealed abnormal subepicardial circumferential layer strain basal inferior and posterior as well as abnormal apical rotation (Figure 2). The net effect of rotation resulted in a reduced net torsion and an abnormal/chaotic torsion rate pattern (Figure 2, Supplementary material online, Videos S1–S4).



**Figure 2** Echocardiographic findings in acute HIV infection: illustration of the tracking area of apical (A, B) and basal (C, D) LV segments in parasternal short-axis views during diastole (A, C) and systole (B, D) documenting counter-clockwise rotation of the apex (B) and clockwise rotation of the base (D). Normal regional radial deformation of apical (E) and biphasic radial deformation of basal LV segments (F). Two-dimensional parasternal short-axis views showing segmental deformation and subepicardial circumferential strain values (G–J) including segmental strain graphs and colour-M-modes; abnormal subepicardial deformation is documented basal inferior and posterior; line graphs of apical (blue) and basal (magenta) rotation as well as twist (white) (K) and corresponding line graphs of rotation rate (L) document abnormal twist-/untwisting.



**Figure 3** Echocardiographic findings at 6-month-follow-up: 2D speckle tracking bull's eye patterns of global longitudinal strain (A) and post-systolic shortening (B) illustrating basal septal and anterior hypokinesia as well as post-systolic shortening. Strain graphs of normal radial deformation of apical and basal LV segments (C, D). Two-dimensional parasternal short-axis views showing segmental subendo- and subepicardial circumferential strain values (E–H) including segmental strain graphs and colour-M-Modes; abnormal deformation is documented apical inferior and posterior as well as basal inferoseptal; line graphs of apical (blue) and basal (magenta) rotation as well as twist (white) (I) and corresponding line graphs of rotation rate (J) still document abnormal twist-/untwisting.

Laboratory findings showed thrombocytopenia [30 000/ $\mu$ L (140 000–360 000/ $\mu$ L)], leukopenia [3300/ $\mu$ L (3500–9800/ $\mu$ L)] and slightly elevated Troponin-T-values [45 pg/mL (<14 pg/mL)]. The decision to test the patient for HIV was based on the laboratory findings (thrombocytopenia and leucopenia) and a more detailed patient's history at the second visit. Virologic testing revealed >1 000 000 HIV copies/mL (<40 copies/mL) confirming the diagnosis of acute phase of HIV infection. Cardiac magnet resonance (CMR) showed ubiquitous myocardial oedema and focal hyperaemia in absence of significant delayed enhancement confirming the diagnosis of AM in acute stage of HIV infection.

The patient was treated with beta-blocker (Metoprolol 50 mg) once a day since the diagnosis of AM has been assumed. Antiviral treatment was started with weight-related dose of emtricitabine/tenofovir and nevirapine according to the current guidelines.<sup>9</sup>

In addition to CMR, the diagnosis of AM could have been confirmed retrospectively by changes of deformation patterns at 6-month follow-up in comparison to baseline (Figure 3). Longitudinal strain pattern has changed showing abnormalities in the basal septal and anterior segments with normalization basal inferior. Global radial strain (GRS) was significantly increased, showing normal monophasic pattern of basal segments. Circumferential layer strain was abnormal in the apical inferior and posterior as well as basal inferoseptal segments. Net-rotation rate still showed a 'chaotic' pathological pattern during diastole. After 6 months, the effectiveness of antiviral treatment could be documented by improvement of clinical (improvement of physical capacity) and laboratory findings (decrease of HIV copies).

At 12-month follow-up regional longitudinal deformation and longitudinal post-systolic shortening index were normal. No relevant changes of GRS were observed. Circumferential strain still showed slight abnormalities in the apical inferior and posterior as well as basal inferoseptal segment. Furthermore, net-rotation rate still showed an abnormal pattern.

## Discussion

Chronic inflammation with myocardial involvement in HIV patients has previously been described.<sup>1,10,11</sup> However, distinct echocardiographic changes of LV deformation at acute stage of HIV infection and at 6-month follow-up during antiretroviral treatment are described for the first-time. The present case underlines the importance of echocardiography in combination with laboratory findings to detect myocardial involvement in systemic infectious diseases, e.g. HIV infection, prior to the detection of myocardial involvement by CMR.

The analysis of different components of LV deformation including circumferential layer strain, torsion and net torsion rate might presumably be helpful to detect subclinical or early stages of myocardial dysfunction in patients with AM and systemic infectious diseases as well as to monitor changes during treatment.<sup>7,8,12–16</sup> Alterations of longitudinal and radial LV deformation have already been described in patients with AM and reduced LV systolic function.<sup>7,8</sup> Former studies have shown that LV deformation analyses might be suitable for the detection of AM—especially at early stages.<sup>7,8</sup> LV rotation might significantly be altered in AM, because subepicardial circumferential

fibres are often involved in inflammatory processes.<sup>3–5</sup> An impairment of LV twist might be the first sign of myocardial involvement in viral AM. Early diagnosis of AM is important because it is associated with a higher risk of cardiovascular morbidity and mortality at acute stage as well as in the further course of the disease due to the development of myocardial fibrosis.<sup>6</sup>

Theoretically, a normalization of echocardiographic findings could have been expected after 6 months because of the absence of significant delayed enhancement by CMR, which actually implies the full integrity of the myocardium. Nevertheless, minor myocardial involvement of the outer LV layers might be the reason for remaining alterations of LV deformation after 6 months.

CMR represents the gold standard to confirm AM.<sup>3–5</sup> However, the availability of CMR is still limited and the risk of spreading the disease will be increased if complex and time-consuming diagnostic procedures would be used, especially in infectious diseases with high contagiousness. In contrast, the confirmation of AM by echocardiography is still challenging due to the heterogeneity of the myocardial involvement. Furthermore, the assessment of LV deformation by echocardiography—especially of circumferential layer strain, radial strain and twist/untwisting—requires an advanced level of skills and expertise. In this context also the importance of sharing these experiences between different centres and between echocardiographers should be mentioned.

## Conclusion

In summary, this case demonstrates a possibly new approach for the detection of myocardial involvement at early stages of systemic infectious diseases using modern echocardiography. As an alternative approach to CMR speckle tracking echocardiography enables a fast and widely available opportunity to detect AM—especially in diseases with high contagiousness. Further studies are necessary to set the stage for the application and the prognostic value of deformation imaging in patients with AM.

## Lead author biography



Prof. Dr med. Andreas Hagendorff is since 1999 the Associate Director of the Department of Cardiology and the Head of the Laboratories of Echocardiography and Cardiac Magnetic Resonance at the University Hospital in Leipzig, Germany. He was the president of the Working Group of Echocardiography of the German Society of Ultrasound Medicine (2006–2012) and Working Group of Cardiovascular Ultrasound of the German Society of Cardiology (2011–2013), Board member of the European

Association of Cardiovascular Imaging (2008–2012; 2014–2016), the local host of EUROECHO Imaging in Leipzig/Germany (2016). His main research areas are imaging in valvular heart diseases and infectious cardiac diseases.

## Supplementary material

Supplementary material is available at *European Heart Journal - Case Reports* online.

**Funding:** none declared.

**Slide sets:** A fully edited slide set detailing this case and suitable for local presentation is available online as [Supplementary data](#).

**Consent:** The authors confirm that written consent for submission and publication of this case report including images and associated text has been obtained from the patient in line with COPE guidance.

**Conflict of interest:** none declared.

## References

1. Ntusi NAB. HIV and myocarditis. *Curr Opin HIV AIDS* 2017;**12**:561–565.
2. Sliwa K, Carrington MJ, Becker A, Thienemann F, Ntsekhe M, Stewart S et al. Contribution of the human immunodeficiency virus/acquired immunodeficiency syndrome epidemic to *de novo* presentations of heart disease in the Heart of Soweto Study cohort. *Eur Heart J* 2012;**33**:866–874.
3. Friedrich MG, Sechtem U, Schulz-Menger J, Holmvang G, Alakija P, Cooper LT et al.; International Consensus Group on Cardiovascular Magnetic Resonance in Myocarditis. Cardiovascular magnetic resonance in myocarditis: a JACC White Paper. *J Am Coll Cardiol* 2009;**53**:1475–1487.
4. Caforio AL, Pankuweit S, Arbustini E, Basso C, Gimeno-Blanes J, Felix SB et al.; European Society of Cardiology Working Group on Myocardial and Pericardial Diseases. Current state of knowledge on aetiology, diagnosis, management, and therapy of myocarditis: a position statement of the European Society of Cardiology Working Group on Myocardial and Pericardial Diseases. *Eur Heart J* 2013;**34**:2636–2648.
5. Friedrich MG, Marcotte F. Cardiac magnetic resonance assessment of myocarditis. *Circ Cardiovasc Imaging* 2013;**6**:833–839.
6. Shirani J, Freant LJ, Roberts WC. Gross and semiquantitative histologic findings in mononuclear cell myocarditis causing sudden death, and implications for endomyocardial biopsy. *Am J Cardiol* 1993;**72**:952–957.
7. Afonso L, Hari P, Pidlovan V, Kondur A, Jacob S, Khetarpal V. Acute myocarditis: can novel echocardiographic techniques assist with diagnosis? *Eur J Echocardiogr* 2010;**11**:E5.
8. Khoo NS, Smallhorn JF, Atallah J, Kaneko S, Mackie AS, Paterson I. Altered left ventricular tissue velocities, deformation and twist in children and young adults with acute myocarditis and normal ejection fraction. *J Am Soc Echocardiogr* 2012;**25**:294–303.
9. DHHS Panel on Antiretroviral Guidelines for Adults and Adolescents. Guidelines for the use of antiretroviral agents in HIV-1 infected adults and adolescents. AIDSinfo Website Accessed March 9, 2016]. Updated January 28, 2016.
10. Frustaci A, Petrosillo N, Francone M, Verardo R, Ippolito G, Chimenti C. Biopsy-proven autoimmune myocarditis in HIV-associated dilated cardiomyopathy. *BMC Infect Dis* 2014;**14**:729.
11. Ntusi N, O'Dwyer E, Dorrell L, Wainwright E, Piechnik S, Clutton G et al. HIV-1-related cardiovascular disease is associated with chronic inflammation, frequent pericardial effusions, and probable myocardial edema. *Cardiovasc Imaging* 2016;**9**:e004430.
12. Escher F, Kasner M, Kühl U, Heymer J, Wilkenshoff U, Tschöpe C et al. New echocardiographic findings correlate with intramyocardial inflammation in endomyocardial biopsies of patients with acute myocarditis and inflammatory cardiomyopathy. *Mediators Inflamm* 2013;**2013**:1–9.
13. Løgstrup BB, Nielsen JM, Kim WY, Poulsen SH. Myocardial oedema in acute myocarditis detected by echocardiographic 2D myocardial deformation analysis. *Eur Heart J Cardiovasc Imaging* 2016;**17**:1018–1026.
14. Sturmberger T, Niel J, Aichinger J, Ebner C. Acute myocarditis with normal wall motion detected with 2D speckle tracking echocardiography. *Echo Res Pract* 2016;**3**:K15–K19.
15. Caspar T, Fichot M, Ohana M, El Ghannudi S, Morel O, Ohlmann P. Late detection of left ventricular dysfunction using two-dimensional and three-dimensional speckle-tracking echocardiography in patients with history of nonsevere acute myocarditis. *J Am Soc Echocardiogr* 2017;**30**:756–762.
16. Du Toit R, Herbst PG, van Rensburg A, Snyman HW, Reuter H, Doubell AF. Speckle tracking echocardiography in acute lupus myocarditis: comparison to conventional echocardiography. *Echo Res Pract* 2017;**4**:9–19.