

Anomalous Origin and Course of the Suprascapular Artery Combined with Absence of the Suprascapular Vein: Case Study and Clinical Implications

Panagiotis Pyrgakis, Eleni Panagouli, Dionysios Venieratos

Department of Anatomy, Medical School, University of Athens, 116 27 Athens, Greece

Abstract

Background: Variations concerning the origin and course of the suprascapular artery are numerous and present important clinical implications. **Aim:** In the present study the origin and course of the suprascapular artery are investigated in a sample of Greek (Caucasian) origin. **Materials and Methods:** The anatomy and course of the suprascapular artery were carefully examined in 31 adult human cadavers (16 male and 15 female). **Results:** Anomalous origin of the suprascapular artery from the third segment of the subclavian artery was observed in the right side of only one female Caucasian specimen (1/62 = 1.6%). The suprascapular artery and the suprascapular nerve passed together under the superior transverse scapular ligament through the suprascapular notch, whereas the suprascapular vein was absent. **Conclusion:** According to the available literature, this type of variation in the origin of the suprascapular artery is considered rare. This variation is clinically important, since it is related to the creation mechanism of suprascapular neuropathy and has also obvious surgical implications. The variation is embryologically enlightened and has an interesting ontogenic aspect.

Keywords: Shoulder pain, Subclavian artery, Superior transverse scapular ligament, Suprascapular nerve, Suprascapular notch

Address for correspondence: Dr. Eleni Panagouli, Department of Anatomy, Medical School, University of Athens, Mikras Asias Str. 75, 116 27 Athens, Greece. E-mail: eleni72000@yahoo.gr

Introduction

According to classic anatomical textbooks, the suprascapular artery is the first (lower) branch of the thyrocervical trunk and runs transversely in the posterior cervical triangle, parallel, behind, and above the clavicle.^[1] The artery first courses laterally, in front of the scalene anterior muscle and the phrenic nerve and then crosses anterior to the third part of the subclavian artery and the primary cords of the brachial plexus.^[1] Then, it continues backward and skirt the inferior belly of the omohyoid muscle to reach the superior border of the scapula, where it normally passes over the superior transverse scapular ligament (STSL).^[1] By this way, it

reaches the supraspinous fossa and continues to the infraspinous fossa through the spinoglenoid notch.^[1] At the dorsal scapula, it creates an important anastomotic network with the dorsal scapular artery (also known as deep branch of the transverse cervical artery) and the circumflex scapular branch of the subscapular artery.^[1]

Normally, the suprascapular artery joins the suprascapular nerve near the middle half of the superior border of the scapula.^[1] The nerve passes under the STSL and through the suprascapular notch, before entering the supraspinous fossa.^[1] At the dorsal scapula the suprascapular artery and nerve run together supplying the same targets (supraspinatus and infraspinatus muscles).^[1] The suprascapular notch is located at the superior border of the scapula, medial to the base of the coracoid process, and is converted into a foramen by the STSL.^[2]

Variations concerning the origin and course of the suprascapular artery are numerous and well described in the literature. A common trunk providing the suprascapular and the superficial cervical (also known

Access this article online

Quick Response Code:



Website:
www.najms.org

DOI:
10.4103/1947-2714.107534

as transverse cervical) artery has been described in 30% of the individuals, whereas in 28% of the cases both arteries arise directly from the thyrocervical trunk^[3] (the transverse cervical artery, whenever it exists, provides both the superficial cervical and the dorsal scapular arteries^[1]). The origin of the suprascapular artery from different segments of the subclavian artery or from the axillary artery has been reported with a median incidence of 10%.^[3] In the most common type, the artery arises from the subclavian artery, with an incidence between 2.8%^[4] and 21.3%.^[5] The suprascapular artery might also emerge from the internal thoracic artery (1-5.1%),^[1,5,6] from the costocervical trunk (1%),^[6] or from the dorsal scapular artery.^[7]

There has also been a report of two cases of duplicated suprascapular arteries existing bilaterally—one rising from the thyrocervical trunk and one rising from the third part of the subclavian artery.^[8] In both cases, the artery with normal origin had also a normal course, whereas the other one passed below the transverse scapular ligament. Finally, the suprascapular artery may be absent almost in 3% of the cases.^[8]

The suprascapular vein accompanies the artery and usually lies ventral and superior to it.^[1] The vein normally drains the same region as the corresponding artery, passes through the suprascapular notch, and finally flows into the external jugular vein (as a rule).^[1] This anatomic region (dorsal scapula) may also be drained by the dorsal scapular vein (deep branch of the transverse cervical vein flowing into the jugular vein) and the circumflex scapular branch of the subscapular vein.^[1]

In the present study, after a thorough examination of the suprascapular artery in a sample of Greek (Caucasian) origin, we describe one case of anomalous origin of the suprascapular artery from the third segment of the subclavian artery, combined with anomalous course under the transverse scapular ligament. Moreover, surprisingly enough, no suprascapular vein was detected, a very rare finding, which has never been mentioned in the available literature.

This specific arterial pattern is considered of major clinical importance since it can be related to undiagnosed shoulder pain and neurogenic malfunction of the shoulder's rotator cuff.

Materials and Methods

The anatomy and course of the suprascapular artery were carefully examined in 31 embalmed adult human cadavers of Caucasian (Hellenic) origin (16 male and 15 female). A total of 62 sides were dissected. The age of the specimens ranged between 39 and

98 years (average age 77.5 years, SD = ±11.107, SE = 1.385). All the cadavers were derived from body donation with informed consent,^[9] written and signed with signature authentication by the donator himself. The dissection was performed for educational purposes. All donated cadavers were used; consequently, our specimens may be considered as randomly selected.

The proper dissection to reach and enlighten the suprascapular artery, without damaging the structures of the corresponding area, must follow this order: Platysma, external jugular vein, sternocleidomastoid and omohyoid muscles, internal jugular vein, vertebral artery, subclavian artery, thyrocervical trunk, suprascapular and superficial (or transverse) cervical arteries, phrenic nerve, anterior scalene muscle, primitive trunks of the brachial plexus, suprascapular nerve and vein, continuation of the subclavian artery, STSL, and the suprascapular notch.

All the distances were measured using calipers. To obtain the distances between the vessels, the center of the origin of each vessel was taken as the recordable point of origin.

Results

The left suprascapular artery presented the usual described course and origin in all cadavers.

On the right side of only one female cadaver (deceased at the age of 88 years), we observed at the right posterior cervical triangle an anomalous origin of the right suprascapular artery. The artery emerged from the third segment of the subclavian artery, very close to the first segment of the axillary artery and 4.7 cm distal to the origin of the thyrocervical trunk [Figure 1]. Because of this origin external to the scalene anterior muscle, the suprascapular artery did not cross superficially the phrenic nerve and the muscle, as usual, but it ran immediately in front of the brachial plexus and under the suprascapular nerve. The artery continued parallel to the nerve until it reached the suprascapular notch [Figure 1]. There, the suprascapular artery and nerve passed under the STSL into the suprascapular notch (converted by the ligament into a foramen). The STSL was found ossified to a great extent, converting the notch into a foramen. The ossification was examined physically: The STSL was harder than a fibrous tissue when pushed and squeezed; the percussion of the STSL with forceps created a pitched sound as if hitting a rock or bone and not a dull sound. Inside this foramen, the artery ran in front of the nerve. The artery was measured to be 7.6 cm from its origin to the foramen. Surprisingly, the suprascapular vein was absent.

The frequency of the above-described variation was thus 1.6% (1/62 sides).

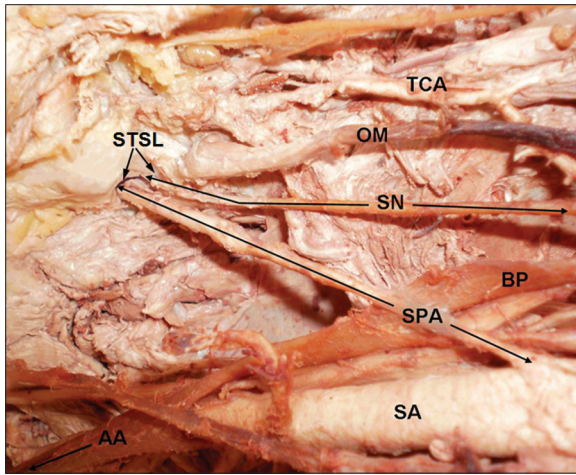


Figure 1: The suprascapular artery (SPA) originates from the third segment of the subclavian artery (SA), very close to the first segment of the axillary artery (AA) and passes under the superior transverse scapular ligament (STSL), together with the suprascapular nerve (SN) and over the brachial plexus (BP). TCA: Transverse cervical artery; OM: Omohyoid muscle

Discussion

Several types of anomalous origin of the suprascapular artery are extensively studied and quantified. The deviation from the normal pattern is not unusual,^[1-8] as the subclavian artery and different types of common arterial trunks had been described at different locations of origin. In the present study the suprascapular artery constituted a branch of the thyrocervical trunk in all but one case (1.6%, 1/62) where it emerged from the third segment of the subclavian artery (right side of a female cadaver), very close to the first segment of the axillary artery. According to the available literature, this type of origin seems to be one of the rarest. Mishra and Ajmani^[10] reported that the suprascapular artery originated from the first part of the axillary artery with an incidence of 1.6% (1/60 sides, variation observed on the left side), whereas Adibatti and Prasanna^[11] observed the same variation in one cadaver (male, left side) out of 30 studied. Additionally, Mahato^[12] recorded a single case of anomalous bilateral origin of the suprascapular artery from the third part of the axillary artery.

Extensive studies^[7,13,14] have been carried out on the subligamentous course of the suprascapular artery. According to Tubbs *et al.*,^[15] the suprascapular artery, accompanied by the suprascapular nerve, passes under the STSL with a median incidence of 2.5% (3/120). In one (male) cadaver, the finding was bilateral and in one other (also male) unilateral.^[15] Yang *et al.*^[16] classified the arrangement of the suprascapular vessels into three types: In Type I (59.4%), all suprascapular vessels ran over the STSL; in Type II (29.7%), the vessels ran over and under the STSL simultaneously (at least one vessel

passed under or over the STSL); and in Type III (10.9%), all vessels ran under the STSL. Furthermore, three cases of the suprascapular artery passing through the suprascapular notch during endoscopic suprascapular nerve release have been reported by Reineck and Krishnan.^[17]

Anomalous course of the suprascapular artery inside the suprascapular notch very frequently coexists with an ipsilateral variation in the origin of the artery.^[1,3] In particular, this variation was combined with anomalous origin from the subclavian or axillary artery.^[2,10,11,12] This was similar to the findings in the study of Adibatti and Prasanna.^[11] Nevertheless, Mishra and Ajmani^[10] observed three cases where the suprascapular artery coursed inside the notch, with only one of them combined with variation in the origin of the artery (1/60 = 1.6%). In the present study, the sole case of unusual origin of the suprascapular artery was indeed combined with its passage under the STSL (1.6%, 1/62).

In our case, variation of the artery's origin and course is accompanied by total absence of the suprascapular vein. This finding is not described in the available literature.

According to the available literature, the incidence of complete ossification of the STSL varied from 3.7% to 13.6%.^[18] However, complete ossification of the STSL is exceptionally rare in some populations, such as in Alaskan Eskimos or Indians.^[18] Duparc *et al.*^[19] reported that STSL appeared calcified and rigid (not necessarily completely ossified) in 26.7% of the cases. The calcified STSL is considered to be a sign of entrapment. On the other hand, simultaneous ossification of the coracoid process and epiphysis, as observed mostly in Nigerian infants, might change the shape of the notch.^[20]

Embryologically, all main vessels develop from a primary plexus of smaller ones.^[15] The prevailing conditions lead some vessels to enlarge and form definitive channels and others to regress.^[7] During this phase of development, it is possible that different patterns in the vessels may appear, including both the origin and/or the course of either arteries or veins.

An origin of the suprascapular artery in the vicinity of the thyrocervical trunk (either from the subclavian artery itself or from a common trunk with the transverse cervical artery) is by far the most common variation and at the same time the least interesting one from an anatomical or clinical viewpoint, since in this case the course and relations of the artery are hardly influenced. On the contrary, an origin of the suprascapular artery from the third part of the subclavian artery or from the axillary artery is rarer and clinically significant. Furthermore, this variation is frequently accompanied

by the passage of the artery through the suprascapular notch.

Surgeries in the anterior neck and supraclavicular region, such as radical and modified neck dissections to control the lymphogenous spread of head and neck cancer, may require ligation of the suprascapular artery. Thus, knowledge of the possible variations in the origin and the course of the artery are very important.^[21]

Clavicular fractures are fairly common and most often occur in the middle third of the bone.^[22-24] The suprascapular artery supplies with blood the proximal 4/5th of the clavicle and constitutes the exclusive blood supply for the middle 1/3rd of the clavicle.^[25] On doing so, it runs parallel, above and close to the clavicle, but not in touch with it. This usually avoids a disastrous damage of the artery during clavicular fractures. A direct origin of the suprascapular artery from the middle of the subclavian artery coursing below the clavicle merely enhances the probability of arterial damage during fracture of this bone. The seemingly illogical origin of the suprascapular artery from the thyrocervical trunk (since it results in its greater length) may be attributed to an effort to minimize the danger of its injury. If the suprascapular artery rises from an anomalous position it is possible that its unusual origin and course could either increase or decrease the danger of being damaged by a broken clavicle, according to the vicinity of this origin with the middle of the bone. In our case, the suprascapular artery emerged very close to the first segment of the axillary artery and almost behind the external third of the clavicle, which means that the usual middleclavicular break would not pose great danger to the artery. However, if the suprascapular artery arises from the internal thoracic, its ascending course behind the middle third of the clavicle could be extremely dangerous not only for the nutrient wigs of the bone but also for the whole suprascapular artery.

Inside the suprascapular notch, the suprascapular nerve is restrained by the transverse scapular ligament. This may lead to friction of the nerve, inflammation, and finally constriction of the nerve, leading to suprascapular neuropathy.^[26] Factors such as ossification of the STSL and anomalous course of the suprascapular artery under the ligament could lead to a faster and more severe constriction of the nerve, since they reduce the capacity of the notch.^[15] Chronically, this could lead to atrophy of the supraspinatus and infraspinatus muscles, limited decreasing abduction, and external rotation of the shoulder and chronic deep-seated pain in the shoulder that is aggravated with movement (suprascapular neuropathy symptoms).^[27] Suprascapular neuropathy may of course occur by other mechanisms as well: For

example, by mikroembols in the vasa nervosum of the suprascapular nerve engendered through a damage of the suprascapular artery.^[10]

Thus, “unexplained” shoulder pain, namely pain not due to arthritis (inflammation of glenohumeral or acromioclavicular joints), or malfunction of the shoulder’s rotator cuff must lead to investigation of an eventual neuropathy. Noticeably, in our case, in which the suprascapular vein is absent, the probability of a suprascapular neuropathy was reduced, since the suprascapular notch contained two items (artery and nerve) instead of three. However, the pulsing artery might produce minor annoyance to the nerve, especially when it contacts its sensitive fibers.

Conclusion

In a sample of 31 cadavers, we found a suprascapular artery rising in an anomalous way from the third part of the subclavian artery in the right side of only one cadaver (1.6%, 1/62). However, the sample (62 sides) is not big enough to identify the prevalence of the specific variation in the general population. The suprascapular artery exhibited a variation in its course, too, as it passed through the suprascapular foramen together with the suprascapular nerve. Both the variations in the origin and the course have already been reported in the past and should be considered as independent variations since they do not always appear together in the same individual. However, the variations in the origin of this artery are numerous and usually coexist with an abnormal course underneath the STSL. Surgeons and orthopedics should be familiar with these variations, which may complicate their task.

References

1. Standring S, Borley NR, Collins P, Crossman AR, Gatzoulis MA, Healy JC, *et al.* Gray’s anatomy. The Anatomical Basis of Clinical Practice. Edinburgh: Elsevier; 2008. p. 449-450, 814, 820-1.
2. Natsis K, Totlis T, Tsikaras P, Appell HJ, Skandalakis P, Koebeke J. Proposal for classification of the suprascapular notch: A study on 423 dried scapulas. *Clin Anat* 2007;20:135-9.
3. Tountas CP, Bergman RA. Anatomic Variations of the Upper Extremity. Chap. 3, Arteries. Churchill Livingstone; 1993. p. 190-2.
4. Degaris CF. Patterns of branching of the subclavian artery in white and negro stocks. *Am J Phys Anthropol* 1924;7:95-107.
5. Reed WT, Trotter M. The origins of the transverse cervical and of transverse scapular arteries in American Whites and Negroes. *Am J Phys Anthropol* 1941;28:239-47.
6. Lippert H, Pabst R. Arterial variations in man. Classification and Frequency. Muenchen: Bergmann; 1985. p. 78-9.
7. Saadeh FA. The suprascapular artery: Case report of an unusual origin. *Anat Anz* 1979;145:83-6.

8. Takafuji T, Sato Y. Study on the subclavian artery and its branches in Japanese adults. *Okajimas Folia Anat Jpn* 1991;68:171-85.
9. McHanwell S, Brenner E, Chirculescu AR, Drukker J, van Mameren H, Mazzotti G, *et al.* The legal and ethical framework governing body donation in Europe: A review of current practice and recommendations for good practice. *Eur J Anat* 2008;12:1-24.
10. Mishra S, Ajmani ML. Anomalous origin of the suprascapular artery: A case report. *J Anat Soc India* 2003;52:180-2.
11. Adibatti M, Prasanna LC. Variation in the origin of suprascapular artery. *IJAV* 2010;3:178-9.
12. Mahato NK. Bilateral anomalous suprascapular arteries. *Eur J Anat* 2010;14:31-4.
13. Pye-Smith PH, Howse HG, Davies-Colley JN. Notes on abnormalities observed in the dissection room during the winter sessions of 1868-1869 and 1869-1870. In: Fagge CH, Durham AE, editors. *Guy's Hospital Reports*. London: J and A Churchill; 1871. p. 147-64.
14. Cummins CA, Anderson K, Bowen M, Nuber G, Roth SI. Anatomy and histological characteristics of the spinoglenoid ligament. *J Bone Joint Surg Am* 1998;80:1622-5.
15. Tubbs RS, Smyth MD, Salter G, Oakes WJ. Anomalous traversement of the suprascapular artery through the suprascapular notch: A possible mechanism for undiagnosed shoulder pain? *Med Sci Monit* 2003;9:BR116-9.
16. Yang HJ, Gil YC, Jin JD, Ahn SV, Lee HY. Topographical anatomy of the suprascapular nerve and vessels at the suprascapular notch. *Clin Anat* 2012;25:359-65.
17. Reineck JR, Krishnan SG. Subligamentous suprascapular artery encountered during arthroscopic suprascapular nerve release: A report of three cases. *J Shoulder Elbow Surg* 2009;18:e1-3.
18. Polgaj M, Jędrzejewski K, Podgórski M, Topol M. Morphometric study of the suprascapular notch: Proposal of classification. *Surg Radiol Anat* 2011;33:781-7.
19. Duparc F, Coquerel D, Ozeel J, Noyon M, Gerometta A, Michot C. Anatomical basis of the suprascapular nerve entrapment, and clinical relevance of the supraspinatus fascia. *Surg Radiol Anat* 2010;32:277-84.
20. Sinkeet SR, Awori KO, Odula PO, Ogeng'o JA, Mwachaka PM. The suprascapular notch: Its morphology and distance from the glenoid cavity in a Kenyan population. *Folia Morphol (Warsz)* 2010;69:241-5.
21. Lamb DD. Radical neck dissection. *Surg Technol* 2010;449-54.
22. Neer CS 2nd. Nonunion of the clavicle. *J Am Med Assoc* 1960;172:1006-11.
23. Rowe CR. An atlas of anatomy and treatment of midclavicular fractures. *Clin Orthop Relat Res* 1968;58:29-42.
24. Robinson CM. Fractures of the clavicle in the adult. Epidemiology and classification. *J Bone Joint Surg Br* 1998;80:476-84.
25. Havet E, Duparc F, Tobenas-Dujardin AC, Muller JM, Delas B, Fréger P. Vascular anatomical basis of clavicular non-union. *Surg Radiol Anat* 2008;30:23-8.
26. Antoniadis G, Richter HP, Rath S, Braun V, Moese G. Suprascapular nerve entrapment: Experience with 28 cases. *J Neurosurg* 1996;85:1020-5.
27. Kato K. Innervation of the scapular muscles and its morphological significance in man. *Anat Anz* 1989;168:155-68.

How to cite this article: Pyrgakis P, Panagouli E, Venieratos D. Anomalous origin and course of the suprascapular artery combined with absence of the suprascapular vein: Case study and clinical implications. *North Am J Med Sci* 2013;5:129-33.

Source of Support: Nil. **Conflict of Interest:** None declared.