

# Surgical treatment of secondary fractures after percutaneous vertebroplasty: A retrospective study

Jiang-jun Zhu, Dong-sheng Zhang, Su-liang Lou, Yong-hong Yang

## ABSTRACT

**Background:** Percutaneous vertebroplasty (PVP) and percutaneous kyphoplasty (PKP) are effective procedures for the treatment of vertebral compression fractures (VCFs). However, recent studies have reported that secondary VCFs develop in patients after PVP or PKP treatment. This study aimed to investigate the clinical characteristics and management of secondary fractures after PVP or PKP.

**Materials and Methods:** 599 cases who had vertebral compression fracture and underwent PVP or PKP between September 2008 and June 2014 were enrolled, including 121 males and 478 females. Secondary fractures were observed in 52 cases, including 3 males and 49 females, who were treated by re-operation with PVP or PKP.

**Results:** The ratio of secondary fracture after PVP or PKP was 8.68% in all cases. The age ranged from 59 to 92 years (74.41 ± 6.83 average). A composition of 44.44% of the secondary fracture occurred near the initial fracture vertebrae. After re-operation with PVP or PKP, visual analog scale score significantly decreased to 2.72 ± 0.88 or 2.52 ± 1.12, respectively, anterior height of vertebral bodies increased to 24.69 ± 4.59 or 24.54 ± 5.97 mm, respectively, and middle height of vertebral bodies increased to 20.90 ± 3.72 or 20.36 ± 6.33 mm, respectively.

**Conclusions:** There is a high chance of secondary fracture near the initially operated vertebrae after PVP or PKP. Re-operation with PVP or PKP achieves satisfactory outcomes in these patients such as pain relief and the recovery of the vertebrae height.

**Key words:** Osteoporosis, thoracolumbar fracture, vertebroplasty, secondary fracture, bone cement

**MeSH terms:** Osteoporosis, bone cements, vertebral, thoracic vertebra, lumbar vertebra

## INTRODUCTION

Osteoporosis is a common disease in the elderly, leading to vertebral compression fractures (VCFs), which is a major health care problem and there is high incidence of morbidity and mortality.<sup>1</sup> About 26% of the women over 50-year-old and 40% of the women over 80-year-old have sustained VCF.<sup>2</sup> With the trend of increased aging of population, the incidences of osteoporosis and associated VCFs are expected to be more prevalent. The main conservative management for symptomatic VCFs include medical therapy, activity

modification, external bracing, and rehabilitation. However, percutaneous vertebroplasty (PVP) and balloon kyphoplasty are minimally invasive and effective treatment of VCFs. PVP involves minimal invasive injection of bone cement into the fractured vertebral body, therefore stabilizing osteoporotic VCFs and relieving associated local back pain. Percutaneous kyphoplasty (PKP) is a modification of PVP and involves the insertion of an inflatable instrument into the vertebral body to restore the height of a collapsed vertebral body and create a cavity inside before the cement is injected.<sup>3</sup> PVP and PKP have been shown to significantly improve the long term outcomes of VCFs in terms of pain control, analgesic requirements, function, cost, and the incidence of serious complications.<sup>4-8</sup>

Department of Orthopaedics, The No. 117 Hospital of PLA, Hangzhou, Zhejiang, China

**Address for correspondence:** Dr. Yong-hong Yang, Department of Orthopaedics, The No. 117 Hospital of PLA, Tian Cheng Road, Hangzhou, Zhejiang, 310013, China. E-mail: 173770976@qq.com

| Access this article online                                                          |                                  |
|-------------------------------------------------------------------------------------|----------------------------------|
| Quick Response Code:                                                                | Website:<br>www.ijoonline.com    |
|  | DOI:<br>10.4103/0019-5413.205677 |

This is an open access article distributed under the terms of the Creative Commons Attribution-NonCommercial-ShareAlike 3.0 License, which allows others to remix, tweak, and build upon the work non-commercially, as long as the author is credited and the new creations are licensed under the identical terms.

**For reprints contact:** reprints@medknow.com

**How to cite this article:** Zhu Jj, Zhang Ds, Lou Sl, Yang Yh. Surgical treatment of secondary fractures after percutaneous vertebroplasty: A retrospective study. Indian J Orthop 2017;51:269-72.

However, recent studies reported that secondary VCFs developed in patients after they were treated with PVP or PKP, such as the compression of previously operated vertebrae and newly developed fractures in adjacent vertebrae.<sup>9-11</sup> It remains unclear how to manage secondary VCFs in patients after PVP or PKP operation. In this study, we aimed to define the clinical characteristics of secondary fracture after PVP and investigate the management of secondary fracture by re-operation with PVP or PKP.

## MATERIALS AND METHODS

The study was approved by the hospital Ethical Committee informed and an informed consent was taken from all patients. 599 patients who underwent PVP or PKP between September 2008 and June 2014 were enrolled in this study, including 121 males and 478 females. They were followed up from 3 to 72 months for the presence of thoracic and lumbar back pain and examined by magnetic resonance and X-ray examination. Secondary fracture was observed in 52 cases, including 3 males and 49 females, whose age ranged from 59 to 92 years, (average age  $74.41 \pm 6.83$  years).

Among 52 patients with secondary fractures, two received conservative treatment and the fractures were successfully managed. The remaining 50 patients were randomly divided into two groups as follows: Group 1, treated with PVP and Group 2, treated with PKP. The age, gender, and other demographic data of the patients in two groups showed no significant differences. For PVP or PKP procedure, the inclusion criteria included osteoporotic vertebral fractures or fractures caused by malignant tumor and the exclusion criteria included over 90% collapse of fractured vertebral body.

### Operative procedure

The surgery was performed in prone position and under local anesthesia with 1% lidocaine before the operation. To access the collapsed vertebral body, the transpedicular approach was employed. Briefly, biplane fluoroscopy

with two C-arms was placed in the posteroanterior and lateral positions, and then, trephine with a diameter of 3 mm (Medtronic, Minneapolis, MN, USA) was passed immediately into the vertebral body through the previously inserted cannula. For PVP or PKP, the cannula was inserted before the infusion of polymethylmethacrylate cement Osteopal®V (Heraeus Medical GmbH, Wehrheim, Germany) or before the insertion of an inflatable bone tamp, respectively. After the operation, the patients were kept in the prone position for 15 min.

### Evaluation of operation outcomes

All patients were examined for pain assessments using visual analog scale (VAS), and anteroposterior and lateral radiographs were taken to measure the vertebral body height.

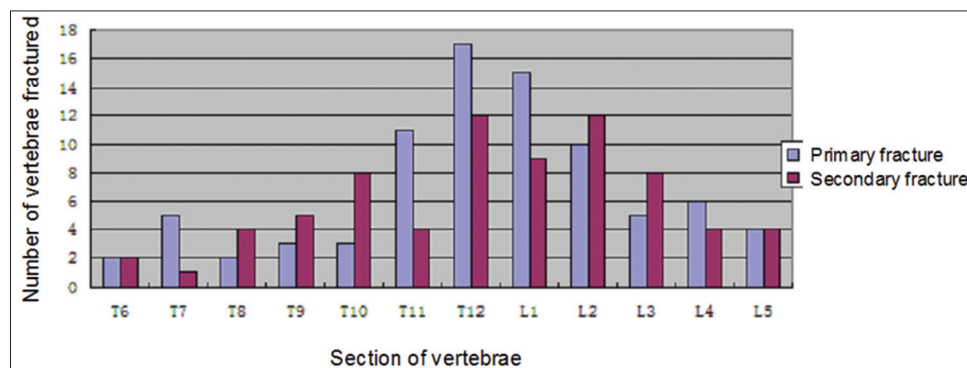
### Statistical analysis

Data were analyzed using SPSS version 19.0 statistical analysis package (SPSS Inc., Chicago, IL, USA). Examined data were assessed using the *t* test.  $P < 0.05$  was accepted as statistically significant.

## RESULTS

Among 52 patients with secondary fractures, the primary VCFs involved 83 vertebrae, including 27 cases of single fracture and 25 cases of multiple fractures, among which 21 cases had two fractures, 2 cases had three fractures, and 2 cases had four fractures. The secondary VCFs involved 72 vertebrae, including 36 cases of single fracture and 16 cases of multiple fractures (involving 36 vertebrae), among which 13 cases had two fractures, 2 cases had three fractures, and 1 case had four fractures.

The primary and secondary fractures mainly occurred in thoracic and/or lumbar spine from T6 to L5 [Figure 1]. In primary fractures, 53 vertebra (63.86%) located in T11 to L2 were involved, whereas in secondary fractures, 37 vertebra (51.38%) located in T11 to L2 were



**Figure 1:** A Bar diagram showing the distribution of the vertebrae with primary and secondary fractures in all cases enrolled in this study

involved. About 26 cases of secondary fractures (involving 32 vertebrae) occurred adjacent to primary fractures. In the three male patients, both primary and secondary fractures were multiple fractures.

In 52 patients, secondary fractures developed between 7 days and 84 months after primary PVP or PKP treatment (average 27 months). Among them, 7 patients (7/52, 13.46%) had secondary fractures within 1 month after PVP or PKP. One female patient (63-year-old) had fractures three times. At first, she received PVP on T10, T11, and L5, she had fracture in L1 41 months later and received PVP, and then she had fracture in L2 17 months later. Another female patient (70-year-old) had fractures four times. At first, she received PVP on T10, T11, and L5, 2 months later, she had fracture in T11 and T12 and received conservation treatment. However, she had fracture in T8 and L5 34 months later and was treated by PVP, and then she had fracture in L3 and L4 19 months later and received PVP again.

### Operations by percutaneous vertebroplasty versus percutaneous kyphoplasty

Bilateral vertebral puncture was performed in 43 vertebrae, whereas unilateral vertebral puncture was performed in 27 vertebrae, 18 vertebrae in the left and 9 vertebrae in the right. Individual lumbar vertebral surgery took 12–110 min (an average of  $31.70 \pm 20.49$  min). Individual thoracic vertebral surgery took 15–65 min (an average of  $31.19 \pm 13.61$  min). During individual lumbar vertebral surgery, 2.5–6 ml of bone cement (an average of  $4.75 \pm 1.17$  ml) was filled in. During individual thoracic vertebral surgery, 1.5–6 ml of bone cement (an average of  $3.94 \pm 1.64$  ml) was filled in. Bone cement leakage occurred in 19 vertebrae, accounting for 27.14% of the total number of vertebrae undergoing surgery, and included a small amount of spinal canal leakage in one case, intervertebral disk leakage in two cases, vertebral venous leakage in six cases, and leakage at other parts of vertebral body in ten cases. However, all the leakage cases showed no obvious clinical symptoms. In PKP group, 12 vertebrae had leakage, accounting for 27.27% of all vertebrae in this group. In PVP group, 7 vertebrae had leakage, accounting for 26.92% of all vertebrae in this group. There was no significant difference in the leakage between PVP and PKP groups ( $P > 0.05$ , *t*-test).

### Outcomes of percutaneous vertebroplasty versus percutaneous kyphoplasty

Pain was relieved in all patients after surgery by PVP or PKP. In PKP group, VAS score was significantly decreased from  $8.16 \pm 1.75$  before surgery to  $2.72 \pm 0.88$  after surgery ( $P < 0.01$ , *t* test). In PVP group, VAS score was significantly decreased from  $7.92 \pm 1.61$  before surgery to  $2.52 \pm 1.12$

after surgery ( $P < 0.01$ , *t* test). When PKP and PVP groups were compared, there was no significant difference in VAS score ( $P > 0.05$ , *t* test), indicating that PKP and PVP have similar analgesia effect. All patients were discharged 3–9 days after surgery (average length of stay at 4.5 days).

The anterior height of vertebral bodies was  $23.34 \pm 5.44$  mm in PKP group and  $23.57 \pm 5.80$  mm in PVP group before surgery, and increased to  $24.69 \pm 4.59$  mm in PKP group and  $24.54 \pm 5.97$  mm in PVP group after surgery. The middle height of vertebral bodies was  $19.17 \pm 4.37$  mm in PKP group and  $19.71 \pm 4.05$  mm in PVP group before surgery, and increased to  $20.90 \pm 3.72$  mm in PKP group and  $20.36 \pm 6.33$  mm in PVP group after surgery. Both anterior and middle heights of vertebral bodies increased in PKP and PVP groups after the surgery by PKP or PVP, but there were no significant differences in anterior and middle heights of vertebral bodies between PKP and PVP groups ( $P > 0.05$ , *t* test). These data indicate that PKP and PVP have similar effect to recover the heights of vertebral bodies after fracture.

### DISCUSSION

Since the first report on the use of PVP,<sup>3</sup> PVP has been increasingly performed to treat thoracolumbar osteoporotic compression fractures, vertebral hemangioma, spinal metastases, spinal myeloma, and other diseases. In particular, PVP was employed to treat VCFs refractory to conservation treatment, and remarkable pain relief was achieved in many patients. PVP becomes an ideal therapy approach because it is safe and minimally invasive, has good analgesic effect, and enhances quick recovery of the patients. However, with the wide application of PVP, the issue of secondary VCFs developed after PVP has attracted attention from the patients and surgeons. The management of secondary VCFs in patients after PVP becomes a new challenge. In this study, we reported our experiences dealing with secondary fracture after PVP.

Two main reasons may account for the development of secondary VCFs in patients who have undergone PVP or PKP. First, with the progression of osteoporosis, the vertebral bodies become more vulnerable to fractures. Earlier study showed that women with osteoporosis who developed vertebral fracture were at a substantial risk for additional fracture within the next year after the first fracture.<sup>12</sup> Second, during PVP or PKP, vertebral augmentation is employed, leading to the changes of biomechanics of the spine. Consequently, through the “pressure ascension” effect, the load is transmitted to the segment of vertebral body adjacent to the first fractured segment. This increases the risk of new fractures.<sup>13</sup> In this study, we found that

among new fractures which developed within 1 year after PVP, 15 vertebrae (15/19, 78.88%) were adjacent to the segments which had been treated by PVP. However, among new fractures developing more than 1 year after PVP, only 17 vertebrae (32.01%) were adjacent to the segments which had been treated by PVP. These data provide the support for the second reason described above to explain the development of secondary VCFs after PVP or PKP surgery. In contrast, at a long time after PVP or PKP surgery, the newly developed fractures were more likely to be due to the progression of osteoporosis.

It is generally accepted that the age, bone mineral density, body mass index (BMI), treatment methods, and the leakage of bone cement in the intervertebral disc are the main risk factors for new fracture after PVP. The age, bone mineral density, and BMI will affect the vertebral bodies. With the increase of age, the absorption of bone and bone mineral density decreases gradually, thus increasing the risk of fracture. BMI is related to the level of estrogen, which can stimulate the osteoblasts and increase bone mass. Thus, a low BMI increases the risk of fracture. Rho *et al.* reported that new fracture was significantly associated with bone density and age, and bone density was identified as the only significant factor of fracture by multivariate logistic regression analysis.<sup>14</sup> It has been proposed that the most important predisposing factor for fracture after PVP or PKP was osteoporosis.<sup>9</sup> In agreement with this, we found that new fractures developed at much higher chance in women than in men ( $P < 0.05$ ), only 3 men (2.48%) developed secondary fractures among the total 121 men who received PVP or PKP, while 49 women (10.23%) developed secondary fractures among the total 478 women who received PVP or PKP. Therefore, it is very important to develop strategy against osteoporosis to prevent secondary fractures after PVP or PKP. In this series, all patients took calcium carbonate and vitamin D3 tablets every day after surgery.

Although there is still controversy about whether PVP itself is a risk factor for subsequent vertebral fracture, a recent meta-analysis showed that it is unlikely that vertebroplasty contributes to an increased risk of subsequent vertebral fracture.<sup>15</sup> In this study, we treated secondary fractures by PVP or PKP and found that PVP and PKP achieved similar satisfactory outcomes such as pain relief and the recovery of the heights of vertebral bodies. Therefore, PVP or PKP is a feasible method to manage secondary fracture.

## CONCLUSIONS

There is a high chance of secondary fracture near the initial surgery vertebrae after PVP or PKP. Re-operation with PVP or PKP could achieve satisfactory outcomes in the patients

with secondary fracture.

## Financial support and sponsorship

Nil.

## Conflicts of interest

There are no conflicts of interest.

## REFERENCES

1. Edidin AA, Ong KL, Lau E, Kurtz SM. Life expectancy following diagnosis of a vertebral compression fracture. *Osteoporos Int* 2013;24:451-8.
2. Bonnick SL. Osteoporosis in men and women. *Clin Cornerstone* 2006;8:28-39.
3. Garfin SR, Yuan HA, Reiley MA. New technologies in spine: Kyphoplasty and vertebroplasty for the treatment of painful osteoporotic compression fractures. *Spine (Phila Pa 1976)* 2001;26:1511-5.
4. McKiernan F, Faciszewski T, Jensen R. Quality of life following vertebroplasty. *J Bone Joint Surg Am* 2004;86-A: 2600-6.
5. Garfin SR, Buckley RA, Ledlie J; Balloon Kyphoplasty Outcomes Group. Balloon kyphoplasty for symptomatic vertebral body compression fractures results in rapid, significant, and sustained improvements in back pain, function, and quality of life for elderly patients. *Spine (Phila Pa 1976)* 2006;31:2213-20.
6. Hulme PA, Krebs J, Ferguson SJ, Berlemann U. Vertebroplasty and kyphoplasty: A systematic review of 69 clinical studies. *Spine (Phila Pa 1976)* 2006;31:1983-2001.
7. Prather H, Van Dillen L, Metzler JP, Riew KD, Gilula LA. Prospective measurement of function and pain in patients with non-neoplastic compression fractures treated with vertebroplasty. *J Bone Joint Surg Am* 2006;88:334-41.
8. Gerling MC, Eubanks JD, Patel R, Whang PG, Bohlman HH, Ahn NU. Cement augmentation of refractory osteoporotic vertebral compression fractures: Survivorship analysis. *Spine (Phila Pa 1976)* 2011;36:E1266-9.
9. Heo DH, Chin DK, Yoon YS, Kuh SU. Recollapse of previous vertebral compression fracture after percutaneous vertebroplasty. *Osteoporos Int* 2009;20:473-80.
10. Kim YY, Rhyu KW. Recompression of vertebral body after balloon kyphoplasty for osteoporotic vertebral compression fracture. *Eur Spine J* 2010;19:1907-12.
11. Fribourg D, Tang C, Sra P, Delamarter R, Bae H. Incidence of subsequent vertebral fracture after kyphoplasty. *Spine (Phila Pa 1976)* 2004;29:2270-6.
12. Lindsay R, Silverman SL, Cooper C, Hanley DA, Barton I, Broy SB, *et al.* Risk of new vertebral fracture in the year following a fracture. *JAMA* 2001;285:320-3.
13. Legroux-Gérot I, Lormeau C, Boutry N, Cotten A, Duquesnoy B, Cortet B. Long term followup of vertebral osteoporotic fractures treated by percutaneous vertebroplasty. *Clin Rheumatol* 2004;23:310-7.
14. Rho YJ, Choe WJ, Chun YI. Risk factors predicting the new symptomatic vertebral compression fractures after percutaneous vertebroplasty or kyphoplasty. *Eur Spine J* 2012;21:905-11.
15. Han SL, Wan SL, Li QT, Xu DT, Zang HM, Chen NJ, *et al.* Is vertebroplasty a risk factor for subsequent vertebral fracture, meta-analysis of published evidence? *Osteoporos Int* 2015;26:113-22.