

Case Report

## Two novel mutations of lecithin:cholesterol acyltransferase (*LCAT*) gene and the influence of *APOE* genotypes on clinical manifestations

Akihiro Katayama<sup>1</sup>, Jun Wada<sup>1</sup>, Hitomi Usui Kataoka<sup>2</sup>, Hiroko Yamasaki<sup>1</sup>, Sanae Teshigawara<sup>1</sup>, Takahiro Terami<sup>1</sup>, Kentaro Inoue<sup>1</sup>, Motoko Kanzaki<sup>1</sup>, Kazutoshi Murakami<sup>1</sup>, Atsuko Nakatsuka<sup>1</sup>, Hitoshi Sugiyama<sup>1</sup>, Norio Koide<sup>3</sup>, Hideaki Bujo<sup>4</sup> and Hirofumi Makino<sup>1</sup>

<sup>1</sup>Department of Medicine and Clinical Sciences, Okayama University Graduate School of Medicine, Dentistry and Pharmaceutical Sciences, Okayama, Japan, <sup>2</sup>Department of Primary Care and Medical Education, Okayama University Graduate School of Medicine, Dentistry and Pharmaceutical Sciences, Okayama, Japan, <sup>3</sup>Department of Laboratory Medicine, Okayama University Graduate School of Medicine, Dentistry and Pharmaceutical Sciences, Okayama, Japan and <sup>4</sup>Department of Genome Research and Clinical Application, Graduate School of Medicine, Chiba University, Chiba, Japan

Correspondence and offprint requests to: Jun Wada; E-mail: junwada@md.okayama-u.ac.jp

### Abstract

Familial lecithin:cholesterol acyltransferase deficiency (FLD) is an autosomal recessive disorder characterized by corneal opacity, hemolytic anemia, low high-density lipoprotein cholesterol (HDL-C) and proteinuria. Two novel lecithin:cholesterol acyltransferase (*LCAT*) mutations [c.278 C>T (p.Pro69Leu); c.950 T>C (p.Met293Thr)] were identified in a 27-year-old man and in a 30-year-old woman, respectively. Both patients manifested corneal opacity, hemolytic anemia, low low-density lipoprotein cholesterol and HDL-C and proteinuria. Lipid deposits with vacuolar lucent appearance in glomerular basement membranes were observed in both cases. *APOE* genotype was also investigated: the first case results  $\epsilon 4/\epsilon 3$ , the second  $\epsilon 2/\epsilon 2$ ; however, they shared a similar phenotype characterized by the presence of intermediate-density lipoproteins (IDL) remnant and the absence of lipoprotein-X. In conclusion, our findings suggest that *APOE*  $\epsilon 2/\epsilon 2$  may not be the major determinant gene for the appearance of IDL in FLD patients.

**Keywords:** *APOE* genotype; familial *LCAT* deficiency (FLD); IDL remnant; lipoprotein-X

### Background

Mutations in the lecithin:cholesterol acyltransferase (*LCAT*) gene cause either familial lecithin:cholesterol acyltransferase deficiency (FLD) (OMIM# 245900) or fish-eye disease (FED, OMIM# 136120) [1]. FLD patients are characterized by a significant reduction in serum high-density lipoprotein cholesterol (HDL-C) level, corneal opacity, normochromic anemia and proteinuria with progression to end-stage renal disease [1, 2]. Plasma low-density lipoprotein cholesterol (LDL-C) levels are widely variable among FLD patients

although plasma *LCAT* activity catalyzing HDL (*LCAT* $\alpha$  activity) and catalyzing apolipoprotein B containing lipoproteins (*LCAT* $\beta$  activity) is absent or nearly absent. The loss of *LCAT* activity leads to increased levels of phosphatidylcholine and free cholesterol (FC) in the blood and to the formation of an abnormal lipoprotein called lipoprotein-X (Lp-X). As a result, accumulation of FC occurs in various tissues, including the cornea, erythrocyte membrane and the kidney [3]. Recent report suggests an etiological role for Lp-X in the development of glomerulosclerosis [4].

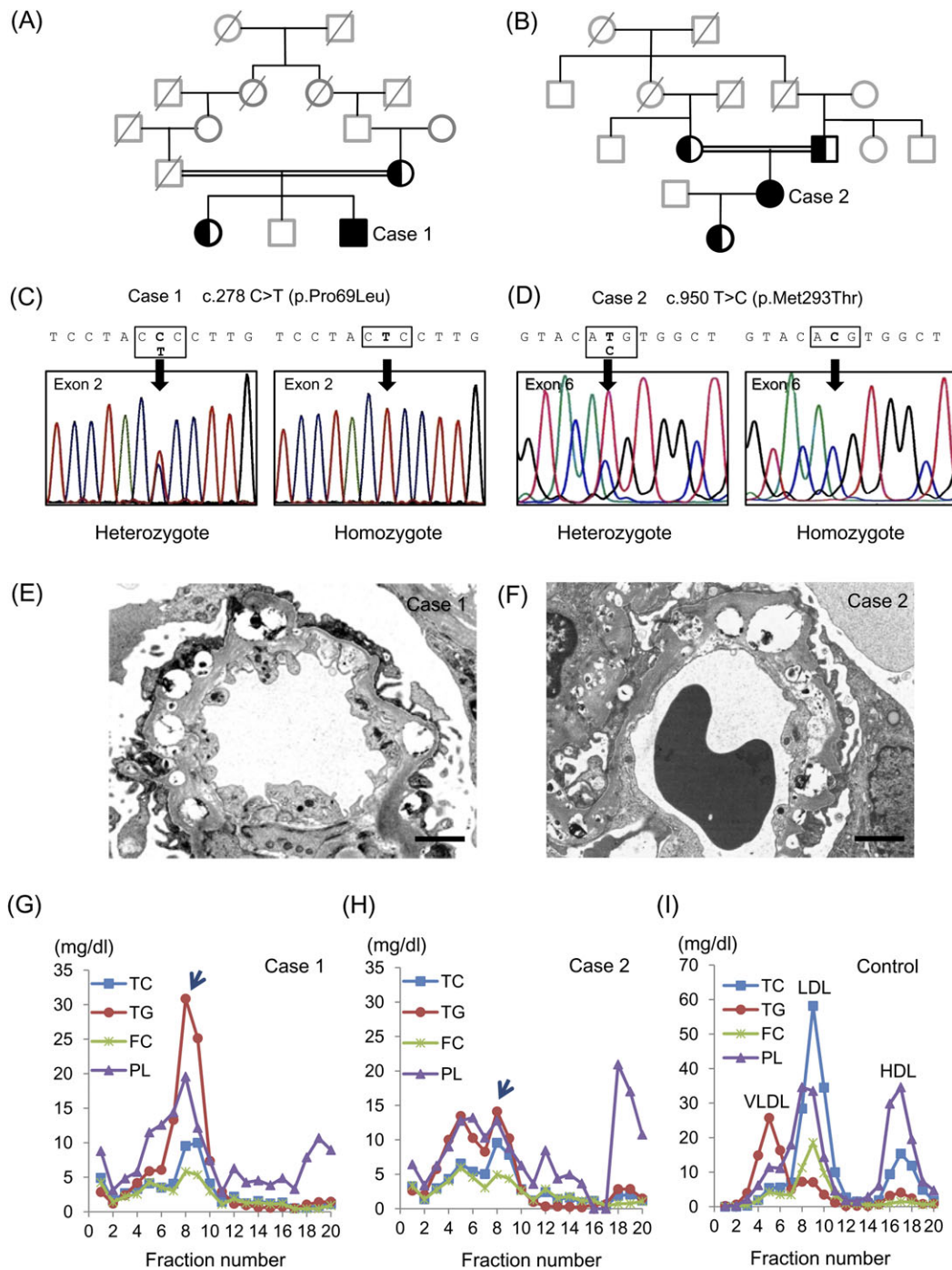
Here, we describe two novel mutations of *LCAT* gene, a C to T transition in Exon 2 converting proline 69 to leucine (Pro69Leu) and a T to C transition in Exon 6 converting methionine 293 to threonine (Met293Thr). Since Baass *et al.* [5] hypothesized that the presence of the *APOE*  $\epsilon 2$  allele contributed to the accumulation of intermediate-density lipoprotein (IDL) in the patients with *LCAT* deficiency, we investigated their *APOE* genotypes and phenotypic manifestations of the patients with FLD.

### Case reports

#### Case presentation

**Case 1.** A 27-year-old Japanese man was referred to Okayama University Hospital because he had extremely low HDL-C and LDL-C concentrations. On physical examination, he showed bilateral corneal opacity, but no other abnormal findings. Laboratory findings demonstrated a mild degree of normochromic-normocytotic anemia (11.3 g/dL). Although his renal function was normal, (+1) proteinuria was revealed via the dipstick method (0.21 g/day). The consanguinity was found in his parents as shown in Figure 1A.

**Case 2.** A 30-year-old Japanese woman was referred because of very low HDL-C and LDL-C associated with (1+)



**Fig. 1.** Presented cases with FLD. (A, B) Family trees of Cases 1 and 2. Squares are male, circles are female. Filled symbols indicate homozygous carriers and left filled symbols indicate heterozygous carriers. The deceased subjects are indicated with the oblique lines. Members without genetic analysis are presented in gray tone. The consanguinity of patients' parents are indicated by doubled line. (C, D) Determination of the *LCAT* gene sequences of proband and their families. Heterozygous mutation of mother and elder sister and homozygous mutation of proband are shown in Cases 1 (C) and 2 (D). (E, F) Renal biopsy findings of Cases 1 and 2. Electron micrograph shows lipid deposits with a vacuolar lucent appearance in the GBM (bar = 2  $\mu$ m). (G–I) High-performance liquid chromatography patterns of Cases 1 (G), 2 (H) and normal healthy control (I).

proteinuria via dipstick (0.08 g/day). She also showed bilateral corneal opacity and mild hemolytic anemia (11.2 g/dL), demonstrating target cells on her peripheral blood smear. Her renal function was within normal range. She was a daughter of consanguineous parents (Figure 1B).

#### *Sequencing of LCAT gene, renal biopsy findings and LCAT activity*

Direct sequencing of *LCAT* gene and comparison with reference sequence (NM\_000229) revealed that Case 1 had a C to T nucleotide substitution in Exon 2 resulting

in Pro69Leu [c.278 C>T (p.Pro69Leu)] (Figure 1C) and Case 2 had a T to C substitution in Exon 6 resulting in Met293Thr mutations [c.950 T>C (p.Met293Thr)] (Figure 1D). Both cases showed homozygous mutation and their parents showed heterozygous mutation. We further examined the APOE genotype of the presented cases. Case 1 carried APOE  $\epsilon 4/\epsilon 3$  genotype, whereas Case 2 carried APOE  $\epsilon 2/\epsilon 2$  genotype (Table 1). The mother of Case 1 carried APOE  $\epsilon 3/\epsilon 3$  genotype and genomic DNAs were not available from the deceased father. The parents of Case 2 carried APOE  $\epsilon 3/\epsilon 2$  genotype. Renal biopsy in both cases revealed similar histological findings; diffuse vacuolization of the glomerular basement membranes (GBM) by periodic acid-methenamine silver stain and lipid deposits with a vacuolar lucent appearance in the mesangial matrix and the GBM by electron microscopy (Figure 1E and F). In both cases, half normal LCAT activity was observed by using exogenous substrate, suggesting the diagnosis of FED. However, clinical manifestations with hemolytic anemia and renal involvement coincided with the features of FLD.

#### Plasma lipids and lipoproteins

Both Cases 1 and 2 revealed similar lipid profile; LDL-C and HDL-C were extremely low (Table 1). Furthermore, FC/total cholesterol (TC) ratio was much higher than normal value, suggesting reduced activity of esterification of plasma cholesterol due to LCAT deficiency. In both cases, the lipoproteins in fraction 7–10, corresponding to IDL particle size, were characterized by triglycerides (TG)- and phospholipid (PL)-rich. Since Lp-X is FC- and PL-rich lipoprotein particle, the peaks appeared in fraction 7–10 seem to be remnant lipoproteins containing IDL remnant (Figure 1G and H; arrows). In addition, Lp-X was not detected by agarose gel electrophoresis in both cases. The remnant-like particles cholesterol was measured with MetaboLead RemL-C well-reflects IDL remnant compared with immunoseparation assay, the high values of RemL-C in both cases also support the elevation of IDL remnant.

## Discussion

Lynn *et al.* [6] recently reported that accumulation of Lp-X in renal lesion can stimulate monocyte chemoattractant protein-1 expression in mesangial cells via nuclear factor- $\kappa$ B. Nishiwaki *et al.* [7] reported Lp-X is larger than normal LDL-C in size, and the percentages for TG, cholesteryl ester, FC and PL were 9.5, 6.2, 27.6 and 56.8% in Lp-X, respectively. In our cases, we found TG- and PL-rich remnant IDL particles, where TC and FC contents are very low. Previous research has observed that APOE  $\epsilon 2$  allele carriers reveal decreased LDL-C and increased TG and lipoprotein remnants, whereas APOE  $\epsilon 4$  carriers have increased LDL-C and TG in comparison to  $\epsilon 3/\epsilon 3$  subjects [8, 9]. It has been suggested that lipoproteins of  $\epsilon 2$  carriers have a low affinity for lipoprotein receptors, which induces decreased cholesterol delivery to the hepatocytes and a following upregulation of hepatic sterol synthesis and LDL receptors [10]. Therefore, a decreased conversion of very low-density lipoprotein into LDL and appearance of IDL is observed in  $\epsilon 2$  carriers. Baass *et al.* [5] hypothesized that the presence of the APOE  $\epsilon 2$  allele contributed to the accumulation of IDL instead of Lp-X in the patients with LCAT deficiency, but IDL remnant is even higher in Case 1 carrying APOE  $\epsilon 4/\epsilon 3$  genotype compared with Case 2 with APOE  $\epsilon 2/\epsilon 2$  genotype (Figure 1G and H). The discrepancy of these observations may attribute to the difference in mutations of LCAT gene rather than APOE genotype and further characterization of enzymatic activities of mutated gene products is required in future investigations.

In conclusion, we describe two unrelated FLD patients with corneal opacity, hemolytic anemia, abnormalities in serum lipoprotein profile and lipid accumulation in GBM. Instead of Lp-X, we detected IDL remnant in both cases and similar pathological findings in renal biopsy. Genotyping APOE gene revealed APOE  $\epsilon 4/\epsilon 3$  in Case 1 and a rare association of APOE  $\epsilon 2/\epsilon 2$  in Case 2, thus APOE  $\epsilon 2/\epsilon 2$  may not be the major modifier gene for the appearance of

**Table 1.** Characteristics and lipoprotein profiles of presented cases<sup>a</sup>

	Normal values	Case 1	Case 2	Mother of Case 2
Sex		Male	Female	Female
Age (years)		27	30	55
c.278 C>T (p.Pro69Leu)		Homozygous	none	none
c.950 T>C (p.Met293Thr)		none	Heterozygous	Heterozygous
Total cholesterol (mg/dL)	130–220	84	73	193
Triglycerides (mg/dL)	40–150	90	71	97
LDL-cholesterol (mg/dL) (direct homogenous assay)	70–139	28	24	126
HDL-cholesterol (mg/dL)	41–85	3	5	43
FC (mg/dL)	25–60	61	50	55
Cholesteryl ester (mg/dL)	90–200	23	23	138
FC/TC (%)	<28	72.6	68.5	28.4
RemL-C (mg/dL)	0.0–7.5	34.4	23.2	5.4
Phospholipid (mg/dL)	150–250	157.8	178.3	ND
Apo A-I (mg/dL)	119–155	46	69	124
Apo A-II (mg/dL)	25.9–35.7	5.3	5.1	28.3
Apo B (mg/dL)	73–109	60	40	113
LCAT activity (nmol/mL/h/37°C)	M 67.3–108.2 F 53.3–95.5	31.7	29.4	ND
APOE genotype		$\epsilon 4/\epsilon 3$	$\epsilon 2/\epsilon 2$	$\epsilon 3/\epsilon 2$

<sup>a</sup>RemL-C, remnant-like particles cholesterol measured with MetaboLead RemL-C; ND, not determined.

IDL in FLD patients. More cases need to be investigated to draw the definitive conclusions on the relation among *LCAT* mutation, *APOE* genotype and lipoprotein profile in FLD patients.

## References

1. Kuivenhoven JA, Pritchard H, Hill J *et al.* The molecular pathology of lecithin:cholesterol acyltransferase (LCAT) deficiency syndromes. *J Lipid Res* 1997; 38: 191–205
2. Funke H, von Eckardstein A, Pritchard PH *et al.* Genetic and phenotypic heterogeneity in familial lecithin: cholesterol acyltransferase (LCAT) deficiency. Six newly identified defective alleles further contribute to the structural heterogeneity in this disease. *J Clin Invest* 1993; 91: 677–683
3. Guerin M, Dolphin PJ, Chapman MJ. Familial lecithin:cholesterol acyltransferase deficiency: further resolution of lipoprotein particle heterogeneity in the low density interval. *Atherosclerosis* 1993; 104: 195–212
4. Lambert G, Sakai N, Vaisman BL *et al.* Analysis of glomerulosclerosis and atherosclerosis in lecithin cholesterol acyltransferase-deficient mice. *J Biol Chem* 2001; 276: 15090–15098
5. Baass A, Wassef H, Tremblay M *et al.* Characterization of a new *LCAT* mutation causing familial *LCAT* deficiency (FLD) and the role of *APOE* as a modifier gene of the FLD phenotype. *Atherosclerosis* 2009; 207: 452–457
6. Lynn EG, Siow YL, Frohlich J *et al.* Lipoprotein-X stimulates monocyte chemoattractant protein-1 expression in mesangial cells via nuclear factor-kappa B. *Kidney Int* 2001; 60: 520–532
7. Nishiwaki M, Ikewaki K, Bader G *et al.* Human lecithin:cholesterol acyltransferase deficiency: in vivo kinetics of low-density lipoprotein and lipoprotein-X. *Arterioscler Thromb Vasc Biol* 2006; 26: 1370–1375
8. Heeren J, Beisiegel U, Grewal T. Apolipoprotein E recycling: implications for dyslipidemia and atherosclerosis. *Arterioscler Thromb Vasc Biol* 2006; 26: 442–448
9. Topic A, Spasojevic Kalimanovska V, Zeljkovic A *et al.* Gender-related effect of apo E polymorphism on lipoprotein particle sizes in the middle-aged subjects. *Clin Biochem* 2008; 41: 361–367
10. Mahley RW, Rall SC Jr. Apolipoprotein E: far more than a lipid transport protein. *Annu Rev Genomics Hum Genet* 2000; 1: 507–537

Received for publication: 21.10.10; Accepted in revised form: 20.6.11