


# A successful management of late-presenting transposition with intact septum and severe coarctation of the aorta

SAGE Open Medical Case Reports  
Volume 8: 1–3  
© The Author(s) 2020  
Article reuse guidelines:  
sagepub.com/journals-permissions  
DOI: 10.1177/2050313X20956412  
journals.sagepub.com/home/sco



Pribadi Wiranda Busro<sup>1,2</sup>, Alvin Ariyanto Sani<sup>1,2</sup>   
and Michael Caesario<sup>1,2</sup>

## Abstract

A 13-week-old baby was referred with dextrocardia, situs inversus, transposition of the great arteries, intact ventricular septum, patent *foramen ovale*, right aortic arch with severe preductal aortic coarctation and large patent ductus arteriosus. Left ventricular mass index as well as thickness was adequate, 118 g/m<sup>2</sup> and 5.9 mm, respectively; thus, a primary arterial switch with aortic coarctation repair was performed. The patient made a full recovery without the need for extracorporeal life support. Adequate left ventricular mass index and thickness in late-presenting transposition of the great arteries with intact ventricular septum might justify primary arterial switch.

## Keywords

Arterial switch operation, late-presenting, transposition of the great arteries, intact ventricular septum

Date received: 2 June 2020; accepted: 10 August 2020

## Introduction

Primary arterial switch operation (ASO) is recommended to be performed in patients with transposition of the great arteries with intact ventricular septum (TGA-IVS) within 3 weeks of life, before the left ventricle becomes deconditioned to function as the systemic pumping ventricle.<sup>1</sup> We presented a case of late-presenting TGA-IVS successfully underwent primary ASO without the need of extracorporeal life support (ECLS). Written informed consent was obtained from the patient's parents for his anonymized information to be published in this article.

## Case report

A 13-week-old infant, 3.6 kg in weight and 52 cm in height, was referred to our institution. After chest X-ray and echocardiography, it was revealed that the patient had situs inversus, dextrocardia, TGA-IVS, patent *foramen ovale* (with bidirectional shunt), type A patent ductus arteriosus (PDA), and right aortic arch with preductal coarctation of the aorta. Interestingly, left ventricular mass index (LVMI) was 118 g/m<sup>2</sup> and end-diastolic LV posterior wall thickness (LVPWd) was 5.9 mm (Figure 1). The patient was admitted for 6 days in the pediatric intermediate ward and prepared for urgent surgical intervention.

We performed primary ASO and coarctation repair. End-to-side repair of severe preductal coarctation of the aorta was performed on aortic cross clamp. We encountered a single ostium coronary artery emerged from the left sinus and run transversely in front of the pulmonary artery. Primary ASO and LeCompte maneuver was performed followed by direct anastomosis of the neo-aorta and main pulmonary artery reconstruction with a preserved pericardial patch. The patient was successfully weaned from cardiopulmonary bypass (CPB) with aortic cross clamp and CPB time of 85 and 143 min, respectively. The chest was closed and the patient was transferred to the ICU without elective ECLS support.

The patient was extubated on postoperative day 2. Length of postoperative ICU stay was 4 days. Postoperative echocardiography assessment after surgery showed no pericardial

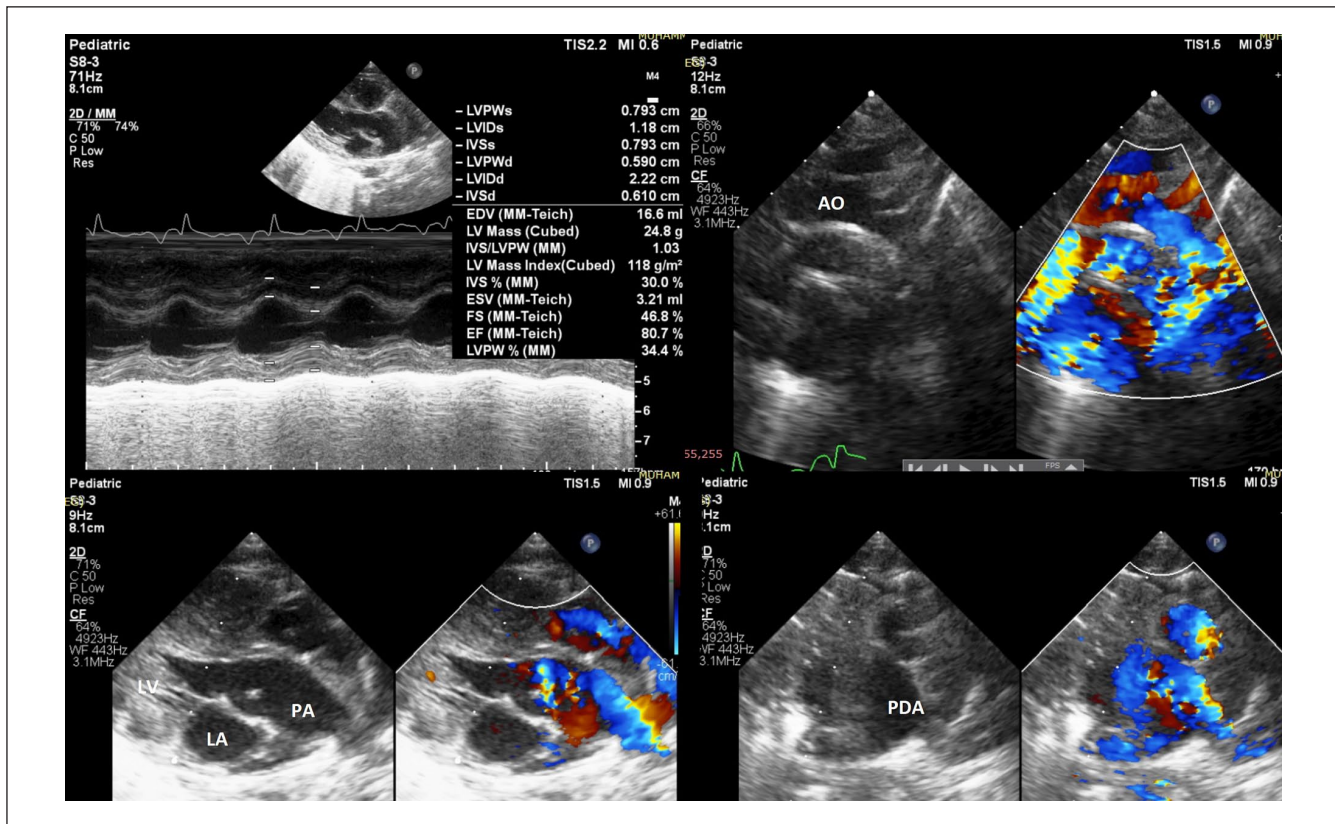
<sup>1</sup>Pediatric and Congenital Heart Surgery Unit, Department of Surgery, National Cardiovascular Center Harapan Kita, Jakarta, Indonesia

<sup>2</sup>Thoracic, Cardiac, and Vascular Surgery Division, Department of Surgery, Faculty of Medicine, Universitas Indonesia, Jakarta, Indonesia

## Corresponding Author:

Alvin Ariyanto Sani, Thoracic, Cardiac, and Vascular Surgery Division, Department of Surgery, Faculty of Medicine, Universitas Indonesia, Jl. Pangeran Diponegoro No. 71, RW 5, Kenari, Kec. Senen, Kota Jakarta Pusat, DKI Jakarta 10430, Indonesia.  
Email: sani.alvin@gmail.com





**Figure 1.** Preoperative echocardiography.

AO: aorta, LA: left atrium, LV: left ventricle, PA: pulmonary artery, PDA: patent ductus arteriosus.

effusion, good neo-aorta and neo-pulmonal anastomosis, no residual coarctation, as well as good contracting left and right ventricle (Figure 2). The patient was discharged on postoperative day 9.

## Discussion

After the first successful ASO in the 1980s,<sup>2,3</sup> this anatomical repair was prominently implemented despite the excellent survival of atrial switch repair for TGA-IVS at the time.<sup>4</sup> The procedure utilizes the morphologic left ventricle as the systemic ventricle hence avoiding late systemic ventricular and atrioventricular valve dysfunction and cardiac arrhythmias that were apparent in late follow-up of atrial switch repairs.<sup>5,6</sup>

The age limit for a primary ASO for TGA-IVS has been a matter of debate. Recent European guidelines stated that primary ASO should be considered up until 60 days of age with ECLS backup.<sup>1</sup> Primary ASO for late-presenting TGA-IVS (beyond 8 weeks old) had been reported to be done up to 9 months of age with postoperative ECLS backup<sup>7</sup> and the risk of prolonged hospital stay.<sup>8</sup>

Another option for late presenters is a two-stage approach which includes left ventricular training as the first stage followed by ASO. The criteria that justify this option are indexed left ventricular mass <35 g/m<sup>2</sup>, end-diastolic LV posterior wall thickness <4 mm, age above 3 weeks,

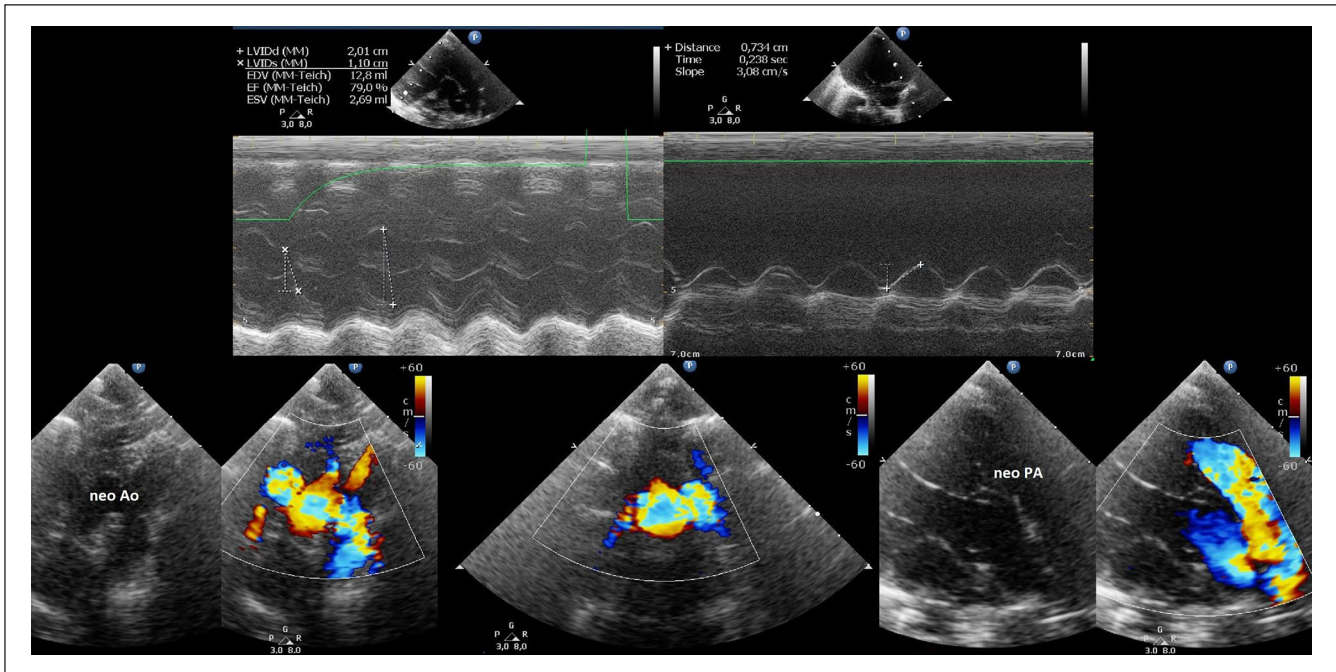
banana-like left ventricular shape on two-dimensional echocardiograms, and the absence of patent ductus arteriosus (PDA) or left ventricular outflow tract obstruction (preoperative pulmonary stenosis).<sup>1,9</sup>

In this case, however, the patient present at 13 weeks of age with a large-sized PDA and severe aortic coarctation. The large-sized PDA in this patient permits an unrestricted connection of the abnormally located great arteries hence prevents the progressive regression of left ventricular myocardial mass. This was proven by the preoperative echocardiographic findings of well-prepared ventricle for primary ASO (i.e. LVMI of 118 g/m<sup>2</sup> and (LVPWd) of 5.9 mm).

The postoperative course in this patient was uneventful. There was no need for postoperative ECLS support and the postoperative hospital length of stay was acceptable. This might be due to the optimal preoperative condition of the left ventricle, so that postoperative left ventricular failure was not encountered during the postoperative period.

## Conclusion

Late-presenting TGA-IVS can be safely treated with primary ASO as long as preoperative echocardiographic features are suitable. Associated anomalies such as PDA and severe aortic coarctation prevent LV mass regression which justify primary arterial switch in this subset of patient.



**Figure 2.** Postoperative echocardiography.  
neo Ao: neo-aorta; neo PA: neo-pulmonary artery.

### Acknowledgements

The authors wish to thank the parents of the patient described for allowing us to share his details and thank all nurses and physicians at the National Cardiovascular Centre *Harapan Kita*, Indonesia, for their contribution on the treatment of the patient.

### Author contributions

Pribadi Wiranda Busro, MD, PhD; Alvin Ariyanto Sani, MD; and Michael Caesario, MD, involved in drafting article, critical revision, and approval of article.

### Declaration of conflicting interests

The author(s) declared no potential conflicts of interest with respect to the research, authorship, and/or publication of this article.

### Ethical approval

Our institution does not require ethical approval for reporting individual cases or case series.

### Funding

The author(s) received no financial support for the research, authorship, and/or publication of this article.

### Informed consent

Written informed consent was obtained from the patient's parents for their anonymized information to be published in this article.

### ORCID iD

Alvin Ariyanto Sani  <https://orcid.org/0000-0003-4128-1729>

### References

1. Sarris GE, Balmer C, Bonou P, et al. Clinical guidelines for the management of patients with transposition of the great arteries with intact ventricular septum. *Eur J Cardiothorac Surg* 2017; 51: e1–e32.
2. Quaegebeur J, Rohmer J, Ottenkamp J, et al. The arterial switch operation: an eight-year experience. *J Thorac Cardiovasc Surg* 1986; 92(3 Pt 1): 361–384.
3. Castaneda A, Norwood W, Jonas R, et al. Transposition of the great arteries and intact ventricular septum: anatomical repair in the neonate. *Ann Thorac Surg* 1984; 38: 438–443.
4. Turley K, Hanley F, Verrier E, et al. The Mustard procedure in infants (less than 100 days of age). *J Thorac Cardiovasc Surg* 1988; 96(6): 849–853.
5. Hagler D, Ritter D, Mair D, et al. Right and left ventricular function after the Mustard procedure in transposition of the great arteries. *Am J Cardiol* 1979; 44: 276–283.
6. Gewilig M, Cullen S, Mertens B, et al. Risk factors for arrhythmia and death after Mustard operation for simple transposition of the great arteries. *Circulation* 1991; 84(Suppl. III): 187–192.
7. D'Udekem Y, Cheung M, Butt W, et al. Transposition with intact septum diagnosed at nine months: arterial switch? *Asian Cardiovasc Thorac Ann* 2012; 20(3): 333–334.
8. Kang N, De Leval MR, Elliott M, et al. Extending the boundaries of the primary arterial switch operation in patients with transposition of the great arteries and intact ventricular septum. *Circulation* 2004; 110: 123–127.
9. Nakazawa M, Oyama K, Imai Y, et al. Criteria for two-staged arterial switch operation for simple transposition of great arteries. *Circulation* 1988; 78(1): 124–131.