

A systematic approach to the management of microspherophakia

Prasanna Venkataraman, Aravind Haripriya, Neethu Mohan, Anand Rajendran

Microspherophakia is a rare developmental abnormality of the crystalline lens with a myriad of ocular and systemic associations. Glaucoma is a serious complication associated with this disorder. Early identification of the disease, timely visual rehabilitation, and appropriate management of the lens and glaucoma can help us prevent blindness from this condition. Multidisciplinary care with lifelong follow-up is recommended, as this typically affects the younger population. Current treatment protocols for this condition are mainly based on case reports and retrospective studies with shorter follow-up. Due to the rarity of this disease, designing a large randomized controlled trial to identify the merits and demerits of each management strategy is challenging. With cataract, glaucoma, and vitreoretinal specialists, each having their preferred way of managing microspherophakic lenses, we decided to do a comprehensive review of the existing literature to devise an integrated approach toward effective management of these patients. This review will collate all evidence and provide a very practical decision-making tree for its management.

Key words: Capsular Tension Ring, ectopia lentis, glaucoma, intraocular pressure, iris-fixated intraocular lens, microspherophakia, peripheral iridotomy, pupillary block, scleral-fixated intraocular lens, trabeculectomy

Microspherophakia is a rare congenital anomaly characterized by a spherical lens and lax zonules with associated subluxation or dislocation of the crystalline lens [Fig. 1]. The spherical configuration results from the increased anteroposterior diameter and reduced equatorial diameter of the lens, thereby resulting in the visibility of the lens equator on full mydriasis.^[1] Lenticular myopia, shallow anterior chamber, and angle closure glaucoma (ACG) characterize the hallmark triad of microspherophakia in a young patient.^[2] It is usually bilateral, and most patients have isolated microspherophakia. Weill–Marchesani syndrome (WMS)^[3] and homocystinuria^[4] are the most commonly reported systemic associations.

The treating physician is in a dilemma regarding the extraction of the subluxated lens via the limbal approach or simply referring to a vitreoretinal colleague for pars plana lensectomy (PPL). Each approach has its own merits and demerits, and as the zonular laxity is variable, there is no standard surgical technique. The type of presentation, associated glaucoma, and skill of the surgeon dictate the appropriate approach. With many isolated reports on success with different techniques, we did a comprehensive review of all the available evidence on the surgical management of microspherophakia and provide a decision-making tree for the management.

Pathology of Microspherophakia

The fetal lens is physiologically spherical. It is speculated that in spherophakia, the lens is never subjected to the force

of an optimally acting ciliary body and zonules.^[5] The long zonules, especially on the posterior lens surface, are often unattached to the ciliary processes. Because of the frailty of the zonules, these lenses are prone to dislocation into the anterior chamber or vitreous cavity, either spontaneously or with trivial trauma [Fig. 2].

The abnormal zonules can lead to the forward movement of the spherical lens, leading to acute pupillary block glaucoma.^[2,6] Continued unrecognized intermittent pupillary blocks can also result in permanent peripheral anterior synechiae (PAS) and trabecular damage, causing chronic ACG. Laser peripheral iridotomy (LPI) is a safer initial procedure to relieve the pupillary block. In selected cases with high intraocular pressure (IOP) and dislocated lens in the anterior chamber, intravenous mannitol, pharmacologic mydriasis, and making the patient lie supine may help in the repositioning of the lens posteriorly. These patients may require emergency lensectomy to prevent corneal decompensation and relieve the pupillary block.

Developmental abnormalities of the angle and secondary open-angle mechanisms of glaucoma have also been reported.^[7] It is hypothesized that LPI, by preventing intermittent pupillary block, can be helpful even in eyes with open angles. Laser and medical therapy are often not sufficient to control the IOP, as there are multiple mechanisms of glaucoma involved other than pupillary block.^[3,8]

This is an open access journal, and articles are distributed under the terms of the Creative Commons Attribution-NonCommercial-ShareAlike 4.0 License, which allows others to remix, tweak, and build upon the work non-commercially, as long as appropriate credit is given and the new creations are licensed under the identical terms.

For reprints contact: WKHLRPMedknow_reprints@wolterskluwer.com

Cite this article as: Venkataraman P, Haripriya A, Mohan N, Rajendran A. A systematic approach to the management of microspherophakia. Indian J Ophthalmol 2022;70:2262-71.

Access this article online

Website:

www.ijo.in

DOI:

10.4103/ijo.IJO_2888_21

Quick Response Code:



Glaucoma Services, Aravind Eye Hospital, Chennai, Tamil Nadu, India

Correspondence to: Dr. Prasanna Venkataraman, Glaucoma Services, Aravind Eye Hospital, Poonamallee High Road, Noombal, Chennai - 600 077, Tamil Nadu, India. E-mail: prasanna2006venkat@gmail.com

Received: 08-Feb-2022

Revision: 01-Mar-2022

Accepted: 12-Apr-2022

Published: 30-Jun-2022

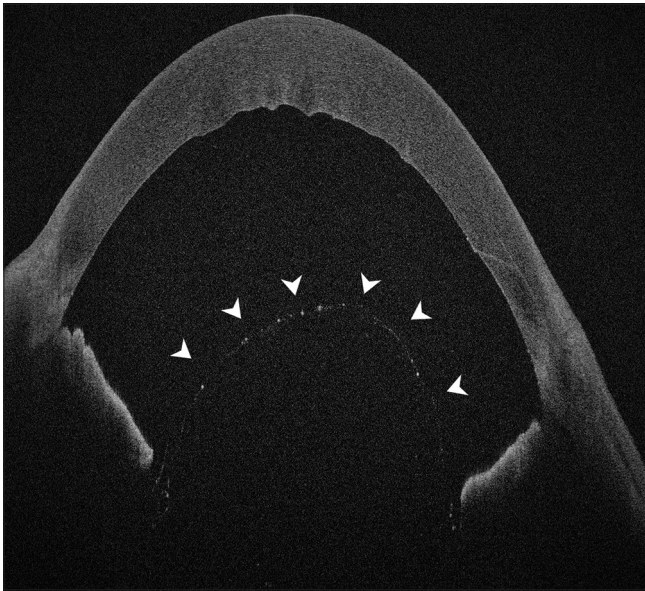


Figure 1: Anterior segment optical coherence tomography showing subluxated spherophakic lens (white arrowheads)

Lensectomy: The Good and Bad

Refractive lensectomy is a good surgical option to improve not only vision, but also the overall quality of life in these young patients. Lensectomy not only addresses myopia, but also the intermittent pupillary block resulting in glaucoma. Preserving the posterior capsule to maintain the separation between anterior and posterior compartments of the eye is critical to avoid the risk of vitreous loss, cystoid macular edema (CME), and retinal detachment (RD) in these susceptible individuals. In a study by Rao *et al.*, three eyes which developed choroidal detachment after lensectomy were managed conservatively and one eye had vision-threatening RD.^[9]

Lensectomy: The Decision-Making

Indications for lens surgery:

1. Significant diplopia not amenable to optical correction
2. The lens equator is at the pupil center with resultant ametropia
3. Progressive subluxation
4. Significant lens opacification
5. Serious complications occur, such as intermittent pupillary block, secondary glaucoma, posterior dislocation of the lens, lens in the anterior chamber with corneolenticular touch, and imminent complete luxation of the lens^[10,11]

The indication, timing, and mode of extraction of the subluxated/dislocated lens are debatable. Till date, there are no controlled trials or retrospective studies that have specifically identified an ideal age for intervention.^[12] Rao *et al.* reported a median age of 12 years (interquartile range [IQR]: 6–18 years) at lensectomy.^[9] Each surgical strategy has to be planned bearing in mind the risk of repeated anesthesia in children with systemic syndromes and the chance of amblyopia with suboptimal treatment.




Figure 2: Slit-lamp photograph showing subluxated lens (a) and weak zonular fibers in high magnification (b)

Surgical Strategies for Lens Surgery via the Limbal Approach

Hoffman *et al.*^[13] proposed the following classification for lens subluxation:

1. Mild – lens edge uncovers 0%–25% of the dilated pupil
2. Moderate – lens edge uncovers 25%–50% of the dilated pupil
3. Severe – lens edge uncovers greater than 50% of the pupil.

It would be prudent to examine these patients in the supine and sitting positions with the head tilted backward. This preoperative examination is critical as lenses that appear approachable with the patient in an upright position but subluxate further in the supine position are better managed with a PPL.^[13] The appropriate strategy has to be decided keeping in mind the progressive nature of the zonulopathy and the young age of the patient.

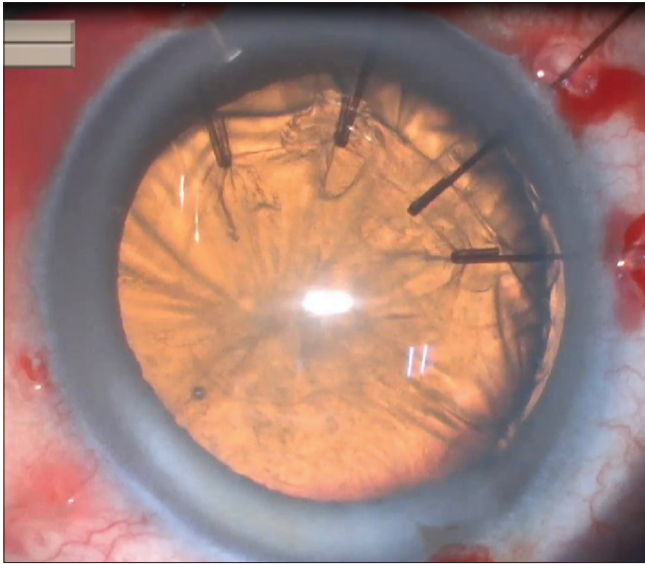


Figure 3: Intraoperative picture illustrating the use of iris hooks to support the capsular bag during phacoemulsification

Incision

Since scleral rigidity has to be taken into account, temporal clear corneal incisions can be employed in patients over 10 years of age. In younger children, superior scleral tunnel incision is preferred to ensure a watertight seal. It is advisable to place the incision in the quadrant away from zonular dehiscence to reduce the stress during phacoemulsification, but the surgeon should not compromise his ergonomics.

Ophthalmic viscosurgical device

Appropriate use of ophthalmic viscosurgical device (OVD) is important. Using dispersives to plug the area of zonular dehiscence even before initiating rhexis can prevent vitreous prolapse. If vitreous prolapse is noted, anterior vitrectomy is to be performed before proceeding to phacoemulsification to avoid undue vitreous traction.^[13] Initiating capsulorhexis under cohesive OVD can help flatten the elastic anterior capsule and prevent tear outs in these young patients with low scleral rigidity.

Capsulorhexis

An intact capsulorhexis is a prerequisite for any capsular support device. It is advisable to err on the side of small rhexis and enlarge later if required, to avoid peripheral tear outs. In subluxated lenses, one can start the capsulorhexis away from the area of zonular dialysis, so that adequate counter traction is provided by the remaining intact zonules. Mackool's capsular support system (Impex Surgical, Brooklyn, NY, USA: FCI Ophthalmics) or iris hooks can also be used to stabilize the capsular bag and provide counter traction during capsulorhexis [Fig. 3]. After the completion of capsulorhexis, a cortical cleaving hydrodissection can be performed either before or after implantation of the capsular support devices.

Endocapsular stabilization devices

The extent of subluxation/dislocation determines the choice of the operative procedure. The goal of the surgery is to prevent the worsening of preexisting subluxation and maintain capsular stability intraoperatively and for a long term. The capsular support devices along with appropriate phaco fluidics

can help stabilize and preserve the capsular bag even in severe zonular weakness.

Capsular tension ring (CTR; Morcher GmbH, Stuttgart, Germany) is a compressible, single-piece, incomplete, polymethylmethacrylate (PMMA) ring. This ring makes the weak bag taut, expands the fornices, and redistributes the mechanical forces centrifugally all around the equator, thus avoiding focal stress on zonules.^[14] It can be implanted at any stage after capsulorhexis as late as possible, but as soon as necessary. Early implantation offers good stability during phaco, but makes cortex removal slightly difficult due to the entrapment of cortex at the fornices.^[15] The selection of CTR size is based on capsular bag dimensions. Horizontal white-to-white and axial lengths determine the selection of the appropriate size of CTR.^[16] Though patients with microspherophakia have a small capsular bag with an average lenticular equatorial diameter of 6.75–7.5 mm, a standard size CTR can be comfortably placed inside.^[17] There appears to be no disadvantage to having too large a CTR in an eye, so many surgeons opt for placing the largest available CTR in all cases.^[18]

Mackool's capsular support system (Impex Surgical: FCI Ophthalmics), also known as capsule retention hooks, may be used together with CTR to stabilize the bag for surgery and delay CTR insertion until after the cortex has been removed.^[19] Unlike iris retractors, capsular retractors are designed not only to support the capsulorhexis, but also to support the capsular equator and to center the capsular bag.

Modified CTR (M-CTR, Morcher GmbH) is similar to the standard CTR, but can be used in more severe cases of lens subluxation. It has one or two fixation eyelets positioned anterior to the main ring to anchor the capsular bag to the scleral wall [Fig. 4]. One has to be meticulous during implantation, as implantation of the standard Cionni ring in a relatively small bag of these spherophakic lenses may lead to a capsular tear.

Ahmed capsular tension segments (CTS, Morcher GmbH) is a partial PMMA ring segment spanning 120° arc with a raised single eyelet, which can be suture fixated to the scleral wall. These devices combine the concept of M-CTR and capsular retractor and unlike CTR, can be inserted atraumatically even with a discontinuous anterior rhexis.^[20] It provides forces in a transverse plane rather than 360° circumferentially.

Both M-CTR and CTS can be used in extensive/progressive zonular weakness. Double-eyelet M-CTR is tricky to insert, and hence, many surgeons prefer a single-eyelet M-CTR with a CTS or a standard CTR with two CTS in these cases.^[21] An ab externo approach using 9-0/10-0 polypropylene (Prolene) or Gore-Tex suture is used to anchor these devices to the sclera.

Cionni *et al.* studied the effect of the M-CTR in 90 eyes with congenital loss of zonular support and reported that the M-CTR provided good centration of the capsular bag and Posterior chamber Intraocular lens (PCIOL) in over 94% of the cases and recommended using 9-0 Prolene rather than 10-0 suture for sclera fixation, as it is more sturdy.^[22] Anterior capsular tear, posterior capsular opacification (PCO), transient increase in the magnitude of subluxation during insertion, iritis, glaucoma, intraoperative suture-related complications, CME, and RD are some of the other complications one can encounter with these devices.

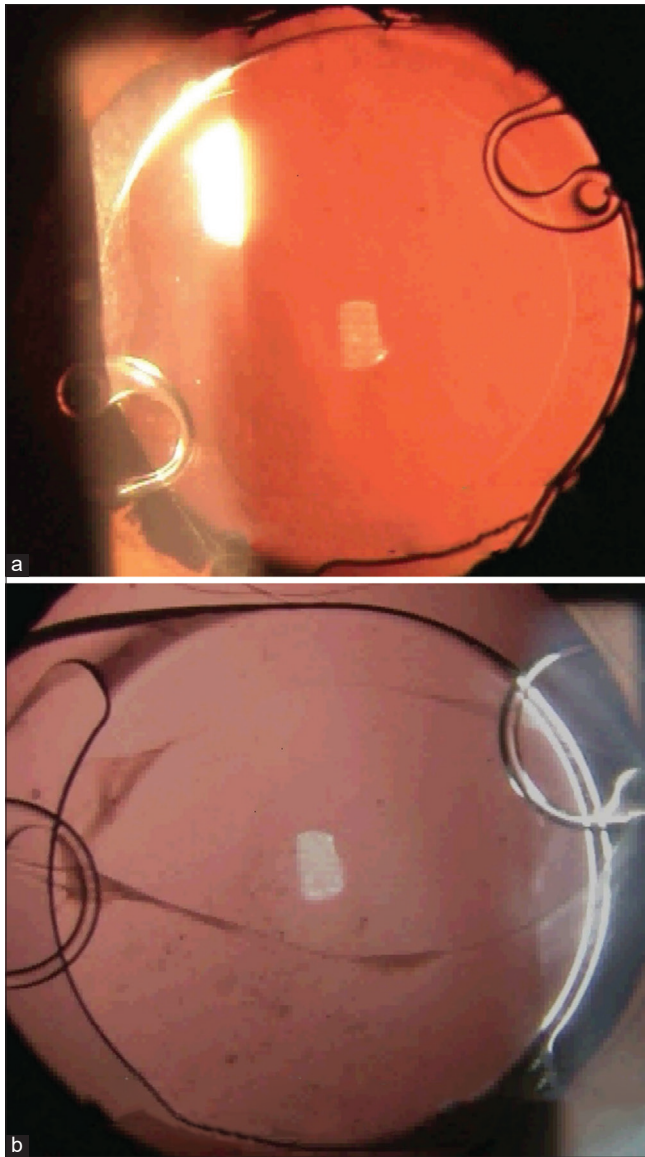


Figure 4: Postoperative images following successful implantation of capsular stabilization devices - postoperative day 1 (a) and late postoperative image of the other eye (b)

Kim *et al.*, in their retrospective series on outcomes of scleral-fixated capsular support devices in 19 pediatric eyes, reported well-centered intraocular lenses (IOLs) in all eyes, with over 94% of them achieving visual acuity better than 20/40.^[23] In another retrospective series with long-term follow-up, outcomes of pediatric patients having transscleral fixation of the capsular bag with IOL for ectopia lentis were analyzed. The authors reported that this technique improved visual acuity and IOL stability and supported its use as an alternative to aphakia, anterior chamber IOL (ACIOL), or scleral-fixated IOL (SFIOL).^[24]

Phacoaspiration

After capsule stabilization, multiquadrant gentle hydrodissection can reduce undue zonular tension. Most of the spherophakic lenses undergoing lensectomy are clear or have an early cataract, needing only safe irrigation aspiration (I/A) of the lenticular material under low fluidics with low bottle

height and vacuum settings. The cortex should be stripped along a vector tangential to the capsular bag fornices to decrease the risk of further zonular loss when the CTR has been used. Bimanual I/A is ideal in these challenging situations.

Once the bag is empty, cohesive viscoelastics can be used to inflate the bag and if a late CTR implantation is contemplated, it should be inserted with good counter-traction from capsular hooks that fix the bag to the eyewall securely. Otherwise, with the centrifugal motion of CTR, further subluxation of the already weak bag can occur with consequent vitreous loss. It is crucial to continuously refill the anterior chamber with viscoelastics to avoid aspirating the posterior capsule which can trampoline forward.

IOL implantation

With the development of new surgical techniques to support the bag and alternative IOL fixation methods, aphakia may not be an option, except in young infants. This also reduces the stress on the child and the parents for amblyopic management with spectacles and/or contact lenses which are poorly tolerated. However, the decision to implant an IOL has to be decided on a case-to-case basis, considering the degree of subluxation and surgeon's expertise. If the stability of the bag is ensured with good CTR/M-CTR support, a foldable hydrophobic acrylic IOL is the ideal choice. However, this may not be possible always and one has to resort to other IOL fixation techniques.

Iris-fixated IOL

With inadequate capsule or zonular support, the haptics of the IOL can be sutured to the iris or sclera, each having its pros and cons. Iris-fixated posterior chamber IOLs (IFIOL) have a negligible impact on refractive correction of the IOL as the effective lens position (ELP) of IFIOL is similar to in-the-bag IOLs. Furthermore, fixation of the flexible haptics to the iris creates a slight posterior vault, thus separating the optic from the posterior surface of the iris, reducing chaffing and pigment dispersion.

A three-piece foldable IOL (MA60AC [Alcon Fort Worth, TX, USA] or the AR40e [AMO Santa Clara, CA, USA]) can be iris-fixated at the haptics by McCannel sutures or Seipsler slipknots. A 10-0 polypropylene (CIF-4, Ethicon) or 10-0 polyester (PC-7, Alcon) suture with a long, curved needle is usually preferred. IFIOL technique is less demanding than SFIOLs because of the lack of scleral or conjunctival incisions and lower requirement for vitrectomy; therefore, it can be performed by an anterior segment surgeon comfortably.

Care must be taken to place the bites at mid-peripheral iris without excessive tension to avoid pupil peaking, iris chaffing, and consequent pigment dispersion. Though immediate pigment dispersion occurs perioperatively, progressive pigmentary glaucoma has not been identified as a common late complication.^[25] This technique is better avoided if insufficient iris tissue support is encountered.

Degradation of the Prolene suture is an important concern as this is the only anchor supporting the IOL to iris. However, unlike sclera-sutured IOLs, sutures of IFIOL are not subjected to the mechanical stress with lid closure and/or blinking. It is further suggested that the lower risk of late suture breakage may be the result of the fact that the elasticity of the peripheral iris provides a more forgiving suspension system than the

sclera.^[26] These sutures are in a less-dynamic and less-stressful environment and are therefore relatively more stable.

Yen *et al.* observed that there was a higher rate of IFIOL dislocation in patients with a history of ectopia lentis resulting from Marfan syndrome or hereditary or idiopathic causes than in patients being treated for aphakia resulting from other causes.^[27] In contrast, Dureau *et al.* reported good anatomical and functional results with well-centered IFIOLs in children with ectopia lentis.^[28] Median age at the time of IOL placement in these studies was 5.76 and 4.8 years with a mean follow-up of 12.48 and 16.3 months, respectively.^[27,28] Given the deficiency of knowledge in the literature regarding the time at which suture degradation occurs in IFIOLs and the consequences in these pediatric eyes, it will suffice to say that IFIOLs should be placed with caution in young children until further studies with longer follow-up are available.

Scleral-fixated IOL

SFIOL can be employed when there is insufficient capsular/zonular and iris support. Since this technique has minimal contact with the uveal tissue, one can expect less pigment dispersion compared to IFIOLs. After making two partial-thickness scleral flaps and a 6–7 mm scleral incision, two scleromies are made 1.5–2 mm posterior to the limbus. This landmark is crucial to implant the haptic and place the sutures in the area of the ciliary sulcus to help promote adequate scar formation and prevent future lens dislocation. A double-armed 10-0 Prolene suture with a straight needle (STC-6 needle; Ethicon, Somerville, NJ, USA) can then be used to fixate a PMMA IOL with fixation eyelets to the sclera. Subbiah *et al.* reported good control of IOP with no intraoperative or postoperative complications after sutured-SFIOL was used in their series of eight patients with microspherophakia.^[29] However, this technique can be associated with a variety of complications like IOL tilt, vitreous entrapment, PAS, suprachoroidal hemorrhage, vitreous hemorrhage, and RD.^[30]

The potential causes of dislocation of a scleral sutured IOL include suture degradation, suture breakage, suture erosion, untying of the knot, and slippage of the haptic from the suture. Late polypropylene suture degradation is an important concern in SFIOL and capsular support devices. The reported prevalence of suture erosion after sutured SFIOL ranges from 0% to 28.5%, which may increase the risk of suture tract endophthalmitis. The prevalence of suture breakage has been reported as high as 24%.^[31] Histopathology in cases of late dislocation 7–14 years after implantation has revealed degradation of the 10-0 polypropylene suture material without signs of untied knots, which may be accelerated with tension on the suspended sclerally fixated lens from eye movement and/or blinking.^[32] 10-0 Polypropylene can undergo hydrolytic degradation over time, leading to late IOL decentration.

Vote *et al.* reported 61 eyes with SFIOLs utilizing 10-0 Prolene sutures with a 27.9% suture breakage rate.^[33] Asadi and Kheirkhah evaluated the long-term results of sutured SFIOLs with 10-0 Prolene in 23 children.^[34] They reported late suture breakage in six of 25 eyes (24%) with breakage occurring 7–10 years postimplantation, and concluded that further research is needed to find an ideal method for fixation of IOL to the sclera. A survey of pediatric ophthalmologists' experience with suture breakage was performed in the same

study and it was found that over 70% of suture breakage occurred spontaneously with no obvious etiology such as trauma, after a mean duration of 5 years postoperatively. 10-0 Polypropylene suture had been used in all cases with suture breakage in this series.

Stewart and Landers recommended that 9-0 polypropylene suture used as an alternative to 10-0 polypropylene may reduce IOL dislocation due to the breakage of polypropylene sutures, because it has a 60% greater tensile strength, 50% greater diameter, and 125% greater cross-sectional area.^[35] In the literature to date, there are no reports on the interval before degradation of 9-0 Prolene suture.^[36] The only difficulty associated with the use of these sutures is the size of the knot being larger, requiring deeper burying to avoid conjunctival erosion and late endophthalmitis. However, follow-up in most of the reported studies is short to draw any meaningful conclusions regarding the true incidence of this late-onset complication. Currently, 9-0 Prolene suture is available with the CIF-4 needle, but not with the STC-6 needle.

Gore-Tex (W. L. Gore and Associates, Inc.) CV-8 expanded polytetrafluoroethylene is a nonabsorbable monofilament suture with greater tensile strength and longevity than Prolene. It is widely used in cardiovascular surgeries, but is not labeled for ophthalmic use yet. To date, this suture degradation has not been reported in the ophthalmic or non-ophthalmic literature. Khan *et al.* reported the 1-year outcomes of combined pars plana vitrectomy (PPV) and scleral fixation of an Akreos AO60 (Bausch and Lomb, Bridgewater, NJ, USA) or CZ70BD (Alcon Laboratories, Fort Worth, TX, USA) IOL using Gore-Tex suture. There were no cases of IOL dislocation, IOL decentration, IOL tilt, or suture breakage in their series of 148 eyes.^[37] The phenomenon of suture degradation is a special concern in pediatric patients, given their long life expectancy in decades.

In response to these concerns, a sutureless scleral fixation "glued IOL" technique had been described by Agarwal *et al.* Here, the haptics of a three-piece foldable IOL are externalized through scleromies under partial-thickness scleral flaps and tucked under scleral tunnels. The flaps are then secured using biological glue. This technique obviates suture-related complications like degradation, erosion, and late decentration. The intrascleral tissue is a good anatomical site because it is avascular and has a low tendency for inflammation. Though the use of these glued IOLs has been described in children, their long-term outcomes are unknown.^[38]

Kannan *et al.*,^[40] in a large series of 40 pediatric eyes with ectopia lentis, evaluated the safety and efficacy of the sutureless, glueless, intrascleral IOL fixation technique developed originally by Scharioth *et al.*^[39] The mean age of the study population was 13.4 ± 3.7 years, and the median follow-up was 1 year. The authors demonstrated a reduced risk of intraoperative and postoperative complications and reported that around 90% of eyes attained uncorrected visual acuity $\geq 20/60$ and had spherical equivalent less than 1 Dioptre (DS).^[40]

Anterior chamber IOL

Open-loop, angle-supported, ACIOL is the simplest surgical procedure for the correction of aphakia, but if not sized appropriately, it can lead to sight-threatening complications. Improper fit can lead to Uveitis Glaucoma Hyphema (UGH) syndrome, CME, and corneal decompensation. Khokhar

et al., in their prospective interventional study, reported success with implantation of ACIOL in 13 out of the 23 eyes that underwent lensectomy for microspherophakia.^[41] Determining the proper size of ACIOL in children with continuing eye growth is difficult. With other better options of IOL in these patients with a long life expectancy and the risk of glaucoma, ACIOLs may not be the best choice.^[42]

Iris-enclavated ACIOLs, such as the Artisan Aphakic IOL (Ophtec BV, Groningen, The Netherlands) has gained recent attention as it offers freedom from scleral suture fixation and its consequent problems in younger children. This IOL has a vault modification to create a distance from the iris to reduce pigment dispersion. When enclavated at the mid-peripheral iris, pupillary movements are relatively unaffected. Iris atrophy at the enclavation site, traumatic or accidental disenclavation of the haptics, pigment deposits on the IOL, secondary glaucoma, CME, and pupil deformation are some of the associated complications.

The reported risk of endothelial cell loss (ECL) after this IOL implantation in the literature is variable due to the differences in incisions, surgical technique, and duration of follow-up.^[31] Retropupillary enclavation is a safe alternative which reduces the chances of ECL. A randomized controlled trial comparing the outcomes and complication rates of IFIOL and iris claw IOL in subluxated lenses found no significant difference in terms of postoperative visual acuity and ECL.^[43]

Surgical Strategies for PPV with PPL

The standard setup for three-port PPV is used. Scleral indentation ensures complete removal of all cortex and capsule remnants. After core vitrectomy, a complete peripheral retinal examination is performed. Pars plana approach for lensectomy (PPL) is safe as it avoids vitreous incarceration and is the preferred method for posteriorly dislocated lenses.^[44] However, one must bear in mind that the pars plana does not reach adult proportions before 7 years of age, and also must exercise extreme caution to avoid complications like vitreous hemorrhage and RD in young children. Babu *et al.*, in a large retrospective study, reported the safety and efficacy of 23-gauge two-port PPL in 50 pediatric eyes with a mean follow-up of 14.3 months.^[45] Though the common practice is to go with SFIOL after PPV-PPL, one can consider IFIOLs too. A retrospective study analyzing the outcomes of PPV-PPL with and without IFIOL in children found IFIOLs can yield excellent visual outcomes that are at least as good as those obtained by optically correcting aphakia with spectacles or contact lenses.^[46] If glaucomatous optic neuropathy is advanced and needs concurrent management, one can implant glaucoma drainage devices and insert the tube via pars plana into the vitreous cavity in the same setting. This approach may yield better results than a concurrent trabeculectomy in eyes undergoing vitrectomy.

The Ideal Lensectomy Approach and IOL Fixation Technique

The anterior segment surgeon performing limbal lensectomy needs the aid of appropriate OVDs, hooks, rings, meticulous fluids, and IOL implantation technique to ensure long-term centration of the IOL-bag complex in these spherophakic eyes with progressive zonulopathy. The integrity of the posterior

capsule must be maintained to reduce the risk of posterior segment complications, especially in children with Marfan syndrome. A PPL with SFIOL, on the other hand, reduces the complexity of the surgery to some extent. So, how does one choose the appropriate route of lensectomy?

In a prospective, nonrandomized, interventional case series by Yang *et al.*, patients with spherophakia and secondary glaucoma were split into two groups and they underwent either phacoemulsification + CTR + IOL or PPL + SFIOL. The authors found that both techniques were effective in lowering the IOP and improving visual acuity over a follow-up period of 3 years.^[47] In another comparative study by Thapa *et al.*, 28 eyes of 14 children with a mean age of 8.06 ± 4.49 years underwent either phacoaspiration with Cionni ring-assisted PCIOL implantation or PPL + glued SFIOL for lens subluxation. The authors found no significant difference in the rates of complications at 1 year and concluded that the decision to choose either technique may be based on the operating surgeon's skill, experience, and preference.^[48]

A report from the American Academy of Ophthalmology reviewed the literature on open-loop ACIOL, IFIOL, and SFIOL implantation in the absence of capsule support and concluded that there was insufficient evidence to demonstrate the superiority of one lens type or fixation site over the other.^[36] Patient age, status of the cornea, angle, iris, and coexisting glaucoma are all important considerations in selecting the appropriate IOL fixation technique.

Surgical Management of Glaucoma: Trabeculectomy or Lensectomy?

Microspherophakia is a potentially blinding disease. In a retrospective study by Senthil *et al.*, it was found that 51% of the eyes with microspherophakia presented with glaucoma and 20%–30% of them were blind from glaucomatous optic neuropathy.^[3] In another study by Muralidhar *et al.*, the incidence of glaucoma was found to be 44.4%, the majority being ACG.^[4] Mean age of presentation of patients with microspherophakia has been reported to be around 16 and 19 years in various studies.^[3,4] Close to 90% of the individuals with glaucoma were younger than 30 years in a study, indicating the seriousness of this condition.^[3]

Willoughby and Wishart described a case of spherophakia with glaucoma, whose IOP was successfully controlled following lensectomy without additional medication.^[49] Harasymowycz and Wilson advocated a combination of lensectomy, anterior vitrectomy, sutured IOL, and Molteno tube shunt to successfully control IOP in advanced chronic ACG caused by microspherophakia.^[50] Dagi and Walton believed that early detection and prophylactic lensectomy alone could control IOP by preventing synechial angle closure.^[51] Khokhar *et al.*, in their prospective study on 26 eyes of 13 patients, concluded that lensectomy may be a viable option for controlling glaucoma. Of the 10 eyes that presented with glaucoma, only three required trabeculectomy to control the IOP further.^[41] Taylor reported good IOP control over 2 years in two spherophakic eyes after lensectomy and IOL implantation.^[52]

In contrast, Muralidhar *et al.*, in their retrospective analysis of 36 eyes of 18 patients followed over 8 years, found no protective role of lensectomy for glaucoma with no impact on IOP.^[4] Of the

16 eyes that underwent lensectomy, six had glaucoma. Yasar^[53] described a patient in whom IOP was not controlled with lensectomy in the short term, requiring mitomycin-C-augmented trabeculectomy in both eyes subsequently. Yang *et al.* reported the need for medical/surgical control of IOP in the long term after successful lensectomy and IOL implantation.^[47] Lensectomy alone cannot be effective if there is significant PAS or angle anomaly. Asaoka *et al.* performed trabeculectomy with Mitomycin C (MMC) and reported good control of IOP in a patient with microspherophakia and chronic ACG.^[54]

Trabeculectomy in spherophakic eyes has to be meticulous, keeping in mind the risk of postoperative complications like flat anterior chamber and malignant glaucoma. Care must be taken to avoid hypotony and intraoperative vitreous loss in these eyes with deficient zonules. Of the 48 eyes that required surgical intervention in a large retrospective study by Senthil *et al.*, 24 eyes underwent trabeculectomy. Though the authors reported higher trabeculectomy success rates (61% at 8 years), few cases had a persistent flat chamber, necessitating further

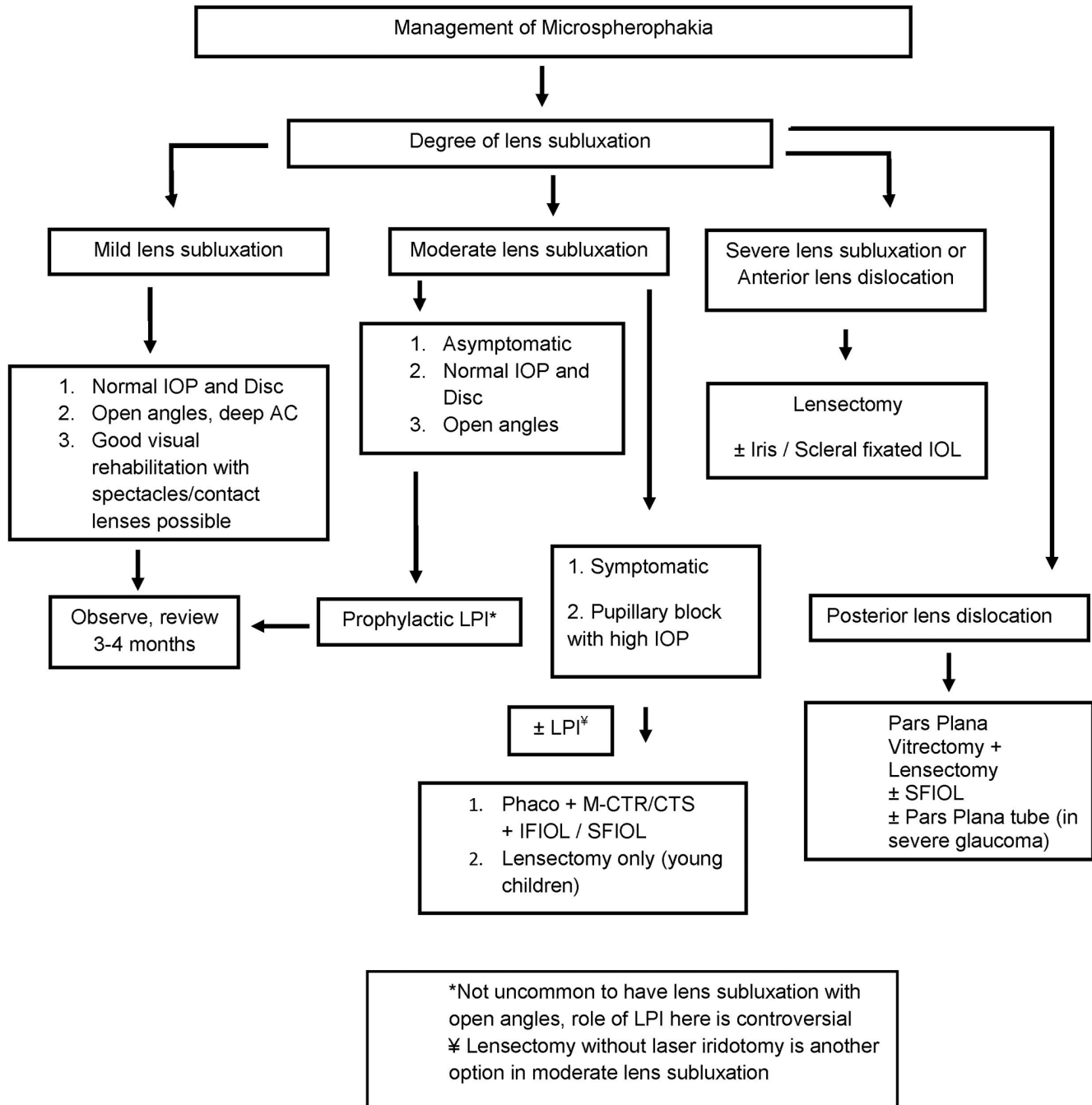


Figure 5: Decision tree for microspherophakia. CTS = capsular tension segment, IFIOL = iris-fixated IOL, IOL = intraocular lens, IOP = intraocular pressure, LPI = laser peripheral iridotomy, M-CTR = modified capsular tension ring, SFIOL = scleral-fixated IOL

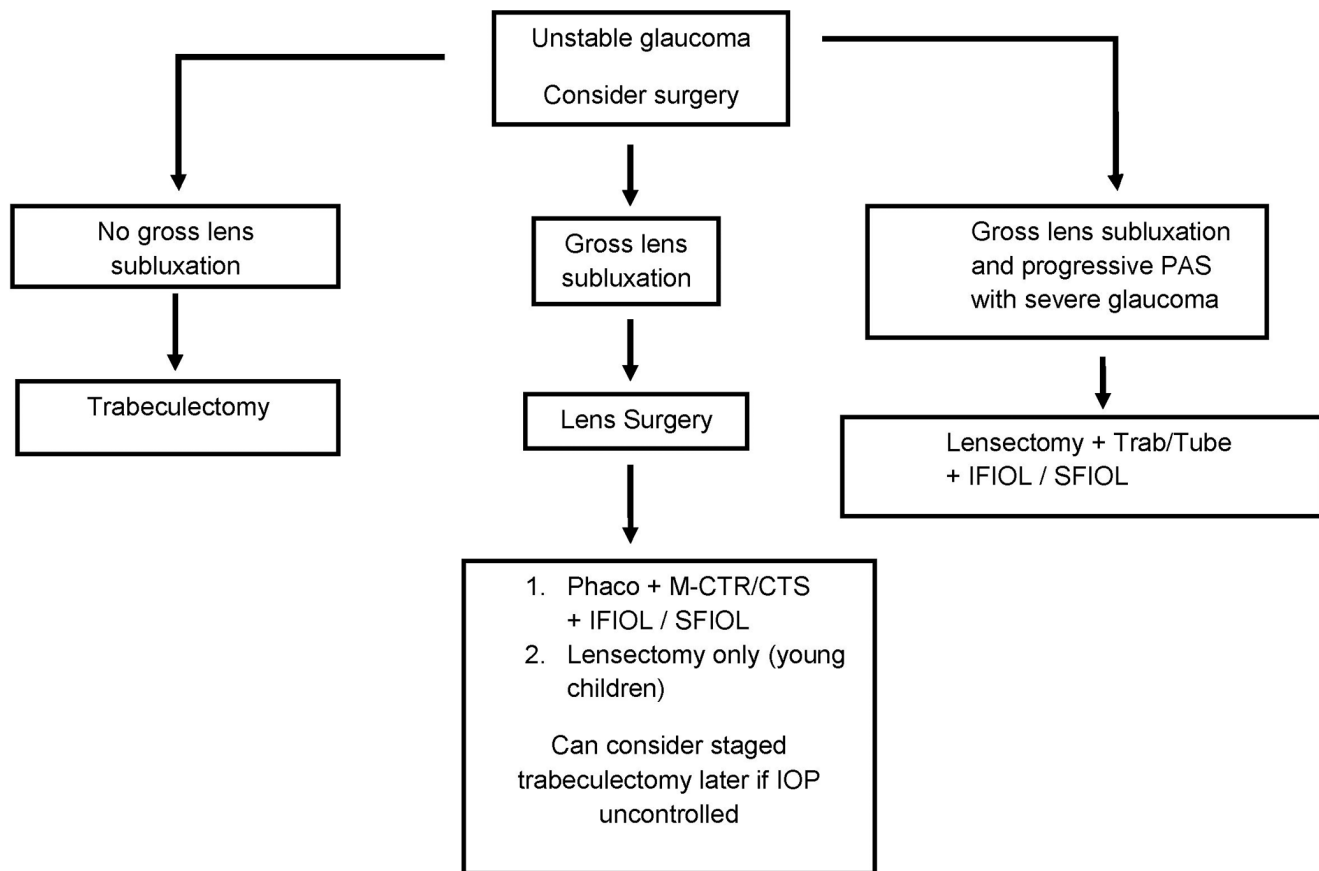


Figure 6: Decision tree for microspherophakia with glaucoma. PAS = peripheral anterior synechiae

surgical intervention.^[3] In the same study, of the 14 eyes that underwent PPL with anterior vitrectomy, 50% of eyes achieved IOP control, the rest needed medications to control IOP, and none required further surgical intervention.

Another study by Senthil *et al.* showed that, following trabeculectomy in spherophakic eyes with glaucoma, 45% (13/29) of the eyes required lensectomy later.^[55] It is interesting to note that the trabeculectomy in these studies was performed without adjunctive antimetabolites.^[3,55] The IOP was controlled without any medications in these eyes after lensectomy until the last follow-up. A majority of these eyes that underwent lensectomy had a subtle subluxation of the lens at the time of presentation, before trabeculectomy.

Rao *et al.* also analyzed the efficacy of lensectomy in spherophakic eyes with subluxated or dislocated lenses associated with glaucoma in a series of 52 eyes. They reported that the IOP was well controlled without medications in half of all eyes over a period of 5 years, and close to 40% eyes had IOP control with medications and only 7.7% eyes needed further surgical intervention for IOP control.^[9] Younger age and severe glaucoma at presentation predicted lensectomy failure and the need for further medical/surgical interventions to control IOP in their patients. The authors recommended that lensectomy be performed in eyes with lens subluxation/dislocation and high IOP, rather than trabeculectomy. In eyes with advanced glaucoma and gross lens subluxation, a combined lensectomy and

trabeculectomy/tube shunt would be a better option. It is critical to understand that the disease duration and the extent of angle damage also determine the final IOP, and hence, lensectomy alone may not offer relief in all cases.

With these mixed results, how does one decide to proceed with lensectomy or trabeculectomy or combine them both? If so, which is the best approach to extract the lens, limbal or pars plana? What is the best technique for primary IOL implantation? To answer these practical questions, we have formulated a decision tree collating all evidence from the current literature [Figs. 5 and 6].

Follow-Up and Visual Rehabilitation

It is critical to educate the patients regarding lifelong follow-up for monitoring of glaucoma and development of complications like IOL decentration and dislocation. The appropriate lens surgery and IOL fixation technique have to be selected, keeping in mind the progressive nature of the zonulopathy status of the posterior segment in microspherophakia. After surgery, the complex process of visual rehabilitation with spectacles/contact lens should begin, which requires frequent follow-up visits.

Conclusion

Microspherophakia is a rare, but potentially blinding disease with a variety of associated systemic syndromes and varied clinical presentations. Early identification of the disease,

timely visual rehabilitation, and appropriate management of the lens and glaucoma can help us prevent blindness from this condition. Multidisciplinary care with lifelong follow-up is recommended.

Methods of literature search

A comprehensive search of the ophthalmology literature through the PubMed database was carried out for the articles using the following search terms: microspherophakia, ectopia lentis, secondary glaucoma, intraocular pressure, pupillary block, peripheral iridotomy, capsular tension rings, phacoemulsification, intraocular lens, aphakia. Reference lists were reviewed for additional relevant articles. Only articles in English were considered. No constraints were placed on publication date.

Acknowledgement

We would like to thank Mrs Kumaragurupari, Chief librarian at the Aravind Eye Care System, for her expert assistance.

Financial support and sponsorship

Nil.

Conflicts of interest

There are no conflicts of interest.

References

- Chan RT, Collin HB. Microspherophakia. *Clin Exp Optom* 2002;85:294-9.
- Macken PL, Pavlin CJ, Tuli R, Trope GE. Ultrasound biomicroscopic features of spherophakia. *Clin Exp Ophthalmol* 1995;23:217-20.
- Senthil S, Rao HL, Hoang NT, Jonnadula GB, Addepalli UK, Mandal AK, *et al.* Glaucoma in microspherophakia: Presenting features and treatment outcomes. *J Glaucoma* 2014;23:262-7.
- Muralidhar R, Ankush K, Vijayalakshmi P, George VP. Visual outcome and incidence of glaucoma in patients with microspherophakia. *Eye (Lond)* 2015;29:350-5.
- Dietlein TS, Mietz H, Jacobi PC, Kriegelstein GK. Spherophakia, nanophthalmia, hypoplastic ciliary body, and glaucoma in brachydactyly-associated syndromes. *Graefes Arch Clin Exp Ophthalmol* 1996;234:187-92.
- Willi M, Kut L, Cotlier E. Pupillary-block glaucoma in the Marchesani syndrome. *Arch Ophthalmol* 1973;90:504-8.
- Feiler-Ofry V, Stein R, Godel V. Marchesani's syndrome and chamber angle anomalies. *Am J Ophthalmol* 1968;65:862-6.
- Ritch R, Chang BM, Liebmann JM. Angle closure in younger patients. *Ophthalmology* 2003;110:1880-9.
- Rao DP, John PJ, Ali MH, Kekunnaya R, Jalali S, Garudadri CS, *et al.* Outcomes of lensectomy and risk factors for failure in spherophakic eyes with secondary glaucoma. *Br J Ophthalmol* 2018;102:790-5.
- Wu-Chen WY, Letson RD, Summers CG. Functional and structural outcomes following lensectomy for ectopia lentis. *J AAPOS* 2005;9:353-7.
- Halpert M, BenEzra D. Surgery of the hereditary subluxated lens in children. *Ophthalmology* 1996;103:681-6.
- Simon MA, Origlieri CA, Dinallo AM, Forbes BJ, Wagner RS, Guo S. New management strategies for ectopia lentis. *J Pediatr Ophthalmol Strabismus* 2015;52:269-81.
- Hoffman RS, Snyder ME, Devgan U, Allen QB, Yeoh R, Braga-Mele R. Management of the subluxated crystalline lens. *J Cataract Refract Surg* 2013;39:1904-15.
- Leger U, Witschel BM, Lim SJ. "The capsular ring: A new device for complicated cataract surgery". Presented at the third American-International Congress on Cataract, IOL and Refractive Surgery. Seattle, Washington, May 11, 1993.
- Ahmed IK, Cionni RJ, Kranemann C, Crandall AS. Optimal timing of capsular tension ring implantation: Miyaki-Apple video analysis. *J Cataract Refract Surg* 2005;31:1809-13.
- Vass C, Menapace R, Schetterer K, Findl O, Rainer G, Steineck I. Prediction of pseudophakic capsular bag diameter based on biometric variables. *J Cataract Refract Surg* 1999;25:1376-81.
- Khokhar S, Gupta S, Kumar G, Rowe N. Capsular tension segment in a case of microspherophakia. *Cont Lens Anterior Eye* 2012;35:230-2.
- Riedel PJ, Samuelson TW. Capsular tension rings. In: Colvard DM, editor. *Achieving Excellence in Cataract Surgery: A Step-by-step Approach*; 2009. p. 116.
- Hasanee K, Butler M, Ahmed II. Capsular tension rings and related devices: Current concepts. *Curr Opin Ophthalmol* 2006;17:31-41.
- Hasanee K, Ahmed I, Kranemann C. "Capsular tension segment: Clinical results and complications". Presented at the American Academy of Ophthalmology Meeting. New Orleans, October 25, 2004.
- Ahmed IK, Butler M. Capsular tension devices for the glaucoma surgeon. *Glaucoma Today*. 2004. p. 1-4.
- Cionni RJ, Osher RH, Marques DM, Marques FF, Snyder ME, Shapiro S. Modified capsular tension ring for patients with congenital loss of zonular support. *J Cataract Refract Surg* 2003;29:1668-73.
- Kim EJ, Berg JP, Weikert MP, Kong L, Hamill MB, Koch DD, *et al.* Scleral-fixated capsular tension rings and segments for ectopia lentis in children. *Am J Ophthalmol* 2014;158:899-904.
- Byrd JM, Young MP, Liu W, Zhang Y, Tate DB, Crandall AS, *et al.* Long-term outcomes for pediatric patients having transscleral fixation of the capsular bag with intraocular lens for ectopia lentis. *J Cataract Refract Surg* 2018;44:603-9.
- Garcia-Rojas L, Paulin-Huerta JM, Chavez-Mondragon E, Ramirez-Miranda A. Intraocular lens iris fixation. Clinical and macular OCT outcomes. *BMC Res Notes* 2012;5:560.
- Condon GP, Masket S, Kranemann C, Crandall AS, Ahmed I. Small-incision iris fixation of foldable intraocular lenses in the absence of capsule support. *Ophthalmology* 2007;114:1311-8.
- Yen KG, Reddy AK, Weikert MP, Song Y, Hamill MB. Iris fixated posterior chamber intraocular lens in children. *Am J Ophthalmol* 2009;147:121-6.
- Dureau P, de Laage de Meux P, Edelson C, Caputo G. Iris fixation of foldable intraocular lenses for ectopia lentis in children. *J Cataract Refract Surg* 2006;32:1109-14.
- Subbiah S, Thomas PA, Jesudasan CA. Scleral-fixated intraocular lens implantation in microspherophakia. *Indian J Ophthalmol* 2014;62:596-600.
- Solomon K, Gussler JR, Gussler C, Van Meter WS. Incidence and management of complication of transsclerally sutured posterior chamber lenses. *J Cataract Refract Surg* 1993;19:488-93.
- Cheung CS, VanderVeen DK. Intraocular lens techniques in pediatric eyes with insufficient capsular support: Complications and outcomes. *Semin Ophthalmol* 2019;34:293-302.
- Price MO, Price FW Jr, Werner L, Berlie C, Mamalis N. Late dislocation of scleral-sutured posterior chamber intraocular lenses. *J Cataract Refract Surg* 2005;31:1320-6.
- Vote BJ, Tranos P, Bunce C, Charteris DG, Da Cruz L. Long-term outcome of combined pars plana vitrectomy and scleral fixated sutured posterior chamber intraocular lens implantation. *Am J Ophthalmol* 2006;141:308-12.
- Asadi R, Kheirkhah A. Long term results of scleral fixation of posterior chamber intraocular lenses in children. *Ophthalmology*

- 2008;115:67-72.
35. Stewart MW, Landers MB 3rd. Transscleral intraocular lens fixation with a "homemade" needle and hook. *J Cataract Refract Surg.* 2006; 32:200-2.
 36. Wagoner MD, Cox TA, Ariyasu RG, Jacobs DS, Karp CL. Intraocular lens implantation in the absence of capsular support: A report by the American Academy of Ophthalmology. *Ophthalmology* 2003;110:840-59.
 37. Khan MA, Samara WA, Gerstenblith AT, Chiang A, Mehta S, Garg SJ, *et al.* Combined pars plana vitrectomy and scleral fixation of an intraocular lens using gore-tex suture: One-year outcomes. *Retina* 2018;38:1377-84.
 38. Kumar DA, Agarwal A, Prakash D, Prakash G, Jacob S, Agarwal A. Glued intrascleral fixation of posterior chamber intraocular lens in children. *Am J Ophthalmol* 2012;153:594-601.
 39. Scharioth GB, Prasad S, Georgalas I, Tataru C, Pavlidis M. Intermediate results of sutureless intrascleral posterior chamber intraocular lens fixation. *J Cataract Refract Surg* 2010;36:254-9.
 40. Kannan NB, Kohli P, Pangtey BPSB, Ramasamy K. Evaluation of sutureless, glueless, flapless, intrascleral fixated posterior chamber intraocular lens in children with ectopia lentis. *J Ophthalmol* 2018;2018:3212740.
 41. Khokhar S, Pillay G, Sen S, Agarwal E. Clinical spectrum and surgical outcomes in spherophakia: A prospective interventional study. *Eye* 2018;32:527-36.
 42. Epley KD, Shainberg MJ, Lueder GT, Tychemsen L. Pediatric secondary lens implantation in the absence of capsular support. *J AAPOS* 2001;5:301-6.
 43. Hirashima DE, Soriano ES, Meirelles RL, Alberti GN, Nos'e W. Outcomes of iris claw anterior chamber versus iris-fixated foldable intraocular lens in subluxated lens secondary to Marfan syndrome. *Ophthalmology* 2010;117:1479-85.
 44. Anteby I, Isaac M, BenEzra D. Hereditary subluxated lenses; Visual performances and long-term follow-up after surgery. *Ophthalmology* 2003;110:1344-8.
 45. Babu N, Muraly P, Ramasamy K. Twenty-three-gauge two-port pars plana lensectomy for the management of ectopia lentis in children. *Retina* 2010;30:971-4.
 46. Kopel AC, Carvounis PE, Hamill B, Weikert MP, Hotz ER. Iris-sutured intraocular lenses for ectopia lentis in children. *J Cataract Refract Surg* 2008;34:595-600.
 47. Yang J, Fan Q, Chen J, Wang A, Cai L, Sheng H, *et al.* The efficacy of lens removal plus IOL implantation for the treatment of spherophakia with secondary glaucoma. *Br J Ophthalmol* 2016;100:1087-92.
 48. Thapa BB, Agarwal A, Singh R, Gupta PC, Ram J. Phacoaspiration with a Cionni ring versus pars plana lensectomy, vitrectomy and sutureless transscleral IOL fixation in pediatric patients with a subluxated lens. *Graefes Arch Clin Exp Ophthalmol* 2016;254:901-9.
 49. Willoughby CE, Wishart PK. Lensectomy in the management of glaucoma in spherophakia. *J Cataract Refract Surg* 2002;28:1061-4.
 50. Harasymowycz P, Wilson R. Surgical treatment of advanced chronic angle closure glaucoma in Weill-Marchesani syndrome. *J Pediatr Ophthalmol Strabismus* 2004;41:295-9.
 51. Dagi LR, Walton DS. Anterior axial lens subluxation, progressive myopia, and angle closure glaucoma: Recognition and treatment of atypical presentation of ectopia lentis. *J AAPOS* 2006;10:345-50.
 52. Taylor JN. Weill-Marchesani syndrome complicated by secondary glaucoma. Case management with surgical lens extraction. *Aust N Z J Ophthalmol* 1996;24:275-8.
 53. Yasar T. Lensectomy in the management of glaucoma in spherophakia: Is it enough? *J Cat Refract Surg* 2003;29:1052-3.
 54. Asaoka R, Kato M, Suami M, Usami Y, Hotta Y, Sato M. Chronic angle closure glaucoma secondary to frail zonular fibres and spherophakia. *Acta Ophthalmol Scand* 2003;81:533-5.
 55. Senthil S, Rao HL, Babu JG, Mandal AK, Addepalli UK, Garudadri CS. Outcomes of trabeculectomy in microspherophakia. *Indian J Ophthalmol* 2014;62:601-5.