


CLINICAL ARTICLE

Clinical Observations of Kümmell Disease Treatment Through Percutaneous Fixation Combined with Vertebroplasty

Dong-Hao Gan, MD^{1†} , Meng-Ze Fang, Master^{2†}, Hai-Peng Xue, MD^{1,3}, Guo-Qing Tan, MD³, Nian-Hu Li, MD³, Zhi-Chao Li, Master¹, Zhan-Wang Xu, MD^{1,3}

¹First College of Clinical Medicine and ²College of Traditional Chinese Medicine, Shandong University of Traditional Chinese Medicine and ³Department of Orthopedics, Affiliated Hospital of Shandong University of Traditional Chinese Medicine, Jinan, China

Objective: To explore the safety and efficacy of percutaneous pedicle screw fixation combined with vertebroplasty for the treatment of stage III Kümmell disease.

Methods: The clinical data and follow-up results of 22 patients with Kümmell disease who were admitted to our department from 2014 to 2018 were analyzed. There were 14 females and eight males, and the Age range was 58–81 years. All patients were followed up for 24 months. The treatment method was percutaneous pedicle screw fixation combined with vertebroplasty. The patient general information such as age, gender, bedrest time and location of fracture vertebrae were recorded. The clinical symptoms and imaging data of visual analogue scale (VAS), bone cement leakage, Oswestry Disability Index (ODI), Cobb angle, anterior, middle and posterior height of the diseased vertebral body, and complications were recorded before operation and during follow-up.

Results: For patients enrolled, no bone cement leakage was observed during the operation; no patients developed infections after operation. The operation was safe and resulted in a short bedrest time. The VAS score and ODI index at 3 and 24 months postoperative (2.86 ± 0.83 , $31.68\% \pm 6.21\%$; 3.0 ± 0.82 , $32.78\% \pm 6.05\%$) were significantly lower than that recorded preoperatively (7.59 ± 0.59 , $71.5\% \pm 8.84\%$) ($P < 0.05$). Additionally, there was no significant difference between the records at 3 and 24 months after operation ($P > 0.05$). Imaging data showed that the bone cement and screws were in good position and did not move during postoperative and follow-up. The anterior, middle and posterior height of the diseased vertebral body measured 2 days after surgery (23.46 ± 4.72 , 23.12 ± 3.05 , 25.81 ± 2.22) and at last follow-up (20.83 ± 4.48 , 21.78 ± 2.74 , 24.74 ± 1.93) were higher than that recorded preoperatively (13.08 ± 4.49 , 12.93 ± 3.53 , 19.32 ± 2.73) ($P < 0.05$), and the Cobb angle measured 2 days and 24 months after operation (9.57 ± 4.63 , 10.68 ± 3.97) were lower than that recorded preoperatively (28.24 ± 8.95) ($P < 0.05$), and no significant difference was found between the values recorded at 2 days and 24 months after operation ($P > 0.05$). Follow-up for 24 months, there was no re-fracture of the diseased vertebrae and internal fixation loosening, but two cases of adjacent vertebral refracture complications occurred, and the effect was good after PVP treatment.

Conclusion: Short-segment percutaneous pedicle screw fixation combined with vertebroplasty in the treatment of stage III Kümmell disease can effectively restore the height of the diseased vertebrae, kyphosis correction, reduce trauma, prevent the diseased vertebral body from collapsing again, and effectively improves clinical symptoms.

Key words: Clinical outcome; Kümmell disease; Osteoporosis; Percutaneous fixation; Vertebroplasty

Address for correspondence Zhan-Wang Xu, MD, Department of Orthopaedics, Affiliated Hospital of Shandong University of Traditional Chinese Medicine, 16369 Jingshi Road, Lixia District, Jinan, Shandong, China 250014. Tel: +86 0531 68617065; Fax: +86 0531 68616620; Email: xzw6001@163.com

Disclosure: The authors declare no conflict of interest. No benefits in any form have been, or will be, received from a commercial party related directly or indirectly to the subject of this manuscript.

[†]Dong-Hao Gan and Meng-Ze Fang contributed equally to this work.

Received 6 September 2020; accepted 27 December 2020

Introduction

The incidence rate of osteoporosis (OP) increases gradually with age¹, OP is a systemic skeletal disease characterized by destruction of bone microstructure and increased bone fragility, which eventually leads to increased risk of osteoporotic vertebral compression fractures (OVCF)². OVCF are mostly caused by trauma, and patients can generally adopt non-surgical therapies such as bed rest, drugs, external fixation braces, and so on, but there are still about 10% of patients who develop fracture nonunion^{3,4}, and this incidence may be underestimated. Kümmell disease, first identified by German surgeon Hermann Kümmell in the 19th century⁵, is a common complication of OVCF. It is mostly caused by prolonged non-healing of osteoporotic compression fractures⁶, which are characterized by signs of vacuum fissure, ischemia, and pseudoarticular formation^{5,7-9}, and often occurs in the thoracolumbar segment of the vertebral body.

Due to the cavity and pseudointerjoint, the vertebral body is unstable, as the disease progresses, patients with Kümmell will gradually develop symptoms such as progressive kyphosis, intractable back pain, or neurological deficits, which seriously affect the quality of life. For Kümmell's disease, non-surgical treatment is usually less effective and carries a risk of pneumonia, bedsores, venous thrombosis of the lower limbs, or delayed neurological deficits^{10,11}. At present, surgical treatment of Kümmell's disease is recommended. Combined with clinical symptoms and imaging evaluation, Kümmell's disease can be divided into three stages. Stage I: vertebral body height loss <20%, with or without back pain; stage II: vertebral body height loss >20%, with or without radiculopathy; and stage III: posterior vertebral cortical rupture with spinal cord compression¹². Surgical treatment of Kümmell's disease is aimed at restoring spinal stability and decompressing nerves. For patients with stage I and II Kümmell disease, Percutaneous vertebroplasty (PVP) or Percutaneous kyphoplasty (PKP) therapy can effectively relieve back pain and restore the height and stability of the diseased vertebral body^{13,14}. However, if it is not diagnosed and treated in time, as the disease progresses, these patients will gradually develop stage III symptoms, such as vertebral collapse, kyphosis, and even spinal nerve compression^{15,16}. Currently, different views exist regarding treatment options available for stage III Kümmell disease¹⁷. For patients with stage III Kümmell disease with spinal cord, neurological symptoms, and spinal instability, surgical treatment such as spinal canal decompression should be performed as soon as possible. However, the compression of the spinal cord and the appearance of symptoms are a gradual process. For this kind of patient who has no or only mild neurological symptoms in the early stage, the treatment principle is to restore the integrity and stability of the affected vertebra as soon as possible, and prevent delayed nerve injury.

For patients with no neurological symptoms or mild neurological symptoms, nerve decompression and kyphosis correction are difficult to achieve using single vertebroplasty¹⁸.

Moreover, due to posterior cortical fracture of diseased vertebral body, high-pressure injection is prone to leakage of bone cement into the spinal canal or blood vessels, leading to serious complications such as spinal cord nerve damage or pulmonary embolism¹⁹. Kümmell's disease is associated with OP and there is vertebral cavity or pseudarthrosis, which lead to instability of the diseased vertebrae. Screw loosening and fixation failure tend to occur in the late stage of simple vertebral screw correction and fixation²⁰, so this procedure is not suitable for Kümmell patients with no neurological symptoms or mild neurological symptoms in stage III. Screw fixation combined with vertebroplasty can not only restore the height of the vertebral body, correct the kyphosis, but also fill the vertebral body cavity, restore the stability of the vertebral body, and reduce the leakage of bone cement. However, the physical quality of elderly patients is poor, open reduction and internal fixation surgery have great trauma, which is not conducive to postoperative recovery of patients.

Combined with our clinical experience and existing studies, we believe that it is appropriate for those who have no neurological symptoms or have mild neurological symptoms by using minimally invasive treatment to correct kyphosis, restore spinal stability and relieve nerve compression indirectly and back pain symptoms. Therefore, this study reports the therapy of percutaneous screw fixation combined with PVP in the treatment of stage III Kümmell with mild or with no neurological symptoms, aiming to provide surgeons with a new safe and effective surgical approach for stage III Kümmell, and comprehensively evaluate the minimally invasive surgery. It aims to: (i) evaluate the safety of the operation by analyzing the intraoperative operations and postoperative complications; (ii) evaluate the efficacy and stability of the minimally invasive surgery for the treatment of stage III Kümmell by retrospectively analyzing the clinical symptoms and imaging data of patients before and after the operation; and (iii) support the concept of effective minimally invasive treatment of Kümmell patients with no neurological symptoms or mild neurological symptoms in stage III.

Materials and Methods

Patient Demographics

This retrospective study was approved by the Ethics Committee of the Affiliated Hospital of Shandong University of Traditional Chinese Medicine.

Patients inclusion criteria were as follows: (i) patients were diagnosed as Kümmell stage III based on the Imaging classification; (ii) conservative treatment was ineffective; (iii) neurological deficit: Frankel grade E; (iv) bone density examination criteria: osteoporosis, T value ≤ 2.5 ; and (v) retrospective study, and the data of patients were complete.

The exclusion criteria were as follows: (i) patients with severe systemic underlying diseases who cannot tolerate surgery; (ii) patients had a continuous multi-segment vertebral body with Kümmell disease; and (iii) the occurrence of

spinal metastases: pathological fractures caused by primary and secondary tumors.

Imaging classification of Kümmell's disease

According to the signs of vertebral fracture on X-ray and CT or evidence of adjacent disc degeneration and osteonecrosis with characteristic signs on MRI, Kümmell's disease can be divided into three stages^{6,12}: stage I, vertebral compression rate <20% with intravertebral vacuum cleft (IVC) sign; stage II, vertebral compression rate >20% with dynamic mobile fracture and adjacent disc degenerative disease; and stage III, posterior cortex breakage of vertebral body with cord compression.

Surgical Procedures

All operations were performed by the same group of physicians. All patients were treated with percutaneous pedicle screw fixation combined with percutaneous vertebroplasty (Fig. 1). General anesthesia was successfully induced, and the patient was placed in the prone position to enable spinal column hyperextension. C-arm fluoroscopy was used to determine the adjacent vertebral body puncture needle insertion

point. After the conventional operation area was disinfected, screws were inserted through the bilateral pedicles under fluoroscopy, two fixation rods were used to restore the height of the vertebral body, and the spinal canal was decompressed indirectly through the tension of the posterior longitudinal ligament and the screws were fixed. Afterwards, a puncture needle was used on the side of the diseased vertebra to puncture the anterior and middle 1/3 of the diseased vertebra through the pedicle. Effusion or gas from the injured vertebra was extracted and the required amount of bone cement was injected under fluoroscopy. The bone cement filled the cavity well and the screw position was adjusted after fluoroscopy. Then the wound was washed, sutured and bandaged.

Postoperative Treatment

Two days after surgery, patients were able to move to the ground for daily activities; X-ray examinations are routinely conducted after operation. Additionally, they were assisted through functional exercises to prevent lower extremity thrombosis, and were given calcium, vitamin D and salmon calcitonin for anti-osteoporosis treatment.

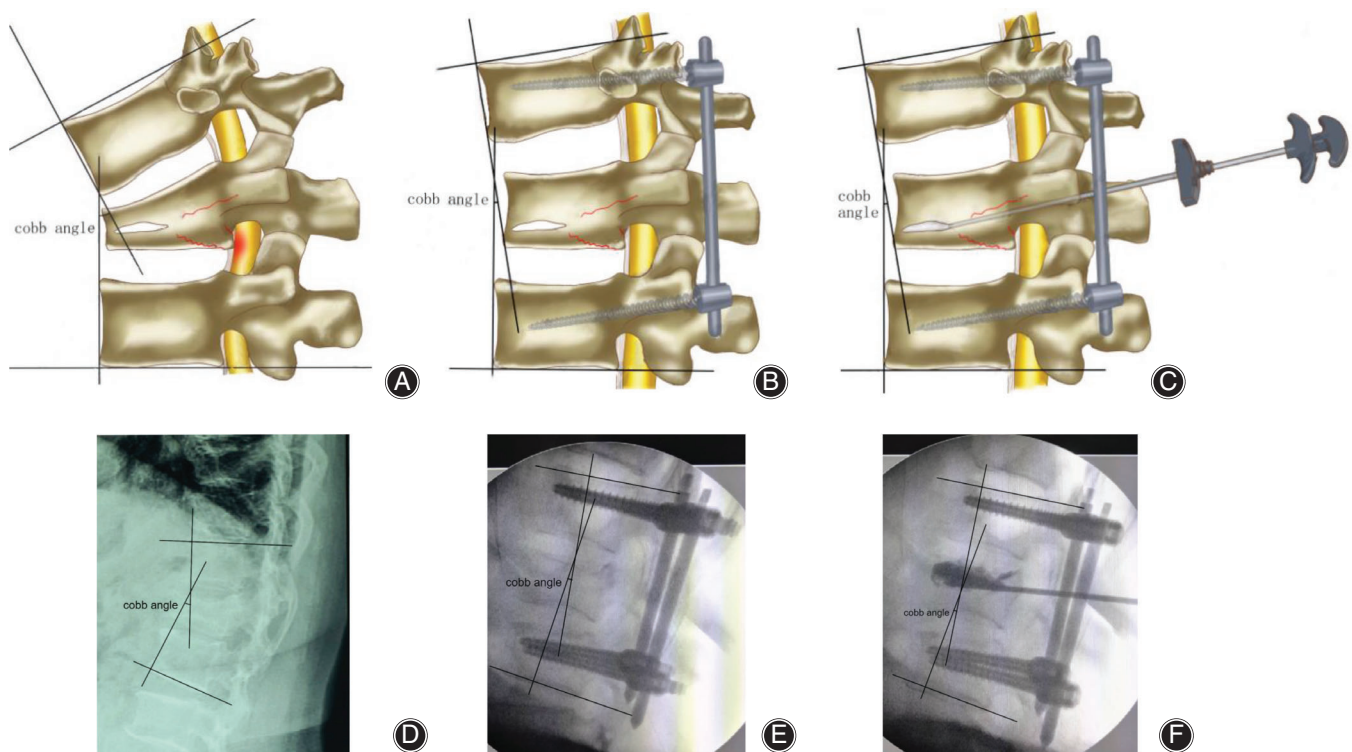


Fig. 1 Schematic diagram of percutaneous pedicle screw fixation combined with vertebroplasty for the treatment of stage III Kümmell disease. (A, D) Stage III Kümmell disease: vertebral compression, Cobb angle enlargement, posterior vertebral cortical rupture with spinal cord compression. (B, E) Percutaneous pedicle screw fixation: decrease the Cobb angle, enlarge the upper and lower gap of the diseased vertebrae and restore the height of the diseased vertebrae. (C, F) Percutaneous vertebroplasty: injection of bone cement to fill the enlarged diseased vertebral cavity to restore the height and stability of the vertebral body.

Effectiveness Evaluation

Clinical Assessment

To evaluate the therapeutic effect of this operation, the Visual Analogue Scale (VAS) and Oswestry disability index (ODI) before operation, 3 and 24 months after operation were recorded.

Visual Analogue Scale

The VAS score system is used to measure low back pain and leg pain. It is the most commonly used questionnaire for quantification of pain. The VAS is a continuous scale comprised of a horizontal or vertical line, usually 10 cm in length. The intensity of pain experienced by the patient, the scale is most commonly anchored by “no pain” (score of 0) and “unbearable pain” (score of 10). A score of 0 is considered as no pain, 1–3 means mild pain that the patient could endure; 4–6 indicates that the patient is in tolerable pain that affects sleep; and 7–10 means the patient had intense pain and was unable to tolerate the pain.

Oswestry Disability Index

ODI is a principal condition-specific outcome measure used in the management of spinal disorders, and to assess patient progress in routine clinical. It is used to assess the impact of spinal diseases on patients' daily lives. The ODI score system includes 10 sections: patient's pain intensity, personal life care status, lifting, walking, sitting, standing, sleeping, sex life, patient's social life, and traveling. For each section of the six statements, the total score is 5. The first statement is marked with the score “zero,” the last one is marked as “five.” Intervening statements are scored according to patient situation. If more than one box is marked in a section, the highest score is taken. If all 10 sections are completed the score is calculated as follows: total scored/50 (total possible score) × 100%. If one section is missed (or not applicable), the score is calculated as: total scored/45 (total possible score) × 100%. Therefore, the final score may be summarized as: (total score/[5 × number of questions answered]) × 100%. A score of 0%–20% is considered mild dysfunction, 21%–40% is moderate dysfunction, 41%–60% is severe dysfunction, and 61%–80% is very severe dysfunction. 80%–100% means patients with very exaggerated symptoms.

Radiologic Assessment

All patients were evaluated by imaging according to relevant indicators before surgery and during the follow-up. The vertebral height and Cobb angle were recorded before operation, 2 days and 24 months after operation.

Cobb Angle

The Cobb angle is a measure of the curvature of the spine in degrees. Spine radiographs, measure from the superior endplate of a superior vertebra to the inferior endplate of an inferior vertebra at a particular region of the vertebral column. The improvement of the intervertebral Cobb angle is

calculated by comparing the preoperative Cobb angle and the postoperative Cobb angle. The better the Cobb angle improvement, the better the kyphosis correction.

The Height of Vertebral Body

In the X-ray film, the height of the vertebral body is directly measured. Draw tangent lines from the top and bottom of the vertebral body, tangent to the anterior and posterior edges of the vertebral body, and connect the tangent points of the anterior and posterior edges respectively, and what you get is the height of the anterior and posterior edges of the vertebral body.

Complications

Common surgical complications include intraoperative cement leakage and vertebral fracture, postoperative re-fracture of adjacent vertebral bodies and internal fixation loosening. All patients were evaluated preoperatively, at 2 days postoperatively, and at the final follow-up.

Bone Cement Leakage

Bone cement leakage refers to the situation where bone cement flows from the vertebral body to the outside of the vertebral body. Bone cement leakage can lead to serious complications. This is also one of the indicators to evaluate the effect of PVP surgery. X-ray film should be used for cement leakage assessment according to the standard after the operation.

Statistical Analysis

Measurement data were expressed as mean ± standard deviation (mean ± SD). SPSS 19.0 statistical software (IBM, Armonk, NY, USA) was used for one-way analysis of variance. $P < 0.05$ indicated a significant difference.

Results

General Patient Information

Twenty-two patients (14 females and 8 males; age: 58–81 years old) with Kümmell disease, admitted from 2014 to 2018, were enrolled in this study. All patients were followed up for 24 months. Causes of injury: 12 cases—fracture after fall; seven cases—fracture without obvious inducement; and 3 cases—fracture after sprain. Site of fracture: seven cases—T₁₂; nine cases—L₁; three cases—L₃; and three cases—T₁₁ (Figs 2–4).

Clinical Improvement

This surgical method has achieved good results in improving clinical symptoms. The VAS scores at 3 and 24 months after operation were significantly lower than those recorded preoperatively ($P = 0.000$ for 3 months) ($P = 0.000$ for 24 months). Additionally, there was no significant difference between 3 and 24 months after operation ($P = 0.551$) (Table 1).

The ODI index at 3 and 24 months after operation were significantly lower than those recorded preoperatively ($P = 0.000$ for 3 months) ($P = 0.000$ for 24 months).

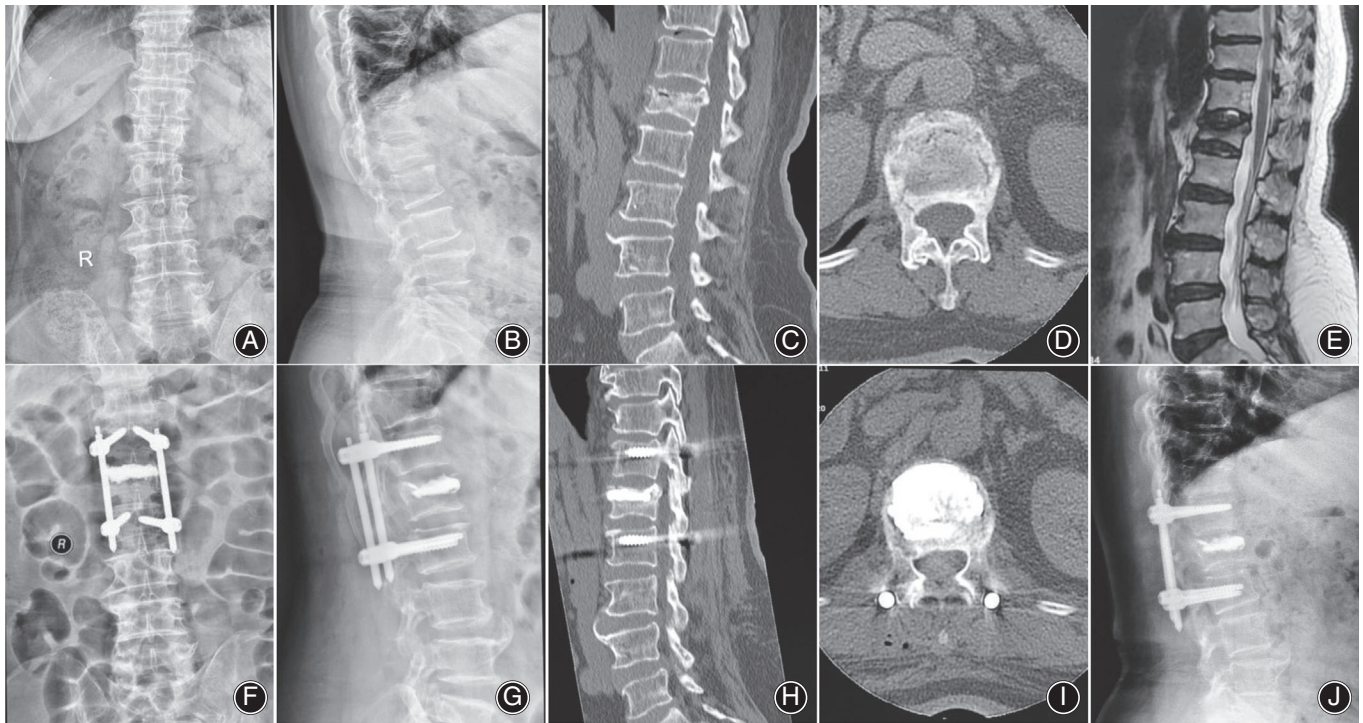


Fig. 2 A 67-year-old-female patient who underwent percutaneous fixation combined with vertebroplasty for L₁ Kümmell disease. (A–E) Preoperative imaging showed L₁ vertebral fracture with Kümmell changes. (F, G) Postoperative X-ray showed fine bone cement position and Kümmell disease vertebral body height recovery. (H, I) Postoperative CT showed bone cement filling and fine internal fixation position. (J) Postoperatively 24 months X-ray showed firm internal fixation, stable vertebral body height, and fine bone cement position.

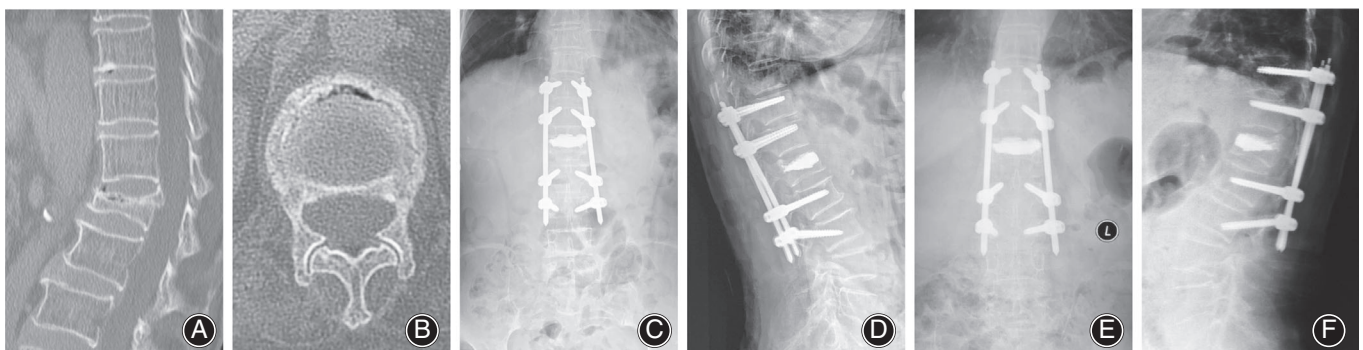


Fig. 3 A 81-year-old female patient who underwent percutaneous fixation combined with vertebroplasty for L₁ Kümmell disease. (A, B) Preoperative CT scan showing L₁ fracture with IVC. (C, D) Postoperative X-ray showed fine bone cement position and Kümmell disease vertebral body height recovery. (E, F) final follow-up X-rays revealing good internal fixation and bone cement position.

Additionally, there was no significant difference between 3 and 24 months after operation ($P = 0.615$) (Table 1).

Radiographic Improvement

Imaging data showed that the bone cement and screws were in good position and did not move during postoperative and follow-up. The anterior, middle and posterior heights of vertebral body measured 2 days and 24 months after operation were higher than that recorded preoperatively ($P = 0.000$, P

$= 0.000$, $P = 0.000$ for 2 days) ($P = 0.000$, $P = 0.000$, $P = 0.000$ for 24 months), but there was no significant difference between the 2 days and 24 months postoperative ($P = 0.061$, $P = 0.160$, $P = 0.132$).

The Cobb angle measured 2 days and 24 months after operation was lower than that recorded preoperatively ($P = 0.000$ for 2 days; $P = 0.000$ for 24 months), but there was no significant difference between the 2 days and 24 months postoperative ($P = 0.775$) (Table 2).

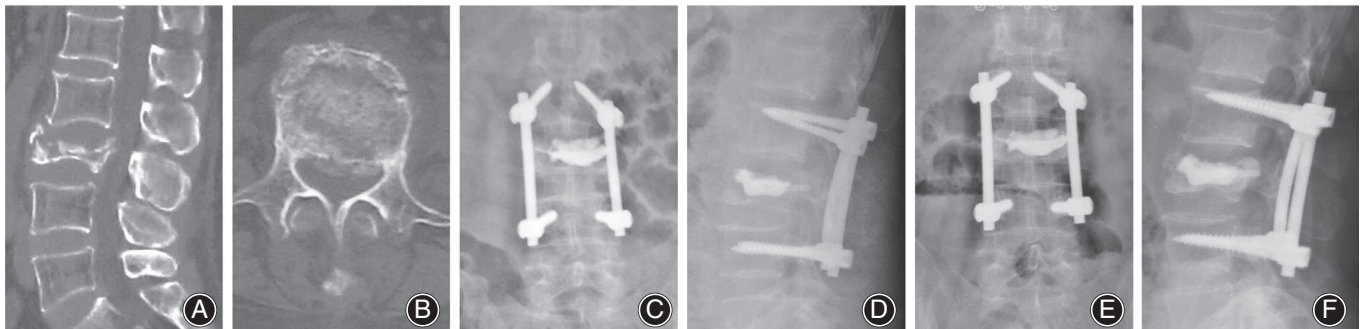


Fig. 4 A 58-year-old male patient who underwent percutaneous fixation combined with vertebroplasty for L₃ Kümmell disease. (A, B) Preoperative CT scan showing L₃ fracture with IVC. (C, D) Postoperative X-ray showed fine bone cement position and Kümmell disease vertebral body height recovery. (E, F) Final follow-up X-rays revealing good internal fixation and bone cement position.

TABLE 1 Comparison of VAS and ODI values before and after surgery (Mean ± SD)

| | Cases | Preoperative | Postoperatively 3 months | Postoperatively 24 months |
|---------|-------|--------------|--------------------------|---------------------------|
| VAS | 22 | 7.59 ± 0.59 | 2.86 ± 0.83* | 3 ± 0.82*# |
| ODI (%) | 22 | 71.5 ± 8.84 | 31.68 ± 6.21* | 32.78 ± 6.05*# |

*indicates compared with preoperative $P < 0.05$, #indicates compared with 3 months after operation $P > 0.05$.

TABLE 2 Comparison of vertebral height and Cobb angle before and after surgery (Mean ± SD)

| | Cases | Preoperative | Postoperatively 2 days | Postoperatively 24 months |
|---------------------------------|-------|--------------|------------------------|---------------------------|
| Anterior vertebral height (mm) | 22 | 13.08 ± 4.49 | 23.46 ± 4.72* | 20.83 ± 4.48*# |
| Middle vertebral height (mm) | 22 | 12.93 ± 3.53 | 23.12 ± 3.05* | 21.78 ± 2.74*# |
| Posterior vertebral height (mm) | 22 | 19.32 ± 2.73 | 25.81 ± 2.22* | 24.74 ± 1.93*# |
| Cobb angle (°) | 22 | 28.24 ± 8.95 | 9.57 ± 4.63* | 10.68 ± 3.97*# |

*indicates compared with preoperative $P < 0.05$, #indicates compared with 2 days after operation $P > 0.05$.

Complication

There was no bone cement leakage and vertebral fracture during the operation. During the follow-up period, there was no re-fracture of the diseased vertebrae and internal fixation loosening, but two cases of adjacent vertebral refracture complications occurred, and the effect was good after PVP treatment.

Discussion

Characteristics and Treatment Strategies of Kümmell Disease

Kümmell disease is a special type of osteoporotic vertebral compression fracture that is caused by local vertebral ischemic necrosis after trauma, which results in the occurrence of a vacuum fissure and pseudoarthrosis^{9,15,16,21} More than

two-thirds of the patients enrolled in this study were affected by various traumas. PVP or PKP surgery is a minor operation for the treatment of Kümmell disease, but its role in correcting kyphosis is limited, while it frequently causes bone cement leakage into the spinal canal and is not able to reset the fracture block. Therefore, it is mostly used in Kümmell disease only at stages I and II^{18,19}. However, as the disease progresses, Kümmell disease will gradually present stage III symptoms, such as vertebral collapse, kyphosis, and even spinal nerve compression^{15,16}. Therefore, early intervention is required. Symptomatic treatment that is appropriate for each pathological stage should be applied. Patients with fractures protruding into the spinal canal or with severe nerve compression need to undergo surgical treatments, such as spinal canal decompression. However, for patients with no neurological symptoms or mild neurological symptoms, surgical

procedures, including vertebroplasty, open reduction and internal fixation combined with bone grafting, and open reduction and internal fixation combined with vertebroplasty are commonly used²²⁻²⁴.

Some studies have suggested that PKP combined with hyperextension reset is effective for the treatment of Kümmell disease^{25,26}, but the correction of kyphosis is limited by this therapy, leading to the inability to effectively support the vertebral body, and thus prone to collapse again after the operation. Therefore, this procedure is used only in patients with no neurological symptoms and kyphosis that is not more severe. Open reduction and internal fixation combined with intervertebral body fusion can effectively resolve nerve compression and correct kyphosis, it is commonly used for patients with neurological dysfunction^{23,27}. However, Kümmell disease is often accompanied with insufficient blood supply of injured vertebrae⁷, therefore, bone nonunion and severe trauma are prone to occur during bone graft fusion, which will increase the risk to patients with physical conditions. Internal fixation combined with bone cement is a conventional method of treating kyphosis or a fracture in the spine without neurological symptoms. However, the bone mass of patients with Kümmell's disease is reduced, and there is a risk of screw loosening and removal over time²⁰. Therefore, some studies have suggested that bases on open reduction and internal fixation, the bone cement can be used to strengthen the nail path, which could increase the strength of the control force^{28,29}. Several clinical studies have shown that this therapy is effective and has less failure of internal fixation^{24,30}, while another study concluded that there is no significant difference between the efficacy of the pedicle screw combined with bone cement and pedicle screw alone, but the former therapy increases complications due to prolonged operation time and bone cement leakage^{31,32}.

Safety and Efficacy of this Minimally Invasive Surgery

Our research group believes that patients with Kümmell's disease mostly develop the disease as a result of the non-union of bones involved in compression fractures, with extended duration of the disease, so it is urgent to improve the quality of life of patients. Moreover, the patients are in poor physical condition, therefore trauma minimizing strategies should be adopted to relieve symptoms and restore lumbar stability. Percutaneous screw fixation shows a similar efficacy compared with the therapy of open screw fixation, but with less trauma and shorter duration of surgery and hospital stay³³⁻³⁶, which are particularly important for patients with Kümmell disease patients. It is direct and reliable to restore the height of the injured vertebra by a short segment pedicle screw, which not only produces a stable reduction effect on the anterior column and the middle column, but can also restore the fracture block to its original position using the tension of the posterior longitudinal ligament, and indirectly expanding the space of the spinal canal.

Clinical observations showed that it increased the height of the anterior, middle and posterior margins of

the injured vertebrae, and decreased the Cobb angle. After the injured vertebra is propped open, an eggshell-like negative cavity inside the injured vertebra, which reduces the pressure of bone cement injection and the risk of leakage¹⁹, and also promotes the effective dispersion of bone cement into the loose bone trabecular space, fully fills the crevice between the opening and the necrosis, and better reconstructs the anterior and middle column of the diseased vertebra allowing it to play a good supporting role. The resulting VAS score and ODI index were found to have significantly decreased. In addition, the filled bone cement can effectively disperse the stress load of the upper and lower pedicle screws, which prevents further collapse. The height of the front, middle and rear edges and the Cobb Angle of the injured vertebra can be effectively maintained after operation.

Concept of Minimally Invasive Treatment

Percutaneous pedicle screw fixation combined with vertebroplasty conforms to the concept of minimally invasive treatment. It is suitable for patients with stage III Kümmell disease without neurological symptoms. During the operation, the intervertebral space should be carefully enlarged to avoid damage to the fixed vertebra. Incision decompression combined with PVP therapy can also be used for patients with neurological symptoms, but this therapy has some disadvantages, such as loosening of internal fixation. If loosening occurs, removal of internal fixation and bone grafting can be considered. These patients often suffer from osteoporosis, poor bone quality, and easy fracture during distraction, therefore, caution should be exercised during surgery. There are also cases of adjacent vertebral refracture, which may have been caused by an imbalance of mechanical distribution between vertebral bodies³⁷⁻³⁹, but most studies indicated that the main cause of refracture is not PVP but osteoporosis⁴⁰⁻⁴³.

Limitations

The less than clinical sample and the lack of control studies on other treatment methods, may limit the reliability of this study, therefore further research is needed.

Conclusions

Percutaneous distraction and internal fixation could correct the deformity, relieve nerve compression, and combined with PVP can be used to restore the height of the injured vertebrae, which leads to early stability. In general, the whole process is minimally invasive, has reliable curative effect, negligible surgical trauma, quick postoperative recovery, and short bed rest time. However, the treatment of Kümmell disease is a continuous process. In addition to surgery that can be used to resolve the main symptoms, it is necessary for standardized anti-osteoporosis treatment to be continued. Appropriate health education to prevent falls and avoid fracture recurrence will help decrease the occurrence of Kümmell disease.

Acknowledgments

This work was supported by the Natural Science Foundation of Shandong Province (ZR2020KH011, ZR2020MH362), Jinan Science and Technology Development Plan Project (No. 202019148, 201401261), National Natural Science Foundation of China (81473709), National

famous Traditional Chinese Medicine expert inheritance studio of Yixun Cao, (State Administration of Traditional Chinese Medicine 2018), Shandong famous Traditional Chinese Medicine expert inheritance studio of Zhanwang Xu, (Shandong Provincial Health Committee 2019).

References

- Vandenbroucke A, Luyten FP, Flamaing J, Gielen E. Pharmacological treatment of osteoporosis in the oldest old. *Clin Interv Aging*, 2017, 12: 1065–1077.
- Compston JE, McClung MR, Leslie WD. Osteoporosis. *Lancet*, 2019, 393: 364–376.
- Wang W, Liu Q, Liu WJ, Li QB, Cai L, Wang ZK. Different performance of intravertebral vacuum clefts in Kümmell's disease and relevant treatment strategies. *Orthop Surg*, 2020, 12: 199–209.
- Feng SW, Chang MC, Wu HT, Yu JK, Wang ST, Liu CL. Are intravertebral vacuum phenomena benign lesions?. *Eur Spine J*, 2011, 20: 1341–1348.
- Brower AC, Downey EF Jr. Kümmell disease: report of a case with serial radiographs. *Radiology*, 1981, 141: 363–364.
- Kim YC, Kim YH, Ha KY. Pathomechanism of intravertebral clefts in osteoporotic compression fractures of the spine. *Spine J*, 2014, 14: 659–666.
- Libicher M, Appelt A, Berger I, et al. The intravertebral vacuum phenomenon as specific sign of osteonecrosis in vertebral compression fractures: results from a radiological and histological study. *Eur Radiol*, 2007, 17: 2248–2252.
- Mirovsky Y, Anekstein Y, Shalmon E, Peer A. Vacuum clefts of the vertebral bodies. *AJNR Am J Neuroradiol*, 2005, 26: 1634–1640.
- Steel HH. Kümmell's disease. *Am J Surg*, 1951, 81: 161–167.
- Wu XF, Ping Y, Zeng XQ, et al. Percutaneous vertebroplasty with side-opening cannula or front-opening cannula in the treatment of Kümmell disease?. *Orthop Surg*, 2020, 12: 1190–1198.
- Li H, Liang CZ, Chen QX. Kümmell's disease, an uncommon and complicated spinal disorder: a review. *J Int Med Res*, 2012, 40: 406–414.
- Li KC, Li AF, Hsieh CH, Liao TH, Chen CH. Another option to treat Kümmell's disease with cord compression. *Eur Spine J*, 2007, 16: 1479–1487.
- Jang JS, Kim DY, Lee SH. Efficacy of percutaneous vertebroplasty in the treatment of intravertebral pseudarthrosis associated with noninfected avascular necrosis of the vertebral body. *Spine (Phila Pa 1976)*, 2003, 28: 1588–1592.
- Xia YH, Chen F, Zhang L, et al. Percutaneous kyphoplasty treatment evaluation for patients with Kümmell disease based on a two-year follow-up. *Exp Ther Med*, 2018, 16: 3617–3622.
- Formica M, Basso M, Cavignaro L, Formica C, Zanirato A, Felli L. Kümmell disease: illustrative case for definition criteria. *Spine J*, 2016, 16: e707–e708.
- Swartz K, Fee D. Kümmell's disease: a case report and literature review. *Spine (Phila Pa 1976)*, 2008, 33: E152–E155.
- Yang H, Pan J, Wang G. A review of osteoporotic vertebral fracture nonunion management. *Spine (Phila Pa 1976)*, 2014, 39(26 Spec No.): B4–B6.
- Huang Y, Peng M, He S, Tang X, Dai M, Tang C. Clinical efficacy of percutaneous kyphoplasty at the hyperextension position for the treatment of osteoporotic Kümmell disease. *Clin Spine Surg*, 2016, 29: 161–166.
- Hong SJ, Lee S, Yoon JS, Kim JH, Park YK. Analysis of intradiscal cement leakage during percutaneous vertebroplasty: multivariate study of risk factors emphasizing preoperative MR findings. *J Neuroradiol*, 2014, 41: 195–201.
- Galbusera F, Volkheimer D, Reitmaier S, Berger-Roscher N, Kienle A, Wilke HJ. Pedicle screw loosening: a clinically relevant complication? *Eur Spine J*, 2015, 24: 1005–1016.
- Malzer U, Pfeiffer M, Griss P. Posttraumatic vertebral body necrosis (Kümmell-Verneuil disease). Case report of a rare orthopaedic disease with histopathological correlation. *Eur Spine J*, 1992, 1: 55–59.
- Zhang J, Fan Y, He X, et al. Is percutaneous kyphoplasty the better choice for minimally invasive treatment of neurologically intact osteoporotic Kümmell's disease? A comparison of two minimally invasive procedures. *Int Orthop*, 2018, 42: 1321–1326.
- Zhang X, Hu W, Yu J, Wang Z, Wang Y. An effective treatment option for Kümmell disease with neurological deficits: modified transpedicular subtraction and disc osteotomy combined with long-segment fixation. *Spine (Phila Pa 1976)*, 2016, 41: E923–E930.
- Kim HS, Heo DH. Percutaneous pedicle screw fixation with polymethylmethacrylate augmentation for the treatment of thoracolumbar intravertebral pseudoarthrosis associated with Kümmell's osteonecrosis. *Biomed Res Int*, 2016, 2016: 3878063.
- Chen GD, Lu Q, Wang GL, et al. Percutaneous kyphoplasty for Kümmell disease with severe spinal canal stenosis. *Pain Physician*, 2015, 18: E1021–E1028.
- Huang YS, Hao DJ, Feng H, et al. Comparison of percutaneous kyphoplasty and bone cement-augmented short-segment pedicle screw fixation for management of Kümmell disease. *Med Sci Monit*, 2018, 24: 1072–1079.
- Mei L, Sang W, Chen Z, et al. Titanium mesh bone grafting combined with pedicle screw internal fixation for treatment of Kümmell disease with cord compression: a case report and literature review. *Medicine (Baltimore)*, 2018, 97: e12183.
- Elder BD, Lo SF, Holmes C, et al. The biomechanics of pedicle screw augmentation with cement. *Spine J*, 2015, 15: 1432–1445.
- Tolunay T, Basgul C, Demir T, Yaman ME, Arslan AK. Pullout performance comparison of pedicle screws based on cement application and design parameters. *Proc Inst Mech Eng H*, 2015, 229: 786–793.
- Huang YS, Ge CY, Feng H, et al. Bone cement-augmented short-segment pedicle screw fixation for Kümmell disease with spinal canal stenosis. *Med Sci Monit*, 2018, 24: 928–935.
- Mueller JU, Baldauf J, Marx S, Kirsch M, Schroeder HW, Pillich DT. Cement leakage in pedicle screw augmentation: a prospective analysis of 98 patients and 474 augmented pedicle screws. *J Neurosurg Spine*, 2016, 25: 103–109.
- Tan QC, Wu JW, Peng F, et al. Augmented PMMA distribution: improvement of mechanical property and reduction of leakage rate of a fenestrated pedicle screw with diameter-tapered perforations. *J Neurosurg Spine*, 2016, 24: 971–977.
- Fitschen-Oestern S, Scheuerlein F, Weuster M, et al. Reduction and retention of thoracolumbar fractures by minimally invasive stabilisation versus open posterior instrumentation. *Injury*, 2015, 46: S63–S70.
- Lyu J, Chen K, Tang Z, Chen Y, Li M, Zhang Q. A comparison of three different surgical procedures in the treatment of type A thoracolumbar fractures: a randomized controlled trial. *Int Orthop*, 2016, 40: 1233–1238.
- Heintel TM, Dannigkeit S, Fenwick A, et al. How safe is minimally invasive pedicle screw placement for treatment of thoracolumbar spine fractures?. *Eur Spine J*, 2017, 26: 1515–1524.
- Zhang W, Li H, Zhou Y, et al. Minimally invasive posterior decompression combined with percutaneous pedicle screw fixation for the treatment of thoracolumbar fractures with neurological deficits: a prospective randomized study versus traditional open posterior surgery. *Spine (Phila Pa 1976)*, 2016, 41: B23–B29.
- Baek SW, Kim C, Chang H. The relationship between the spinopelvic balance and the incidence of adjacent vertebral fractures following percutaneous vertebroplasty. *Osteoporos Int*, 2015, 26: 1507–1513.
- Cho AR, Cho SB, Lee JH, Kim KH. Effect of augmentation material stiffness on adjacent vertebrae after osteoporotic vertebroplasty using finite element analysis with different loading methods. *Pain Physician*, 2015, 18: E1101–E1110.
- Liebschner MA, Rosenberg WS, Keaveny TM. Effects of bone cement volume and distribution on vertebral stiffness after vertebroplasty. *Spine (Phila Pa 1976)*, 2001, 26: 1547–1554.
- Han SL, Wan SL, Li QT, et al. Is vertebroplasty a risk factor for subsequent vertebral fracture, meta-analysis of published evidence?. *Osteoporos Int*, 2015, 26: 113–122.
- Ma X, Xing D, Ma J, et al. Risk factors for new vertebral compression fractures after percutaneous vertebroplasty: qualitative evidence synthesized from a systematic review. *Spine (Phila Pa 1976)*, 2013, 38: E713–E722.
- Rho YJ, Choe WJ, Chun YI. Risk factors predicting the new symptomatic vertebral compression fractures after percutaneous vertebroplasty or kyphoplasty. *Eur Spine J*, 2012, 21: 905–911.
- Lu K, Liang CL, Hsieh CH, Tsai YD, Chen HJ, Liliang PC. Risk factors of subsequent vertebral compression fractures after vertebroplasty. *Pain Med*, 2012, 13: 376–382.