

## Venous Malformation (Cavernous Hemangioma) of the Supraorbital Nerve

### Abstract

Cavernous hemangiomas are not true vascular tumors, but rather are slow-flow venous malformations (VMs). They are present at birth as nonproliferating vascular birthmarks composed of anomalous ectatic venous channels. VMs have often been incorrectly called cavernous hemangiomas and cavernous angiomas. These terms have for a long time lead to confusion with the more common proliferating or true hemangioma of infancy. VM has been reported to arise at all sites including skin and subcutaneous layers of the head and neck, face, extremities, liver, gastrointestinal tract, and even the thymus. Although VMs are common intraocular tumors and are involved within intracranial, extraaxial cranial nerves within the cavernous sinus has been sporadically reported, and less often in the supraorbital nerve, an extraocular and extracranial division of the trigeminal nerve has not been reported. The authors present an extremely rare occurrence of VM involving the supraorbital nerve in an 80-year-old female.

**Keywords:** *Cavernous hemangioma, supraorbital nerve, trigeminal neuropathic pain, vascular anomaly, venous malformation*

### Introduction

Cavernous hemangioma is not a vascular tumor, but rather a congenital vascular anomaly. It is classified by a venous malformation (VM) in the slow-flow lesion category by International Society for the Study of Vascular Anomalies (ISSVA).<sup>[1-5]</sup> The ISSVA categorization schema is based on the pioneering work of Mulliken and Glowacki;<sup>[3]</sup> the schema was subsequently modified to include descriptions of flow characteristics<sup>[5]</sup> and some rare lesions.<sup>[2]</sup> The ISSVA classification has three levels of division.<sup>[2,4,6]</sup> In the first, vascular tumors are differentiated from malformation. Vascular malformations are then subdivided by flow characteristics into slow- and high-flow.<sup>[5]</sup> Finally, within these categories, lesions are defined by their components as arterial, venous, lymphatic, or mixed.<sup>[4]</sup> According to the ISSVA classification, cavernous hemangioma should be considered slow-flow VMs.<sup>[4,6]</sup>

VMs are a commonly encountered entity in clinical practice, with an estimated incidence of 1–2 in 10,000 births<sup>[7]</sup> and the prevalence of 1%.<sup>[8]</sup> VMs are composed of abnormal collections of veins that have a variable luminal size and wall thickness, and geographically can appear

superficial, deep, diffuse, localized, and not uncommonly multiple.<sup>[9]</sup> VMs can arise anywhere in the body and are the most common intraorbital tumors found in adults.<sup>[10]</sup> Facial VMs involve the skin and subcutaneous tissues, and oral mucosa are well-known entities. Although intracranial, intraaxial VMs (formerly called cavernous hemangiomas) and intraocular VMs are well-known to neurosurgeons, intracranial and extra-axial VMs are rare, accounting for only 0.4%–2% of all intracranial vascular malformations,<sup>[11]</sup> and tend to involve the cavernous sinus and Meckel's cave.<sup>[12-17]</sup> However, to best of our knowledge, its occurrence in the extracranial, extraocular, supraorbital nerve without intraocular involvement has never been reported. This case report was approved by an Institutional Review Boards at out university (KC15ZISE0677).

### Case Report

An 80-year-old woman presented with a 3-year history of localized swelling on the left medial eyebrow area and an aching, dysesthetic pain typically radiating to the left medial forehead, especially when the head was inclined. The dysesthetic pain developed in association with the development of the localized swelling on the medial eyebrow area and progressively

**Jung-hoon Kim<sup>1</sup>,  
Jin-gyu Choi<sup>1</sup>,  
Byung-chul Son<sup>1,2</sup>**

<sup>1</sup>Department of Neurosurgery, Seoul St. Mary's Hospital, College of Medicine, Catholic University of Korea, <sup>2</sup>Catholic Neuroscience Institute, College of Medicine, Catholic University of Korea, Seoul, Korea

**Address for correspondence:**  
Prof. Byung-chul Son,  
Department of Neurosurgery,  
Seoul St. Mary's Hospital,  
Catholic Neuroscience Institute,  
College of Medicine, Catholic  
University of Korea, 222  
Banpo-daero, Seocho-gu, 06591  
Seoul, Korea.  
E-mail: sbc@catholic.ac.kr

#### Access this article online

**Website:** www.asianjns.org

**DOI:** 10.4103/ajns.AJNS\_166\_16

#### Quick Response Code:



**How to cite this article:** Kim Jh, Choi Jg, Son Bc. Venous malformation (Cavernous Hemangioma) of the supraorbital nerve. Asian J Neurosurg 2018;13:499-502.

This is an open access journal, and articles are distributed under the terms of the Creative Commons Attribution-NonCommercial-ShareAlike 4.0 License, which allows others to remix, tweak, and build upon the work non-commercially, as long as appropriate credit is given and the new creations are licensed under the identical terms.

For reprints contact: reprints@medknow.com

worsened with time. The pain distributed along the cutaneous distribution of left supraorbital area to the frontal forehead. Eventually, she suffered from extreme difficulty and pain during daily life in tasks including eating, face washing, brushing, and reading because the pain was instantly aggravated with the face and head in dependent position.

On physical examination, there was no local heat or tenderness and no thrill was felt on palpation of the swollen area. No discoloration and no signs of inflammation were evident. The eye examination was normal. There was no neurologic deficit, except mild hypesthesia in the distribution of the left supraorbital nerve and a sensorineural hearing loss in the left ear. In the medical history, she underwent a gamma knife radiosurgery for a small, left-sided, vestibular schwannoma 5 years before presentation, which had been incidentally detected during an evaluation for left-sided hearing loss and tinnitus. She had been medicated for 10 years with calcium channel blocker for an essential hypertension. There was no history of exposure to antiplatelet or anticoagulation drugs and no history of physical trauma and shingles over the left supraorbital area. She denied discoloration or swelling presented in the left supraorbital area before the development of swelling and pain 3 years ago. Laboratory examination including the coagulation profile was normal.

Magnetic resonance imaging (MRI) showed an approximately 21 mm × 18 mm-sized, irregularly-marginated, highly-enhancing subcutaneous mass in the left supraorbital area. Low signal intensity was produced on both T1 and T2-weighted images, and strong enhancement with gadolinium was evident [Figure 1a and b]. There was no involvement in the adjacent left orbit. Considering the progressive growing nature and medical intractability, surgical resection was planned. On exposure through a supraorbital, eyebrow incision, poorly circumscribed, multiple vascular channels encircling the supraorbital and supratrochlear nerves were encountered. Dissection of the supraorbital and supratrochlear nerves from the vessels was impossible because the nerves were embedded within the vascular channels and profuse venous bleeding was observed. *En bloc* excision of the vascular channels including the involved nerves was performed. Histological examination showed lobulated and dilated, blood-filled vessels lined by CD31 positive endothelial cells [Figure 2a and b]. No cellular atypia was observed. The pathological features were consistent with a diagnosis of formerly-called cavernous hemangioma (slow-flow VM).

The incident, dysesthetic supraorbital pain on inclining the head disappeared immediately after resection. However, a new denervation dysesthetic pain according to the supraorbital neurectomy developed and lasted 9 months postoperatively. The pain eventually subsided with gabapentin therapy. Moderate hypesthesia and mild

dysesthesia in the distribution of the left supraorbital nerve was evident, and no recurrence was observed 2 years postoperatively.

## Discussion

Identification and classification of vascular anomalies were hampered historically by the use of confusing nomenclature.<sup>[2]</sup> Early classification suggested by Virchow<sup>[18]</sup> and Wegener<sup>[19]</sup> classified vascular lesions according to the pathologic appearance of the vessel.<sup>[2]</sup> Vascular growths were divided into angiomas and lymphangiomas without consideration of the biologic behavior and natural history of the vascular lesions.<sup>[2]</sup> Consequently, there was a tendency to identify any vascular anomaly as a hemangioma.<sup>[1-5]</sup> A variety of terms including “venous angioma,” “cavernous angioma,” “cavernous hemangioma,” and “phlebangioma” have been used in the medical literature to describe these anomalies. These terms have led to confusion with the more common proliferating or true hemangioma of infancy.<sup>[1,2]</sup> For example, capillary hemangioma, *nervus flammeus*, and port-wine stain have all been used in the literature to describe a capillary malformation of the skin.<sup>[20]</sup>

In 1982, Mulliken and Glowacki<sup>[3]</sup> proposed a modern classification of vascular anomaly according to the lesion’s biologic and pathologic differences; all vascular anomalies were assigned to one of two broad categories: hemangiomas and vascular malformations. The former category was later expanded to include vascular tumor. The suffix “-oma” was only to be reserved for those lesions exhibiting increased cellular turnover, the classic example within this category being the infantile hemangioma.<sup>[1,4]</sup> The term “vascular malformation” was applied to those lesions present at birth growing commensurately or *pari passu* with the child. The vascular malformation was composed of normal “mature” flat endothelial-lined vascular spaces with normal rate of cell turnover and were further subdivided into capillary malformation; VM; arterial (arteriovenous) malformation; and lymphatic malformations.<sup>[1,4]</sup>

VMs are slow-flow vascular malformations that are present at birth.<sup>[1,2]</sup> However, they are not always evident. They typically become more prominent as the patient matures; the most pronounced enlargement is usually seen from infancy to puberty with less pronounced changes in adulthood.<sup>[2]</sup> They are nonproliferating vascular birthmarks composed of anomalous ectatic venous channels. They present as soft, compressible blue masses that enlarge when the affected area is in a dependent position or with physical activity.<sup>[2]</sup> The blue color is pathognomonic and caused by the presence of ectatic anomalous venous channels within the dermis.<sup>[2]</sup> There is no increase in local skin temperatures or thrill on palpation of the lesion.<sup>[2]</sup> In the present case, the characteristic aggravation of supraorbital, trigeminal pain on head inclining seems to be related to placement of the affected lesion in the dependent position.

There was no typical bluish discoloration seen in facial lesions, however, it seems to have been related to the patient's lifestyle (tanned skin from several decades of farming). Furthermore, she had a brain MRI for follow-up examination for vestibular schwannoma after radiosurgery 2-year before painful swelling occurred; a subtle signal change in the extracranial left frontal area could be traced retrospectively during the preparation of this report indicating the congenital nature of VM.

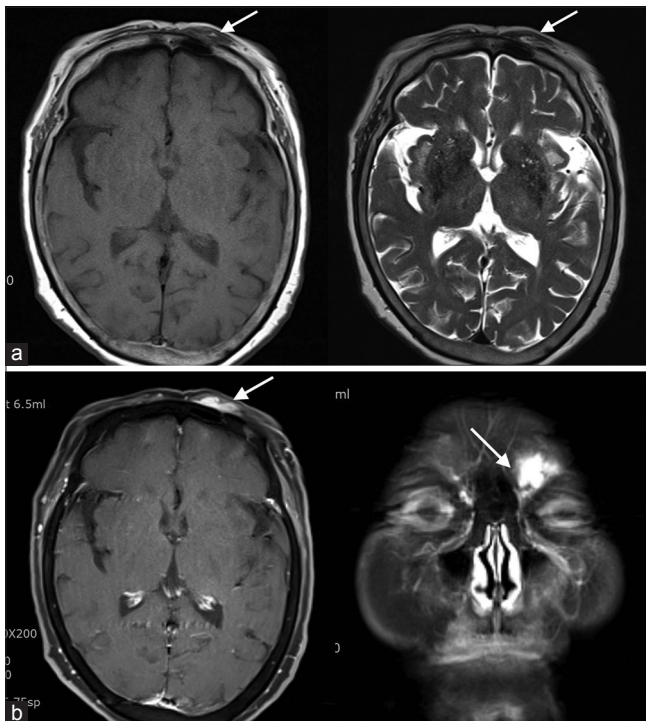
VMs arise at all sites and infiltrate the skin, muscles, and even bones and joints, particularly in the extremities. Therefore, VM can manifest in a wide dysmorphic spectrum from varicosities and ectasias to localized spongy masses and to complex channels that can permeate any organ system.<sup>[21]</sup> They can be localized, however, and are more often multiple. Head and neck VMs are frequently more extensive than is initially apparent.<sup>[2]</sup> Facial VMs involve the skin and subcutaneous layers, but often have extension into the muscle and oral mucosa.<sup>[2]</sup> Extremity lesions are usually localized or segmental, and pain and swelling are common initial symptoms. Phlebothrombosis is the primary event in the formation of pathognomonic phlebolith.<sup>[21]</sup> Extensive VM (or combined with lymphatic malformation) can cause a localized intravascular coagulopathy,<sup>[21-23]</sup> and extension into the skeletal muscles and joints has been reported. Lesions involving deeper

structures without superficial involvement may remain unrecognized until a patient presents with pain, swelling, or functional impairment later in life.<sup>[22]</sup>

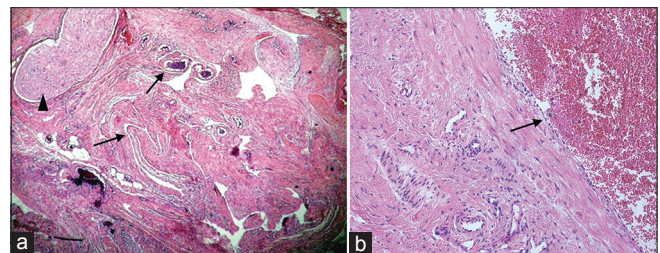
Intracranial VMs (formerly-called cavernous hemangiomas) may be intraparenchymal, intraventricular or, in several cases, extra-axial arising from the cavernous sinus. They are the most common intraorbital tumors found in adults.<sup>[10,24]</sup> In contrast to orbital VMs, extra-axial VMs are highly vascular and bleed easily.<sup>[25]</sup> Although VMs are histologically benign, they can encroach on intraorbital structures or adjacent structures and can be considered anatomically or positionally malignant sometimes.<sup>[10]</sup> Several case reports have described invasion of the cavernous hemangiomas extending across the intracranial, extracranial, and orbital compartments from the extra-axial cavernous hemangiomas.<sup>[15,17,26]</sup> Although the involvement of extracranial and extraorbital soft tissue from extensive VM in the orbit and cavernous sinus has been reported, to the best of our knowledge, primary involvement within extracranial, extraocular supraorbital nerve has never been reported.

MRI is an imaging modality of choice in noninvasive assessment providing superior lesion and soft tissue discrimination to other radiologic imaging studies.<sup>[4]</sup> VMs classically appear as either isointense or hypointense on T1-weighted sequences and may appear more hyperintense if they contain fat.<sup>[4]</sup> T2-weighted or short tau inversion recovery imaging consistently demonstrate high signal intensity and low signal area on T2 can be caused by hemosiderin, calcification, phlebolith, vascular channels, or fibrofatty septa.<sup>[4]</sup> Gadolinium enhancement results in homogeneous or heterogeneous enhancement within the substance of VMs. These features are not pathognomonic for intracranial, extra-axial VMs and can also be seen in hemangiopericytomas, schwannomas, and neurofibromas.<sup>[26]</sup>

Treatment of soft tissue VMs in the extremity is complicated by the fact that they are a very chronic and non-life-threatening medical condition whose symptoms are often quite variable over time.<sup>[4]</sup> The natural history of orbital VMs is contentious.<sup>[6]</sup> Treatment is generally indicated if the lesion causes pain, functional impairment, or esthetic problems, as in craniofacial lesions.<sup>[6]</sup>



**Figure 1:** Magnetic resonance imaging findings of the lesion. (a) T1-weighted (left) and T2-weighted axial (right) images showing a poorly-margined, isointense signal mass (arrows) with inner high signal area possibly indicating hemorrhage or thrombosis, and dilated or serpiginous vascular structure compatible with abnormal veins. (b) T1-weighted axial (left) and coronal (right) images showing the location of lesion (arrows) with strong enhancement



**Figure 2:** Histologic examinations of the lesion. (a) A photograph showing various sized dilated vessels (arrows) and an embedded nerve fascicle (arrowhead) (H and E, ×25). (b) A photograph showing an endothelium-lined dilated vessel wall (H and E, ×100)

## Conclusion

An extremely rare occurrence of VM (formerly-called cavernous hemangioma) involving the extraorbital, extracranial portion of the supraorbital nerve was observed in an elderly female patient. There is still a significant confusion in proper selection of terminology of congenital vascular malformation and anomalies are present in the literature.

## Financial support and sponsorship

Nil.

## Conflicts of interest

There are no conflicts of interest.

## References

- Enjolras O. Classification and management of the various superficial vascular anomalies: Hemangiomas and vascular malformations. *J Dermatol* 1997;24:701-10.
- Garzon MC, Huang JT, Enjolras O, Frieden IJ. Vascular malformations: Part I. *J Am Acad Dermatol* 2007;56:353-70.
- Mulliken JB, Glowacki J. Hemangiomas and vascular malformations in infants and children: A classification based on endothelial characteristics. *Plast Reconstr Surg* 1982;69:412-22.
- Legiehn GM, Heran MK. Venous malformations: Classification, development, diagnosis, and interventional radiologic management. *Radiol Clin North Am* 2008;46:545-97, vi.
- Jackson IT, Carreño R, Potparic Z, Hussain K. Hemangiomas, vascular malformations, and lymphovenous malformations: Classification and methods of treatment. *Plast Reconstr Surg* 1993;91:1216-30.
- Rootman DB, Heran MK, Rootman J, White VA, Luemsamran P, Yucel YH. Cavernous venous malformations of the orbit (so-called cavernous haemangioma): A comprehensive evaluation of their clinical, imaging and histologic nature. *Br J Ophthalmol* 2014;98:880-8.
- Vikkula M, Boon LM, Mulliken JB. Molecular genetics of vascular malformations. *Matrix Biol* 2001;20:327-35.
- Eifert S, Villavicencio JL, Kao TC, Taute BM, Rich NM. Prevalence of deep venous anomalies in congenital vascular malformations of venous predominance. *J Vasc Surg* 2000;31:462-71.
- North PE, Mihm MC Jr. Histopathological diagnosis of infantile hemangiomas and vascular malformations. *Facial Plast Surg Clin North Am* 2001;9:505-24.
- Rosca TI, Pop MI, Curca M, Vladescu TG, Tihoan CS, Serban AT, *et al.* Vascular tumors in the orbit – Capillary and cavernous hemangiomas. *Ann Diagn Pathol* 2006;10:13-9.
- Zabramski JM, Awasthi D. Extra-axial cavernous malformations. In: Awad IA, Barrow DL, editors. *Cavernous Malformations*. Park Ridge, IL: American Association of Neurological Surgeons; 2003. p. 133-44.
- Biondi A, Clemenceau S, Dormont D, Deladoeuille M, Ricciardi GK, Mokhtari K, *et al.* Intracranial extra-axial cavernous (HEM) angiomas: Tumors or vascular malformations? *J Neuroradiol* 2002;29:91-104.
- Fehlings MG, Tucker WS. Cavernous hemangioma of Meckel's cave. Case report. *J Neurosurg* 1988;68:645-7.
- Matias-Guiu X, Alejo M, Sole T, Ferrer I, Noboa R, Bartumeus F. Cavernous angiomas of the cranial nerves. Report of two cases. *J Neurosurg* 1990;73:620-2.
- Puca A, Colosimo C, Tirpakova B, Lauriola L, Di Rocco F. Cavernous hemangioma extending to extracranial, intracranial, and orbital regions. Case report. *J Neurosurg* 2004;101:1057-60.
- Tannouri F, Divano L, Caucheteur V, Hacourt A, Pirotte B, Salmon I, *et al.* Cavernous haemangioma in the cavernous sinus: Case report and review of the literature. *Neuroradiology* 2001;43:317-20.
- Yamasaki T, Handa H, Yamashita J, Paine JT, Tashiro Y, Uno A, *et al.* Intracranial and orbital cavernous angiomas. A review of 30 cases. *J Neurosurg* 1986;64:197-208.
- Virchow R. *Angioma in die krankhaften geschwulste*. Vol. 3. Berlin: Hirschwald; 1863. p. 306-425.
- Wegener G. Ueber lymphanangiome. *Arch Klin Chir* 1977;20:641-707.
- Mulliken JB. Diagnosis and natural history of hemangiomas. In: Mulliken JB, Young AE, editors. *Vascular Birthmarks: Hemangiomas and Malformations*. Philadelphia: WB Saunders; 1988. p. 41-62.
- Mulliken JB, Fishman SJ, Burrows PE. Vascular anomalies. *Curr Probl Surg* 2000;37:517-84.
- Enjolras O, Ciabrini D, Mazoyer E, Laurian C, Herbreteau D. Extensive pure venous malformations in the upper or lower limb: A review of 27 cases. *J Am Acad Dermatol* 1997;36(2 Pt 1):219-25.
- Enjolras O, Mulliken JB. The current management of vascular birthmarks. *Pediatr Dermatol* 1993;10:311-3.
- Demirci H, Shields CL, Shields JA, Honavar SG, Mercado GJ, Tovilla JC. Orbital tumors in the older adult population. *Ophthalmology* 2002;109:243-8.
- Shi J, Wang H, Hang C, Pan Y, Liu C, Zhang Z. Cavernous hemangiomas in the cavernous sinus. Case reports. *Surg Neurol* 1999;52:473-8.
- Lee KY, Fong KS, Loh HL, Heran MK, Rootman J. Giant cavernous haemangioma mimicking a fifth nerve neurofibroma involving the orbit and brain. *Br J Ophthalmol* 2008;92:423-5.