

Gastrointestinal bleeding in patients with hereditary hemorrhagic telangiectasia: Long-term results of endoscopic treatment



Authors

Guido Manfredi¹, Stefano Francesco Crinò², Saverio Alicante¹, Samanta Romeo¹, Roberto Berté¹, Silvia Gandolfi³, Angelo Spinazzola³, Michela Fiini⁴, Pierangelo Forner⁵, Elisabetta Buscarini¹

Institutions

- 1 Gastroenterology and Endoscopy Department, Center of reference VASCERN HHT, Maggiore Hospital Crema, Crema, Italy
- 2 Digestive Endoscopy Unit, University of Verona, Italy, Verona, Italy
- 3 Radiology Department, Maggiore Hospital Crema, Crema, Italy
- 4 Cardiology Department, Maggiore Hospital Crema, Crema, Italy
- 5 ENT Department, Maggiore Hospital Crema, Crema, Italy

Key words

RFA and ablative methods, Small intestinal bleeding, Small bowel endoscopy

received 1.6.2023

accepted after revision 4.10.2023

accepted manuscript online 12.10.2023

Bibliography

Endosc Int Open 2023; 11: E1145–E1152

DOI 10.1055/a-2190-9303

ISSN 2364-3722

© 2023. The Author(s).

This is an open access article published by Thieme under the terms of the Creative Commons Attribution-NonDerivative-NonCommercial License, permitting copying and reproduction so long as the original work is given appropriate credit. Contents may not be used for commercial purposes, or adapted, remixed, transformed or built upon. (<https://creativecommons.org/licenses/by-nc-nd/4.0/>)

Georg Thieme Verlag KG, Rüdigerstraße 14,
70469 Stuttgart, Germany

Corresponding author

Dr. Guido Manfredi, Maggiore Hospital Crema,
Gastroenterology and Endoscopy Department, Center of
reference VASCERN HHT, Largo U. Dossena, 2, 26013 Crema,
Italy
guido.manfredi@asst-crema.it

Additional material is available at
<https://doi.org/10.1055/a-2190-9303>

ABSTRACT

Background and study aims This longitudinal prospective study evaluated the long-term outcome of endoscopic treatment of gastrointestinal bleeding in hereditary hemorrhagic telangiectases (HHT), its safety and outcome predictors.

Patients and methods Consecutive patients with HHT and either anemia disproportionate to epistaxis or overt gastrointestinal bleeding received endoscopic treatment of gastrointestinal telangiectases with argon plasma coagulation (APC). Hemoglobin levels and transfusion requirements were evaluated before and after treatment. Treatment effectiveness was classified as: 1) complete: hemoglobin level during the follow-up ≥ 9 g/dL; 2) complete with recurrence: hemoglobin ≥ 9 g/dL for at least 12 months with subsequent drop to < 9 g/dL; or 3) absent: no improvement of hemoglobin level. Adverse events (AEs) were classified as mild, moderate, severe or fatal. Correlations were searched between treatment outcome and demographic/genetic characteristics, number, size and site of telangiectases, and hepatic arterio-venous malformations grade.

Results Forty-seven patients with HHT were enrolled. At median follow-up of 134 months (range 20–243 months), 41 of 47 patients showed treatment response (complete or with recurrence) after one (14/47) or more (27/47) endoscopic treatments. Median hemoglobin levels were 7.0 g/dL and 11.9 g/dL at baseline and at the end of follow-up, respectively. Transfusion requirement decreased from 22.8 to 7.3 red cell unit/year. A higher baseline number of telangiectases was associated with a lower chance of response ($P = 0.008$). Only one severe AE (0.4%, jejunal perforation) was recorded.

Conclusions Endoscopic treatment of gastrointestinal telangiectases for gastrointestinal bleeding in patients with HHT is effective in the long term and safe.

Introduction

Hereditary hemorrhagic telangiectases (HHT) is a multisystemic inherited vascular dysplasia that leads to nosebleeds and arteriovenous malformations (AVMs) in organs such as the lungs, liver, and brain, with an estimated prevalence of 1/6000 [1]. The clinical criteria for diagnosing HHT, the Curaçao criteria, were established by a panel of experts [2]. Most patients with HHT have mutations in one of two known disease-related genes, endoglin (*ENG*, HHT1) or activin A receptor type II-like 1 (*ACVRL1*, HHT2), which are both involved in the TGF- β pathway [3]. The clinical presentation varies greatly depending on the number, type, and location of telangiectasis or AVMs with potential morbidity and mortality. A dominant clinical feature is iron deficiency anemia as a result of recurrent bleeds from either nasal or gastrointestinal telangiectasis, which can lead to severe anemia requiring iron supplements and, in more severe forms, a recurrent need for blood transfusions. Another digestive manifestation unique to HHT is liver AVMs, which involve the liver diffusely; intrahepatic shunting can lead to different clinical features, including high-output cardiac failure, portal hypertension, encephalopathy, biliary ischemia, and mesenteric ischemia [4, 5].

Phenotype-genotype correlations have been described: patients with the *ALK1* mutation more often present with hepatic AVMs; *ENG* genotypes are more often associated with pulmonary AVMs [6, 7].

Telangiectases of the digestive tract develop in most patients with HHT and are most commonly found in the stomach, duodenum and proximal jejunum. Gastric telangiectases can be found in all portions of the stomach, albeit with preponderance in the antral region. Several studies conducted with upper gastrointestinal endoscopy, enteroscopy, videocapsule enteroscopy (VCE), and colonoscopy have estimated the prevalence of telangiectases in HHT, comparing them to the general population. Gastric, small intestine, and colon telangiectases were found in 29% to 75%, 56% to 91%, and 9% to 31% of patients, respectively [8, 9, 10, 11, 12]. In the general population, gastric and small intestine telangiectases are found in 0% and 21% of patients, respectively, whereas the prevalence of colon telangiectases in HHT shows overlap with that in the general population [9, 10]. The presence and number of stomach and duodenal telangiectases correlate with the presence and number of jejunal telangiectases [13].

Digestive hemorrhage occurs in 13% to 30% of patients with HHT compared to 3% of the general population. Generally, it occurs in the fourth or fifth decade of life, while presentations at a younger age are rare (1.5% of patients). Digestive bleeding in HHT is generally chronic, asymptomatic, sometimes intermittent, often occult and unrecognized, and symptoms develop when anemia occurs. Acute and massive digestive bleeding is a rare event [5, 14]. Endoscopic evaluation is the gold standard for the evaluation of digestive bleeding in HHT, either when it is overt or, more typically, when iron deficiency anemia is disproportionate to the extent of epistaxis [5], that is, when either the patient or the physician realize that epistaxis frequency and intensity cannot justify severity of anemia.

As the majority of telangiectases are located in the upper gastrointestinal tract, upper gastrointestinal endoscopy examinations are performed first in HHT patients with gastrointestinal bleeding, with VCE and colonoscopy or mesenteric angiography performed only in selected cases.

The first line of treatment, besides iron replacement therapy to manage anemia, includes endoscopic treatment, which is standard of care, generally with thermal coagulation with argon plasma coagulation (APC) or with a neodymium-YAG laser [15, 16, 17, 18, 19]. However, the reported results involved a small series of patients with HHT, the results showed that the treatment had variable effectiveness, and there was a high proportion of patients who were refractory to APC therapy [15, 16, 17, 18, 19, 20].

The primary aim of the study was to evaluate the long-term effectiveness of endoscopic treatment with APC for gastrointestinal telangiectases in patients with HHT. The secondary aims were: 1) to evaluate the safety of endoscopic treatment with APC in this setting; and 2) to evaluate correlations between treatment effectiveness and characteristics of the patients with HHT (demographic and genetic) and gastrointestinal telangiectases (number, size, and location), and the severity of hepatic AVMs.

Patients and methods

Study design

This was a longitudinal prospective study with consecutive enrollment at an HHT reference center. In the center, all patients with HHT are registered in a database, which contains demographic, laboratory, and clinical data regarding diagnosis, follow-up, and treatments. The patient assessment, treatment, and surveillance protocol, which involved the use of standard-of-care interventions, was approved by the Institutional Review Board.

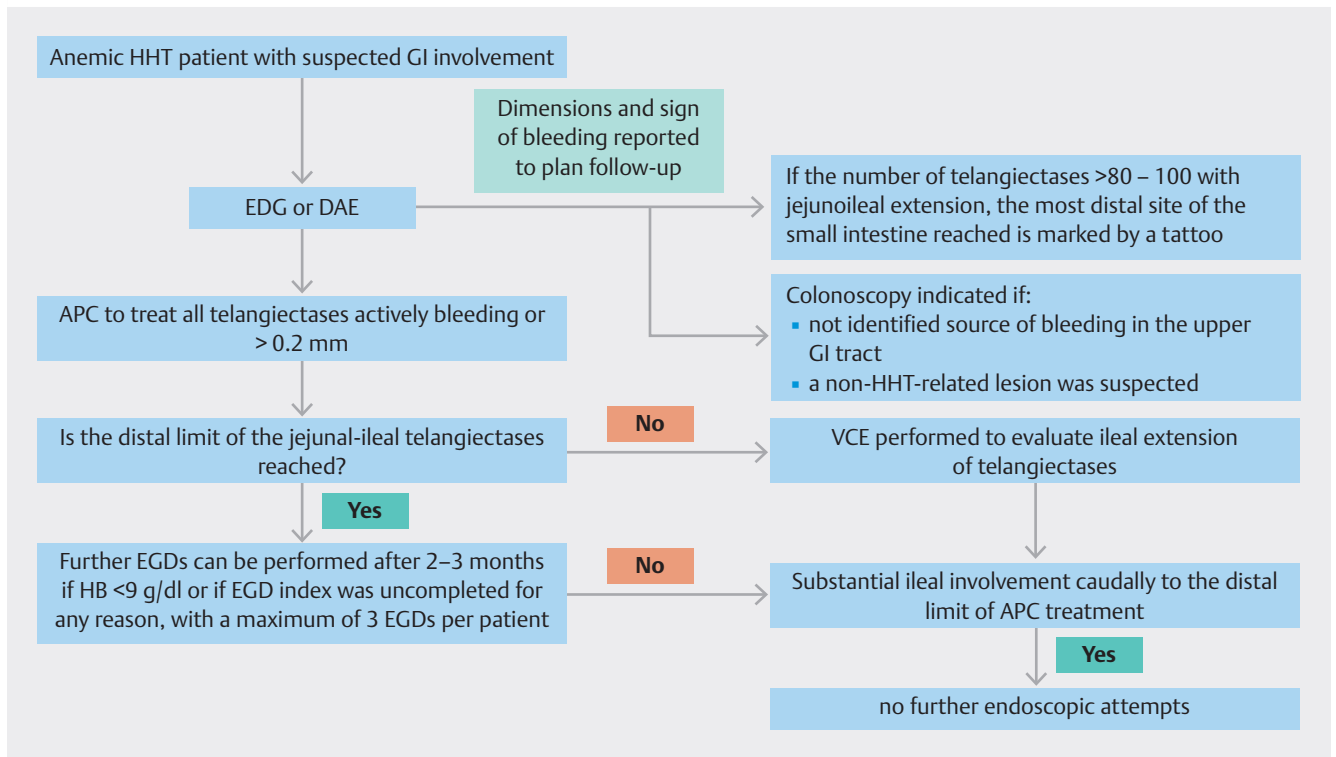
Patient population

The participants were consecutive patients with HHT who were older than age 18, able to provide written informed consent, had been diagnosed with HHT (either confirmed by genetic testing or with the three Curaçao criteria (definite diagnosis) [2]), who had iron deficiency anemia (possibly with transfusion requirement) disproportionate to epistaxis and/or overt gastrointestinal bleeding were assessed for inclusion. Patients with respiratory or cardiac diseases, implying a high risk for endoscopic procedures, were excluded.

Intervention

Patients underwent either esophagogastroduodenoscopy (EGD) or push or device-assisted enteroscopy (DAE) with a single balloon and/or colonoscopy; upper gastrointestinal evaluation was performed first unless overt lower gastrointestinal bleeding was present.

Endoscopic investigations of the upper gastrointestinal were extended to identify the distal limit of telangiectases. For each site (esophagus, stomach, duodenum, jejunum, and colon), the number of lesions, the mean diameter (in millimeters), and any



► Fig. 1 Decision tree.

sign of active or recent bleeding were reported. On the basis of the number and localization of the lesions found at the first examination, further endoscopic procedures were planned with the most appropriate modality of examination to obtain satisfactory control of bleeding with the treatment of all telangiectases that either showed signs of recent or active bleeding or were larger than 0.2 mm during every procedure; whenever the number of telangiectases exceeded 80 to 100 with jejunoileal extension, tattooing was performed to mark the most distal site of the small intestine reached.

If the distal limit of the jejunal-ileal telangiectases was not reached, VCE was performed to evaluate ileal extension of telangiectases; in case of substantial ileal involvement caudally to the distal limit of APC treatment, no further treatment was to be attempted. Colonoscopy was indicated if no source of bleeding was identified in the upper gastrointestinal tract or if a non-HHT-related lesion was suspected.

After the index procedure (s), further procedure(s) could be scheduled at an interval of 2 to 3 months if hematologic findings did not show a response to treatment and with a maximum of three endoscopic attempts per patient. All endoscopic procedures were conducted by expert endoscopists and with specific experience in digestive involvement in HHT.

► Fig. 1 shows the decision tree for patient management. Antibiotic prophylaxis (for the risk of septic paradoxical embolism in patients with HHT who had pulmonary right-to-left shunt) was administered prior to the endoscopic procedures if needed. The type of sedation was chosen based on the duration of the procedure (conscious for EGD and colonoscopy with in-

travenous (IV) midazolam, deep sedation with propofol for enteroscopy with anesthesiologist assistance).

Treatment with APC was performed with Erbe (Elektromedizin GmbH, Tübingen, DE) electrosurgical units as follows: 2002–2008, electrosurgical unit ICC 200, APC module APC 300, and setting forced coagulation APC; 2008–2019, electrosurgical unit VIO 200D, APC module APC 2, and setting pulsed APC, effect 2, flow 0.81/min, power 15 W; 2019–2020, electrosurgical unit VIO 3, APC module APC 3, and setting pulsed APC, effect 1.5, flow 0.81/min, power 15 W.

In the case of large telangiectases and/or those refractory to APC treatment, additional treatment was provided with positioning of metal clips. In case of treatment of bleeding gastric telangiectases, a 3- to 6-month course of proton pump inhibitor was recommended.

Definitions of study endpoints

Primary endpoint

For all patients, the hemoglobin (Hb) value in grams per deciliter and the transfusion requirement to keep Hb at 7 to 8 g/dL (in red cell units [RCU]/year) were assessed at baseline, before and after the endoscopic treatment at each endoscopic session, as well as during follow-up at 1- to 3-month intervals. Based on iron deficiency, an appropriate iron supplementation, either oral or IV, was suggested either during hospital admission or at discharge. During follow-up patients were advised to have periodic assessment of iron deficiency and at least at each consultation [21].

For each patient, hepatic AVMs were evaluated at enrollment and during surveillance.

Treatment effectiveness was classified as follows: 1) complete if the Hb level during the follow-up remained ≥ 9 g/dL; 2) complete with recurrence if the correction of Hb was ≥ 9 g/dL for at least 12 months followed by Hb < 9 g/dL; and 3) absent if no correction of Hb ≥ 9 g/dL was reached. For statistical analysis purposes, the first two were considered as responders.

Secondary endpoints

According to the protocol previously reported [20, 22, 23] for each patient, the mutated gene and mutation type were searched; each patient underwent a personal and family history review for the diagnosis of HHT; blood chemistry tests; echocardiography; chest computed tomography; evaluation by an ear, nose and throat specialist; and cerebral magnetic resonance imaging with contrast medium if the patient had neurological symptoms/signs and/or if the patient wished to have this exam done; hepatic color-Doppler ultrasonography was performed in all patients, and liver AVM severity was classified as previously described [20, 22]. Number, size, and site of gastrointestinal telangiectases were recorded at baseline.

Complications related to the endoscopic procedure were recorded, and their severity was defined as mild, major [need for hospital care or intervention], or fatal; regarding timing they were classified as immediate, early (within 24 hours) and late [within 30 days] [24].

Statistical analyses

Categorical variables were reported as the number of cases and percentage, whereas continuous variables were expressed as the median and interquartile range (IQR). Differences in terms of Hb levels and number of blood transfusion units before vs. after treatment were compared using the paired-sample *t* test.

All analyses were two-tailed, and the threshold of significance was assessed at ≤ 0.05 . To identify the significant predictors for treatment response and bleeding relapse, baseline parameters were entered into a univariate logistic regression model. Significant variables in the univariate analysis were entered into the multivariate model. Overall survival and the other time-to-event outcomes, namely, bleeding-related mortality and relapse-free survival, were analyzed through the Kaplan-Meier method. The statistical analysis was run using the Survival package in R Statistical Software 3.0.2 (Foundation for Statistical Computing, Vienna, Austria).

Results

Patient population

Between January 2002 and December 2020, 47 patients with HHT were considered for endoscopic treatment of gastrointestinal bleeding. The demographic and clinical characteristics of the patients at enrollment are presented in ► **Table 1**.

A total of 42 of 47 patients were deemed responders to the first 111 endoscopic treatments (mean number of exams per patient 2.4), including 41 EGDs, 50 DAEs, and 20 colonoscopies (with 62 index procedures and 49 further endoscopic treat-

► **Table 1** Baseline characteristics of the study cohort.

Males (%)	26 (55.3)
Females (%)	21 (44.7)
Age, mean (range)	58.5 (30–79)
Mutation (%)	
▪ HHT1	9 (19.1)
▪ HHT2	22 (46.8)
▪ Not identified	16 (34.1)
Liver AVMs grade (%)	
▪ 0	9 (19.1)
▪ 1	9 (19.1)
▪ 2	13 (27.7)
▪ 3	6 (12.8)
▪ 4	10 (21.3)
Hb at baseline	
▪ median g/dL (IQR)	8.5 (6.7–9.9)
▪ mean (range)	8.1 (4.4–12.2)
RCU/year	
▪ median (IQR)	4 (0–24)
▪ mean (range)	22.8 (0–190)
AVM, arteriovenous malformation; RCU, red cell units; IQR, interquartile range.	

ments performed within the first 12 (range 1–12) months after the index procedure). A total of 31 of 47 patients (66%) needed a second endoscopic attempt; 12 of 31 needed a third endoscopic attempt (25.5% of the whole cohort), and four of 12 patients (8.5% of the whole cohort) needed further endoscopic attempts (4 in 4 cases, 5 in 3 cases). VCE was performed in six cases in which the distal jejunal limit of telangiectases was not reached.

In 111 endoscopic procedures, 3691 telangiectases were treated with APC, with an average of 78.5 telangiectases per patient.

► **Table 2** summarizes the location, number, and characteristics of the treated lesions.

The median follow-up was 134 months (range 20–243 months).

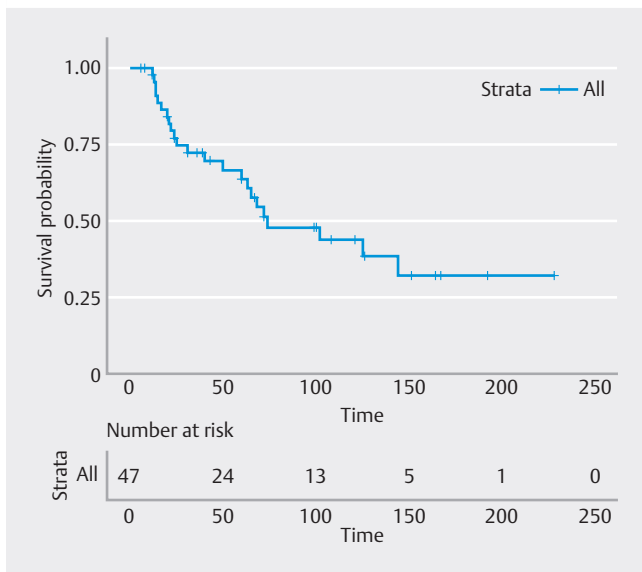
Twenty-two patients (46.8%) relapsed and required at least a second treatment attempt after a median time of 36 months (13–144 months).

► **Fig. 2** represents the relapse-free survival curve in the overall population.

In this group, a total of 22 EGDs, 22 DAEs, and eight colonoscopies were performed, for a total of 52 procedures, including 37 procedures during the second treatment and 15 in further endoscopic treatments. In particular, seven (14.9%), three (6.3%), one (2.1%), and one patient (2.1%) needed third, fourth,

► **Table 2** Total number of telangiectases treated at different sites during first treatments.

Gastrointestinal site	Number (%)	Mean diameter (mm)	% of lesions with bleeding signs (n)
Esophagus	17 (0.5)	0.2	0 (0)
Stomach	623 (16.9)	2.5	4.7 (29)
Duodenum	1259 (34.1)	1.1	0.8 (10)
Jejunum	1729 (46.8)	0.8	0.06 (1)
Colon	63 (1.7)	2.3	3.2 (2)



► **Fig. 2** Relapse-free survival curve in the overall population.

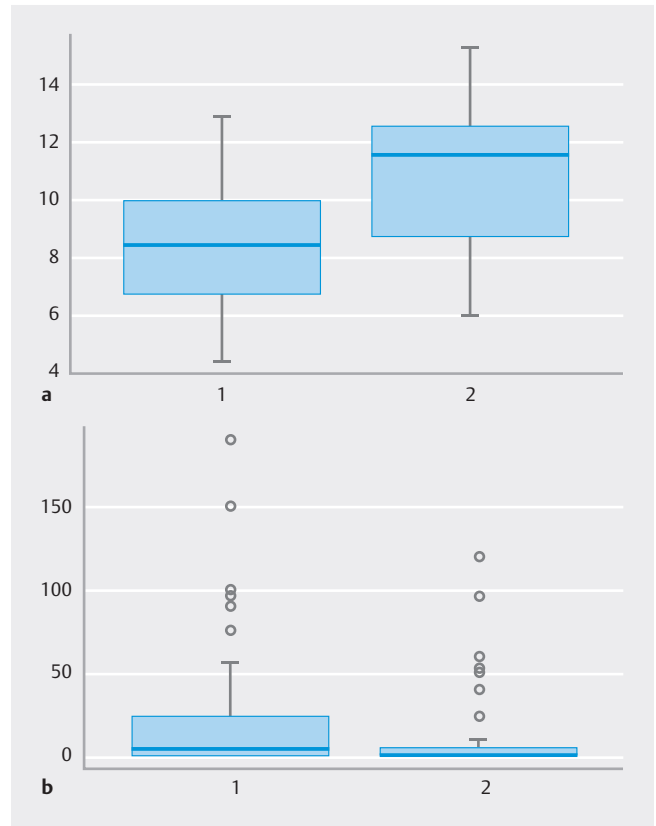
fifth, and sixth endoscopic treatments, respectively. VCE was performed in one case to assess distal jejunal involvement.

Primary outcome

Altogether, 41 of 47 patients were responders after one (14/47) or more (27/47) endoscopic treatments, and six of 47 were nonresponders. In the overall study population, we observed a significant increase in the median value of Hb from 8.5 g/dL (6.7–9.9) to 11.6 g/dL (8.7–12.5) ($P < 0.0001$) and a significant reduction in the transfusion requirement from a median of 4 RCU per year (0–24) to 0 RCU per year (0–5) ($P = 0.05$) (► **Fig. 3**).

The median hemoglobin basal level in the responders was 7.0 g/dL (4.4–12.9 g/dL), with an initial mean transfusion requirement of 22.8 RCU/year (range 0–190 RCU/year); the median hemoglobin level to the end of follow-up was 11.9 g/dL (6.0–15.3 g/dL), with a mean transfusion requirement of 7.3 RCU/year (range 0–120).

In the nonresponders, the median hemoglobin basal level was 7.0 g/dL (7.0–7.5 g/dL) with an initial mean transfusion requirement of 50 (12–100); after treatment, the median hemo-



► **Fig. 3** a Median value of Hb before (1) and after treatment (2). b Transfusion requirement before (1) and after treatment (2).

globin level was 7.2 g/dL [7.0–7.5 g/dL], and the mean transfusion requirement was 34 RCU/year (range 0–96).

The characteristics of the responders and nonresponders are shown in **Supplementary Table 1**.

Secondary outcomes

As reported in ► **Table 3**, in the logistic regression analysis, a higher baseline number of telangiectases was associated with a lower chance of response ($P = 0.008$).

Seventeen patients died during follow-up. Death was related to HHT-related gastrointestinal bleeding in two patients and to other complications of HHT in eight patients, and it was not related to HHT complications in seven patients. One patient with grade IV liver AVM underwent orthotopic liver transplantation.

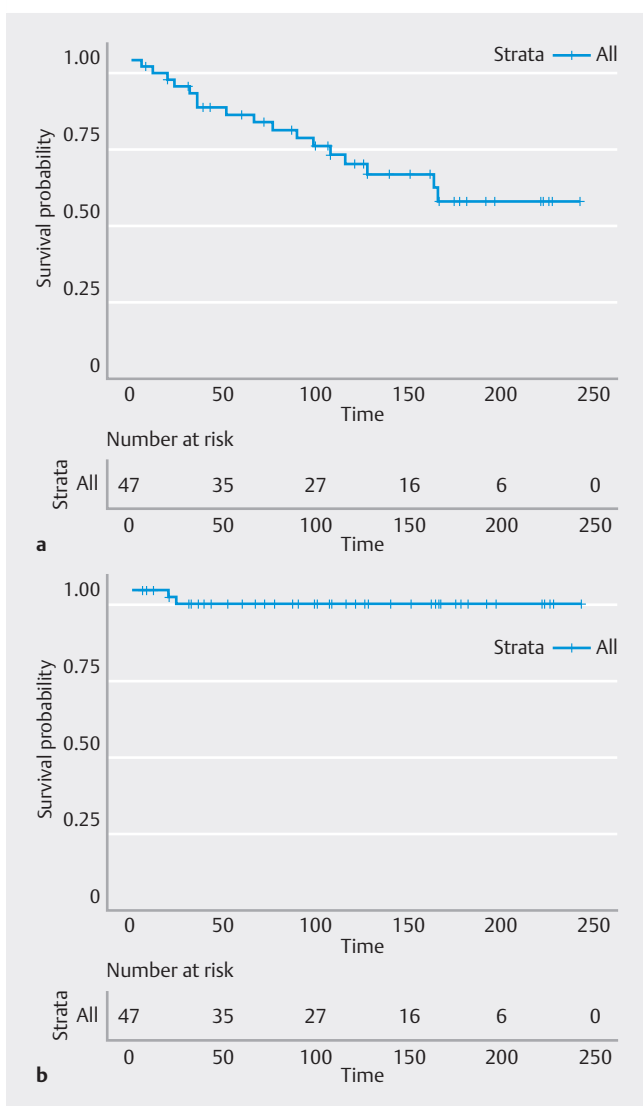
► **Fig. 4** shows the overall survival and bleeding-related mortality in the study population.

There were two mild complications in 228 endoscopic procedures (0.8%), a substantial nosebleed during upper gastrointestinal endoscopy, conditioning the interruption of the examination and its repetition, one immediate and major complication (0.4%), and a jejunal perforation that required segmental jejunal resection. There were no late or fatal complications related to the procedure.

► **Table 3** Factors associated with clinical response to endoscopic treatment.

Variable	OR (95% CI)	P value
Sex (reference female)	0.39 (0.06–2.38)	0.43
Age	0.34 (0.08–1.41)	0.21
Gene (reference 1)	0.09 (0.008–1.09)	0.06
Liver AVMs grade (reference 1)	0.35 (0.03–3.44)	0.37
No. gastrointestinal telangiectases	0.17 (0.04–0.63)	0.008
Gastrointestinal telangiectases size	0.36 (0.06–2.09)	0.26
Gastrointestinal telangiectases site	0.23 (0.03–1.43)	0.11

OR, odds ratio; AVM, arteriovenous malformation.



► **Fig. 4** **a** Overall survival. **b** Bleeding-related mortality in the study population.

Discussion

Patients with HHT who have gastrointestinal bleeding can suffer from anemia that is often severe and can make them chronically dependent on parenteral iron and/or blood transfusions [5, 21]. This is accompanied by frequent hospitalizations, which have a tremendous impact on quality of life, place a burden on health care, and have an individual and societal impact.

According to the Second International Guidelines for the Diagnosis and Management of Hereditary Hemorrhagic Telangiectasia, endoscopic APC is best administered at baseline endoscopy for bleeding [5]. However, even though endoscopic APC is the first line of therapy in non-HHT gastrointestinal vascular lesions [25], scant data support its systematic use in patients with HHT who have gastrointestinal bleeding.

In previous studies dating back to the 1980s and 1990s, endoscopic APC of gastrointestinal telangiectases in HHT was shown to provide temporary control of transfusion requirements. While discrete lesions may respond well to local treatment, most patients with HHT have multiple AVMs, and some symptomatic lesions may not be accessible to APC. As a consequence, more than half of the patients (56%) are refractory to APC therapy [15, 16, 17, 18, 26]. Naveau et al. [18] described the use of neodymium-YAG laser photocoagulation in 60 patients (13 with HHT and 47 with angiodysplasias) and examined prognostic parameters of bleeding recurrence; the initial number of angiodysplasias ($P < 0.02$) showed an independent prognostic value. In more recent years, in a cohort of 44 patients with small bowel angiodysplasias [19], bleeding could be effectively treated with APC during enteroscopy with a long-term increase in Hb levels and reduced blood transfusion requirements; however, the cohort of eight patients with HHT in this study had a lower response rate with a higher bleeding recurrence in comparison with patients who did not have HHT (75% vs. 40%). The authors concluded that efforts are needed to reduce the rebleeding rate, possibly through a more intensive initial treatment.

Previous literature about the results of endoscopic treatment for bleeding gastrointestinal telangiectases in patients with HHT has other important flaws. Thus far, this topic has been reported in only small series including 40 patients overall (range 4–13); long-term results were reported only for a minority of patients [15, 16, 17, 18, 19, 26]. All these series included mainly patients with small bowel angiodysplasias and only a minority of patients with HHT. The number of endoscopic attempts per patient was highly variable in these series. Specific expertise in dealing with patients with HHT was not reported in these series.

On the basis of these studies, which had substantial limitations, the studies were mostly performed with technology and examination techniques that are currently largely outdated, and neither the long-term effectiveness of endoscopic treatment of bleeding telangiectases in HHT nor the complication rate of repeated treatments nor a clear correlation between treatment outcome and patient characteristics can be inferred.

The strengths of the present study, therefore, are many. First, was is a monocentric study performed within an expert

reference center for HHT, which can address all aspects of the disease and inherent needs, including attention to antibiotic prophylaxis and limiting the potential for other complications of endoscopic procedures in patients with HHT, such as nosebleeds during upper gastrointestinal endoscopy. Second, with 47 patients enrolled, this study described the results of APC treatment in the largest series of patients with HHT thus far reported in the literature, thus adding a substantial piece of information to the difficult management of gastrointestinal bleeding in HHT. Third, the present cohort homogeneously included only patients with HHT and was not patients with sporadic gastrointestinal angiodysplasias, thus avoiding the risk of a heterogeneous population and inherent biases in data interpretation. Fourth, with a median follow-up of 134 months (range 20–243 months), the present cohort has the longest follow-up described in the literature after APC treatment of gastrointestinal telangiectases in HHT, thus allowing a sound weighing of the long-term results of endoscopic APC in this setting.

Fifth, the study design allowed us to capture adverse events and to appropriately assess the safety of endoscopic APC for HHT gastrointestinal telangiectases; the 0.4% rate of major complications found in our study supports the safety of this treatment for bleeding gastrointestinal telangiectases in HHT. Sixth, this study allowed us to consistently understand the factors correlated with response to endoscopic treatment of gastrointestinal telangiectases in patients with HHT. Age, sex, severity of liver vascular malformations, and size or site of gastrointestinal telangiectases did not correlate with response; the only characteristic significantly associated with a lower chance of response was a baseline higher number of telangiectases, as previously noted in non-HHT cohorts [18]. Interestingly, the mutation in the endoglin gene shows a trend toward significance for correlation with treatment response.

With these characteristics, the present study provided a sound demonstration of the substantial long-term effectiveness of endoscopic APC treatment of gastrointestinal telangiectases in HHT; the 87.2% response rate over a median follow-up longer than 10 years is actually a reassuring figure. The two deaths related to gastrointestinal bleeding occurred within 2 years and were due to the severity of the patients' conditions aside from the lack of response of the bleeding itself. In fact, the nonresponder cohort included older patients with a higher mortality rate.

The present study also had some limitations. First, it was performed in an HHT referral center; thus far, the results described may not be reproducible in other centers with lesser or no specific HHT expertise. Second, the endoscopic treatments were performed using the "push" enteroscopy technique, which may not reach the same depth in all cases and does not explore the entire small bowel. Moreover, the possibility of progress with the enteroscope and consequently its effectiveness is anatomy-related; thus, we cannot exclude that other enteroscopy techniques (e.g., double balloon or spiral enteroscopy) would have further improved patient outcomes.

Conclusions

In conclusion, the present study demonstrates the long-term effectiveness of endoscopic treatment of bleeding from gastrointestinal telangiectases in patients with HHT, all along with its safety; these data are useful for clinical management of this difficult condition.

Conflict of Interest

Guido Manfredi: teaching fee from Fujifilm. Stefano Francesco Crinò: paid speaker for Steris Endoscopy. Elisabetta Buscarini: consultant for Olympus, teaching fee from Fujifilm. No other potential conflict of interest relevant to this article was reported.

Funding

Italian Association for Hereditary Hemorrhagic Telangiectasia "Onilde Carini" This study has been funded with an unrestricted grant by Italian Association for Hereditary Hemorrhagic Telangiectasia "Onilde Carini". The funding body had no role in the design of the study and collection, analysis, and interpretation of data nor in writing the manuscript.

References

- [1] Shovlin CL, Buscarini E, Kjeldsen AD et al. European Reference Network For Rare Vascular Diseases (VASCERN) Outcome Measures For Hereditary Haemorrhagic Telangiectasia (HHT). *Orphanet J Rare Dis* 2018; 13: 136 doi:10.1186/s13023-018-0850-2
- [2] Shovlin CL, Guttmacher AE, Buscarini E et al. Diagnostic criteria for hereditary hemorrhagic telangiectases (Rendu-Osler-Weber syndrome). *Am J Med Genet* 2000; 91: 66–67 doi:10.1002/(sici)1096-8628(20000306)91:1<66::aid-ajmg12>3.0.co;2-p
- [3] McDonald J, Woodechak-Donahue W, VanSant Webb C et al. Hereditary hemorrhagic telangiectases: genetics and molecular diagnostics in a new era. *Front Genet* 2015; 6: 1
- [4] Pagan JC, Buscarini E, Janssen HLA et al. European Association for the Study of the Liver. Vascular diseases of the liver. *J Hepatol* 2016; 64: 179–202
- [5] Faughnan ME, Mager JJ, Hetts SW et al. Second International Guidelines for the Diagnosis and Management of Hereditary Hemorrhagic Telangiectasia. *Ann Intern Med* 2020; 173: 989–1001 doi:10.7326/M20-1443
- [6] Letteboer TG, Mager JJ, Snijder RJ et al. Genotype-phenotype relation in hereditary hemorrhagic telangiectases. *J Med Genet* 2006; 43: 371–377
- [7] Lesca G, Olivieri C, Burnichon N et al. Genotype-phenotype correlations in hereditary hemorrhagic telangiectases: data from the French-Italian HHT network. *Genet Med* 2007; 9: 14–22
- [8] Canzonieri C, Centenara L, Ornati F et al. Endoscopic evaluation of gastrointestinal tract in patients with hereditary hemorrhagic telangiectases and correlation with their genotypes. *Genet Med* 2014; 16: 3–10
- [9] Grève E, Moussata D, Gaudin JL et al. High diagnostic and clinical impact of small-bowel capsule endoscopy in patients with hereditary hemorrhagic telangiectases with overt digestive bleeding and/or severe anemia. *Gastrointest Endosc* 2010; 71: 760–767 doi:10.1016/j.gie.2021.11.030

- [10] Chamberlain SM, Patel J, Carter Balart J et al. Evaluation of patients with hereditary hemorrhagic telangiectases with video capsule endoscopy: a single-center prospective study. *Endoscopy* 2007; 39: 516–520
- [11] Ingrosso M, Sabbà C, Pisani A et al. Evidence of small-bowel involvement in hereditary hemorrhagic telangiectases: a capsule-endoscopic study. *Endoscopy* 2004; 36: 1074–1079 doi:10.1055/s-2004-826045
- [12] Longacre AV, Gross CP, Gallitelli M et al. Diagnosis and management of gastrointestinal bleeding in patients with hereditary hemorrhagic telangiectases. *Am J Gastroenterol* 2003; 98: 59–65
- [13] Proctor DD, Henderson KJ, Dziura JD et al. Enteroscopic evaluation of the gastrointestinal tract in symptomatic patients with hereditary hemorrhagic telangiectases. *J Clin Gastroenterol* 2005; 39: 115–119
- [14] Kjeldsen AD, Kjeldsen J. Gastrointestinal bleeding in patients with hereditary hemorrhagic telangiectases. *Am J Gastroenterol* 2000; 95: 415–418 doi:10.1111/j.1572-0241.2000.01792.x
- [15] Sargeant IR, Loizou LA, Rampton D et al. Laser ablation of upper gastrointestinal vascular ectasias: long term results. *Gut* 1993; 34: 470–475 doi:10.1136/gut.34.4.470
- [16] Gostout CJ, Bowyer BA, Ahlquist DA et al. Mucosal vascular malformations of the gastrointestinal tract: clinical observations and results of endoscopic neodymium: yttrium-aluminum-garnet laser therapy. *Mayo Clinic proceedings* 1988; 63: 993–1003 doi:10.1016/s0025-6196(12)64914-3
- [17] Bown SG, Swain CP, Storey DW et al. Endoscopic laser treatment of vascular anomalies of the upper gastrointestinal tract. *Gut* 1985; 26: 1338–1348 doi:10.1136/gut.26.12.1338
- [18] Naveau S, Aubert A, Pynard T et al. Long-term results of treatment of vascular malformations of the gastrointestinal tract by neodymium YAG laser photocoagulation. *Dig Dis Sci* 1990; 35: 821–826
- [19] May A, Friesing-Sosnik T, Manner H et al. Long-term outcome after argon plasma coagulation of small-bowel lesions using double-balloon enteroscopy in patients with mid-gastrointestinal bleeding. *Endoscopy* 2011; 43: 759–765
- [20] Buscarini E, Buscarini L, Danesino C et al. Hepatic vascular malformations in hereditary hemorrhagic telangiectases: Doppler sonographic screening in a large family. *J Hepatol* 1997; 26: 111–118 doi:10.1016/s0168-8278(97)80017-7
- [21] Shovlin CL, Buscarini E, Kjeldsen AD. European Reference Network For Rare Vascular Diseases (VASCERN). et al. Outcome Measures For Hereditary Haemorrhagic Telangiectasia (HHT). *Orphanet J Rare Dis* 2018; 13: 136
- [22] Buscarini E, Danesino C, Olivieri C et al. Doppler ultrasonographic grading of hepatic vascular malformations in hereditary hemorrhagic telangiectases – results of extensive screening. *Ultraschall Med* 2004; 25: 348–355 doi:10.1055/s-2004-813549
- [23] Buscarini E, Leandro G, Conte D et al. Natural history and outcome of hepatic vascular malformations in a large cohort of patients with hereditary hemorrhagic teleangiectasia. *Dig Dis Sci* 2011; 56: 2166–2178
- [24] Cotton PB. Outcomes of endoscopy procedures: struggling towards definition. *Gastrointest Endosc* 1994; 40: 514–518 doi:10.1016/s0016-5107(94)70228-4
- [25] Becq A, Rahmi G, Perrod G et al. Hemorrhagic angiodysplasia of the digestive tract: pathogenesis, diagnosis, and management. *Gastrointest Endosc* 2017; 86: 792–806 doi:10.1016/j.gie.2017.05.018
- [26] Rutgeerts P, Van Gompel F, Geboes K et al. Long term results of treatment of vascular malformations of the gastrointestinal tract by neodymium Yag laser photocoagulation. *Gut* 1985; 26: 586–593 doi:10.1136/gut.26.6.586