

N-Butyl Cyanoacrylate Transvenous Arteriovenous Malformation Embolization with Arterial Balloon Assistance: Defining Parameters for a Transvenous Approach as a Potential Upfront Treatment Option in Managing Cerebral Arteriovenous Malformations

Abstract

Complete obliteration of arteriovenous malformations (AVMs) using a transvenous approach as the primary and stand-alone treatment modality has been increasingly considered as a useful endovascular approach in the treatment of AVMs. AVMs are typically treated with microsurgery, stereotactic radiosurgery, endovascular embolization, or some combination of the three methods. Preservation of the draining vein is a key requisite common to all treatment modalities. Transvenous embolization (TVE) is conventionally not recommended as a stand-alone treatment for the vast majority of AVMs and has been thought to be best indicated when traditional approaches are considered less safe and when specific evaluation criteria are met. We report a case of a 35-year-old asymptomatic male diagnosed with a small intracranial AVM adjacent to the right motor strip which was managed utilizing this approach. We employed endovascular embolization via a transvenous approach with arterial balloon assistance due to the small size of the nidus, eloquent location, *en passage* arterial supply proximal to the venous varix, and a single draining vein from the fistula. This case illustrates the selective indications and technical nuances of TVE approach in managing AVMs as a potential upfront treatment option. When patients harbor AVMs with specific angio-architectural findings as outlined, TVE utilizing Onyx or N-butyl cyanoacrylate can be safely performed as a primary treatment modality.

Keywords: Arteriovenous malformation, balloon assistance, transvenous embolization

Introduction

Arteriovenous malformations (AVMs) of the brain parenchyma are frequently encountered vascular anomalies with a myriad of clinical presentation. An inherent defect in the vascular smooth muscle layer predisposes them to hemorrhage which can be potentially fatal. These lesions can be managed by conventional microsurgical excision, stereotactic radiosurgery (SRS), endovascular embolization, or some combination of the three depending largely on their size and anatomic location, clinical presentation, and angio-architecture of the AVM.^[1,2] Obliteration of the arterial feeders with the preservation of venous drainage is the key factor common to all of these treatment modalities.

Endovascular approaches offer the neuro-interventionalist minimally invasive approach that can be utilized as a part

of SRS or presurgical strategy or as a potentially curative option. Transarterial embolization (TAE) approach is commonly employed to identify and obliterate the arterial feeders to the nidus and to penetrate the substance of the AVM. AVMs that lack a discrete arterial supply may not be amenable to endovascular treatment via a transarterial route. Such lesions can be considered for embolization through the venous side and embolized in a retrograde manner. A steep learning curve, technical challenges, and risk of complications have limited the utilization of this approach.^[3-5] However, Transvenous embolization (TVE) has a significant potential as an upfront treatment option in managing certain angio-architectural subtypes of AVMs effectively that theoretically could result in improved outcomes over current conventional treatment.

This is an open access journal, and articles are distributed under the terms of the Creative Commons Attribution-NonCommercial-ShareAlike 4.0 License, which allows others to remix, tweak, and build upon the work non-commercially, as long as appropriate credit is given and the new creations are licensed under the identical terms.

For reprints contact: reprints@medknow.com

**Catherine Higbie,
Deepak Khatri,
Barbara Ligas,
Rafael Ortiz,
David Langer**

*Department of Neurosurgery,
Lenox Hill Hospital, New York
City, New York, USA*

Address for correspondence:
Dr. David Langer,
Lenox Hill Hospital, 3 Black
Hall, 130 E 77th ST, New York
City, New York 10075, USA.
E-mail: dlang@northwell.edu

Access this article online

Website: www.asianjns.org

DOI: 10.4103/ajns.AJNS_357_19

Quick Response Code:



How to cite this article: Higbie C, Khatri D, Ligas B, Ortiz R, Langer D. N-butyl cyanoacrylate transvenous arteriovenous malformation embolization with arterial balloon assistance: Defining parameters for a transvenous approach as a potential upfront treatment option in managing cerebral arteriovenous malformations. *Asian J Neurosurg* 2020;15:434-9.

Submitted: 10-Dec-2019 **Revised:** 03-Jan-2020
Accepted: 08-Feb-2020 **Published:** 07-Apr-2020

Case Report

Our patient was a 35-year-old asymptomatic male who was incidentally found to have a small (2 cm) intracranial AVM located in the right precentral cortical location on the dorsolateral aspect on a screening magnetic resonance imaging (MRI) of the head [Figure 1]. Magnetic resonance angiogram showed that the AVM was being supplied by distal M4 branches with the varix draining into the vein of Labbe through an intermediate vein and subsequently into the right transverse sinus [Figure 1]. No evidence of deep venous drainage was observed. Next, functional MRI was performed which determined the perilesional parenchyma to be eloquent [Figure 1]. Based on the size (2 cm) and eloquence, the patient was diagnosed with a Spetzler–Martin (SM) Grade II AVM.

A diagnostic angiogram was done which revealed a compact nidus with multiple *en passage* arterial feeders and a single draining venous varix [Figure 2]. It was determined that a safe embolization would be difficult to perform through a transarterial approach. Microsurgical excision and radiosurgery were considered as well. Given the high likelihood of at least a temporary if not permanent deficit with either SRS or microsurgery, we felt after reviewing the diagnostic portion of the study that the angioarchitecture was ideal for a TVE. The patient consented to the proposed procedure. A thorough understanding of the venous anatomy

was required before moving forward with a venous approach considering the venous varix proximal to the drainage via vein of Labbe as well as the acute angulation of the vein of Labbe at its drainage into the transverse sinus [Figure 2]. Under general anesthesia, a short angiographic sheath (6F size) was introduced into the right common femoral artery using modified Seldinger's technique. A Chaperon (MicroVention, Inc., CA) guide catheter with a vertebral inner catheter was then advanced up to the origin of the right common carotid artery and standard roadmap views (both anteroposterior and lateral) were obtained. Using roadmap guidance, a distal internal carotid artery (ICA) access catheter was further advanced coaxially with a Prowler 14 (DePuy Synthes Companies, MA) microcatheter in the distal middle cerebral artery. Selective distal middle cerebral arterial injection revealed the presence of *en passage* right middle cerebral branch supply to the AVM nidus with multiple small distal M4 branches with and a venous varix. Considering the lack of a clearly defined arterial feeder in our patient, a decision was made in favor of endovascular embolization via transvenous approach.

The left common femoral vein was accessed using a 5F short angiographic sheath. An Envoy 5F (DePuy Synthes Companies, MA) catheter was then initially navigated into the right transverse sinus over a 0.035 size Bentson microguidewire (Boston Scientific, MA). The vein of Labbe could not be accessed via the right transverse sinus directly due to the acute angulation at their junction [Figure 2]. We then removed the Envoy (DePuy Synthes Companies, MA) from the right transverse sinus and accessed the left transverse sinus. Given the new access distance from the left transverse sinus to the right vein of Labbe and into the proximal nidal drainage, a much longer catheter (180 cm) was required due to the alternate trajectory. Venous access was then secured using a non-Onyx-compatible Prowler 14 (DePuy Synthes Companies, MA) microcatheter (180 cm length) by navigating through the transverse sinuses from the left side to the right side and eventually to the venous varix via Labbe's vein. Positioning of the venous catheter inside the varix was confirmed by microinjection. Little contrast was observed exiting the fistula, indicating that the catheter was occlusive. The arterial balloon (Scepter C 4 mm × 10 mm) (MicroVention Inc., CA) was then advanced through the Chaperon (MicroVention, Inc., CA) guide catheter in the right ICA to the arterial feeder and secured with roadmap assistance over a microwire. With the balloon inflated, contrast was injected into the varix from the venous side to confirm occlusion of the arterial flow.

With the Sceptre C (MicroVention Inc., CA) balloon inflated, 33% N-butyl cyanoacrylate (NBCA)/ethiodol mixture was then injected slowly through the Prowler 14 (DePuy Synthes Companies, MA) microcatheter into the venous varix. The varix expanded upon injection and trace

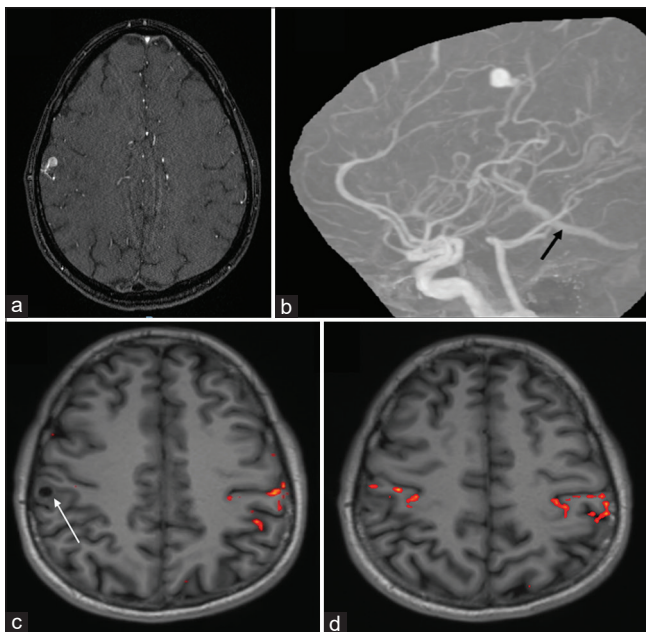


Figure 1: (a) Magnetic resonance imaging (axial view) demonstrating a small (about 2 cm) arteriovenous malformations located in the right precentral cortical location on the dorsolateral aspect. (b) Magnetic resonance angiogram (lateral view) showed that the arteriovenous malformations was being supplied by distal M4 branches with the venous varix draining into the vein of Labbe through an intermediate vein (black arrow) and subsequently into the right transverse sinus. No evidence of deep venous drainage was observed. (c and d) Functional magnetic resonance imaging axial views showing the eloquence of perilesional brain parenchyma

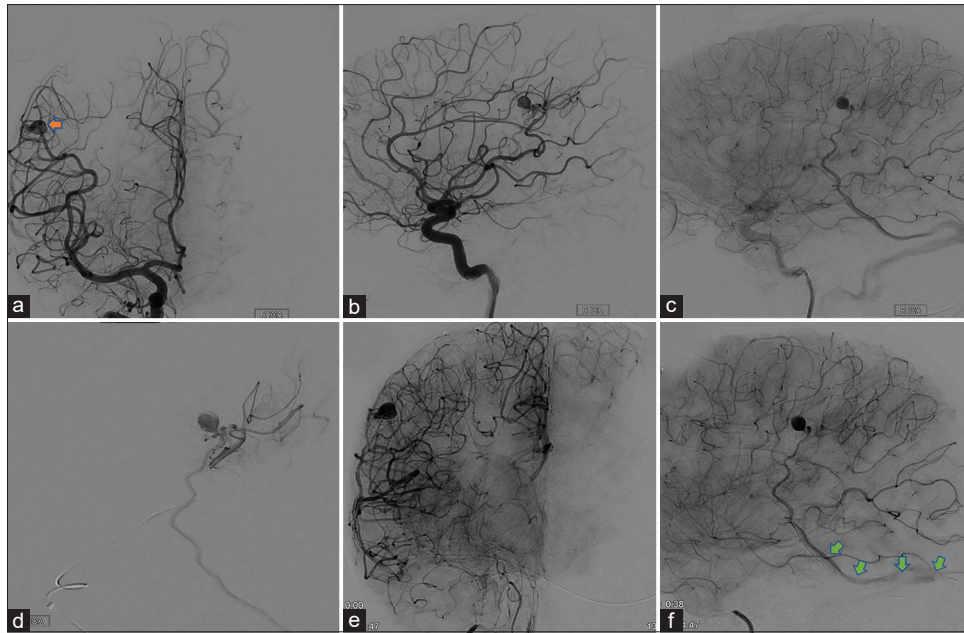


Figure 2: (a and b) A diagnostic angiogram was done which revealed a compact nidus with multiple small *en passage* arterial feeders from middle cerebral artery and a single draining venous varix (Orange arrow) in anteroposterior and lateral views. (c) Venous phase angiogram showing the drainage through the vein of Labbe into the right transverse sinus with an acute angulation. (d) Branch of middle cerebral artery supplying the nidus was selectively catheterized. (e and f) The draining vein was approached through the left side which provided a longer, but, more suitable trajectory (green arrows)

amounts of NBCA were carried through the draining vein and the vein of Labbe prior to catheter extraction [Figure 3]. Following the catheter removal, the balloon was deflated and complete AVM occlusion on the arterial side was confirmed in an arterial angiogram. The procedure was completed uneventfully and the patient recovered well in the postoperative period without neurological deficit.

Discussion

Microsurgical excision, SRS, and endovascular embolization, typically through the arterial feeder, are common modalities of treatment in AVMs. Clinical presentation, size, location, and angio-anatomy of the nidus often dictate the treatment modality to be used.

Close proximity of the AVM to eloquent brain increases the risk for safe microsurgical resection.^[6] In patients with nidus volume of $<3 \text{ cm}^3$ treated with SRS, 1.9%–10% of patients experience hemorrhage and 2%–3% of cases develop irreversible neurological damage.^[6-8] The risk may be even higher for patients with small AVMs in eloquent locations. If a clearly defined arterial feeder is identified angiographically, TAE can be safely presumed to be the most effective modality of treatment. When complex angioarchitecture of the nidus renders the AVM inaccessible via the arterial end, consideration of treatment utilizing a transvenous approach can be considered; however, arterial control as well as venous architecture plays a significant role in the safety profile of TVE.^[3-5] Systemic or local hypotension is often helpful when embolizing an AVM through the venous side. Temporary arterial balloon placement as permitted by the arterial anatomy

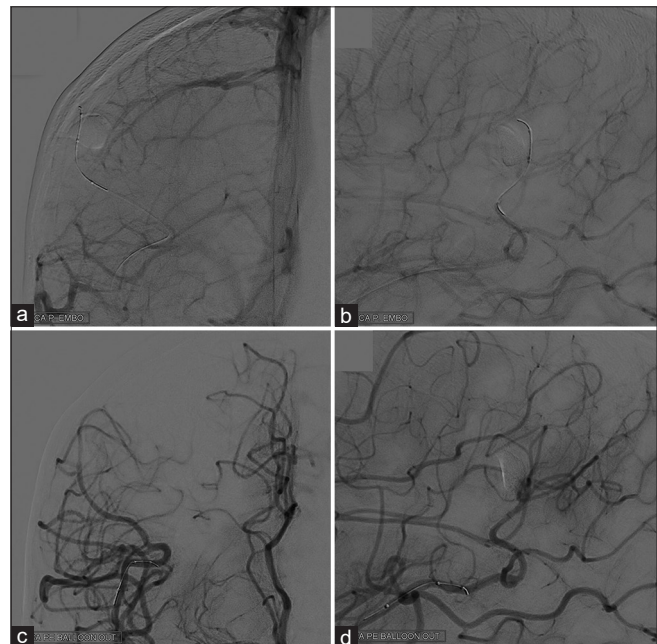


Figure 3: (a and b) Postembolization angiograms showing a complete obliteration of the arteriovenous malformations nidus in anteroposterior and lateral views. (c and d) Angiogram was done at the end of the procedure after removing the arterial balloon

may further optimize the safety of nidus occlusion by this method. Primary risks associated with TVE include premature occlusion of the venous drainage or inadvertent arterial occlusion resulting in hemorrhage or ischemia.^[9] If carefully performed, TVE is an effective method to avoid potentially irreversible damage to eloquent tissue from radiation or edema from microsurgery. Experience with this

Table 1: A summary of previously reported arteriovenous malformations cases which utilized transvenous embolization as an upfront treatment approach

Study	Age/sex	Location/size/ SM grade	Clinical presentation	Rationale for TVE approach	Agent used	Transarterial assistance	Outcome	Intra-operative complications	Postoperative complications
Nguyen <i>et al.</i> , 2010 ^[13]	50/male	Left sylvian, size <1 cm (SM Grade III)	Global aphasia and right hemiplegia with left intraopercular front parietal parenchymal hematoma	Multiple <i>en-passage</i> arterial feeders Single drainage via vein of Labbe	Onyx	Onyx 34 was injected at the arterial end of the nidus	Complete occlusion	Occlusion of left Rolandic feeder artery	Patient developed generalized seizures on day of procedure
Kessler <i>et al.</i> , 2011 ^[14]	57/male	Right CP angle, 1 cm (SM Grade III)	Hemorrhage	SCA feeder Single drainage via Pontine vein	Onyx	Systemic hypotension	Complete occlusion	Nil	Nil
	32/male	Left basal ganglia, 2 cm (SM Grade III)	Hemorrhage	Lenticulostriate feeder from M1 segment ICV drainage with venous stenosis			Complete occlusion	Nil	Nil
	19/ female	Choroid plexus of right lateral ventricle, 2 cm (SM Grade III)	Headache, left hemiparesis with right thalamic and intraventricular hemorrhage	Anterior and lateral posterior choroidal arterial feeders with aneurysm Single, deep venous drainage via ICV, VOG, SS			Partial occlusion Patient was sent to a GK radiosurgery service for adjunctive treatment, and a follow-up angiography was scheduled in 2 years	Nil	Nil
Consoli <i>et al.</i> , 2013 ^[15]	23/ female	Left thalamo- mesencephalic, <3 cm (SM Grade III)	Prior history of hemorrhage with moderate right hemiparesis, a slight left seventh cranial nerve palsy, left ptosis, and a partial deficit of the homolateral cranial nerve III with left mydriasis	Feeders from distal Acho A and thalamogeniculate perforators Single drainage via left peduncular vein	Onyx	Balloon	Complete occlusion	Nil	Nil
Pereira <i>et al.</i> , 2013 ^[16]	31/male	Medial wall of occipital horn in right lateral ventricle, 2 cm (SM grade II)	Headache, vomiting with right lateral ventricular hemorrhage	Multiple feeders from posterior choroidal artery Single, deep venous drainage via ICV, VOG, SS	Squid 18	Balloon	Complete occlusion	Nil	Nil
Trivelato <i>et al.</i> , 2014 ^[17]	56/male	Right middle cerebellar peduncle, 0.8 cm (SM Grade II)	Sudden onset headache with SAH in prepontine cistern	Multiple feeders from double-origins right SCA and internal auditory artery with aneurysm Single, deep venous drainage via SPS	Onyx	Not reported	Complete occlusion	Nil	Patient developed edema of right lateral surface of pons with V1 hypoesthesia which improved 1 month later

Contd...

Table 1: Contd...

Study	Age/sex	Location/size/ SM grade	Clinical presentation	Rationale for TVE approach	Agent used	Transarterial assistance	Outcome	Intra-operative complications	Postoperative complications
Zhang et al., 2017 ^[18]	58/ female	Left basal ganglia, 2 cm (SM Grade III)	Hemorrhage	Multiple feeders from lenticulostriate arteries, and left ACA	Onyx, coils	Balloon	Complete occlusion	Nil	Nil
Present case	35/ male	Right precentral cortical AVM, 2 cm (SM Grade II)	Asymptomatic	Single draining vein Multiple <i>en-passage</i> feeders from M4 segment Venous drainage via vein of labbe with a proximal venous varix	NBCA glue	Balloon	Complete occlusion	Nil	Nil

AVM – Arteriovenous malformation; SM – Spetzler-Martin; SAH – Subarachnoid hemorrhage; SCA – Superior cerebellar artery; ICV – Internal cerebral vein; VOG – Vein of Galen; ACA – Anterior cerebral artery; NBCA – N-butyl cyanoacrylate; TVE – Transvenous embolization; SS – Straight sinus; GK – Gamma knife

technique is growing and there exists a significant potential to its clinical applications.

Incidental diagnosis of an AVM in an eloquent location such as our patient has become a management dilemma, especially in the post-ARUBA trial era. However, with the advent of newer microcatheters and embolizing materials, neurosurgeons and neuro-interventionalists frequently consider endovascular treatment as a component of treatment. Where appropriate, TVE may increase the frequency of curative embolization when patients are carefully selected.

Experience with transvenous retrograde embolization of the AVMs has risen in the recent few years. Commonly agreed criteria for TVE include – small size (<3 cm), deeply seated nidus, lesions in eloquent location, lesions not amenable to microsurgical excision or SRS, ill-defined arterial feeders, inability to access the arterial supply, *en passage* arteries, and single venous drainage of the AVM.^[10-12] Viana et al. were able to establish the application of TVE in superficial AVMs in their case series.^[11] Table 1 summarizes the number of cases reported so far which utilized the TVE approach as an upfront option in managing AVMs.^[13-18] Inability to access the arterial supply due to multiple small feeders in a deep-seated AVM was the leading rationale in all of these cases. Seven of 8 previous cases achieved complete occlusion of the nidus via an upfront TVE approach. Two patients developed complications in the form of inadvertent feeder branch occlusion and transient V1 hypoesthesia.

Our patient harbored an asymptomatic SM Grade II AVM in an eloquent region with significant risks associated with both SRS and microsurgery. The angio-anatomical complexity rendered a TAE high risk. We elected to treat the AVM utilizing a transvenous approach due to our ability to control the arterial side as well as due to its discrete single venous drainage outflow. We were able to demonstrate that an immediate complete occlusion of the nidus was achievable with the good outcome which further extends the utilization of TVE in such seemingly innocuous yet “deficit-prone” low-grade cortical AVMs.

It is interesting to note that none of the previous cases have utilized glue as embolizing material. In a previous study, authors have identified the usage of glue to be unsuitable in TVE approach due to the potential risk of immediate occlusion of draining vein.^[12] However, we were successful in achieving complete occlusion of the nidus using glue without any complications. We considered NBCA as an appropriate choice because a longer microcatheter (180 cm) was required in our case as opposed to the usual length (150 cm) of Onyx-compatible microcatheter. Inadvertent early occlusion of draining vein and reflux was avoided by effectively occluding the draining vein using the diameter of the microcatheter, and flow arrest was established by inflating the balloon on the arterial side

of the fistula. Thus, a good control of the injection was maintained with no significant outflow from the fistula into the draining vein. Arterial embolization using NBCA has shown complete occlusion rates typically between 5% and 15%, with earlier studies indicating a cure rate of up to 40%.^[19] Therefore, NBCA may still be considered in embolizing certain AVMs via this approach.

Arterial flow reduction is essential to safe TVE. Published studies initially utilized systemic hypotension; however, arterial balloon assistance when suitable is favored in our opinion. While performing TVE, induced hypotension by using a temporary arterial balloon placement is an effective strategy to eliminate or reduce arterial inflow into the nidus, thus improving venous side nidal embolic penetration and avoiding reflux of embolizing material while lowering the risk and controlling arterial side rupture.

Conclusion

When patients harbor AVMs with specific angio-architectural findings as outlined, TVE utilizing Onyx or NBCA can be safely performed as a primary treatment modality.

Financial support and sponsorship

Nil.

Conflicts of interest

There are no conflicts of interest.

References

1. Valavanis A, Yaşargil MG. The endovascular treatment of brain arteriovenous malformations. *Adv Tech Stand Neurosurg* 1998;24:131-214.
2. Ding D, Starke RM, Sheehan JP. Radiosurgery for the management of cerebral arteriovenous malformations. *Handb Clin Neurol* 2017;143:69-83.
3. Ye M, Zhang P. Transvenous balloon-assisted Onyx embolization of dural arteriovenous fistulas of hypoglossal canal. *Neuroradiology* 2018;60:971-8.
4. Mendes GA, Kalani MY, Iosif C, Lucena AF, Carvalho R, Saleme S, *et al.* Transvenous curative embolization of cerebral arteriovenous malformations: A prospective cohort study. *Neurosurgery* 2018;83:957-64.
5. Mendes GA, Iosif C, Silveira EP, Waihrich E, Saleme S, Mounayer C. Transvenous embolization in pediatric plexiform arteriovenous malformations. *Neurosurgery* 2016;78:458-65.
6. Tong X, Wu J, Cao Y, Zhao Y, Wang S. New predictive model for microsurgical outcome of intracranial arteriovenous malformations: Study protocol. *BMJ Open* 2017;7:e014063.
7. Levegrün S, Hof H, Essig M, Schlegel W, Debus J. Radiation-induced changes of brain tissue after radiosurgery in patients with arteriovenous malformations: Dose/volume-response relations. *Strahlenther Onkol* 2004;180:758-67.
8. Ding D, Starke RM, Kano H, Mathieu D, Huang P, Kondziolka D, *et al.* Radiosurgery for cerebral arteriovenous malformations in a randomized trial of unruptured brain arteriovenous malformations (ARUBA)-eligible patients: A multicenter study. *Stroke* 2016;47:342-9.
9. Haw CS, terBrugge K, Willinsky R, Tomlinson G. Complications of embolization of arteriovenous malformations of the brain. *J Neurosurg* 2006;104:226-32.
10. Chen CJ, Norat P, Ding D, Mendes GA, Tvrdik P, Park MS, *et al.* Transvenous embolization of brain arteriovenous malformations: A review of techniques, indications, and outcomes. *Neurosurg Focus* 2018;45:E13.
11. Viana DC, de Castro-Afonso LH, Nakiri GS, Monsignore LM, Trivelato FP, Colli BO, *et al.* Extending the indications for transvenous approach embolization for superficial brain arteriovenous malformations. *J Neurointerv Surg* 2017;9:1053-9.
12. Choudhri O, Ivan ME, Lawton MT. Transvenous Approach to intracranial arteriovenous malformations: Challenging the axioms of arteriovenous malformation therapy? *Neurosurgery* 2015;77:644-51.
13. Nguyen TN, Chin LS, Souza R, Norbash AM. Transvenous embolization of a ruptured cerebral arteriovenous malformation with en-passage arterial supply: Initial case report. *J Neurointerv Surg* 2010;2:150-2.
14. Kessler I, Riva R, Ruggiero M, Manisor M, Al-Khawaldeh M, Mounayer C. Successful transvenous embolization of brain arteriovenous malformations using Onyx in five consecutive patients. *Neurosurgery* 2011;69:184-93.
15. Consoli A, Renieri L, Nappini S, Limbucci N, Mangiafico S. Endovascular treatment of deep hemorrhagic brain arteriovenous malformations with transvenous onyx embolization. *AJNR Am J Neuroradiol* 2013;34:1805-11.
16. Pereira VM, Marcos-Gonzalez A, Radovanovic I, Bijlenga P, Narata AP, Moret J, *et al.* Transvenous embolization of a ruptured deep cerebral arteriovenous malformation. A technical note. *Interv Neuroradiol* 2013;19:27-34.
17. Trivelato FP, Manzato LB, Rezende MT, Uihôa AC. Transitory brain stem edema following successfully transvenous embolization of a posterior fossa arteriovenous malformation. *Clin Neuroradiol* 2014;24:151-3.
18. Zhang G, Zhu S, Wu P, Xu S, Shi H. The transvenous pressure cooker technique: A treatment for brain arteriovenous malformations. *Interv Neuroradiol* 2017;23:194-9.
19. Fokas E, Henzel M, Wittig A, Grund S, Engenhart-Cabillic R. Stereotactic radiosurgery of cerebral arteriovenous malformations: Long-term follow-up in 164 patients of a single institution. *J Neurol* 2013;260:2156-62.