

Duodenal Obstruction Due to Missed Pre-duodenal Portal Vein in a Patient with Intestinal Malrotation

Stephen Akau Kache^{1,2}, Danjuma Sale^{1,2}, Victoria Ijeoma Chinwuko², Philip Mari Mshelbwala³

¹Department of Surgery, College of Medicine, Kaduna State University and Barau Dikko Teaching Hospital, ²Department of Surgery, Epsilon Specialist Hospital, Barnawa, Kaduna, ³Department of Surgery, College of Medicine, Kaduna State University and Barau Dikko Teaching Hospital, Kaduna, Nigeria

Abstract

Pre-duodenal portal vein (PDPV) is a rare anomaly and a rare cause of duodenal obstruction (DO), with only a few cases reported in the literature. We present an infant whose bilious vomiting persisted despite having Ladd's procedure for intestinal malrotation due to a missed diagnosis of DO from PDPV that was found at re-exploration. The patient was diagnosed with malrotation and had Ladd's procedure at 12 weeks of age, but bilious vomiting persisted post-operatively. The patient presented to us after 4 weeks, was clinically malnourished and dehydrated, resuscitation was done and re-exploratory laparotomy performed, where an obstructing PDPV was found and a duodeno-duodenostomy was performed anterior to PDPV. However, the patient died on post-operative day 7 probably from severe malnutrition due to delayed diagnosis and absence of parenteral nutrition. We conclude that PDPV may be a cause of DO in infants with malrotation and should be properly sought for during Ladd's procedure for possible bypass surgery if found.

Keywords: Duodenal obstruction, intestinal malrotation, missed diagnosis, pre-duodenal portal vein

INTRODUCTION

Pre-duodenal portal vein (PDPV) is a rare anomaly with only a few cases reported in the literature.^[1-9] It results from the embryonic mal-development of the portal venous system and is characterised by an anteriorly placed portal vein.^[1,2] It is commonly associated with other congenital anomalies including heterotaxia or polysplenia syndrome, situs inversus, cardiac defects, malrotation, biliary or duodenal atresia and annular pancreas.^[1-5,7-9] It is a rare cause of acute duodenal obstruction (DO).^[1,2,4,5,8]

The aim of this report is to present an infant whose bilious vomiting persisted despite having Ladd's procedure for malrotation due to a missed diagnosis of DO from PDPV that was found at re-exploration.

CASE REPORT

A 4-month-old boy, delivered through spontaneous vaginal delivery at term, after an uneventful gestational period, was found to have frequent persistent projectile bilious vomiting from

second day of life, with associated upper abdominal distension and failure to pass meconium. Birth weight was 2.5 kg.

The patient was diagnosed with malrotation at another hospital and had Ladd's procedure at 12 weeks of age, but bilious vomiting persisted postoperatively, resulting in severe dehydration and failure to thrive, before patient presented to us through self-referral, details of the initial presentation and management was obtained by contacting the primary surgeon.

On admission, baby weighed 2.43 kg (37% of expected weight) was tachycardic, hypothermic and had faint peripheral pulses. There was upper abdominal distension, with right transverse supraumbilical surgical scar and no palpable abdominal mass. Apex beat was in the normal position. The packed cell volume was 28%, urea and electrolytes were as follows urea 10.2 mmol/L, Na 125 mmol/L, Cl 88 mmol/L, K 3.0 mmol/L and Hco₃ 20 mmol/L.

Address for correspondence: Dr. Stephen Akau Kache, Department of Surgery, College of Medicine, Kaduna State University and Barau Dikko Teaching Hospital, Kaduna, Nigeria. E-mail: kachesteve@yahoo.com

Received: 01-10-2020 Revised: 05-01-2021 Accepted: 22-03-2021 Available Online: 01-01-2022

Access this article online

Quick Response Code:



Website:
www.afripaedurg.org

DOI:
10.4103/ajps.AJPS_146_20

This is an open access journal, and articles are distributed under the terms of the Creative Commons Attribution-NonCommercial-ShareAlike 4.0 License, which allows others to remix, tweak, and build upon the work non-commercially, as long as appropriate credit is given and the new creations are licensed under the identical terms.

For reprints contact: WKHLRPMedknow_reprints@wolterskluwer.com

How to cite this article: Kache SA, Sale D, Chinwuko VI, Mshelbwala PM. Duodenal obstruction due to missed pre-duodenal portal vein in a patient with intestinal malrotation. Afr J Paediatr Surg 2022;19:109-11.

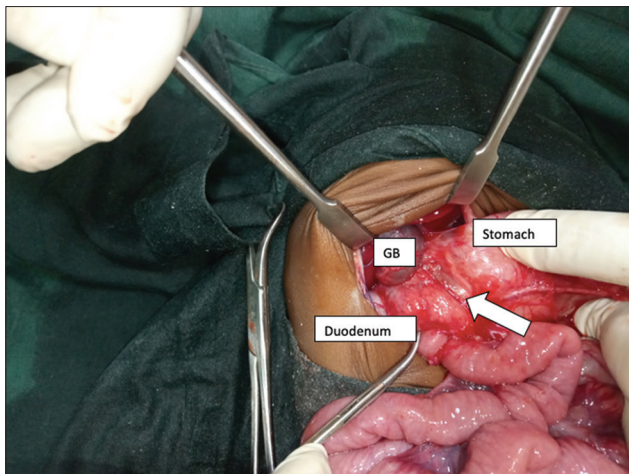


Figure 1: Pre-duodenal portal vein (thick white arrow)

The patient was resuscitated, and re-exploratory laparotomy was performed through the previous incision. The intra-operative findings included, caecum and appendix in the left hypochondrium, moderate adhesions, pre-duodenal portal vein overlying and compressing the 2nd part of the duodenum [Figure 1], dilated stomach and first part of the duodenum, collapsed distal bowel. Gallbladder, liver, pancreas and spleen were found to be normal.

Adhesiolysis was done, and duodeno-duodenostomy was performed anterior to the PDPV. Appendicectomy was not done [Figure 2]. Postoperatively, the patient was stable, well hydrated, making adequate urine, with no features of sepsis.

There was initial significant drainage of bilious fluid through NG tube, which progressively reduced over 3 days.

Bowel sounds returned to normal, patient passed gas and stool by 3rd day post-operative, and oral feeding was commenced on the same day, but the patient was not tolerating more than 60 ml of feeds per day. The patient sadly died by 7th day post-operative probably from severe malnutrition.

DISCUSSION

The index patient had PDPV with associated malrotation which was treated by Ladd's procedure but the symptoms persisted. The association of PDPV with intestinal malrotation has been previously reported, however, in those reports, PDPV was not thought to be the cause of the obstruction.^[1,3-5] Other associated congenital anomalies are heterotaxia or polysplenia syndrome, situs inversus, cardiac defects, biliary or duodenal atresia and annular pancreas. Isolated PDPV has also been reported.^[10]

Symptomatic DO may occur in 50% of patients with PDPV; the obstruction is either due to direct compression of the duodenum or due to coexisting anomalies.^[1,3,4]

Most symptomatic cases of PDPV occur in childhood, whereas most asymptomatic cases are diagnosed incidentally during surgery, typically in adults.^[1]

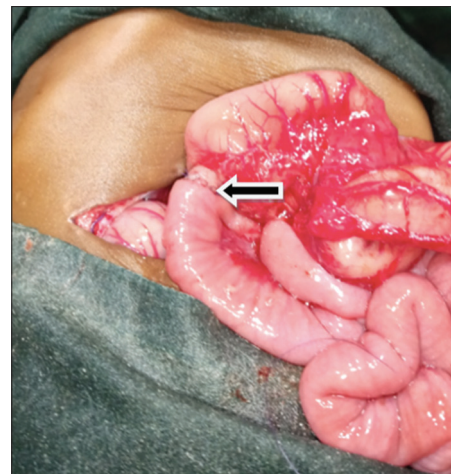


Figure 2: Anastomotic line following duodeno-duodenostomy over the pre-duodenal portal vein (thick black arrow)

The index patient was treated with duodeno-duodenostomy. This is the mode of treatment in most reported series and this bypasses the portal vein anteriorly.^[1,5,6,7] In some other reported series, a gastro-duodenostomy was performed.^[1,9] In these later cases, the vein crosses proximal to the second part of the duodenum making a duodeno-duodenostomy more technically challenging.^[1,9] In a report in an adult patient, PDPV was treated with gastrojejunostomy.^[10]

The DO was relieved by the procedure in our index patient; it is therefore likely that PDPV contributed to the initial presentation of the patient which was missed at the initial surgery. Most series report good outcome with the bypass surgery.^[1,5,6,7]

Our patient sadly died probably from malnutrition due to delayed diagnosis and absence of parenteral nutrition.

We conclude that PDPV may be a cause of DO in infants with malrotation and should be properly sought for during Ladd's procedure for possible bypass surgery if found.

Declaration of patient consent

The authors certify that they have obtained all appropriate patient consent forms. In the form the patient(s) has/have given his/her/their consent for his/her/their images and other clinical information to be reported in the journal. The patients understand that their names and initials will not be published and due efforts will be made to conceal their identity, but anonymity cannot be guaranteed.

Financial support and sponsorship

Nil.

Conflicts of interest

There are no conflicts of interest.

REFERENCES

1. Kim SH, Cho YH, Kim HY. Preduodenal portal vein: A 3-case series demonstrating varied presentations in infants. *J Korean Surg Soc* 2013;85:195-7.
2. Walsh G, Williams MP. Congenital anomalies of the portal venous

- system-CT appearances with embryological considerations. *Clin Radiol* 1995;50:174-6.
3. Srivastava P, Shaikh M, Mirza B, Jaiman R, Arshad M. Preduodenal portal vein associated with duodenal obstruction of other etiology: A case series. *J Neonatal Surg* 2016;5:54.
 4. Kouwenberg M, Kapusta L, van der Staak FH, Severijnen RS. Preduodenal portal vein and malrotation: What causes the obstruction? *Eur J Pediatr Surg* 2008;18:153-5.
 5. Vilakazi M, Ismail F, Swanepoel HM, Muller EW, Lockhat ZI. Duodenal obstruction due to a preduodenal portal vein. *Afr J Paediatr Surg* 2014;11:359-61.
 6. Georgacopulo P, Vigi V. Duodenal obstruction due to a preduodenal portal vein in a newborn. *J Pediatr Surg* 1980;15:339-40.
 7. Choi SO, Park WH. Preduodenal portal vein: A cause of prenatally diagnosed duodenal obstruction. *J Pediatr Surg* 1995;30:1521-2.
 8. Pathak D, Sarin YK. Congenital duodenal obstruction due to a preduodenal portal vein. *Indian J Pediatr* 2006;73:423-5.
 9. Baglaj M, Gerus S. Preduodenal portal vein, malrotation, and high jejunal atresia: A case report. *J Pediatr Surg* 2012;47:e27-30.
 10. John AK, Gur U, Aluwihare A, Cade D. Pre duodenal portal vein as a cause of duodenal obstruction in an adult. *ANZ J Surg* 2004;74:1032-3.