



CASE REPORT

# Inactivated COVID-19 vaccine triggering hemophagocytic lymphohistiocytosis in an immunocompetent adult - A case report

Saad Nasir, Saqib Raza Khan\*, Rodaba Iqbal, Alizah Pervaiz Hashmi, Munira Moosajee, Noreen Nasir

Department of Medical Oncology, Aga Khan University Hospital, Karachi, Pakistan

ARTICLE INFO

Article history:

Received: January 22, 2022

Revised: February 10, 2022

Accepted: March 11, 2022

Published online: March 31, 2022

Keywords:

hemophagocytic lymphohistiocytosis  
COVID-19 Vaccine  
immunohistochemistry

\*Corresponding author:

Saqib Raza Khan

Aga Khan University Hospital, Karachi, Pakistan.

E-mail: [saqib.raza31@yahoo.com](mailto:saqib.raza31@yahoo.com)

© 2022 Nasir, *et al.* This is an Open Access article distributed under the terms of the Creative Commons Attribution-NonCommercial License, permitting all non-commercial use, distribution, and reproduction in any medium, provided the original work is properly cited.

ABSTRACT

**Background and Aim:** Hemophagocytic lymphohistiocytosis (HLH) is a severe hyperinflammatory syndrome that is induced by hyper-activated macrophages, cytotoxic T cells, and reduced natural killer cell activity. A 46-year-old gentleman presented to us with complaints of intermittent fever for the past 2 weeks associated with fatigue along with oral ulcers and skin rashes which resolved spontaneously. These symptoms started after he received the second dose of the BBIP-CorV COVID-19 vaccine. His complete blood picture showed pancytopenia. A detailed infectious disease workup was unrevealing; however, his bone marrow biopsy revealed increased histiocyte activity, with some showing hemophagocytosis and dysplasia. Immunohistochemistry profile demonstrated strong CD 68 positivity. Further investigations showed raised serum ferritin and fasting triglyceride levels. He was immediately started on dexamethasone acetate at a dose of 10 mg/m<sup>2</sup>, after which his clinical symptoms, as well as his blood parameters, improved remarkably. This is the first documented case in Pakistan.

**Conclusion:** The data from clinical trials support the general safety profile of inactivated COVID-19 vaccines. We endorse its mass implementation. However, we believe that robust data need to be generated to evidence any adverse events, especially those with serious outcomes. Physicians should be aware of inactivated COVID-19 vaccine as a possible trigger for HLH and start prompt treatment, resulting in favorable outcomes.

**Relevance for Patients:** The presentation of HLH may vary and can present in an immunocompetent patient with no underlying risk factor. HLH should be kept in differentials when a patient presents with pancytopenia with a recent history of receiving COVID-19 vaccination. Steroids play a major role in the treatment of HLH, and definitive diagnosis and early treatment improve clinical outcomes.

## 1. Introduction

Hemophagocytic lymphohistiocytosis (HLH) is a severe hyperinflammatory syndrome induced by hyper-activated macrophages, cytotoxic T cells, and reduced natural killer (NK) cell activity. The primary form, caused by familial genetic mutations affecting immune regulation, is most commonly found in children. In contrast, the secondary form, the acquired one, is observed mostly in adults. Secondary HLH is multifactorial, triggered by infections or malignancies but may also be induced by autoimmune disorders, in which case it is called macrophage activation syndrome [1]. The list of potential documented etiologies for secondary HLH includes infections (Epstein-Barr virus, herpes simplex virus, cytomegalovirus, and avian influenza), rheumatologic diseases (rheumatoid arthritis, systemic lupus erythematosus, and Kawasaki syndrome), malignancy (NK cell leukemia, peripheral T-cell lymphoma, and B-cell lymphoma), acquired immune deficiency states (after organ transplantation), and drugs [2].

The initial diagnostic guidelines of HLH were further updated in 2004. With a mortality rate of approximately 40%, the HLH patients may present with progressive multi-organ failure resulting in adverse outcomes [3]. Hence, the prognosis of secondary HLH is dismal if not managed early. Liederman *et al.* reported secondary HLH cases associated with adult pneumococcal and influenza vaccinations [4].

In this paper, we report a case of a 46-year-old gentleman who recently received the inactivated (BIPP-CorV) COVID-19 vaccine and then developed fever, pancytopenia, and subsequently diagnosed with secondary HLH.

## 2. Case Report

A 46-year-old gentleman, married, resident of Karachi, Pakistan, presented to the emergency department in our institution in the fall of May 2021 with complaints of intermittent fever for 2 weeks associated with chills and generalized weakness along with reduced appetite, disturbed sleep, fatigue, and weight loss. He also had shortness of breath on exertion. He had no prior medical condition. His medical and family history was also negative for any autoimmune disease. However, the patient connected the onset of symptoms after the second dose of the BBIP-CorV COVID-19 vaccine, which he had received approximately 3 weeks before the beginning of these symptoms. He also reported developing oral ulcers and skin rashes, especially on his hands post-vaccination, which resolved spontaneously. His COVID-19 polymerase chain reaction was negative.

On examination, he was alert and oriented but tachypneic with a respiratory rate of 27 breaths/min; however, he maintained oxygen saturation at 99% on room air. There were occasional left basal crepitations on chest auscultation and the rest of the systemic examination was unremarkable. Relevant blood investigations were initially performed, and his blood picture showed a decrease in all cell lineages, as shown in Table 1. Our Initial differentials included; drug-induced cytopenia, sepsis, any autoimmune condition, or viral infection leading to these clinical symptoms. Peripheral blood films showed persistent pancytopenia and atypical lymphocytes. Detailed autoimmune workup and the infection screen including CMV, Epstein Barr virus (EBV), human immunodeficiency virus (HIV), Hepatitis panel, and Brucella serology were performed, but all investigation results were negative.

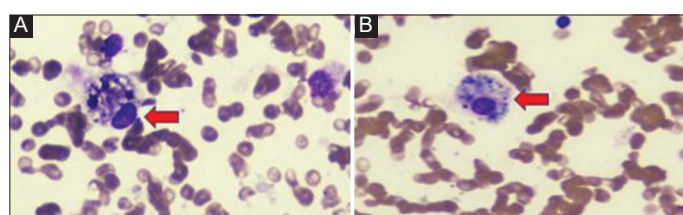
A bone marrow biopsy (BMB) was performed, which showed hypocellularity for age with overall cellularity of approximately 25%. There were megakaryocytes present along with increased histiocyte activity, with some showing hemophagocytosis and dysplasia. The Immunohistochemistry profile demonstrated strong CD 68 positivity with overall findings suggestive of HLH (Figure 1A and B). Hence, this prompted further investigations, including fasting triglyceride levels and serum ferritin, shown in Table 2. A computed tomography scan was also performed, which did not report any significant findings. A unifying diagnosis of HLH was made as our patient met the 2004 HLH-diagnostic criteria (Table 2). We also discussed this case at our multidisciplinary board meeting, where it concurred that the patient had acquired HLH post-COVID-19 vaccination.

## 3. Treatment and Follow-up

The patient was immediately commenced on dexamethasone acetate at a dose of 10 mg/m<sup>2</sup>. His blood parameters (Figure 2) and his clinical condition continued to improve over time, and he started feeling better few weeks after the treatment was initiated; hence, no cytotoxic chemotherapy was prescribed. He continued dexamethasone 10 mg/m<sup>2</sup> for 2 weeks followed by 5 mg/m<sup>2</sup> for 2 weeks, 2.5 mg/m<sup>2</sup> for the next 2 weeks, 1.5 mg/m<sup>2</sup> for further 1 week, and then taper and discontinue during 8<sup>th</sup> week and now on close follow-ups.

## 4. Discussion

HLH is a life-threatening, hyper-inflammatory hematological disorder characterized by excessive stimulation of lymphocytes and macrophages, causing release of a large amount of pro-inflammatory cytokines [5]. Unrecognized and untreated, this



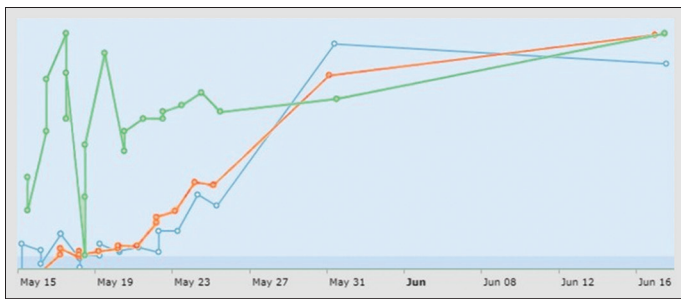
**Figure 1.** (A and B) Bone marrow smear showing hemophagocytosis histiocyte (arrow) with engulfed red blood cells and platelets (hemophagocytosis).

**Table 1.** Complete blood picture details

CBC Parameter	14/5/21	15/5/21	16/5/21	17/5/21	18/5/21	19/5/21	20/5/21	21/5/21	22/5/21	23/5/21	24/5/21	25/5/21
Hb (g/dl)	7.5	7.4	8.9	8.3	7.1	9.3	7.8	8.3	8.3	8.5	8.7	8.4
HCT (%)	22.1	20.8	25.2	23.5	19.8	26.9	22.3	23.3	23.5	24.5	24.5	23.8
WBC (×10 <sup>9</sup> /l)	0.5	<0.5	<0.5	0.6	0.7	0.7	0.8	0.9	1.7	2.1	3.1	3
PMN (%)	6	11.1	7.3	6.6	12.3	15.4	29.4	54.1	52.6	60.9	56.8	54.4
Lymphocytes (%)	NA	74.1	80.5	78.7	76.9	76.9	61.3	35.6	43.9	33.3	33.1	31.8
NLR	NA	0.1	0.1	0.1	0.2	0.2	0.5	1.5	1.2	1.8	1.7	1.7
Monocytes (%)	NA	11.1	12.2	13.1	10.8	7.7	9.3	10.3	3.5	5.8	10.1	13.5
MCHC (g/dl)	NA	35.6	36.5	35.3	35.9	34.6	35	35.6	35.3	34.7	35.5	35.3
Platelets (×10 <sup>9</sup> /l)	6	<4	5	23	3	10	12	15	12	25	47	40

**Table 2.** Patient investigation results and 2004 HLH diagnostic criteria

HLH-2004 criteria: [4]	Patient's values
1. Fever: $\geq 38.5^{\circ}\text{C}$	$39^{\circ}\text{C}$
2. Splenomegaly	No
3. Cytopenia affecting $\geq 2$ lineages:	Yes, all three lineages (as above)
4. Hypertriglyceridemia: fasting triglycerides $> 265$ mg/dl OR hypofibrinogenemia: $\leq 150$ mg/dl	Fasting TG: 274 mg/dl
5. Hemophagocytosis in bone marrow, spleen, or lymph nodes	Bone marrow biopsy showed increased histiocyte activity with hemophagocytosis
6. Hyperferritinemia: $> 500$ $\mu\text{g/l}$ ( $= 500$ ng/ml)	7068.1 ng/ml
7. Low or absent NK-cell activity	Test not performed
8. Elevated soluble IL-2R/CD25: $\geq 2,400$ U/ml	Test not performed

**Figure 2.** Improvement in blood parameters. Green: Hemoglobin, Blue: Platelets, Orange: White blood cells.

rapid cellular activation culminates in progressive multi-organ failure and mortality. HLH is classified into two categories; primary (familial) and secondary (acquired) [6]. Primary HLH entails cytotoxic lymphocyte dysfunction arising from a genetic mutation [7]. The acquired form of HLH occurs from an underlying predisposing factor such as systemic infections, malignancy, immune-mediated inflammatory diseases, or immunodeficiencies, in which a trigger is usually identified, leading to immune dysregulation [8]. The clinical presentation of this rare disorder varies significantly and presents a diagnostic dilemma [1]. In 2004, the histiocyte society published clinical guidelines defining a spectrum of clinical, laboratory, and molecular mechanisms to establish a diagnostic criterion for primary and secondary HLH [9].

Most patients with secondary HLH present with fever, hepatosplenomegaly, and cytopenias, while the most common laboratory findings include deranged liver enzymes, hyperferritinemia, hypertriglyceridemia, and coagulopathy [4]. In secondary HLH, an identifiable underlying cause, for example, acute viral infection, can help in prompt diagnosis and adequate management. The most common cause of acquired HLH includes viruses, of which the EBV is the most common agent; others include the cytomegalovirus, the human-herpes-8 virus, and the HIV [8]. Malignancies and autoimmune diseases account for the remaining causes of acquired (reactive) HLH [8]. More recently, the severe acute respiratory syndrome coronavirus 2 (SARS-CoV-2),

causing the coronavirus infectious disease (COVID-19), has also been reported to lead to secondary HLH [10-13]. The underlying mechanism of secondary HLH from SARS-CoV-2 results from a cytokine-storm generated through various pathways [10,14].

Interestingly, vaccines have also been implicated in activating HLH through their immune mediating mechanisms. Ikebe *et al.* reported one such case, where a patient with aplastic anemia developed secondary HLH after receiving the influenza vaccine [11]. Other vaccines with such evidence include tetanus, pneumococcal, diphtheria-pertussis-tetanus, mumps-rubella, and measles vaccine [9,10]. It is important to note that the majority of these are inactivated vaccines possibly suggesting the existence of an underlying mechanism leading to an exaggerated immune response.

Since the start of the COVID-19 pandemic, the pharmaceuticals and the scientific community all joined the race to manufacture potent vaccines to curb this global disease. One such vaccine, the BBIP-CorV COVID-19, manufactured by Sinopharm's Beijing Institute of Biological Products, has been distributed in various parts of Asia. The rapid release of different vaccines against SARS-CoV-2 has resulted in limited data on the safety profile, which remains an area of interest and further exploration.

A case report from China described a male patient diagnosed with HLH secondary to inactivated COVID-19 vaccine [15]. The patient described in this report was previously vaccinated with the BBIP-CorV vaccine and then went on to develop sudden onset of fever and pancytopenia. Interestingly, he also had evidence of EBV infection, a common cause of acquired HLH, unlike our patient's case. Attwell *et al.* recently reported three cases of COVID Vaccine induced secondary HLH in patients with previously known clinical co-morbid conditions [16]. Hence, in our case, given the recent history of COVID-19 vaccination, associated with the clinical and histopathological profile of HLH, and having met five out of the eight components of the 2004 HLH trial criteria, we diagnosed our patient with acquired HLH secondary to the BBIP-CorV vaccine. To the best of our knowledge, this is the first ever case report related to HLH following the receipt of inactivated COVID-19 vaccine (BBIP-CorV) in an immunocompetent individual in our population. Our search showed one similar case of a vaccine induced HLH from the United Kingdom [17]. However, it was a recombinant vaccine (ChAdOx1 nCoV-19), unlike in our case.

A clinical trial from China, including 192 participants vaccinated with the BBIP-CorV vaccine, shows that most participants experienced fever as the most common systemic adverse effect. In contrast, most of the participants tolerated it well [18]. Glucocorticoids are the mainstay of clinical management in these patients, while cyclosporine and intravenous immunoglobulin have also improved overall survival [19]. We started our patient on dexamethasone therapy, which led to a switch-off effect on systemic inflammation and prompt clinical and laboratory profile resolution. Our experience further supports the evidence for the therapeutic role of glucocorticoids in these patients.

This report aims to highlight the association of an inactivated COVID-19 vaccine (BBIP-CorV) as a stimulus for secondary

HLH. Since HLH is a diagnosis often made with a high index of suspicion, we recommend that physicians be aware of this adverse condition, as prompt diagnosis and early initiation of effective treatment for HLH are associated with improved patient outcomes.

## 5. Conclusion

The data from clinical trials support the general safety profile of inactivated COVID-19 vaccines. We endorse its mass implementation, as the benefits far outweigh individual risk, which seems minimal. However, we hope that robust data are required to evidence any adverse events, especially those with serious outcomes. Physicians should be aware of inactivated COVID-19 vaccine as a potential cause for HLH in the presence of suggestive clinical and laboratory criteria and start prompt treatment for improved outcome and survival.

## Conflict of Interest

The authors declare that they have no competing interests.

## Acknowledgments

I would like to acknowledge and thank Mr. Salman Muhammad Soomar Research Specialist Oncology and Team of Department of Hematology and Oncology, Aga Khan University Hospital for providing data and relevant details for the case report.

## References

- [1] La Rosée P, Horne A, Hines M, von Bahr Greenwood T, Machowicz R, Berliner N, *et al.* Recommendations for the Management of Hemophagocytic Lymphohistiocytosis in Adults. *Blood J Am Soc Hematol* 2019;133:2465-77.
- [2] Majumder A, Sen D. An Autopsy Series of an Oft-missed Ante-mortem Diagnosis: Hemophagocytic Lymphohistiocytosis. *Autops Case Rep* 2021;11:e2021243.
- [3] Grzybowski B, Vishwanath VA. Hemophagocytic Lymphohistiocytosis: A Diagnostic Conundrum. *J Pediatr Neurosci* 2017;12:55.
- [4] Liederman Z. Hemophagocytic Lymphohistiocytosis Associated with Adult Vaccination: A Case of Cytokine Flurries. *Can J Gen Intern Med* 2015;10:32.
- [5] Madkaikar M, Shabrish S, Desai M. Current Updates on Classification, Diagnosis and Treatment of Hemophagocytic Lymphohistiocytosis (HLH). *Indian J Pediatr* 2016;83:434-43.
- [6] Campo M, Berliner N. Hemophagocytic Lymphohistiocytosis in Adults. *Hematology Oncol Clin North Am* 2015;29:915-25.
- [7] Allen CE, McClain KL. Pathophysiology and Epidemiology of Hemophagocytic Lymphohistiocytosis. *Hematology Am Soc Hematol Educ Program* 2015;2015:177-82.
- [8] Bode SF, Lehmborg K, Maul-Pavicic A, Vraetz T, Janka G, Stadt UZ, *et al.* Recent Advances in the Diagnosis and Treatment of Hemophagocytic Lymphohistiocytosis. *Arthritis Res Ther* 2012;14:213.
- [9] Henter J. Diagnostic Guidelines for Hemophagocytic Lymphohistiocytosis. The FHL Study Group of the Histiocyte Society. *Semin Oncol* 1991;18:29-33.
- [10] Tholin B, Hauge MT, Aukrust P, Fehrle L, Tvedt TH. Hemophagocytic Lymphohistiocytosis in a Patient with COVID-19 Treated with Tocilizumab: A Case Report. *J Med Case Rep* 2020;14:187.
- [11] Ikebe T, Takata H, Sasaki H, Miyazaki Y, Ohtsuka E, Saburi Y, *et al.* Hemophagocytic Lymphohistiocytosis Following Influenza Vaccination in a Patient with Aplastic Anemia Undergoing Allogeneic Bone Marrow Stem Cell Transplantation. *Int J Hematol* 2017;105:389-91.
- [12] Wiseman D, Lin J, Routy JP, Samoukovic G. Haemophagocytic Lymphohistiocytosis in an Adult with Postacute COVID-19 Syndrome. *BMJ Case Rep* 2021;14:e245031.
- [13] Dandu H, Yadav G, Malhotra HS, Pandey S, Sachu R, Dubey K. Hemophagocytic Histiocytosis in Severe SARS-CoV-2 Infection: A Bone Marrow Study. *Int J Lab Hematol* 2021;43:1291-301.
- [14] Soy M, Atagündüz P, Atagündüz I, Sucak GT. Hemophagocytic Lymphohistiocytosis: A Review Inspired by the COVID-19 Pandemic. *Rheumatol Int* 2021;41:7-18.
- [15] Tang LV, Hu Y. Hemophagocytic Lymphohistiocytosis after COVID-19 Vaccination. *J Hematol Oncol* 2021;14:1-5.
- [16] Atwell L, Zaw T, McCormick J, Marks J, McCarthy H. Haemophagocytic Lymphohistiocytosis after ChAdOx1 nCoV-19 Vaccination. *J Clin Pathol* 2022;75:282-4.
- [17] Cory P, Lawrence H, Abdulrahim H, Mahmood-Rao H, Hussein A, Gane J. Lessons of the Month 3: Haemophagocytic Lymphohistiocytosis Following COVID-19 Vaccination (ChAdOx1 nCoV-19). *Clin Med (London, England)* 2021;21:e677-9.
- [18] Xia S, Zhang Y, Wang Y, Wang H, Yang Y, Gao GF, *et al.* Safety and Immunogenicity of an Inactivated SARS-CoV-2 Vaccine, BBIBP-CorV: A Randomised, Double-blind, Placebo-controlled, Phase 1/2 Trial. *Lancet Infect Dis* 2021;21:39-51.
- [19] Manuel RC, Pilar BZ, Armando LG, Munther AK, Xavier B. Adult Haemophagocytic Syndrome. *Lancet* 2014;383:1503-16.

## Publisher's note

Whioce Publishing remains neutral with regard to jurisdictional claims in published maps and institutional affiliations.