

Submacular hemorrhage secondary to age-related macular degeneration managed with vitrectomy, subretinal injection of tissue plasminogen activator, hemorrhage displacement with liquid perfluorocarbon, gas tamponade, and face-down positioning



Abdullah Ozkaya*; Gurkan Erdogan; Hatice Nur Tarakcioglu

Abstract

Purpose: To investigate the outcomes of vitrectomy, subretinal tissue plasminogen activator (tPA) injection, hemorrhage displacement with liquid perfluorocarbon, gas tamponade, and face-down positioning, in hemorrhagic neovascular age-related macular degeneration (AMD) patients.

Methods: In this retrospective case series, we reviewed the records of patients who were diagnosed as having submacular hemorrhage (SMH) secondary to neovascular AMD between January and June 2016. The main outcome measure was the difference between preoperative and postoperative best corrected visual acuity (BCVA).

Results: In 9 eyes of 9 patients, mean preoperative and postoperative BCVA at the last follow-up were 1.65 and 1.49 LogMAR, respectively ($p = 0.1$), after a mean follow up time of 12.4 ± 1.0 months. The SMH was successfully displaced in 5 of the 9 patients (55.5%). Four out of 9 patients (44.4%) gained ≥ 3 lines. The duration of SMH was 3.6 ± 2.1 days (range 1–7) in the successfully displacement group, and was 10.0 ± 1.8 days (range 8–12) in the group in which was SMH could not be displaced ($p = 0.002$). The mean SMH area was smaller in the successfully displacement group than the group in which was SMH could not be displaced ($p = 0.04$).

Conclusion: Vitrectomy, subretinal tPA injection, hemorrhage displacement with liquid perfluorocarbon, gas tamponade and face-down positioning was associated with improved visual outcomes in patients with hemorrhagic neovascular AMD. The duration and area of the SMH seemed to be related to the success of displacement.

Keywords: Age related macular degeneration, Tissue plasminogen activator, Vitrectomy

© 2018 The Authors. Production and hosting by Elsevier B.V. on behalf of Saudi Ophthalmological Society, King Saud University. This is an open access article under the CC BY-NC-ND license (<http://creativecommons.org/licenses/by-nc-nd/4.0/>). <https://doi.org/10.1016/j.sjopt.2018.08.002>

Introduction

Submacular hemorrhage (SMH) secondary to neovascular age-related macular degeneration has a very poor visual prognosis without treatment.^{1–4} Several mechanisms seem to play a role on the damage caused by SMH to the pho-

toceptors.^{2–4} The toxicity of fibrin, iron and hemosiderin released from the hemorrhage and the mechanical barrier formed by the hemorrhage deteriorate the normal metabolism of the retina. The incidence of SMH among patients with neovascular AMD (nAMD) is unknown.⁵ In patients diagnosed with nAMD limited to one eye, neovascular

Received 27 April 2018; received in revised form 29 July 2018; accepted 13 August 2018; available online 15 August 2018.

Beyoglu Eye Training and Research Hospital, Istanbul, Turkey

* Corresponding author at: Beyoglu Eye Training and Research Hospital, Bereketzade Cami Sok., 34421 Beyoglu, Istanbul, Turkey. e-mail address: abdozkaya@gmail.com (A. Ozkaya).

* This retrospective study was not supported by any company. None of the authors has financial or proprietary interests in any material or method mentioned. This data has not been previously published.



Peer review under responsibility of Saudi Ophthalmological Society, King Saud University



Production and hosting by Elsevier

Access this article online: www.saudiophthaljournal.com www.sciencedirect.com

lesions associated by any amount of hemorrhage were found to develop in the other eye in 19% during 4 years of follow up.⁶ As visual outcomes of SMH are usually devastating, several treatment options have been evaluated for its treatment including intravitreal injection of gases and tissue plasminogen activator (tPA), vitrectomy with or without intravitreal/subretinal tPA injection and pneumatic displacement of the hemorrhage.^{4–15} A consensus on the best approach to therapy has not yet emerged.⁸ Usually small hemorrhages are managed with intravitreal anti-vascular endothelial growth factor (Anti-VEGF) and gas/tPA injections, larger and thicker hemorrhages are managed with vitrectomy, intravitreal/subretinal tPA injection and pneumatic displacement, and massive hemorrhages require subretinal surgery.^{4–15} In a multicenter randomized study,⁴ patients who underwent surgery with or without tPA for hemorrhagic nAMD did not have better visual outcomes than patients who did not undergo surgery. In our clinic vitrectomy, subretinal tPA injection, and pneumatic displacement were the main treatment modalities used for SMHs secondary to nAMD until January 2016. However, this technique had some drawbacks such as the inability to predict whether the hemorrhage would be displaced from the fovea. We thus switched our technique to vitrectomy, subretinal tPA injection, hemorrhage displacement with liquid perfluorocarbon and gas tamponade for the treatment of SMH secondary to nAMD and in this study, we aimed to evaluate the outcomes of this technique.

Materials and methods

In this retrospective, interventional case series, we reviewed the records of the patients who were diagnosed as having SMH secondary to nAMD and underwent vitrectomy, subretinal tPA injection, hemorrhage displacement with liquid perfluorocarbon and gas tamponade between January and June 2016. The disease and surgery was explained to the patients in detail, a written informed consent was obtained from all patients before the treatment, and the study adhered to the tenets of the Declaration of Helsinki.

The patients who had suffered from a SMH involving the fovea secondary to nAMD in the last 15 days were included. Patients were not included if they had a history of sudden visual decrease lasting >15 days or harbored SMH secondary to other diseases.

Data collected from the patients' records included age, gender, lens status, use of blood thinners (aspirin, warfarin etc.), duration of SMH, thickness of the SMH at the subfoveal area, area of SMH, pre-operative best corrected visual acuity (BCVA) and BCVA at month 1, 3, 6, 9, 12, surgical complications, post-operative treatments, and duration of follow up.

All patients underwent a standardized examination including the measurement of visual acuity (VA), slit-lamp biomicroscopy, measurement of intraocular pressure via applanation tonometry, biomicroscopic fundus examination, optical coherence tomography (OCT) (Spectralis; Heidelberg Engineering, Heidelberg, Germany), fundus photography, and fluorescein angiography (HRA-2; Heidelberg Engineering, Heidelberg, Germany) when needed. The thickness and area of SMH were measured via the built in software of the devices.

Surgical technique

Surgical procedures were all performed by two surgeons (A.O. and G.E.). In each patient the procedures were as follows. A standard 3-port 23 gauge vitrectomy was performed (Alcon Constellation vitrectomy system, Alcon Laboratories, Fort Worth, TX, USA). First, core vitrectomy was performed and if posterior vitreous detachment was not present it was induced and then posterior vitrectomy was completed. A 41-gauge flexible translocation microcannula was inserted into the subretinal space through the highest part of the hemorrhage, and tPA (Actilyse, Boehringer Ingelheim, Germany) at a concentration of 25 micrograms/ml and a total volume of 0.1–0.2 ml was injected via a silicone oil injection system (Fig. 1a). After a waiting period of 15–30 minutes, a small bubble of perfluorodecaline which formed a circle smaller than the area of SMH was injected over the optic disc (Fig. 1b). Then we tried to displace the SMH away from the fovea with a seesaw maneuver by moving the perfluorodecaline bubble (Fig. 1c). If the clot was found to be dissolved, the hemorrhage was easily displaced in 3–5 minutes of maneuvering (Fig. 1d). However, if the clot did not dissolve and the SMH was not displaced in 3–5 minutes of maneuvering (Fig. 2) then the maneuver was ended and the patient was left for pneumatic displacement at the post-operative period. Fluid-air exchange was then performed, with the air finally being replaced by 20% sulfur hexafluoride that totally filled the vitreous cavity. After surgery, all of patients were asked to maintain a face-down position for 5 days. Intravitreal anti-VEGF injection was not given at the end of the operation because of the potential toxic effects of the drugs under the fully gas filled eye, therefore all patients received intravitreal anti-VEGF injection if they showed activity signs via OCT (subretinal fluid, intraretinal cysts) at the postoperative month 1 visit.

The patients were then called for follow-up visits at post-operative day 1, week 1, and month 1, 3, 6, 9, 12. Patients who presented with active choroidal neovascularization were treated with intravitreal anti-VEGF drugs during the follow-up period and called for more frequent visits if required.

The main outcome measure of the study was the difference between pre-operative and post-operative BCVA at the last follow-up visit. Secondary outcome measures were the rate of the patients who showed an increase of $3 \geq$ lines of BCVA at month 12, the relationship between the thickness and area of SMH and the success of displacement with liquid perfluorocarbon, and surgical complications.

Statistical analysis

Statistical analyses were performed via SPSS statistical software (version 20, SPSS, Chicago, IL). Because of the small number of patients, non-parametric tests were used. The Wilcoxon test was used to compare the differences between two dependent variables. The Mann-Whitney U test was used to compare the differences between two independent variables. Statistical significance was defined as $p < 0.05$.

Results

The inclusion criteria were met by 9 eyes of 9 patients. Prior to surgery, 7 of the 9 (77.7%) patients had received

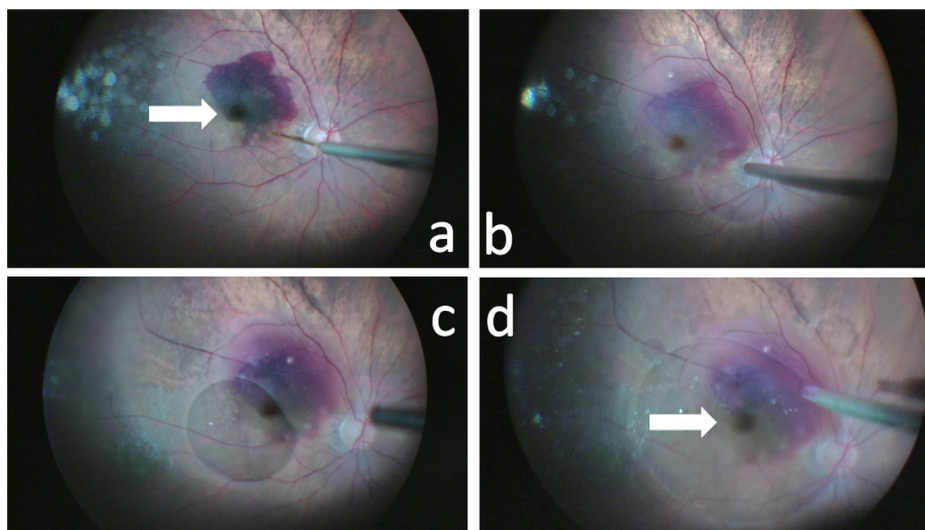


Fig. 1. (a) Injection of subretinal tissue plasminogen activator (white arrow shows that fovea and inferior part of the macula was affected from the subretinal hemorrhage), (b) liquid perfluorocarbon is injected, (c) pushing the submacular hemorrhage inferiorly with the liquid perfluorocarbon, (d) clearing the fovea from the hemorrhage totally with increased amount of liquid perfluorocarbon (white arrow shows that the hemorrhage was totally displaced from the fovea).

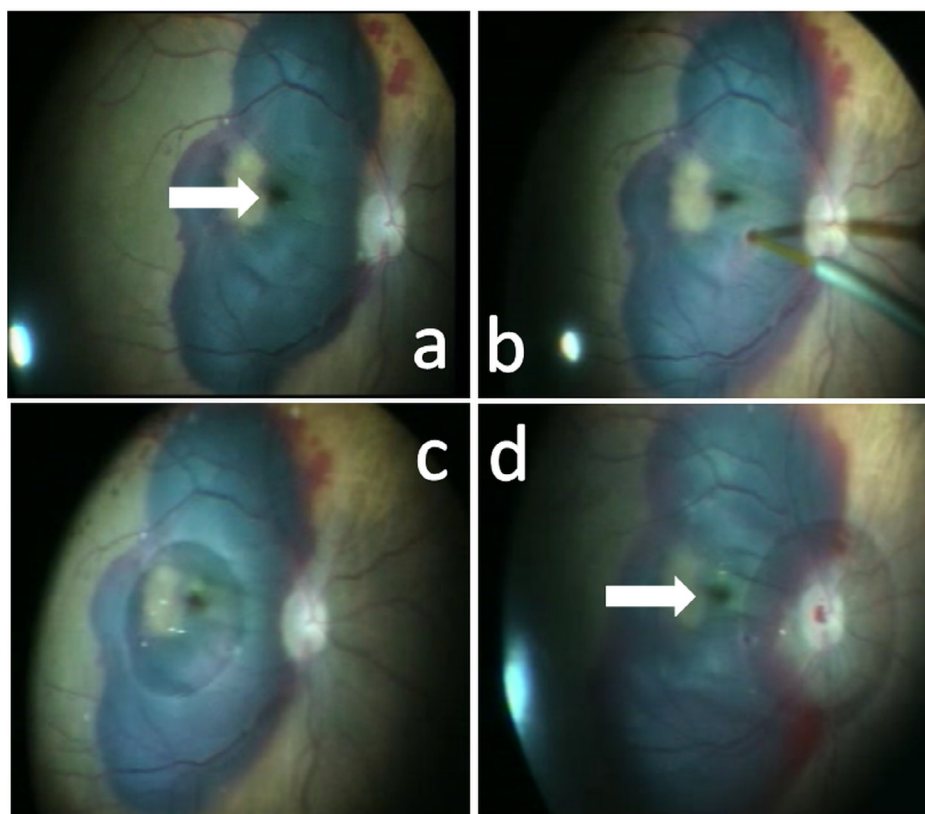


Fig. 2. (a) A large submacular hemorrhage affecting the whole posterior pole, sparing only a small portion of temporal fovea (white arrow shows that fovea was affected from the subretinal hemorrhage), (b) injection of subretinal tissue plasminogen activator, (c) pushing the submacular hemorrhage nasally towards the optic disc with the liquid perfluorocarbon, (d) pushing the submacular hemorrhage temporally from the optic disc with the liquid perfluorocarbon (white arrow shows that the hemorrhage was not displaced from the fovea).

anti-VEGF therapy for nAMD. Blood thinners were being received by 4 patients (44.4%). The general patient characteristics and clinical findings were summarized in [Table 1](#). The overall mean age was 74.7 ± 12.4 years (range 66–84 years). Mean follow up time after surgery was

12.4 ± 1.0 months (range 12–15 months). The mean duration of SMH was 6.4 ± 3.8 days (range 1–12). The mean SMH thickness at the fovea was 844 ± 356 micrometers (range 468–1588). The mean SMH area was 36.3 ± 27.6 mm² (range 2.7–78.8). The mean preoperative and mean BCVA at the last

Table 1. Patients with submacular hemorrhage secondary to neovascular age-related macular degeneration who were treated with pars plana vitrectomy, subretinal injection of tissue plasminogen activator, displacement with liquid perfluorocarbon, gas tamponade, and face-down positioning.

Patient number	Age/sex	Follow-up (months)	SMH displacement	Baseline BCVA	Final BCVA	Complications	Additional treatment	SMH Area (mm ²)	SMH thickness (µm)	Antiplatelet therapy
1	82/M	12	Yes	1.70	1.70	Re-SMH at month 1	2 IVR	17.70	658	No
2	75/M	12	Yes	1.30	1.00	–	1 IVR	51.24	1588	Yes
3	72/M	12	Yes	1.70	1.70	–	3 IVAfl	20.72	893	No
4	84/F	13	Yes	1.70	1.70	–	–	2.78	608	Yes
5	66/F	12	Yes	1.40	1.30	Re-SMH at month 11	4 IVR. vitrectomy	11.54	480	No
6	77/M	12	No	1.70	1.70	–	–	54.15	844	No
7	72/M	12	No	2.00	2.00	–	–	70.70	1140	Yes
8	71/F	12	No	1.70	1.30	–	3 IVAfl	19.71	468	Yes
9	74/F	15	No	1.70	1.40	–	1 IVR	78.84	923	No

F: Female, M: Male, BCVA: Best corrected visual acuity, SMH: Submacular hemorrhage, IVR: Intravitreal ranibizumab, IVAfl: Intravitreal aflibercept, µm: micrometer.

follow up visit were 1.65 ± 0.20 (1.3–2.0) and 1.49 ± 0.34 (1.0–2.0) LogMAR, respectively ($p = 0.1$). Mean BCVA improved 1.6 lines, 4/9 patients (44.4%) gained 3 or more lines, 8 of the 9 patients remained stable (gained < 3 lines, or no change, or lost < 3 lines) (Fig. 3). Six of the 9 (66%) patients required intravitreal anti-VEGF therapy during the follow-up period.

The SMH was successfully displaced away from the fovea in 5 of the 9 patients (55.5%). The duration of SMH was 3.6 ± 2.1 days (range 1–7) in the successfully displacement group, and was 10.0 ± 1.8 days (range 8–12) in the group in which was SMH could not be displaced ($p = 0.002$). The general characteristics and treatment outcomes of the two groups were summarized in Table 2. The mean SMH thickness at the fovea was not statistically different between the two groups ($p = 0.9$). The mean SMH area was smaller in the successfully displacement group than the group in which was SMH could not be displaced ($p = 0.04$). The change in mean BCVA from baseline to the last follow-up visit was not statistically different between the two groups ($p = 0.4$).

There were no complications peroperatively in any of the patients. Post-operatively re-hemorrhage occurred in 2 of the patients. One showed recurrent SMH at post-operative

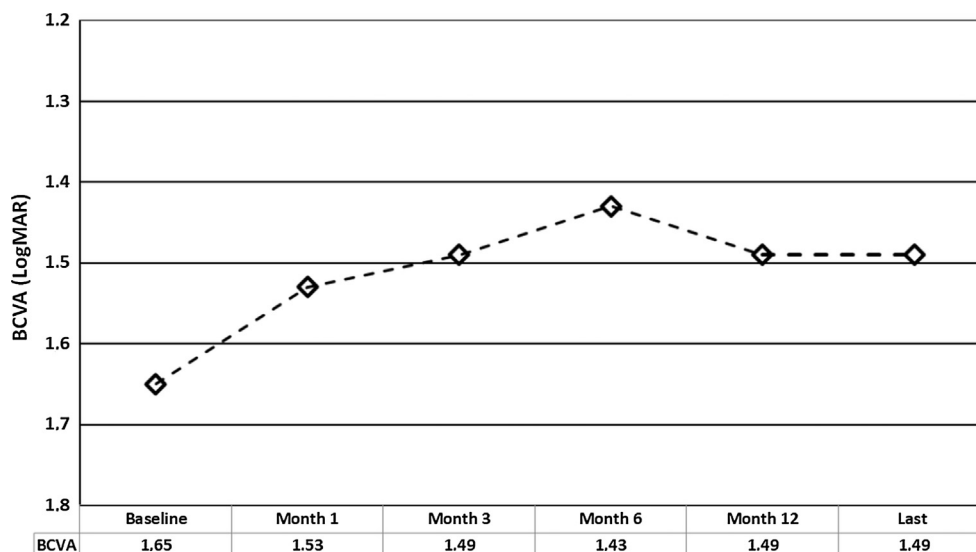
Table 2. General characteristics of the two groups in which submacular hemorrhage was displaced or not.

	Displacement (+)	Displacement (–)	p value
Number of eyes	5	4	–
Age (years)	75.8 ± 7.6	73.5 ± 2.6	0.5
SMH duration (days)	3.6 ± 2.1	10.0 ± 1.8	0.002*
SMH thickness (micrometers)	845 ± 441	843 ± 280	0.9
SMH area (mm ²)	20.7 ± 18.3	55.8 ± 26.1	0.04*
Baseline BCVA (LogMAR)	1.55 ± 0.19	1.77 ± 0.15	0.1
Last BCVA (LogMAR)	1.47 ± 0.31	1.52 ± 0.42	0.8
Change in BCVA (LogMAR lines)	0.8	2.5	0.4

Displacement (+): the group of the patients in whom the submacular hemorrhage could be displaced peroperatively, Displacement (–): the group of the patients in whom the submacular hemorrhage could not be displaced peroperatively, SMH: submacular hemorrhage, BCVA: best corrected visual acuity, LogMAR: logarithm of the minimum angle of resolution.

* p value less than 0.05 was considered statistically significant.

month 1 and the other at post-operative month 11. The first patients showed a small hemorrhage which was decided to manage with only anti-VEGF injection. The other patient underwent re-operation.

**Fig. 3.** The change in best corrected visual acuity in different time points.

Discussion

In this study we evaluated the treatment outcomes of the surgical technique of vitrectomy, subretinal tPA injection and hemorrhage displacement with liquid perfluorocarbon in patients with SMH secondary to nAMD. Also we evaluated the factors affecting surgical displacement of the SMH. We were able to displace the SMH with the described technique in 5 of the 9 patients. The duration and area of the SMH seemed to be related to the success of displacement. The SMH could be displaced successfully in patients with a shorter duration of disease onset and in those having smaller areas affected. However, displacement of SMH did not affect the visual outcomes and despite anatomical success with immediate per-operative surgical displacement the visual results were similar between the two groups and indeed poor when the whole group was considered. This might be due to poor visual acuity at presentation and preexisting underlying retinal dysfunction secondary to nAMD. Also, the potential harmful effect of the surgical technique which might have increased the photoreceptor damage mechanically cannot be excluded and might account for the poor visual outcomes.

To date, various surgical techniques and pneumatic methods have been investigated for manipulating the SMH and displacing it.^{4–15} Techniques consisting of vitrectomy and direct subretinal removal of the SMH have been found ineffective. With the increasing use of tPA, pneumatic displacement techniques have become preferred methods.^{8–15} Vitrectomy-based methods have been preserved for large SMHs, whereas intravitreal-injection based methods were used for limited SMHs.^{10–15} Recently in a randomized clinical trial,⁴ surgical treatment has been compared to observation.^{8–13} Also, treatment methods that incorporated tPA have been investigated in comparative studies.^{8–13} Although the studies regarding the surgical treatment of SMH secondary to nAMD methods have been case series in which the patients were all treated with a given method, the treatment outcomes could be evaluated at least in terms of whether they were better than the natural untreated course of the disease. In a retrospective study by Avery et al the natural history of hemorrhagic nAMD was evaluated.¹ The lesions were composed of more than 50% hemorrhage, and were studied in 41 eyes of 40 patients. After a follow-up period of 3 years, 44% of eyes lost ≥ 6 lines of visual acuity. In another study, patients with hemorrhagic nAMD were randomly assigned to undergo observation or surgical treatment.⁴ After a follow-up period of 24 months, ≥ 6 lines of visual acuity was lost in 36% of the untreated eyes whereas this was seen in only 20% of the surgically treated eyes. The difference was reported to be significant and the authors concluded that surgery seemed to prevent severe visual loss.

Several studies evaluating the efficacy of vitrectomy, subretinal tPA injection, gas tamponade and face positioning appeared to provide better visual outcomes than the untreated course of the disease.^{8–17} In these pneumatic methods, the patients have generally been instructed to maintain a face-down or upright position for a specified length of time postoperatively.^{9–12,7,17} The suitability of face-down positioning has been questioned on different studies and an alternative position in which the eyes are directed 40° below the horizontal has been reported to be capable of displacing SMH when used in combination with

perfluorocarbon gas.^{7,17–19} Recently another surgical technique was described in the treatment of subretinal and subretinal pigment epithelial hemorrhages.²⁰ The authors used a two-step vitrectomy technique to displace the SMH away from the fovea. In the first surgery tPA was injected subretinally into the hemorrhage site, then at the end of the surgery the vitreous cavity was filled with 4–5 cc of liquid perfluorocarbon which was left there for 7–17 days. The liquid perfluorocarbon that displaced mechanically the SMH was removed with a second operation. This new described technique is quiet similar to the pneumatic techniques in use. In the pneumatic techniques tPA is injected intravitreally or subretinally with gases, with the aim of dissolving the SMH. Then the gas will displace it while the patient is in face-down or sitting position. In the two-step surgery technique liquid perfluorocarbon is used and the patients have to maintain face-up position in contrast to the face-down position in the pneumatic techniques. On the other hand both techniques have a drawback; the displacement of SMH from the fovea is expected to occur due to the applied pressure by the gas or liquid perfluorocarbon but cannot be detected preoperatively. However, the main advantage of our technique is that, it allow us to see the displacement, if any, of the SMH preoperatively. By other means we try to displace the hemorrhage immediately with an indirect method, without aspirating or removing it with a cannula. If it is not possible to displace it, the pneumatic method will be used as we use gas tamponade for all of the patients irrespective of the successful displacement of the SMH. This is especially important in the early post-operative period during which we need the intravitreal gas and face-down positioning to keep SMH away from the fovea even in patients in whom we successfully displaced the SMH. On the other hand we also need gas tamponade and positioning for the pneumatic displacement in patients in whom this is not achieved.

The visual outcomes of our study was acceptable, as we achieved ≥ 3 lines of visual increase in 44.4% of the patients. Also the mean increase in vision was 1.6 lines. In another study from our clinic, vitrectomy combined with subretinal tPA injection, partially gas tamponade, and sitting position was evaluated in the patients with SMH secondary to nAMD.⁷ Ten eyes of ten patients were included in the study with a mean follow-up time of 38.7 months. In this study, 80% of the patients were found to achieve ≥ 3 lines of visual improvement. Bell et al compared the outcomes of intravitreal versus subretinal tPA for SMHs secondary to various diseases in a retrospective study which included 18 patients in the intravitreal tPA + gas injection group and 14 patients in the vitrectomy + subretinal tPA injection group.¹³ They reported that 46% of the patients in the intravitreal injection group and 18% of the patients in the vitrectomy group showed ≥ 3 lines of visual improvement at month 12. There was a trend toward better visual outcomes in the injection group; however, this was not reported as significant. Similar to this study de Jong et al. compared the short term effects between intravitreal gas + tPA injection and vitrectomy + subretinal tPA injection techniques.²¹ At week 12 they measured the relative subretinal blood decrease and both methods had similar effects in regard to the displacement of SMH. Gök et al., evaluated the outcomes of vitrectomy, subretinal tPA injection and gas tamponade and face-down positioning in a retrospective study which included 17 patients.¹⁴ The visual acuity

increased from 1.8 LogMAR to 0.97 LogMAR after a mean follow-up time of 16.9 months. The visual acuity was reported to improve by ≥ 2 lines in 47% of the patients. They also evaluated the effect of SMH thickness on the visual outcomes. No significant relationship was reported. Fessenbender et al. compared 3 treatment methods in the treatment of SMH secondary to AMD.¹² They compared the outcomes of vitrectomy + subretinal tPA, and intravitreal tPA + gas injection, and intravitreal gas injection only. Final visual acuity improvement was found to be statistically significant in the two groups in which tPA was used either subretinally or intravitreally. However, the visual improvement was not statistically significant in the third group which consisted of the patients who received intravitreal gas only. The visual outcomes of two-step vitrectomy technique by Fleissig et al. were also similar with the aforementioned studies and ours.²⁰ They reported that all of the included 7 patients had visual acuity $\leq 6/120$ of which 5 remained stable and 2 showed improved vision at month 6.

The main limitation of the study was the retrospective design and small number of patients. However, we included only nAMD patients and evaluated a new surgical technique in the management of SMH secondary to nAMD, therefore 9 patients might be acceptable for such a pilot study.

Conclusions

In conclusion, vitrectomy, subretinal tPA injection and peroperative SMH displacement with liquid perfluorocarbon seemed to effectively displace the SMH in relatively few and small SMHs. However, visual outcomes were limited probably because of the poor baseline visual acuity levels and preexisting macular dysfunction. Further studies are needed to precisely conclude the anatomical and visual outcomes.

Conflict of interest

The authors declared that there is no conflict of interest.

Acknowledgements

The authors would like to thank Dr. Hande Mefkure Ozkaya for English language review of the manuscript.

References

1. Avery RL, Fekrat S, Hawkins BS, Bressler NM. Natural history of subfoveal subretinal hemorrhage in age-related macular degeneration. *Retina* 1996;**16**:183–9.
2. Stevens TS, Bressler NM, Maguire MG, et al. Occult choroidal neovascularization in age-related macular degeneration. A natural history study. *Arch Ophthalmol* 1997;**115**:345–50.
3. Scupola A, Coscas G, Soubrane G, Balestrazzi E. Natural history of macular subretinal hemorrhage in age-related macular degeneration. *Ophthalmologica* 1999;**213**:97–102.
4. Bressler NM, Bressler SB, Childs AL, et al. Surgery for hemorrhagic choroidal neovascular lesions of age-related macular degeneration: ophthalmic findings: SST report no. 13. *Ophthalmology* 2004;**111**:1993–2006.
5. Steel DH, Sandhu SS. Submacular haemorrhages associated with neovascular age-related macular degeneration. *Br J Ophthalmol* 2011;**95**:1051–7.
6. Submacular Surgery Trials Research Group, Solomon SD, Jefferys JL, Hawkins BS, Bressler NM. Incident choroidal neovascularization in fellow eyes of patients with unilateral subfoveal choroidal neovascularization secondary to age-related macular degeneration: SST report No. 20 from the Submacular Surgery Trials Research Group. *Arch Ophthalmol* 2007;**125**:1323–30.
7. Kapran Z, Ozkaya A, Uyar OM. Hemorrhagic age-related macular degeneration managed with vitrectomy, subretinal injection of tissue plasminogen activator, gas tamponade, and upright positioning. *Ophthalmic Surg Lasers Imag Retina* 2013;**44**:471–6.
8. Todorich B, Scott IU, Flynn Jr HW, Johnson MW. Evolving strategies in the management of submacular hemorrhage associated with choroidal neovascularization in the anti-vascular endothelial growth factor era. *Retina* 2011;**31**:1749–52.
9. Ibanez HE, Williams DF, Thomas MA, et al. Surgical management of submacular hemorrhage. A series of 47 consecutive cases. *Arch Ophthalmol* 1995;**113**:62–9.
10. Hillenkamp J, Surguch V, Framme C. Management of submacular hemorrhage with intravitreal versus subretinal injection of recombinant tissue plasminogen activator. *Graefes Arch Clin Exp Ophthalmol* 2010;**248**:5–11.
11. Tsymanava A, Uhlig CE. Intravitreal recombinant tissue plasminogen activator without and with additional gas injection in patients with submacular haemorrhage associated with age-related macular degeneration. *Acta Ophthalmol* 2011 Feb 18. <https://doi.org/10.1111/j.1755-3768.2011.02115.x>.
12. Fassbender JM, Sherman MP, Barr CC, Schaal S. Tissue plasminogen activator for subfoveal hemorrhage due to age-related macular degeneration: comparison of 3 treatment modalities. *Retina* 2016;**36**:1860–5.
13. Bell JE, Shulman JP, Swan RJ, Teske MP, Bernstein PS. Intravitreal versus subretinal tissue plasminogen activator injection for submacular hemorrhage. *Ophthalm Surg Lasers Imag Retina* 2017;**48**:26–32.
14. Gök M, Karabaş VL, Aslan MŞ, Kara Ö, Karaman S, Yenihayat F. Tissue plasminogen activator-assisted vitrectomy for submacular hemorrhage due to age-related macular degeneration. *Indian J Ophthalmol* 2017;**65**:482–7.
15. Fang IM, Lin YC, Yang CH, Yang CM, Chen MS. Effects of intravitreal gas with or without tissue plasminogen activator on submacular hemorrhage in age related macular degeneration. *Eye (Lond)* 2009;**23**:397–406.
16. Haupt CL, McCuen 2nd BW, Jaffe GJ, et al. Pars plana vitrectomy, subretinal injection of tissue plasminogen activator, and fluid-gas exchange for displacement of thick submacular hemorrhage in age-related macular degeneration. *Am J Ophthalmol* 2001;**131**:208–15.
17. Singh RP, Patel C, Sears JE. Management of subretinal macular haemorrhage by direct administration of tissue plasminogen activator. *Br J Ophthalmol* 2006;**90**:429–31.
18. Stopa M, Lincoff A, Lincoff H. Analysis of forces acting upon submacular hemorrhage in pneumatic displacement. *Retina* 2007;**3**:370–4.
19. Lincoff H, Kreissig I, Stopa M, Uram D. A 40 degrees gaze down position for pneumatic displacement of submacular hemorrhage: clinical application and results. *Retina* 2008;**28**:56–9.
20. Fleissig E, Barak A, Goldstein M, Loewenstein A, Schwartz S. Massive subretinal and subretinal pigment epithelial hemorrhage displacement with perfluorocarbon liquid using a two-step vitrectomy technique. *Graefes Arch Clin Exp Ophthalmol* 2017;**255**:1341–7.
21. de Jong JH, van Zeeburg EJ, Cereda MG, van Velthoven ME, Faridpooya K, Vermeer KA, et al. Intravitreal versus subretinal administration of recombinant tissue plasminogen activator combined with gas for acute submacular hemorrhages due to age-related macular degeneration: an exploratory prospective study. *Retina* 2016;**36**:914–25.