

# <sup>18</sup>F-FDG PET with or without CT in the diagnosis of extrahepatic metastases or local residual/recurrent hepatocellular carcinoma

Xiaoli Liao, MD<sup>a</sup>, Junbao Wei, MS<sup>b</sup>, Yongqiang Li, MS<sup>a</sup>, Jianhong Zhong, MD<sup>c</sup>, Zhihui Liu, MD<sup>a</sup>, Sina Liao, MS<sup>a</sup>, Qian Li, MD<sup>a</sup>, Changyuan Wei, MD<sup>d,\*</sup>

## Abstract

The aim of the present study was to meta-analyze the literature on the diagnostic value of 18-fluorodeoxyglucose (<sup>18</sup>F-FDG) positron emission tomography (PET) with or without computed tomography (CT) in detecting extrahepatic metastases or local residual/recurrent hepatocellular carcinoma (HCC).

Systematic review of literature in MEDLINE, Embase, and Cochrane databases was conducted in March 2017, and relevant studies analyzing the diagnostic performance of <sup>18</sup>F-FDG PET with or without CT were meta-analyzed.

Meta-analysis was carried out on data from 11 studies involving 572 patients. <sup>18</sup>F-FDG PET, with or without CT, showed pooled sensitivity of 64% and pooled specificity of 95%. Pooled sensitivity was similar with CT (74%) or without (52%;  $P = .279$ ). Similarly, pooled specificity was comparable with CT (93%) or without 95% ( $P = .481$ ).

<sup>18</sup>F-FDG PET, with or without CT, shows relatively low sensitivity but high specificity for diagnosing extrahepatic metastases or local residual/recurrent HCC. Adding CT to <sup>18</sup>F-FDG PET may improve diagnostic performance, but the available evidence suggests that the improvement is not statistically significant.

**Abbreviations:** AUC = Area under the receiver operating characteristic curve, CT = computed tomography, DOR = diagnostic odds ratio, <sup>18</sup>F-FDG = 18-fluorodeoxyglucose, HCC = hepatocellular carcinoma, LRs = Likelihood ratios, MRI = magnetic resonance imaging, NLR = negative likelihood ratio, PET = positron emission tomography, PLR = positive likelihood ratio.

**Keywords:** 18-fluorodeoxyglucose, hepatocellular carcinoma, meta-analysis, positron emission tomography/computed tomography, recurrent

## 1. Introduction

Hepatocellular carcinoma (HCC) is the fifth most common cancer and the third leading cause of cancer death worldwide, with half of HCC cases and HCC-related deaths occurring in China.<sup>[1,2]</sup> The best outcomes can be achieved with resection and transplantation in carefully selected patients, with 5-year survival

rates of 60% to 70%,<sup>[3,4]</sup> although a substantial proportion of these patients experience tumor recurrence, which is a major cause of HCC-related death.<sup>[5,6]</sup> Effective treatment and good prognosis depend on early detection and accurate staging of extrahepatic metastases and local residual/recurrent HCC.<sup>[7]</sup>

Residual, recurrent, and metastatic lesions are not detected well by traditional radiography such as magnetic resonance imaging (MRI) or computed tomography (CT), because these modalities detect morphologic changes, which can occur quite slowly in HCC<sup>[8–11]</sup> and MRI or CT imaging sites are often only a part of the body. A more effective modality seems to be positron emission tomography (PET) using the exogenous contrast agent 18-fluorodeoxyglucose (<sup>18</sup>FDG) and can scan the whole body. Talbot et al reported PET/CT is potentially useful in the initial evaluation of HCC or in the detection of recurrent disease.<sup>[12]</sup> Kuehl et al and Paudyal et al reported that PET/CT supports radiofrequency ablation RFA by early identification of residual tumor or local tumor progression.<sup>[13,14]</sup> Sun et al suggest that whole body <sup>18</sup>F-FDG PET/CT may be useful in the early evaluation of residual, intrahepatic recurrent or extrahepatic metastatic lesions and able to provide valuable information for the management of HCC recurrence.<sup>[15]</sup> However, its use in HCC remains controversial because of concerns about the relatively low sensitivity, especially for detecting well-differentiated HCC.<sup>[16,17]</sup> Indeed, the diagnostic performance of <sup>18</sup>F-FDG PET may strongly depend on clinicopathology: 1 study reported that in patients following transplantation, it detected only 25% of intrahepatic recurrence cases, but 92.9% of extrahepatic metastases larger than 1 cm.<sup>[18]</sup> In addition, <sup>18</sup>F-FDG uptake is increased in inflamed tissue, which can contribute to false-positive findings.

Editor: Kou Yi.

XL and JW contributed equally to this work.

The present study was supported by the medication and health care research program of Guangxi (grant nos: S201418-03 and S201634) and key planning development research program of Guangxi (grant no: guikeAB16380215), the Guangxi Natural Science Foundation (grant no: 2017GXNSFAA198103), the Graduate Course Project of Guangxi Medical University (YJSA2017014), and the Guangxi degree and postgraduate education reform (JGY2017035).

The authors have no conflicts of interest to disclose.

Supplemental Digital Content is available for this article.

<sup>a</sup> Department of First Chemotherapy, <sup>b</sup> Department of Therapeutic Radiology, <sup>c</sup> Hepatobiliary Surgery Department, <sup>d</sup> Department of Breast Surgery, Affiliated Tumor Hospital of Guangxi Medical University, Nanning, China.

\* Correspondence: Changyuan Wei, Department of Breast Surgery, Affiliated Tumor Hospital of Guangxi Medical University, He Di Rd 71#, Nanning 530021, China (e-mail: weicy23@163.com).

Copyright © 2018 the Author(s). Published by Wolters Kluwer Health, Inc. This is an open access article distributed under the terms of the Creative Commons Attribution-Non Commercial License 4.0 (CCBY-NC), where it is permissible to download, share, remix, transform, and buildup the work provided it is properly cited. The work cannot be used commercially without permission from the journal.

Medicine (2018) 97:34(e11970)

Received: 19 September 2017 / Accepted: 27 July 2018

<http://dx.doi.org/10.1097/MD.00000000000011970>

To address these limitations, researchers have explored the combination of functional information from  $^{18}\text{F}$ -FDG PET with morphologic information from CT. Several studies from different medical centers have analyzed the performance of this method in different contexts, so we wished to meta-analyze the evidence base to gain a comprehensive overall picture of whether CT can significantly improve the ability of  $^{18}\text{F}$ -FDG PET to detect extrahepatic metastases and local residual/recurrent HCC.

## 2. Materials and methods

### 2.1. Search strategy

MEDLINE, Embase, and Cochrane databases were searched for articles published between January 1990 and March 2017 using as search terms the MeSH headings “hepatocellular carcinoma,” “recurrence,” “metastases,” “positron-emission tomography,” “sensitivity and specificity,” and all possible combinations. Reference lists of all retrieved articles were also manually reviewed to detect additional potentially eligible articles.

### 2.2. Inclusion criteria

Two reviewers independently reviewed all potentially eligible studies for inclusion. To be included, studies had to fulfill the following criteria:  $^{18}\text{F}$ -FDG PET with or without CT was used to identify extrahepatic metastases or local residual/recurrent HCC; the sample contained more than 15 patients; patients were definitively diagnosed based on histology and follow-up for at least 6 months, and results were reported in a  $2 \times 2$  contingency table directly, or such a table could be derived from the reported data. If studies reported insufficient data, authors were contacted for additional information.

### 2.3. Data extraction and quality assessment

The same reviewers who carried out the database searches also independently extracted relevant data from each study using a standardized data extraction form, including test results and study characteristics. They were not blinded with regard to study authors, author affiliations, journal name, or year of publication, since such blinding does not substantially reduce risk of bias or errors.<sup>[19]</sup> Both reviewers extracted data from all studies. To resolve disagreement between reviewers, a third reviewer assessed all discrepant items, and the consensus opinion was used in the analysis.

The following data were extracted from each study: author, year of publication, sample size, age of study participants; and study design (prospective, retrospective, or unknown). Study quality was assessed using the QUADAS checklist for studies of diagnostic accuracy included in systematic reviews.<sup>[20]</sup> Articles were included in the final analysis only if “yes” was the response to at least 10 of the 14 questions on the QUADAS quality assessment tool.

### 2.4. Data synthesis and analysis

Statistical heterogeneity among studies was assessed using the Chi-squared test; results were defined as heterogeneous when  $P < .05$ .<sup>[21,22]</sup> The level of heterogeneity was quantified using the  $I^2$  statistic, which describes the percentage of total variation across studies that is due to heterogeneity rather than chance.<sup>[23]</sup> If heterogeneity existed, meta-analysis was performed using a random-effect model. Summary estimates and corresponding 95% confidence intervals were calculated.

We calculated pooled specificity and sensitivity for  $^{18}\text{F}$ -FDG PET alone and combined with CT. In data from studies reporting specificities or sensitivities of 100%, any 0 values were replaced with 0.5 to avoid problems when calculating odds ratios. Several metrics of diagnostic performance were calculated. Likelihood ratios (LRs) combine specificity and sensitivity:  $\text{LR}^-$  refers to the ratio of (1 = sensitivity) to specificity, while  $\text{LR}^+$  refers to the ratio of sensitivity to (1 = specificity). Both LRs equal 1 when a diagnostic test shows no discriminatory ability. A good diagnostic test has been defined as an  $\text{LR}^+ > 5.0$  and  $\text{LR}^- < 0.2$ , although no consensus standards exist.<sup>[24]</sup> Area under the receiver operating characteristic curve (AUC) was used as a global measure of test performance.<sup>[25]</sup> We also estimated sensitivity, specificity, and their respective variances to construct a summary receiver operating characteristic (SROC) curve and  $Q^*$  index. We used the Z test to compare the 2 techniques in terms of sensitivity, specificity, and DOR. The threshold for significance was defined as  $P < 0.05$ .

Publication bias was assessed by plotting the inverse of the square root of the effective sample size ( $\text{ESS}^{1/2}$ ) against the logarithm of the diagnostic odds ratio (DOR). If publication bias is absent, this scatter plot should show a symmetric funnel shape. To assess whether the plot deviated significantly from this shape, we performed regression of the logarithm of the DOR against  $\text{ESS}^{1/2}$  after weighting the odds ratios according to  $\text{ESS}$ .<sup>[26]</sup> The threshold for significant asymmetry was  $P < .05$ .

### 2.5. Subgroup analysis

We performed subgroup analyses based on technical differences between  $^{18}\text{F}$ -FDG PET when performed with or without CT, and based on whether extrahepatic metastasis or local residual/recurrent HCC was being diagnosed.

## 3. Results

### 3.1. Search results and study selection

After the computerized search was performed and reference lists were extensively cross-checked, 326 articles were identified, of which 36 potentially met the inclusion criteria based on title and abstract review. Of these 36 articles, 25 were excluded based on full-text review because they did not assess the diagnostic value of  $^{18}\text{F}$ -FDG PET with or without CT for identification of extrahepatic metastases or local residual/recurrent HCC ( $n = 18$ ), they did not report histopathology and/or imaging follow-up for at least 6 months as the diagnostic reference ( $n = 2$ ), they did not report data in a way suitable for calculating rates of true and false positives and negatives ( $n = 3$ ), they were associated with more than 5 responses of “no” or “unclear” on the QUADAS tool ( $n = 1$ ) or they were not based on per-patient data ( $n = 1$ ). In the end, 11 articles reporting 14 data sets were retained for data extraction and analysis.

### 3.2. Study characteristics

In the end, 7 publications consisting of 8 data sets analyzed the performance of  $^{18}\text{F}$ -FDG PET combined with CT,<sup>[15,27–32]</sup> while 5 publications consisting of 6 data sets analyzed the performance of  $^{18}\text{F}$ -FDG PET<sup>[14,27,33–35]</sup> (Supporting Table S2, <http://links.lww.com/MD/C418>). The number of patients per study ranged from 11 to 121 patients, with all studies evaluating a total of 572 patients. During our review of the literature, we

found that numerous relevant studies used a diagnostic reference of radiographic confirmation by multiple imaging techniques and/or clinical and imaging follow-up instead of histopathology, since performing such pathology was not feasible because of technical difficulties (e.g., deep-seated location) or ethical concerns. Therefore, we relaxed our original inclusion criterion of a histopathologic diagnostic reference to include such studies.

**3.3. Quality of included studies and publication bias**

Study quality was generally acceptable. All studies included in this meta-analysis fulfilled at least 9 of the 14 criteria in the QUADAS tool for methodologic quality (Supporting Table S1, <http://links.lww.com/MD/C418>). The nonsignificant slope of Deeks funnel plot asymmetry tests (Supporting Figure S1, <http://links.lww.com/MD/C418>) indicated no significant bias ( $P = .198$ ).

**3.4. Data analysis**

Across all 11 studies (Supporting Table S2, <http://links.lww.com/MD/C418>), <sup>18</sup>F-FDG PET with or without CT showed a pooled sensitivity of 64% (95% CI 60–68) (Supporting Figure S3, <http://links.lww.com/MD/C418>) and specificity of 95% (95% CI 91–97) (Supporting Figure S4, <http://links.lww.com/MD/C418>). LR synthesis gave an overall LR+ of 5.32 (95% CI 2.75–10.28) and LR– of 0.39 (95% CI 0.29–0.52).

Seven studies of <sup>18</sup>F-FDG PET with CT<sup>[15,27–32]</sup> showed a pooled sensitivity of 74% (95% CI 68–79) (Fig. 1) and specificity of 95% (95% CI 90–98) (Fig. 2). LR syntheses gave an overall LR+ of 5.54 (95% CI 2.69–11.41) and LR– of 0.33 (95% CI 0.22–0.48). Five studies of <sup>18</sup>F-FDG PET alone<sup>[14,27,33–35]</sup> gave a pooled sensitivity of 52% (95% CI 45–59) (Fig. 3) and specificity of 93% (95% CI 84–98) (Fig. 4). LR syntheses gave an overall LR+ of 5.32 (95% CI 1.44–19.70) and LR– of 0.5 (95% CI 0.34–0.73). No significant differences were found between <sup>18</sup>F-FDG

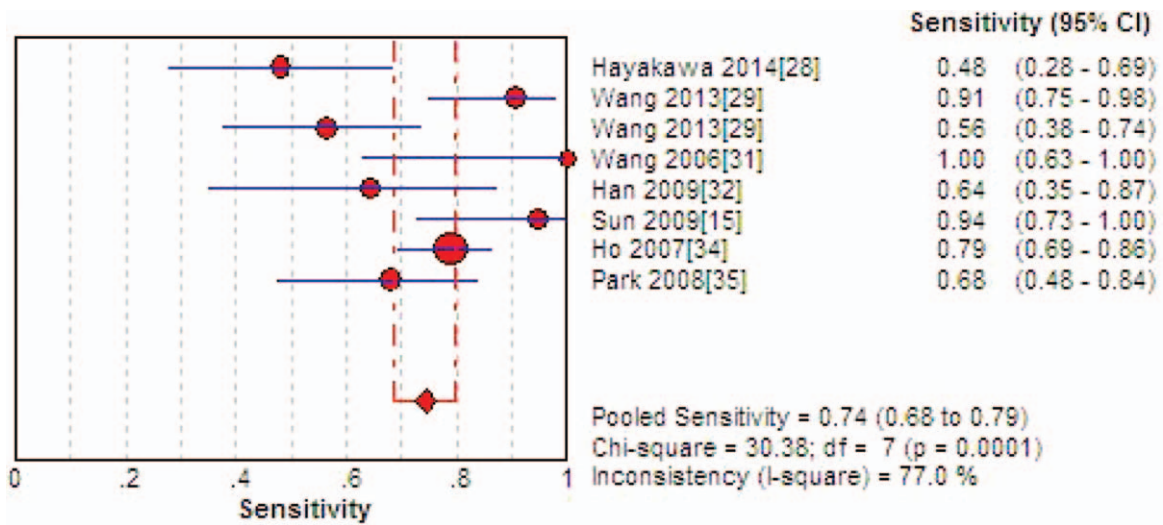


Figure 1. Forest plot of pooled sensitivity of 18-fluorodeoxyglucose positron emission tomography with computed tomography. CI = confidence interval.

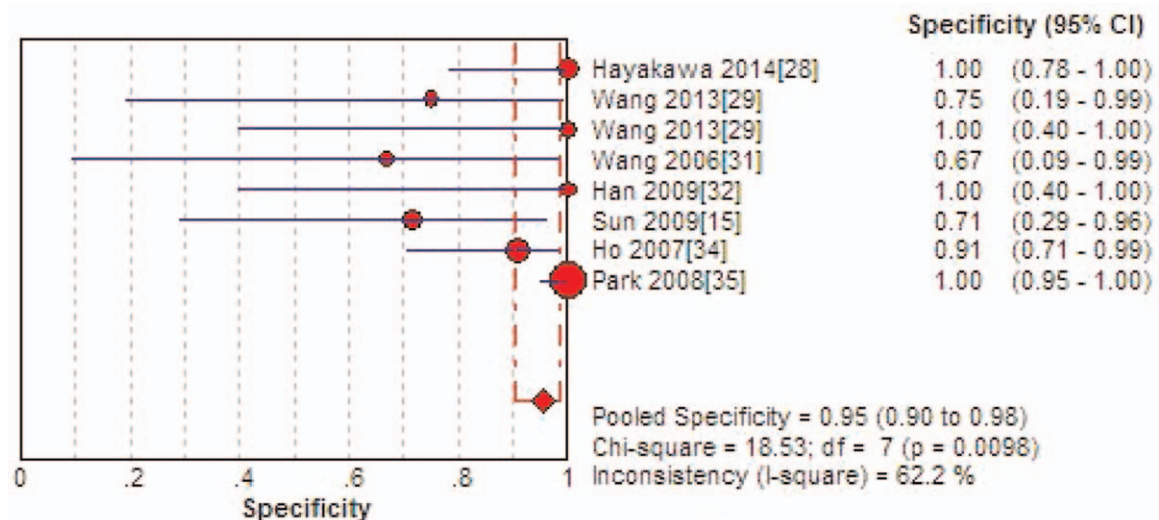


Figure 2. Forest plot of pooled specificity of 18-fluorodeoxyglucose positron emission tomography with computed tomography. CI = confidence interval.

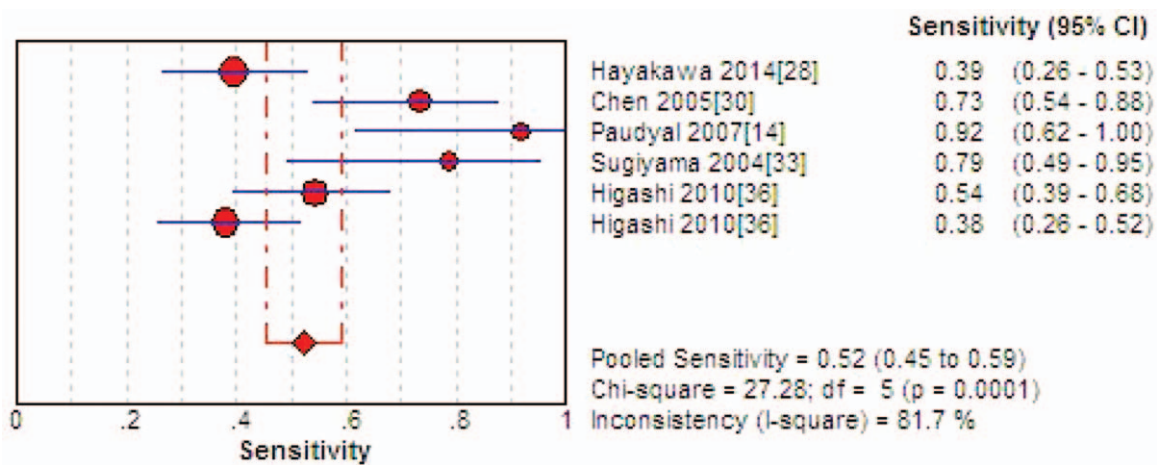


Figure 3. Forest plot of pooled sensitivity of 18-fluorodeoxyglucose positron emission tomography. CI = confidence interval.

PET with or without CT in terms of sensitivity, specificity, positive likelihood ratio (PLR), negative likelihood ratio (NLR), or DOR. Forest plots of the sensitivity and specificity results from each study, together with heterogeneity Chi-squared tests and the  $I^2$  index, indicated significant heterogeneity among the 11 studies. Therefore, pooled results were meta-analyzed using a random-effect model. The AUC for  $^{18}\text{F}$ -FDG PET with or without CT was 0.8846, and the  $Q^*$  index estimate was 0.8152 (Supporting Figure S2, <http://links.lww.com/MD/C418>).

### 3.5. Subgroup analysis

For the subset of data on detecting extrahepatic metastases (Table 1), no significant differences were found between  $^{18}\text{F}$ -FDG PET with or without CT in terms of sensitivity, specificity, PLR, NLR, or DOR. Similar results were obtained for the subset of data on detecting local residual/recurrent analysis.

## 4. Discussion

The present meta-analysis, in contrast to a previous one,<sup>[36]</sup> suggests that the available evidence does not indicate significant benefit of combining CT with  $^{18}\text{F}$ -FDG PET for detecting

extrahepatic metastases of HCC or recurrent HCC. The present meta-analysis may provide more reliable results than the previous one because it contains a larger number of studies selected through strict inclusion criteria and it compared the techniques quantitatively in terms of sensitivity, specificity, DOR, and summary ROC curves. While it remains possible that combining CT with  $^{18}\text{F}$ -FDG PET can provide diagnostic benefit in HCC, this remains to be demonstrated in large, well-controlled studies.

$^{18}\text{F}$ -FDG PET can detect malignancy because malignant lesions have a higher glucose metabolism and thus higher uptake of  $^{18}\text{F}$ -FDG. Since such metabolic changes precede changes in morphology,  $^{18}\text{F}$ -FDG PET can be more effective than MRI or CT for detecting small malignant lesions. In this way,  $^{18}\text{F}$ -FDG PET can work well as a well-established, noninvasive diagnostic tool for detecting malignant tumors<sup>[37,38]</sup> as well as staging and monitoring of therapeutic response in several cancers.

Nevertheless, the available evidence suggests that  $^{18}\text{F}$ -FDG PET does not show as good diagnostic performance for HCC as for other cancers. We found in a previous meta-analysis<sup>[39]</sup> that the technique shows a pooled sensitivity of 93% and specificity of 92% to detect local residual/recurrent nasopharyngeal carcinoma. Goense et al<sup>[40]</sup> reported pooled sensitivity of 96% (95% CI 93–97%) and specificity of 78% (95% CI 66–86%) to detect

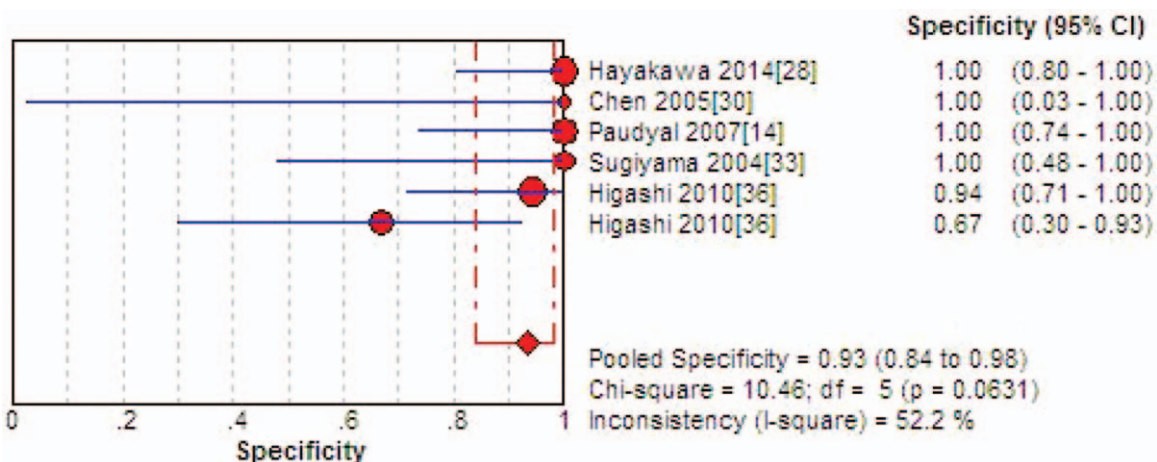


Figure 4. Forest plot of pooled specificity of 18-fluorodeoxyglucose positron emission tomography. CI = confidence interval.

**Table 1****Summary estimates of diagnostic performance for <sup>18</sup>F-FDG PET with or without CT.**

Subgroup	Sensitivity	Specificity	LR+	LR–	DOR
Any lesion	0.64 (0.60–0.68)	0.95 (0.91–0.97)	5.32 (2.75–10.28)	0.39 (0.29–0.52)	21.25 (9.01–50.14)
<sup>18</sup> F-FDG PET/CT	0.74 (0.68–0.79)	0.95 (0.90–0.98)	5.54 (2.69–11.41)	0.33 (0.22–0.48)	35.9 (14.73–87.45)
<sup>18</sup> F-FDG PET	0.52 (0.45–0.59)	0.93 (0.84–0.98)	5.32 (1.44–19.70)	0.5 (0.34–0.73)	13.39 (2.68–67.00)
<i>P</i>	.279	.481	.574	.186	.763
Extrahepatic metastases	0.64 (0.58–0.70)	0.95 (0.90–0.99)	7.07 (1.13–38.31)	0.40 (0.23–0.68)	19.07 (2.52–144.33)
<sup>18</sup> F-FDG PET/CT	0.72 (0.65–0.79)	0.98 (0.93–1.00)	13.14 (3.12–55.36)	0.33 (0.21–0.51)	46.06 (10.52–201.69)
<sup>18</sup> F-FDG PET	0.46 (0.34–0.58)	0.79 (0.49–0.95)	2.41 (0.26–22.6)	0.52 (0.14–1.87)	5.01 (0.18–140.8)
<i>P</i>	.637	.562	.471	.607	.475
Local residual/recurrent	0.75 (0.68–0.81)	0.90 (0.77–0.97)	4.02 (2.11–7.67)	0.26 (0.14–0.48)	27.29 (9.50–78.38)
<sup>18</sup> F-FDG PET/CT	0.88 (0.78–0.94)	0.78 (0.52–0.94)	3.23 (1.54–6.77)	0.18 (0.07–0.49)	28.41 (6.77–119.15)
<sup>18</sup> F-FDG PET	0.65 (0.55–0.75)	0.97 (0.83–1.00)	8.07 (2.17–30.06)	0.34 (0.15–0.78)	26.02 (5.48–123.66)
<i>P</i>	.328	.078	.321	.303	.538

Results are reported as an odds ratio or the indicated ratio, together with 95% CI in parentheses.

CI=confidence interval, CT=computed tomography, DOR=diagnostic odds ratio, <sup>18</sup>F-FDG = 18-fluorodeoxyglucose, LR=Likelihood ratio, PET=positron emission tomography.

recurrent esophageal cancer. The present meta-analysis indicates a pooled sensitivity of only 52% to detect any HCC lesion, 46% to detect extrahepatic metastases, and 65% to detect local residual/recurrent HCC, compared to a much higher pooled specificity of 95% (95% CI 91–97%) to detect extrahepatic metastases or local residual/recurrent HCC. This low sensitivity is consistent with several other studies of <sup>18</sup>F-FDG PET in HCC,<sup>[16,17,41]</sup> and it may reflect the fact that glucose-6-phosphatase, which converts FDG-6-P to FDG, is nearly inactive in most tumors, including many liver tumors,<sup>[42,43]</sup> although FDG metabolism in many well-differentiated HCC cells can be similar to that of normal liver tissue.<sup>[44]</sup> Because of the low sensitivity of FDG PET/CT imaging, there are some promising ways to improve the sensitivity of PET/CT for diagnosis of HCC, such as: 11C-acetate, could make up for the lack of FDG imaging.<sup>[45]</sup> The available evidence, then, suggests that <sup>18</sup>F-FDG PET on its own does not offer satisfactory diagnostic performance for HCC. Lesions showing abnormal extrahepatic accumulation of FDG are likely to be metastases, and diagnosis of local recurrence is difficult even if there is an abnormal accumulation of FDG in the liver. One of the reasons why FDG-PET is not useful in the diagnosis of intrahepatic recurrence is due to the difficulty in distinguishing between abnormal accumulation and physiologic accumulation of FDG in the liver.

Therefore, several studies have assessed whether supplementing the functional information of <sup>18</sup>F-FDG PET with morphologic information of CT can improve diagnostic performance. Our meta-analysis indicates that based on a carefully selected set of studies, there is evidence of a trend toward higher performance with CT, but this trend is not statistically significant for any of the diagnostic indices, including sensitivity, specificity, PLR, NLR, or DOR. These findings are based primarily on studies that examined either <sup>18</sup>F-FDG PET with CT or <sup>18</sup>F-FDG PET alone, not both techniques, which highlights the need for large parallel comparisons to verify and extend the present findings.

Like any meta-analysis of diagnostic accuracy, the present work is limited by heterogeneity among studies in terms of radiologist experience, image interpretation, and methodologic quality. We have attempted to reduce the impact of this heterogeneity in 3 ways. First, we applied various inclusion criteria to minimize differences among study populations and technology. Second, we identified potential sources of heterogeneity using the QUADAS tool. Third, we performed subgroup analyses to assess the impact of factors likely to cause heterogeneity. Even with these measures, our results may be

less reliable because of unmeasured or unreported patient characteristics. The relatively small numbers of patients treated with each modality prevented us from controlling for the influence of certain patient characteristics.

Our estimates of diagnostic performance may also be less reliable because of the absence of a gold standard for imaging-based detection of local residual or recurrent tumor. Most studies in our meta-analysis relied on clinical course and other imaging techniques to confirm the presence of malignant disease; only a subset of patients underwent biopsy. This increases the risk not only of overall misdiagnosis but also of failure to detect smaller lesions, which may not have become detectable even after the six or more months of follow-up reported in the studies.

## 5. Conclusion

<sup>18</sup>F-FDG PET with or without CT can diagnose extrahepatic metastases or local residual/recurrent HCC with high specificity but low sensitivity. Future work is needed to determine whether the tendency toward improved diagnostic performance observed with CT is statistically significant, preferably in prospective studies involving a parallel comparison of the 2 modalities.

## Author contributions

**Conceptualization:** Xiaoli Liao, Junbao Wei.

**Data curation:** Xiaoli Liao, Junbao Wei.

**Formal analysis:** Xiaoli Liao.

**Funding acquisition:** Yongqiang Li.

**Investigation:** Yongqiang Li, Changyuan Wei.

**Methodology:** Yongqiang Li, Qian Li, Changyuan Wei.

**Project administration:** Jianhong Zhong.

**Resources:** Jianhong Zhong, Qian Li, Changyuan Wei.

**Software:** Zhihu Liu, Changyuan Wei.

**Supervision:** Zhihu Liu.

**Validation:** Sina Liao.

**Visualization:** Sina Liao.

**Writing – original draft:** Xiaoli Liao.

**Writing – review & editing:** Xiaoli Liao, Junbao Wei.

## References

- [1] Siegel RL, Miller KD, Jemal A. Cancer statistics, 2015. *CA Cancer J Clin* 2015;65:5–29.
- [2] Jemal A, Bray F, Center MM, et al. Global cancer statistics. *CA Cancer J Clin* 2011;61:69–90.

- [3] Lau W, Lai ECH. Management and recent advances. *Hepatobiliary Pancreat Dis Int* 2008;7:237–57.
- [4] Zhong JH, Ke Y, Gong WF, et al. Hepatic resection associated with good survival for selected patients with intermediate and advanced-stage hepatocellular carcinoma. *Ann Surg* 2014;260:329–40.
- [5] Zhong JH, Ma L, Li LQ. Postoperative therapy options for hepatocellular carcinoma. *Scand J Gastroenterol* 2014;49:649–61.
- [6] Zhong JH, Zhong QL, Li LQ, et al. Adjuvant and chemopreventive therapies for resectable hepatocellular carcinoma: a literature review. *Tumour Biol* 2014;35:9459–68.
- [7] Clavien PA, Lesurtel M, Bossuyt PM, et al. Recommendations for liver transplantation for hepatocellular carcinoma: an international consensus conference report. *Lancet Oncol* 2012;13:e11–22.
- [8] Vogl TJ, Trapp M, Schroeder H, et al. Transarterial chemoembolization for hepatocellular carcinoma: volumetric and morphologic CT criteria for assessment of prognosis and therapeutic success: results from a liver transplantation center. *Radiology* 2000;214:349–57.
- [9] Kamel IR, Bluemke DA, Eng J, et al. The role of functional MR imaging in the assessment of tumor response after chemoembolization in patients with hepatocellular carcinoma. *J Vasc Interv Radiol* 2006;17:505–12.
- [10] Imamura H, Matsuyama Y, Tanaka E, et al. Risk factors contributing to early and late phase intrahepatic recurrence of hepatocellular carcinoma after hepatectomy. *J Hepatol* 2003;38:200–7.
- [11] Johnson PJ. Hepatocellular carcinoma: is current therapy really altering outcome? *Gut* 2002;51:459–62.
- [12] Talbot JN, Gutman F, Fartoux L, et al. PET/CT in patients with hepatocellular carcinoma using [(18)F]fluorocholine: preliminary comparison with [(18)F]FDG PET/CT. *Eur J Nucl Med Mol Imaging* 2006;33:1285–9.
- [13] Kuehl H, Stattaus J, Hertel S, et al. Mid-term outcome of positron emission tomography/computed tomography-assisted radiofrequency ablation in primary and secondary liver tumours - a single-centre experience. *Clin Oncol (R Coll Radiol)* 2008;20:234–40.
- [14] Paudyal B, Oriuchi N, Paudyal P, et al. Early diagnosis of recurrent hepatocellular carcinoma with 18F-FDG PET after radiofrequency ablation therapy. *Oncol Rep* 2007;18:1469–73.
- [15] Sun L, Guan YS, Pan WM, et al. Metabolic restaging of hepatocellular carcinoma using whole-body 18F-FDG PET/CT. *World J Hepatol* 2009;1:90–7.
- [16] Trojan J, Schroeder O, Raedle J, et al. Fluorine-18 FDG positron emission tomography for imaging of hepatocellular carcinoma. *Am J Gastroenterol* 1999;94:3314–9.
- [17] Khan MA, Combs CS, Brunt EM, et al. Positron emission tomography scanning in the evaluation of hepatocellular carcinoma. *J Hepatol* 2000;32:792–7.
- [18] Kim YK, Lee KW, Cho SY, et al. Usefulness 18F-FDG positron emission tomography/computed tomography for detecting recurrence of hepatocellular carcinoma in posttransplant patients. *Liver Transpl* 2010;16:767–72.
- [19] West R. Does blinding of readers affect the results of meta-analyses? *Lancet* 1997;350:185–6.
- [20] Whiting P, Rutjes AW, Reitsma JB, et al. The development of QUADAS: a tool for the quality assessment of studies of diagnostic accuracy included in systematic reviews. *BMC Med Res Methodol* 2003;3:25.
- [21] DerSimonian R, Laird N. Meta-analysis in clinical trials. *Control Clin Trials* 1986;7:177–88.
- [22] Greenland S. Quantitative methods in the review of epidemiologic literature. *Epidemiol Rev* 1987;9:1–30.
- [23] Higgins JP, Thompson SG, Deeks JJ, et al. Measuring inconsistency in meta-analyses. *BMJ* 2003;327:557–60.
- [24] Pakos EE, Kyzas PA, Ioannidis JP. Prognostic significance of TP53 tumor suppressor gene expression and mutations in human osteosarcoma: a meta-analysis. *Clin Cancer Res* 2004;10(Pt 1):6208–14.
- [25] Harbord RM, Deeks JJ, Egger M, et al. A unification of models for meta-analysis of diagnostic accuracy studies. *Biostatistics* 2007;8:239–51.
- [26] Deeks JJ, Macaskill P, Irwig L. The performance of tests of publication bias and other sample size effects in systematic reviews of diagnostic test accuracy was assessed. *J Clin Epidemiol* 2005;58:882–93.
- [27] Hayakawa N, Nakamoto Y, Nakatani K, et al. Clinical utility and limitations of FDG PET in detecting recurrent hepatocellular carcinoma in postoperative patients. *Int J Clin Oncol* 2014;19:1020–8.
- [28] Wang XY, Chen D, Zhang XS, et al. Value of 18F-FDG-PET/CT in the detection of recurrent hepatocellular carcinoma after hepatectomy or radiofrequency ablation: a comparative study with contrast-enhanced ultrasound. *J Dig Dis* 2013;14:433–8.
- [29] Wang XL, Li H, Wang QS, et al. Clinical value of pre-and postoperative 18F-FDG PET/CT in patients undergoing liver transplantation for hepatocellular carcinoma. *Nan Fang Yi Ke Da Xue Xue Bao* 2006;26:1087–95.
- [30] Han AR, Gwak GY, Choi MS, et al. The clinical value of 18F-FDG PET/CT for investigating unexplained serum AFP elevation following interventional therapy for hepatocellular carcinoma. *Hepatogastroenterology* 2009;56:1111–6.
- [31] Ho CL, Chen S, Yeung DW, et al. Dual-tracer PET/CT imaging in evaluation of metastatic hepatocellular carcinoma. *J Nucl Med* 2007;48:902–9.
- [32] Park JW, Kim JH, Kim SK, et al. A prospective evaluation of 18F-FDG and 11C-acetate PET/CT for detection of primary and metastatic hepatocellular carcinoma. *J Nucl Med* 2008;49:1912–21.
- [33] Chen YK, Hsieh DS, Liao CS, et al. Utility of FDG-PET for investigating unexplained serum AFP elevation in patients with suspected hepatocellular carcinoma recurrence. *Anticancer Res* 2005;25:4719–25.
- [34] Sugiyama M, Sakahara H, Torizuka T, et al. 18F-FDG PET in the detection of extrahepatic metastases from hepatocellular carcinoma. *J Gastroenterol* 2004;39:961–8.
- [35] Higashi T, Hatano E, Ikai I, et al. FDG PET as a prognostic predictor in the early post-therapeutic evaluation for unresectable hepatocellular carcinoma. *Eur J Nucl Med Mol Imaging* 2010;37:468–82.
- [36] Lin CY, Chen JH, Liang JA, et al. 18F-FDG PET or PET/CT for detecting extrahepatic metastases or recurrent hepatocellular carcinoma: a systematic review and meta-analysis. *Eur J Radiol* 2011;81:2417–22.
- [37] Higashi T, Saga T, Nakamoto Y, et al. Diagnosis of pancreatic cancer using fluorine-18 fluorodeoxyglucose positron emission tomography (FDG PET) - usefulness and limitations in “clinical reality”. *Ann Nucl Med* 2003;17:261–79.
- [38] Delbeke D, Martin WH. PET and PET-CT for evaluation of colorectal carcinoma. *Semin Nucl Med* 2004;34:209–23.
- [39] Wei J, Pei S, Zhu X. Comparison of 18F-FDG PET/CT, MRI and SPECT in the diagnosis of local residual/recurrent nasopharyngeal carcinoma: a meta-analysis. *Oral Oncol* 2016;52:11–7.
- [40] Goense L, van Rossum PS, Reitsma JB, et al. Diagnostic performance of 18F-FDG PET and PET/CT for the detection of recurrent esophageal cancer after treatment with curative intent: a systematic review and meta-analysis. *J Nucl Med* 2015;56:995–1002.
- [41] Jeng LB, Changlai SP, Shen YY, et al. Limited value of 18F-2-deoxyglucose positron emission tomography to detect hepatocellular carcinoma in hepatitis B virus carriers. *Hepatogastroenterology* 2003;50:2154–6.
- [42] Torizuka T, Tamaki N, Inokuma T, et al. In vivo assessment of glucose metabolism in hepatocellular carcinoma with FDG-PET. *J Nucl Med* 1995;36:1811–7.
- [43] Caracó C, Aloj L, Chen LY, et al. Cellular release of [18F]2-fluoro-2-deoxyglucose as a function of the glucose-6-phosphatase enzyme system. *J Biol Chem* 2000;275:18489–94.
- [44] Seo S, Hatano E, Higashi T, et al. Fluorine-18 fluorodeoxyglucose positron emission tomography predicts tumor differentiation, P-glycoprotein expression, and outcome after resection in hepatocellular carcinoma. *Clin Cancer Res* 2007;13:427–33.
- [45] Park JW, Kim JH, Kim SK. A Prospective evaluation of 18F-FDG and 11C-acetate PET/CT for detection of primary and metastatic hepatocellular carcinoma. *J Nucl Med* 2008;49:1912–21.