

Case report

Open Access

An unusual presentation of Castleman's Disease: a case report

Ifeoma S Izuchukwu^{1,2,5}, Kamal Tourbaf^{2,3} and Martin C Mahoney*^{1,4,5}

Address: ¹Department of Social and Preventive Medicine, State University of New York at Buffalo, 276 Farber Hall, Buffalo, NY, USA, ²Department of Internal Medicine, State University of New York at Buffalo, 462 Grider Street, Buffalo, NY 14215, USA, ³Department of Hematology & Oncology, ECMC, 462 Grider Street, Buffalo, NY 14215, USA, ⁴Department of Family Medicine, State University of New York at Buffalo, ECMC Clinical Center, 462 Grider Street, Buffalo, NY 14215, USA and ⁵Division of Cancer Prevention & Population Sciences, Roswell Park Cancer Institute, Buffalo, NY 14263, USA

Email: Ifeoma S Izuchukwu - dshaikhgroupe@aol.com; Kamal Tourbaf - ktourbaf@ams.ecmc.edu; Martin C Mahoney* - martin.Mahoney@roswellpark.org

* Corresponding author

Published: 11 September 2003

Received: 12 April 2003

BMC Infectious Diseases 2003, 3:20

Accepted: 11 September 2003

This article is available from: <http://www.biomedcentral.com/1471-2334/3/20>

© 2003 Izuchukwu et al; licensee BioMed Central Ltd. This is an Open Access article: verbatim copying and redistribution of this article are permitted in all media for any purpose, provided this notice is preserved along with the article's original URL.

Abstract

Background: Castleman's disease (CD), a rare condition of uncertain etiology, involves a massive proliferation of lymphoid tissues and typically presents as mediastinal masses. We describe a patient with CD who presented with diffuse adenopathy involving the inguinal, paratracheal, retroperitoneal, axillary, and pelvic regions.

Case presentation: Case report describing presentation, work-up, management and clinical course of a patient with Castleman's disease in the setting of a county hospital in metropolitan area. Patient was treated with chemotherapeutic agents.

Conclusions: To our knowledge, this represents the first case of CD involving an HIV-positive patient with a negative Human Herpes Virus (HHV-8) viral panel. Because patients with similar clinical histories are at high risk for the development of non-Hodgkin's lymphoma and Kaposi sarcoma, regular medical surveillance is recommended.

Background

Castleman's disease (CD) involves a massive non-malignant proliferation of lymphoid tissues and typically presents as mediastinal masses. This uncommon condition was initially described among a small series of patients in 1956. [1] Castleman's affects patients of varying ages and cases have been reported from adolescence into the seventh decade. [2]

Most cases of Castleman's Disease represent either the hyaline vascular variant (80–90% of cases) or the plasma cell variant (10–20%); a small percentage present with a

mixed histologic appearance. [3] Patients with the hyaline vascular form of CD may exhibit no symptoms or only lymphadenopathy while persons with the plasma cell variant typically present with fever, weight loss, rash and anemia. Multifocal or Multicentric Castleman's Disease (MCD), is a systemic form of the plasma cell variant with patients exhibiting generalized peripheral lymphadenopathy, hepatosplenomegaly, frequent fevers, and night sweats. [4] Treatment can range from curative surgery for the hyaline form of CD to the use of chemotherapy for MCD.

Case presentation

In 06/01, a white male in his fourth decade presented to the emergency department of a metropolitan county hospital with a 3-month history of an enlarging right inguinal mass. He noted accompanying scrotal swelling, night sweats, and groin pain, rated as 4/10 in severity, intermittent in nature with radiation to the surrounding inguinal area and right testicle.

This patient had been admitted to the same institution one month earlier with the same complaints. At that time, a fine needle biopsy of the right inguinal node was done and the patient was discharged with instructions for medical follow-up. Pain medications were prescribed for symptom control. Before the date of the follow-up visit, the patient returned to the emergency department with the same complaints. The needle biopsy result was subsequently reported as "negative for malignant cells."

Past medical history was significant for infection with Human Immunodeficiency Virus (HIV) and four episodes of pneumocystis carinii pneumonia (most recent in 2000), consistent with a diagnosis of Autoimmune Deficiency Syndrome (AIDS); (a subsequent CD4 count completed in July 2001 was 108/microliter). This patient also reported bilateral hip pain, neuropathic foot pain bilaterally and gastroesophageal reflux disease. Past surgical history revealed repair of a right inguinal hernia as a child, right inguinal fine needle biopsy 5/01, and repair of a left undescended testis as a child. Medications at the time of admission included: efavirenz 600 milligrams (mg) once daily, stavudine 40 mg twice daily, lamivudine 150 mg twice daily, sulfamethoxazole/trimethoprim (800 mg/160 mg) once daily, lansoprazole 15 mg daily, nortriptyline 75 mg daily.

A review of systems was significant for a weight loss of five pounds over the past month and the chronic hip pain reportedly previously diagnosed as osteoarthritis.

At presentation, the oral temperature was 99.1 degrees Fahrenheit and a heart rate of 108; vital signs were otherwise unremarkable. The patient was noted to be conscious, alert and oriented but somewhat agitated; beads of sweat were noted on his forehead. Physical examination was significant for mild pallor, left axillary lymphadenopathy, diffuse abdominal tenderness, mild hepatosplenomegaly and 2+ pitting edema involving the proximal right lower extremity. This edema involved the right inguinal region and extended inferiorly to the upper thigh; right thigh diameter was noticeably larger than the left (objective measurement not recorded). Genital examination revealed a circumcised, thickened, doughy penis and an enlarged right non-erythematous testicle with mild tenderness to palpation/manipulation. The right inguinal

area was swollen, firm and tender with massive adenopathy measuring 12 centimeters (cm) by 8 cm; no discharge or warmth to touch was noted. The left groin area revealed a well-healed inguinal scar consistent with prior surgery and non-tender adenopathy recorded as 4 cm by 2 cm without erythema, warmth, or discharge.

Initial laboratory testing included a complete blood count with differential, chemistry panel, coagulation panel, urinalysis, and computerized tomography (CT) scans of the abdomen and pelvis. Blood tests were unremarkable except for mild anemia with hemoglobin of 10.2 grams/deciliter (g/dl). The CT scan revealed extensive retroperitoneal, pelvic, and bilateral inguinal adenopathy [figure 1].

Following an initial assessment in the emergency department, this patient was admitted for further work-up and pain control. Differential diagnoses were focused on infectious and malignant etiologies [table 1].

Upon admission, additional laboratory studies were ordered including repeat complete blood count with differential, liver profile, Erythrocyte Sedimentation Rate (ESR), protein electrophoresis, and serum immunoelectrophoresis to rule out multiple myeloma, given the chronic hip pain.

CT scan of the chest showed an enlarged right paratracheal lymph node. Radiographs of right hip revealed mixed sclerotic and lytic lesions of the acetabulum and femur. Bone scan showed increased uptake in right femoral head, trochanter and proximal shaft of femur. The differential diagnosis at this point included lymphoma, multiple myeloma, and HIV adenopathy. Surgical and infectious disease consultations were requested.

The infectious disease service noted this patient's immunocompromised status and the possibility of an ineffective febrile response. Accordingly, the possibility of an infectious etiology was expanded to include infectious adenitis, disseminated *Mycobacterium avium intercellulare* (MAC) infection, disseminated tuberculosis, *Cryptococcus*, *Histoplasmosis* and *Rhodococcus equi* (*Nocardia restricta*). *Histoplasmosis* was unlikely as there was no reported travel to histoplasmosis endemic regions. Additional studies were performed: hepatitis profile to rule out hepatitis infection and a viral panel (Human Herpes Virus [HHV]-8, Human T-cell Lymphotropic Virus [HTLV]-1 & HTLV-11, and Epstein Barr Virus [EBV]), since viral infections have been associated with certain malignancies in HIV-positive patients.

Open biopsy and fine needle re-biopsy of the right inguinal lymph nodes were completed by the surgical

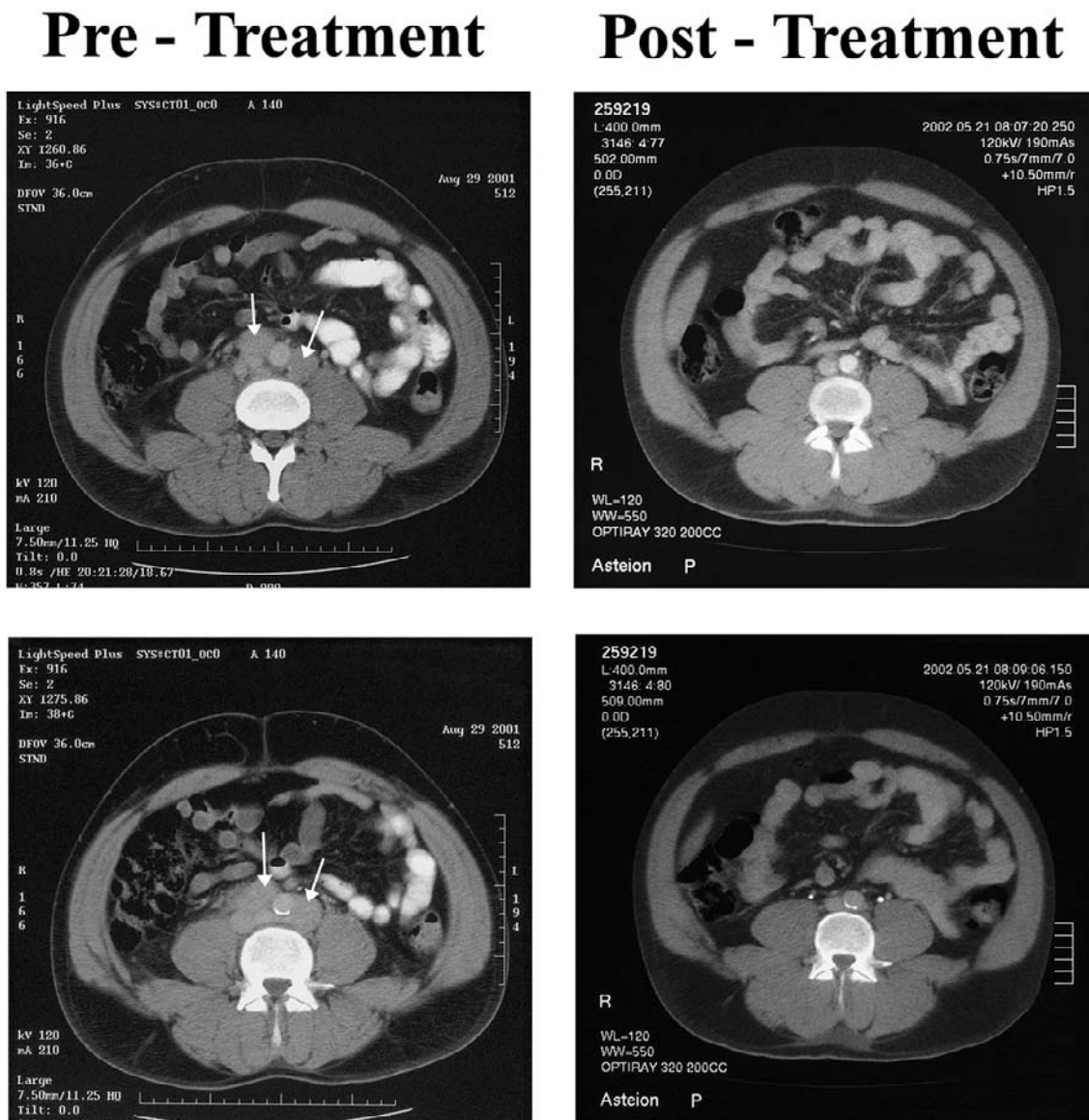


Figure 1
Pre-treatment and post-treatment CT Scans showing diffusely enlarged retroperitoneal adenopathy (see arrows) and subsequent disappearance following chemotherapy.

service. The specimens from these biopsies were sent to pathology for histologic review, bacterial culture, fungal culture, viral culture, and acid-fast bacilli staining. Flow cytometry and repeat CD4 count and HIV RNA load was

performed to assess current immune status and to rule out lymphoma.

The repeat complete blood count revealed normal lymphocyte (3,100 /mm³) and absolute neutrophil counts

Table 1: Initial and expanded differential diagnoses for male HIV(+) patient who presented with painful right inguinal adenopathy

Initial Differential	Expanded Differential
<p>Infectious:</p> <ul style="list-style-type: none"> -tuberculosis, atypical mycobacterium -lymphogranuloma venereum -cat scratch disease -HIV adenopathy -sebaceous cyst -sporotrichosis -other infections (e.g., sexually transmitted diseases) <p>Malignant:</p> <ul style="list-style-type: none"> -Hodgkins' Disease -non-Hodgkins' lymphoma -AIDS-related lymphoma -multiple myeloma -testicular cancer 	<p>Infectious:</p> <ul style="list-style-type: none"> -adenitis -disseminated mycobacterium avium intercellulare -disseminated tuberculosis -cryptococcus -histoplasmosis -nocardia restricta <p>Malignant:</p> <ul style="list-style-type: none"> -angiosarcoma

(9,600/mm³) and stable mild anemia (hemoglobin 10.8 g/dl). ESR was 125 mm/hour. Negative Rapid Plasmin Reagin (RPR) testing served to rule out syphilis. Two sets of blood cultures were negative for bacterial growth. The viral, fungal and bacterial studies, as well as acid-fast testing on the biopsied lymph node material were all negative. Flow cytometry was negative. Protein electrophoresis showed high alpha 2 levels, a faint Immunoglobulin G kappa band, and low albumin, essentially ruling out multiple myeloma. The hepatitis panel was negative. A liver function panel revealed an alanine aminotransaminase level of 194 units/liter, alkaline phosphatase of 253 units/liter and lactate dehydrogenase of 726 IU/liter, essentially unchanged from values noted at time of admission.

An ultrasensitive HIV RNA assay was undetectable and the CD4 count, which was initially 27/microliter, became undetectable during the hospital course. The patient's low CD4 was determined to be secondary to abnormal lymphocyte processing and cell turnover resulting from his current disease process, rather than failure of the highly active anti-retroviral therapy (HAART) and patient was continued on HAART by the infectious disease consultant.

Histologic evaluation revealed atrophic lymphoid follicles with small germinal centers and cellular reticular stroma with increased populations of plasma cells (see Figure 2 and Figure 3). A review of these specimens by pathology staff at a nearby comprehensive cancer center noted "florid HIV-associated plasma cell hyperplasia" and suggested the possibility of Castleman's Disease since this disorder is a plasma cell variant associated with interleukin 6 (IL-6) syndrome. Immunohistochemical stains demonstrated both kappa and lambda positive cells, which are non-specific pathologic findings in Castleman's disease as well as other malignant conditions.

The patient's clinical presentation of non-infectious lymphadenopathy (all cultures negative), in combination with the absence of typical pathognomic features supporting a diagnosis of Castleman's Disease, necessitated a comprehensive review of published literature by the inpatient medical team. Following completion of this review, along with input from the infectious disease consultant, it was determined that this patient's diagnosis was a multicentric type of Castleman's Disease.

Accordingly the patient was started on a chemotherapy regimen of doxorubicin, vincristine, cyclophosphamide and prednisone by the hematology/oncology service. The patient appeared to tolerate this well, achieving some resolution of edema as well as adequate pain control.

This patient was discharged to home on day 3 following the first course of chemotherapy, with instructions for further out-patient follow-up with the oncologist. This patient received a total of six courses of chemotherapy and has remained in remission approximately 18 months following diagnosis (see figure 1 for post-treatment CT scans), although he continues to complain of hip pain.

Discussion

Castleman's Disease (CD) represents a distinct clinicopathological entity first described by Dr. Benjamin Castleman in 1956. [1] Castleman's report described a series of 13 patients with a condition characterized by localized non-malignant mediastinal lymphadenopathy. Most subsequent case series have described affected patients ranging in age between the second and seventh decades. [2]

There are two pathological types of Castleman's Disease – the hyaline vascular variant and plasma cell variant. The hyaline vascular variant exhibits prominent proliferation of small hyalinized follicles with marked interfollicular

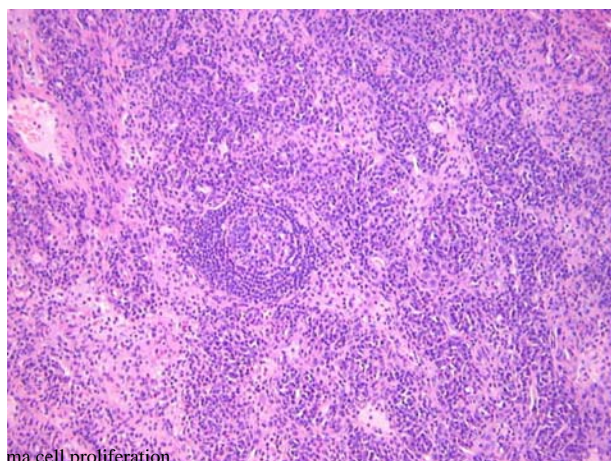


Figure 2
Plasma cell infiltrate in inguinal lymph node biopsy. Atrophic follicles (magnification 40×). Bottom.

vascular proliferation, but while the plasma cell variant exhibits hyperplastic germinal centers, sheets of plasma cells in the interfollicular region, proliferation of blood vessels, and persistent sinuses. It is postulated that 10 – 20 percent of all cases are of the plasma cell variant, with a small percentage being of mixed histologic appearance. [3] Multicentric Castleman's Disease (MCD) or multifocal disease, is usually the plasma cell variant, and is a systemic disease with generalized peripheral lymphadenopathy, hepatosplenomegaly, frequent fevers, and night sweats. [4]

The first case of MCD, which presented as generalized lymphadenopathy with systemic manifestations of fever, night sweats, weight loss and fatigue, was reported in 1978. [5] Castleman's typically presents in patients' ages 50 to 65 years, but for those who are HIV (+), it presents at a younger age, as in the patient described in this report. HIV seropositive individuals appear to be at an increased risk for MCD, [5–7] and it can often arise concurrently with Kaposi sarcoma (KS). It has been reported that among HIV (+) patients with multicentric CD who are infected with HHV-8, up to 70 percent will develop KS at some time in their clinical course. [6–9] MCD commonly results in a fatal outcome due to infectious complications, multi-organ failure, and development of malignancies such as lymphoma (Hodgkin's and non-Hodgkin's) or Kaposi sarcoma. [7,9,10] In contrast, localized, Castleman's Disease, also referred to as unifocal or unicentric disease (UCD), is typically an isolated benign lymphoproliferative disorder of young adults, is usually not associated with HHV-8 infection, and is generally curable with

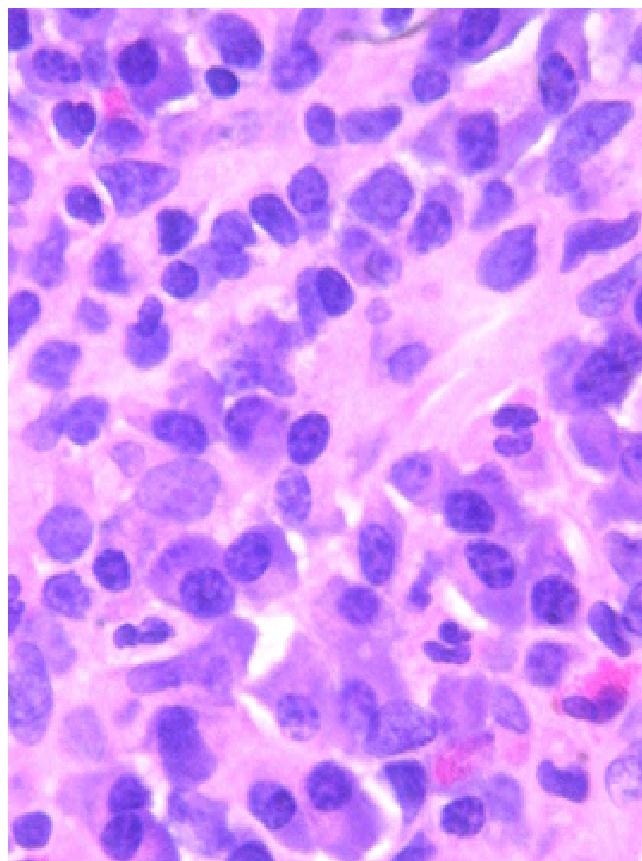


Figure 3
Plasma cells are identified by their eccentric, clock-face nucleus and pale perinuclear cytoplasmic crescent. Staining by hematoxylin-eosin stain (magnification 400×).

surgical resection (with or without radiotherapy). [10–12,3]

In some patients, multi-centric disease has been associated with both HIV infection and co-infection with human herpesvirus-8 (HHV-8). HHV-8 is also known as Kaposi sarcoma-associated virus, [5–7,14] and it is postulated that HHV-8 produces interleukin 6 and is responsible for lymphoplasmacytic proliferation. [5–8,15] Moreover, the presence of other human cytokines produced by HHV-8 could contribute to lymphoplasmacytosis and to endothelial proliferation. [16] In one study, HHV-8 sequences were found in lymph nodes in all 14 cases of HIV(+) MCD and in 7 of 17 cases of HIV(-) MCD, as compared to 1 of 51 HIV(-) reactive lymph nodes and 3 of 17 HIV(+) reactive lymph nodes. [1] Other studies have confirmed that HHV-8 appears to be universally

found in HIV (+) MCD patients and in approximately 40 to 50 percent of MCD patients who are HIV (-) MCD. [1] Interestingly, our patient was negative for HHV-8 virus, based upon negative PCR and immunohistochemistry for blood and lymph node biopsy specimens, which appears to be the first report of an HIV (+) patient with MCD who is negative for HHV-8 infection.

It has been suggested that expression of Castleman's Disease is partly due to IL-6 activity; HHV-8 is known to encode a viral IL-6. One hypothesis for the origin of MCD is that HHV-8 expresses viral IL-6, which induces vascular endothelial growth factor (VEGF), which then induces human IL-6 production by endothelial cells. [19] Use of neutralizing antibodies against IL-6 and monoclonal antibody blocking the IL-6 receptor, have demonstrated clinical efficacy, resulting in symptom resolution. [20,21] All seven patients, in one study, treated with monoclonal antibodies to IL-6 receptor had resolution of their clinical symptoms, followed by improvement in their lymphadenopathy. [22] Once therapy was stopped, however, symptoms recurred. It is possible that the lymphoproliferation noted in our patient was stimulated via other cytokine pathways possibly associated with HIV infection or by an as yet undiscovered mechanism.

After the exclusion of Hodgkin's disease, non-malignant lymphoma, and an infectious etiology, multicentric Castleman's disease (MCD) remained the likely diagnosis in this patient. In addition, the high ESR, in combination with a constellation of relevant clinical signs and symptoms, such as extensive lymphadenopathy, hepatosplenomegaly, night sweats and plasma cell hyperplasia, negative laboratory work up and a history of HIV/AIDS, further supported the diagnosis. The diagnosis was subsequently confirmed via histopathologic evaluation.

Another clinical observation is the association of MCD with POEMS (polyneuropathy, organomegaly, endocrinopathy, monoclonal protein, and skin changes) syndrome. [23] Our patient demonstrated hepatosplenomegaly, polyneuropathy, high alpha 2 protein and skin changes around the genitalia. Although only four aspects of the POEMS syndrome were manifested in our patient, this is similar to presentations reported in other MCD cases. [3]

At present, there is no consensus as to the optimal management strategy for MCD. Successful treatment of MCD has been achieved using chemotherapy, with or without prednisone, given at the time of initial diagnosis. [5] The chemotherapeutic agents used in the various case series that have yielded remissions include doxorubicin, vincristine, cyclophosphamide, melphalan and chlorambucil. These have been used as single agents, together with ster-

oids or in combination (e.g., CHOP). Azathioprine and bone marrow transplantation have also been attempted, especially following failure of CHOP, but have yielded mixed results. [3]

In a case series of seven patients, chemotherapy alone, both as a single agent and in combination with corticosteroids, was used with mixed results: six of the patients died of varied causes (lymphoma, Kaposi sarcoma (n = 3), encephalitis and unknown cause); one patient treated with meticorten survived but length of survival was not stated. [24] Another series of 15 patients with MCD treated with chemotherapy produced clinical responses in 14 of 15 patients (93 %); however, only 7 of 15 patients (47%) were reported to be alive and 4 (27%) had no evidence of disease. [3] No duration of response or survival with chemotherapy was noted in that report.

Subsequent follow-up contact with both the patient and attending oncologist approximately 18 months following diagnosis, documented an excellent response to the chemotherapy regimen and no evidence of active disease; he remains under active surveillance. It should be noted that because of this medical history, this patient is considered to be at high risk for the development of non-Hodgkin's lymphoma and Kaposi sarcoma and regular medical follow up is indicated.

Conclusion

Our patient represents the first report of an HIV/AIDS patient with MCD found to be negative for HHV-8 infection. This case also illustrates additional unique clinical features at time of presentation, including extensive adenopathy of multiple sites and various components of the POEMS syndrome. This patient, and others with similar clinical histories, is at high risk for the development of non-Hodgkin's lymphoma and Kaposi sarcoma and ongoing medical follow up is necessary.

It is important to consider CD in the differential diagnosis for patients presenting with extensive lymphadenopathy, especially those with acquired immunodeficiency. The clinical index of suspicion for CD or MCD is heightened by the presence of other factors such as HIV infection/AIDS, hypoalbuminemia, POEMS syndrome, hypergammaglobulinemia, fever of unknown origin, and night sweats.

Given the guarded prognosis for Castleman's disease, it is prudent to pursue appropriate diagnostic work up for this condition along with other differential diagnoses in order to arrive at an accurate diagnosis and prescribe appropriate therapy. Confirmation of the diagnosis should be based upon the combination of medical history, clinical findings, and histopathological evaluation.

Competing Interests

None declared.

Author Contributions

IS prepared an initial draft and coordinated revisions, MCM participated in manuscript revisions and development of the final manuscript and KT also provided revisions to the text. IS and MCM conceived of this report.

Acknowledgements

We thank staff at the Erie County Medical Center for assistance in evaluation of this patient. In particular, we acknowledge the contributions of Terry Makson, Ross Richer, Dr. Slate and Dr. Balos for administrative and technical support. Written consent was obtained from the patient for publication of this report.

References

1. Castleman B, Iverson I and Menendez VP: **Localized mediastinal lymph-node hyperplasia resembling thymoma.** *Cancer* 1956, **9**:822-830.
2. Herrada J, Cabanillas F, Rice L, Manning J and Pugh W: **Clinical behavior of localized and multicentric Castleman's disease.** *Annals of Internal Medicine* 1998, **128**:657-662.
3. Keller AR and Hochholzer L: **Hyaline-vascular and plasma-cell types of giant lymph node hyperplasia of the mediastinum and other locations.** *Cancer* 1972, **29**:670.
4. Peterson BA and Frizzera G: **Multicentric Castleman's disease.** *Semin Oncol* 1993, **20**(6):636-47.
5. Gaba AR, Stein RS, Sweet DL and Variakojis D: **Multicentric giant lymph node hyperplasia.** *Am J Clin Pathol* 1978, **69**:86-90.
6. Dupin N, Diss TL, Kellam P, Tulliez M, Du MQ, Sicard D, Weiss RA, Isaacson PG and Boshoff C: **HHV-8 is associated with a plasmablastic variant of Castleman disease that is linked to HHV-8-positive plasmablastic lymphoma.** *Blood* 2000, **95**(4):1406-12.
7. Oksenhendler E, Duarte M, Soulier J, Cacoub P, Welker Y and Cadranet J: **Multicentric Castleman's disease in HIV infection: a clinical and pathological study of 20 patients.** *AIDS* 1996, **10**(1):61-7.
8. Zietz C, Bogner JR, Goebel FD and Lohrs U: **An unusual cluster of cases of Castleman's disease during highly active antiretroviral therapy for AIDS.** *N Engl J Med* 1999, **340**(24):1923-4.
9. Oksenhendler E, Boulanger E, Galicier L, Du MQ, Dupin N, Diss TC, Hamoudi R, Daniel MT, Agbalika F, Boshoff C, Clauvel JP, Isaacson PG and Meignin V: **High incidence of Kaposi sarcoma-associated herpesvirus-related non-Hodgkin lymphoma in patients with HIV infection and multicentric Castleman disease.** *Blood* 2002, **99**(7):2331-6.
10. **Case records of the Massachusetts General Hospital; Weekly clinicopathological exercises. Case 39: A 66-year-old man with demyelinating neuropathy and a retroperitoneal mass.** *N Engl J Med* 1990, **323**:895-908.
11. Lachant NA, Sun NC, Leong LA, Oseas RS and Prince HE: **Multicentric angiofollicular lymph node hyperplasia (Castleman's disease) followed by Kaposi's sarcoma in two homosexual males with the acquired immunodeficiency syndrome (AIDS).** *Am J Clin Pathol* 1985, **83**:27-33.
12. Frizzera G, Peterson BA, Bayrd ED and Goldman A: **A systemic lymphoproliferative disorder with morphologic features of Castleman's disease: clinical findings and clinicopathologic correlations in 15 patients.** *J Clin Oncol* 1985, **3**(9):1202-16.
13. Kessler E: **Multicentric giant lymph node hyperplasia. A report of seven cases.** *Cancer* 1985, **56**(10):2446-51.
14. Munoz G, Geijo P, Moldenhauer F, Perez-Moro E, Razquin J and Piris MA: **Plasmacellular Castleman's disease and POEMS syndrome.** *Histopathology* 1990, **17**:172-4.
15. Oksenhendler E, Carcelain G and Aoki Y: **High levels of human herpesvirus 8 viral load, human interleukin-6, interleukin-10, and C reactive protein correlate with exacerbation of multicentric Castleman Disease in HIV-infected patients.** *Blood* 2000, **96**:2069.
16. Aaron L, Lidove O, Viard JP, Troisvallet D, Piketty C and Vittecoq D: **Castleman's disease in patients infected with HIV.** *Revue de Medicine Interne* 2002, **23**(2):155-63.
17. Soulier J, Grollet L, Oksenhendler E, Miclea JM, Cacoub P, Baruchel A, Brice P, Clauvel JP, d'Agay MF and Raphael M: **Molecular analysis of clonality in Castleman's disease.** *Blood* 1995, **86**(3):1131-8.
18. Gessain A, Sudaka A, Briere J, Fouchard N, Nicola MA and Rio B: **Kaposi sarcoma-associated herpes-like virus (human herpesvirus type 8) DNA sequences in multicentric Castleman's disease: is there any relevant association in non-human immunodeficiency virus-infected patients?** *Blood* 1996, **87**(1):414-6.
19. Du MQ, Liu H, Diss Ye H, Hamoudi RA, Cabecada J and Dong HT: **Kaposi sarcoma-associated herpesvirus infects monotypic (Igm lambda) but polyclonal naive B cells in Castleman's disease and associated lymphoproliferative disorders.** *Blood* 2001, **97**(7):2130-2136.
20. Beck JT, Hsu SM, Wijdenes J, Bataille R, Klein B, Vesole D and Hayden K: **Brief report: alleviation of systemic manifestations of Castleman's disease by monoclonal anti-interleukin-6 antibody.** *N Engl J Med* 1994, **330**(9):602-5.
21. Foussat A, Fior R, Girard T, Boue F, Wijdenes J and Galanaud P: **Involvement of human interleukin-6 in systemic manifestations of human herpesvirus type 8-associated multicentric Castleman's disease.** *AIDS* 1999, **13**(1):150-2.
22. Nishimoto N, Sasai M, Shima Y, Nakagawa M, Matsumoto T and Shirai T: **Improvement in Castleman's disease by humanized anti-interleukin-6 receptor antibody therapy.** *Blood* 2000, **95**(1):56-61.
23. Bardwick PA: **Plasma cell dyscrasia with polyneuropathy, organomegaly, endocrinopathy, M protein and skin changes. The POEMS syndrome. Report on two cases and a review of the literature.** *Medicine (Baltimore)* 1980, **59**:311-22.
24. Soulier J, Grollet L, Oksenhendler E, Cacoub P, Cazals-Hatem D and Brice P: **Kaposi's sarcoma-associated herpesvirus-like DNA sequences in multicentric Castleman's disease.** *Blood* 1995, **86**:1276-80.

Pre-publication history

The pre-publication history for this paper can be accessed here:

<http://www.biomedcentral.com/1471-2334/3/20/prepub>

Publish with **BioMed Central** and every scientist can read your work free of charge

"BioMed Central will be the most significant development for disseminating the results of biomedical research in our lifetime."

Sir Paul Nurse, Cancer Research UK

Your research papers will be:

- available free of charge to the entire biomedical community
- peer reviewed and published immediately upon acceptance
- cited in PubMed and archived on PubMed Central
- yours — you keep the copyright

Submit your manuscript here:
http://www.biomedcentral.com/info/publishing_adv.asp

