




Since January 2020 Elsevier has created a COVID-19 resource centre with free information in English and Mandarin on the novel coronavirus COVID-19. The COVID-19 resource centre is hosted on Elsevier Connect, the company's public news and information website.

Elsevier hereby grants permission to make all its COVID-19-related research that is available on the COVID-19 resource centre - including this research content - immediately available in PubMed Central and other publicly funded repositories, such as the WHO COVID database with rights for unrestricted research re-use and analyses in any form or by any means with acknowledgement of the original source. These permissions are granted for free by Elsevier for as long as the COVID-19 resource centre remains active.



Short Communication

Guillain-Barré syndrome associated with SARS-CoV-2 infection: A case report with long term follow up

Nowshin Papri^{a,b}, Shoma Hayat^a, Asif Mohammed^a, Md. Nure Alam Afsar^a, Imran Hasan^a, Ananna Rahman^a, Israt Jahan^a, Zhahirul Islam^{a,*}

^a Laboratory of Gut-Brain Signaling, Laboratory Sciences and Services Division, icddr,b, Dhaka 1212, Bangladesh

^b Department of Neurology, Erasmus MC, University Medical Center, Rotterdam, the Netherlands



ARTICLE INFO

Keywords:

Guillain-Barré syndrome
SARS-CoV-2
COVID-19
Bangladesh

ABSTRACT

A 50-years old male presented with quadriplegia and paresthesia and was diagnosed as Guillain-Barré syndrome (GBS). He was found positive for severe acute respiratory syndrome coronavirus-2 (SARS-CoV-2) six weeks prior to the onset of weakness. GBS disability score was 4. Electrophysiology showed acute inflammatory demyelinating polyradiculopathy. Anti-SARS-CoV-2 IgG was found positive. Immunological tests for *Campylobacter jejuni*, Zika virus, Hepatitis E virus, Herpes Simplex virus, *Haemophilus influenzae* and *Mycoplasma pneumoniae* were negative. Patient received standard dose of intravenous immunoglobulin and after six months had almost complete recovery of muscle power. This case represents possible association of SARS-CoV-2 infection and GBS with good clinical outcome.

1. Introduction

Severe acute respiratory syndrome coronavirus 2 (SARS-CoV-2) which causes coronavirus disease- 2019 (COVID-19) has affected around one hundred and two million people with more than two million mortalities all over the world, as of January 31, 2021 (*Coronavirus Resource Center, 2021*). COVID-19 predominantly causes mild to severe respiratory symptoms; however, multiple systemic manifestations have also been reported (*Huang et al., 2020*). Neurological manifestations due to COVID-19 have been reported among 40% of the patients which include headache, altered consciousness, acute encephalopathy, ataxia or peripheral nervous system involvement (*Mao et al., 2020*). Numerous case-reports/series have been published which suggest a possible association between SARS-CoV-2 infection and Guillain-Barré syndrome (GBS) (*Hasan et al., 2020; Uncini et al., 2020*). Observational multicenter studies in Italy reported 2.6–5.4 -fold increase in the incidence of GBS during the pandemic (*Filosto et al., 2020; Gigli et al., 2021*). However, most of these studies did not exclude the possibility of other common antecedent infections which have been evidenced to trigger the development of GBS. More recently, an epidemiological and cohort study in the UK concluded that GBS was not associated with COVID-19 (*Keddie et al., 2021*). Therefore, it is still too early to rule out the association

between SARS-CoV-2 infection and GBS. Moreover, the clinical outcome of these patients has not been thoroughly investigated. Hereby, we present a GBS case following SARS-CoV-2 infection with exclusion of other common antecedent events that may cause GBS. We also followed up the patients until six months of disease onset to evaluate the recovery pattern.

2. Methods

The patient was admitted to National Institute of Neurosciences and Hospital, Dhaka, Bangladesh on 3 September 2020. GBS was diagnosed as per National Institute of Neurological Disorders and Stroke (NINDS) criteria and confirmed by nerve conduction study (NCS). SARS-CoV-2 infection was confirmed by real-time reverse transcriptase-polymerase chain reaction (RT-PCR). Serological markers and routine laboratory investigations were performed by enzyme-linked immunosorbent assay (ELISA) and chemistry auto-analyzer respectively. We followed up the patient at week 2, week 8 and week 26.

2.1. Case report

On 3rd September 2020, a 50 years old hypertensive male presented

* Corresponding author at: Laboratory of Gut-Brain Signaling, Laboratory Sciences and Services Division, icddr,b, 68, Shaheed Tajuddin Ahmad Sarani, Mohakhali, Dhaka 1212, Bangladesh.

E-mail address: zislam@icddr.org (Z. Islam).

<https://doi.org/10.1016/j.jneuroim.2021.577590>

Received 3 February 2021; Received in revised form 24 April 2021; Accepted 25 April 2021

Available online 28 April 2021

0165-5728/© 2021 Elsevier B.V. All rights reserved.

with progressive symmetrical weakness of both upper and lower limbs for 12 days. He also had complaints of limb pain, mild paresthesia and constipation for 7 days. The patient had a history of flu like symptoms including cough and fever six weeks prior to the onset of weakness. Thereafter, he was tested for SARS-CoV-2 by RT-PCR of nasopharyngeal sample and found positive. Initially, he was managed at home with oral acetaminophen. A week later, he developed respiratory distress and was hospitalized where he was treated with oxygen therapy and antibiotic (ceftriaxone), other supportive treatments. After 5 days of hospitalization, he became clinically stable with subsiding respiratory distress and fever and was discharged from Covid unit to home.

During admission for quadriplegia at NINS, patient was found afebrile with normal vitals except blood pressure 144/99 mmHg during clinical examination. All deep tendon reflexes were absent. Medical Research Council (MRC) scores were: 4/5 in proximal and distal muscles of upper limb and proximal muscles of lower limb; 3/5 in distal muscles of lower limb. GBS disability score was 4 with no sensory, cranial or autonomic dysfunction. All other systemic examination including respiratory system showed no abnormality.

NCS was performed on the same day and demonstrated decreased compound membrane action potential (CMAP) in median, ulnar, tibial and peroneal nerves, however CMAP in sural nerve was normal. Distal motor latency was prolonged and evidence of conduction block was found in all nerves. F waves were absent. No response at sensory nerve action potential (SNAP) in median and ulnar nerves with normal SNAP in sural nerve. The findings were suggestive of acute inflammatory demyelinating polyradiculopathy (AIDP) with sural sparing.

RT-PCR for SARS-CoV-2 infection and serology for anti-SARS-CoV-2 IgG were performed on 3rd September and found positive. Antinuclear antibody (ANA) and anti-GM1 antibody were tested and found negative. Serological tests for *Campylobacter jejuni* (*C. jejuni*), Zika virus, Hepatitis E virus, Herpes simplex virus, *Haemophilus influenzae*, *Mycoplasma pneumoniae* were found negative. However, IgG against cytomegalovirus (CMV) was found positive (Table 1).

The patient received standard dose (0.4 g/Kg per day for 5 days) of intravenous immunoglobulin (IVIg). On 8th September 2020 high resolution CT of chest was performed which showed involvement of both lungs having multifocal ground glass infiltrates, consolidations with fibrosis with total 42% lung involvement. RT-PCR for SARS-CoV-2 remained positive for comparatively longer duration and became negative on 18th September 2020, after eight weeks of onset of initial respiratory symptoms. After six months of onset of GBS, he has MRC sum score - 5/5 (upper limb) and 4/5 (lower limb); GBS disability score was 1 with complaints of tingling sensation in both feet. Patient has resumed his usual daily activities with complaints of minor fatigue in sustained

physical activity (Fig. 1).

3. Discussion

We report a patient who was diagnosed as GBS with confirmed preceding SARS-CoV-2 infection. The clinical features along with NCS findings confirmed the diagnosis of GBS. The association of SARS-CoV-2 infection was confirmed through RT-PCR with serological affirmation of anti-SARS-CoV-2 IgG. The possibilities of other common antecedent infections that trigger the development of GBS were excluded. The patient was followed up at different time points and found good recovery after six months of disease onset.

Till date, more than 70 GBS cases from all over the world have been reported with a possible association with SARS-CoV-2 (Hasan et al., 2020; Uncini et al., 2020). However, most of these cases were reported from western countries, around 80% from Europe (Uncini et al., 2020). Very limited data are available on SARS-CoV-2-associated GBS from low- and middle-income countries except four cases from India, one from Morocco and one from Sudan (Hasan et al., 2020; Nanda et al., 2021; El Otmani et al., 2020; Sidig et al., 2020). About 80% previously reported cases had electro-diagnostic features of demyelinating GBS and 62% showed definite improvement after treatment with IVIg which is consistent with current findings (Hasan et al., 2020; Uncini et al., 2020).

Antecedent infections predominantly respiratory or gastrointestinal symptoms are reported by two-thirds of patients with GBS. The most frequently identified infectious agents that triggers GBS are *C. jejuni*, CMV, Epstein-Barr virus, mycoplasma pneumonia and Zika (Wakerley and Yuki, 2013). SARS-CoV-2 is a very new viral infection and common complications along with the pathogenesis are not yet well established. In general, GBS is a post-infectious disorder which develops due to generation of auto-antibodies that cross react with specific nerve gangliosides (van Den Berg et al., 2014). However, anti-GM1 antibody was negative in the current patient which was similar with previously reported cases (Uncini et al., 2020).

The average period between antecedent infection with SARS-CoV-2 and the onset of GBS is usually 1–2 weeks. However, longer period up to 5 weeks has also been reported in recent study (Hasan et al., 2020). In the current patient, the duration between the development of GBS and infection with SARS-CoV-2 was ~6 weeks. In general, the duration of onset of GBS and any antecedent events is usually considered as 1–4 weeks. But the maximum duration has been reported up to 6 weeks (Yuki and Hartung, 2012). The patient was found negative for other common antecedent infections except positive for CMV IgG antibody indicative of previous infection with CMV. In Bangladesh, CMV-IgG seroprevalence is 98% in healthy adult (Islam et al., personal communication). Considering all these evidences, we cannot exclude SARS-CoV-2 infection as a possible causative agent of GBS in the current patient.

The current patient had positive RT PCR for SARS-CoV-2 even after 6 weeks of COVID-19 diagnosis although he was clinically recovered. This could be due to persistence of shedding of the virus or presence of virus residues in the host even after clearance of live virus which can persist after 20–44 days of active infection (Lan et al., 2020; He et al., 2020).

This case report adds evidence that SARS-CoV-2 infection is associated with typical presentation of GBS, predominantly AIDP variant, that respond to standard IVIg treatment with a favorable outcome. Further case-control and cohort studies are required to evaluate the true causal relationship between SARS-CoV-2 and GBS.

Funding

This research did not receive any specific grant from funding agencies in the public, commercial, or not-for-profit sectors.

Declaration of Competing Interest

The authors declare no competing interests. Z.I. received restricted

Table 1

Recent infections status of the studied patient.

Infectious agents	Results
Anti-SARS-CoV-2 IgG	Positive
<i>C. jejuni</i>	Negative
Anti-Zika IgG	Negative
Anti-Zika IgM	Negative
Anti-CMV IgM	Non-reactive
Anti-CMV IgG	Reactive
Anti-HEV IgM	Negative
Anti-GM1 IgG	Negative
Anti-HSV (Type I + Type 2) IgM	Negative
HBsAg	Non-reactive
HIV Ag/Ab	Non-reactive
<i>H. influenzae</i>	Negative
<i>M. pneumoniae</i>	Negative

C. jejuni: *Campylobacter jejuni*; CMV: Cytomegalovirus; HEV: Hepatitis E virus; HSV: Herpes simplex virus; HBsAg: Hepatitis B Virus Surface Antigen; HIV: Human immunodeficiency virus; SARS-CoV-2: Severe acute respiratory syndrome coronavirus 2; *M. pneumoniae*: *Mycoplasma pneumoniae*; *H. influenzae*: *Haemophilus influenzae*.

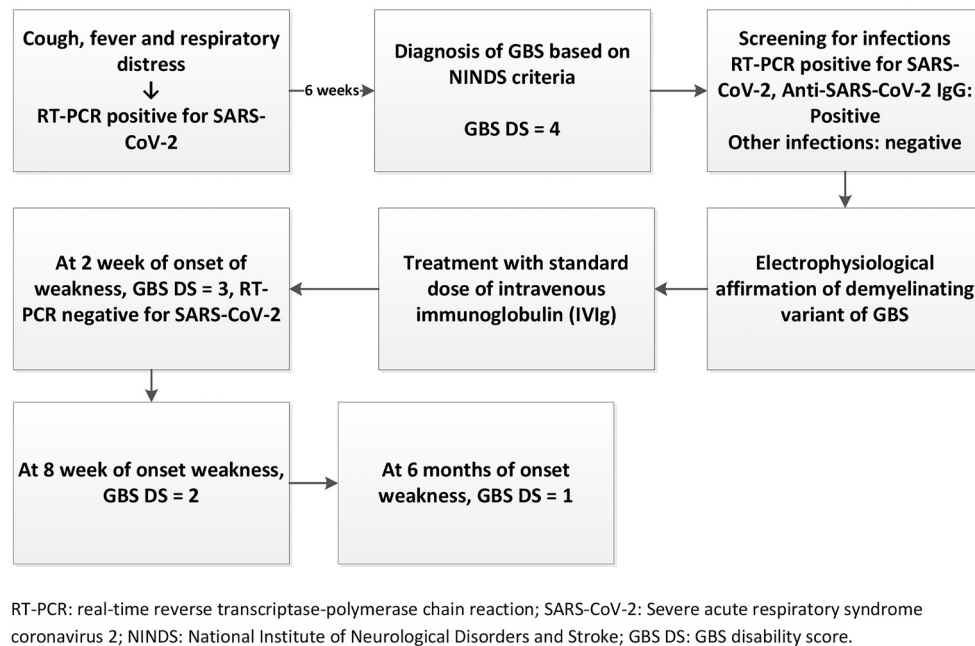


Fig 1. Sequence of events of the patient.

grant (number 1K43TW011447-01) support from Fogarty International Center, the National Institute of Neurological Disorders and Stroke (NINDS), National Institutes of Health (NIH) and Annexon Biosciences for activities unrelated to the subject matter of this paper.

Acknowledgements

icddr,b is grateful to its core donors including the Governments of Bangladesh, Canada, Sweden and the United Kingdom for providing core/unrestricted support for its operations and research. We thank Prof. Dr. Quazi Deen Mohammad for critically reviewing this manuscript.

References

- Coronavirus Resource Center, 2021. Johns Hopkins University. <https://coronavirus.jhu.edu/map.html> (Accessed January 31, 2021).
- van Den Berg, B., Walgaard, C., Drenthen, J., Fokke, C., Jacobs, B.C., Van Doorn, P.A., 2014. Guillain-Barré syndrome: pathogenesis, diagnosis, treatment and prognosis. *Nat. Rev. Neurol.* 10 (8), 469.
- El Otmani, H., El Moutawakil, B., Rafai, M.A., El Benna, N., El Kettani, C., Soussi, M., El Mdaghri, N., Barrou, H., Afif, H., 2020 Jun. Covid-19 and Guillain-Barré syndrome: more than a coincidence! *Rev. Neurol.* 176 (6), 518.
- Filosto, M., Piccinelli, S.C., Gazzina, S., Foresti, C., Frigeni, B., Servalli, M.C., Sessa, M., Cosentino, G., Marchioni, E., Ravaglia, S., Briani, C., 2020 Nov 6. Guillain-Barré syndrome and COVID-19: an observational multicentre study from two Italian hotspot regions. *J. Neurol. Neurosurg. Psychiatry.* <https://doi.org/10.1136/jnnp-2020-324837>.
- Gigli, G.L., Bax, F., Marini, A., Pellitteri, G., Scalise, A., Surcinelli, A., Valente, M., 2021. Guillain-Barré syndrome in the COVID-19 era: just an occasional cluster? *J. Neurol.* 268, 1195–1197. <https://doi.org/10.1007/s00415-020-09911-3>.
- Hasan, I., Saif-Ur-Rahman, K.M., Hayat, S., Papri, N., Jahan, I., Azam, R., Ara, G., Islam, Z., 2020 Dec. Guillain-Barré syndrome associated with SARS-CoV-2 infection: a systematic review and individual participant data meta-analysis. *J. Peripher. Nerv. Syst.* 25 (4), 335–343.
- He, S., Tian, J., Li, X., Zhou, Y., Xiao, M., Zhang, Y., Min, X., Li, X., Jin, D., Zhang, Q., Zheng, Y., 2020. Positive RT-PCR test results in 420 patients recovered from COVID-19 in Wuhan: an observational study. *Front. Pharmacol.* 11 <https://doi.org/10.3389/fphar.2020.549117>.
- Huang, C., Wang, Y., Li, X., Ren, L., Zhao, J., Hu, Y., Zhang, L., Fan, G., Xu, J., Gu, X., Cheng, Z., 2020 Feb 15. Clinical features of patients infected with 2019 novel coronavirus in Wuhan, China. *Lancet.* 395 (10223), 497–506.
- Keddie, S., Pakpoor, J., Mousele, C., Phipps, M., Machado, P.M., Foster, M., Record, C.J., Keh, R.Y., Fehmi, J., Paterson, R.W., Bharambe, V., 2021 Feb. Epidemiological and cohort study finds no association between COVID-19 and Guillain-Barré syndrome. *Brain.* 144 (2), 682–693.
- Lan, L., Xu, D., Ye, G., Xia, C., Wang, S., Li, Y., Xu, H., 2020 Apr 21. Positive RT-PCR test results in patients recovered from COVID-19. *Jama.* 323 (15), 1502–1503.
- Mao, L., Jin, H., Wang, M., Hu, Y., Chen, S., He, Q., Chang, J., Hong, C., Zhou, Y., Wang, D., Miao, X., 2020 Jun 1. Neurologic manifestations of hospitalized patients with coronavirus disease 2019 in Wuhan, China. *JAMA Neurol.* 77 (6), 683–690.
- Nanda, S., Handa, R., Prasad, A., Anand, R., Zutshi, D., Dass, S.K., Bedi, P.K., Pahuja, A., Shah, P.K., Sharma, B., 2021 Jan 1. Covid-19 associated Guillain-Barre syndrome: contrasting tale of four patients from a tertiary care Centre in India. *Am. J. Emerg. Med.* 39, 125–128.
- Sidig, A., Abbasher, K., Digna, M.F., Elsayed, M., Abbasher, H., Abbasher, M., Hussien, A., 2020. COVID-19 and Guillain-Barre Syndrome-a Case Report. <https://doi.org/10.21203/rs.3.rs-48327/v1>.
- Uncini, A., Vallat, J.-M., Jacobs, B.C., 2020. Guillain-Barré syndrome in SARS-CoV-2 infection: an instant systematic review of the first six months of pandemic. *J. Neurol. Neurosurg. Psychiatry* 91 (10), 1105–1110.
- Wakerley, B.R., Yuki, N., 2013. Infectious and noninfectious triggers in Guillain-Barré syndrome. *Expert. Rev. Clin. Immunol.* 9 (7), 627–639.
- Yuki, N., Hartung, H.P., 2012 Jun 14. Guillain-Barré syndrome. *N. Engl. J. Med.* 366 (24), 2294–2304.