

Lateral Pectoralis Major Muscle Flap for Axillary Defect Obliteration

Chad K. Wheeler, MD*

Janelle D. Sousa, MD*

Stephanie R. Moline, MD†

Derek R. Fletcher, MD*

Emily A. Williams, MD*

Christopher J. Pannucci, MD, MS*

Summary: This article describes the use of a lateral pectoralis major muscle flap for preemptive obliteration of axillary defects in breast cancer patients having reconstructive surgery. The muscle flap is based on a consistent lateral branch of the pectoral component of the thoracoacromial system. The flap is useful to improve axillary contour after sentinel lymph node biopsy or axillary lymph node dissection, and to cover lymphovenous anastomoses. (*Plast Reconstr Surg Glob Open* 2020;8:e3221; doi: 10.1097/GOX.0000000000003221; Published online 24 November 2020.)

INTRODUCTION

Axillary hollowing is a multifactorial defect common amongst women who undergo mastectomy and breast reconstruction. Multiple factors contribute to this defect, including aggressive mastectomy, clavipectoral fascia violation with axillary lymph node removal, and post-operative radiation therapy.

This article reports the preventative use of a lateral pectoralis major muscle flap to provide axillary bulk after axillary lymph node removal with resultant defect. This preemptive muscle flap decreases the risk for axillary contour irregularity in breast reconstruction, and has plausible benefits to minimize the risk for lymphedema. The first author (CW) conceptualized this flap during routine use of split-pectoral breast augmentation, as described by Baxter.^{1,2} This technique splits the pectoralis major along the direction of its fibers, using the muscle originating on the sternum to provide superior pole implant coverage while leaving the muscle's costal origin intact. Through the muscle split, the lateral branch of the pectoral branch of the thoracoacromial vessels was consistently visualized on the deep muscle surface, before entering the lateral aspect of the pectoralis major muscle. Given the proximity to the axilla and the moderate length vascular pedicle, this muscle segment seemed ideally suited for pedicled transfer to an axillary defect.

TECHNIQUE

The mastectomy and lymph node removal are performed through an oncologically appropriate incision.

The axilla is then inspected, and the presence of an axillary defect that cannot be repaired through clavipectoral fascia repair alone is confirmed. The sternal and costal origins of the pectoralis major muscle are identified, and the muscle is split along the direction of its fibers at the junction of the sternal and costal origin. The lateral branch of the pectoral branch of the thoracoacromial vessels will reliably be found in the avascular plane deep to the muscle (Fig. 1). The branch location will vary by how medial the muscle split occurs, as well as individual anatomy, as shown by others.³⁻⁵ In our experience, the lateral branch typically crosses the muscle split at the junction of the superior and middle third of the lateral border of the pectoralis major.

Once the pedicle is identified, the muscle can be safely divided proximally and distally. Axillary division of the muscle should occur high under the pectoralis near the musculotendinous junction, as our experience shows that the residual muscle can scar to the superficial tissue, creating an axillary animation deformity. Costal origin division should occur at the length that provides adequate muscle bulk or length to reach/fill the defect. Retraction of the sternal pectoralis major muscle allows pedicle dissection to the main thoracoacromial trunk on the deep surface of the muscle to allow increased mobilization (Fig. 2). The muscle flap is then transposed into the axillary defect. Typically the costal portion is rotated 180 degrees into the defect's apex. A flap size of 18 × 5 cm can consistently be raised. Subsequently, the tissue expander can be inserted in the subpectoral plane, using the split muscle technique described by Baxter. Alternatively, the pre-pectoral plane can be utilized.

Representative pre- and post-operative photographs are shown in Figure 3. Note the absence of axillary hollowing despite a modified radical mastectomy and post-operative radiation.

From the *Plastic Surgery Northwest, Spokane, Wash.; and †Cancer Care Northwest, Spokane Valley, Wash.

Received for publication July 28, 2020; accepted September 8, 2020.

Copyright © 2020 The Authors. Published by Wolters Kluwer Health, Inc. on behalf of The American Society of Plastic Surgeons. This is an open-access article distributed under the terms of the Creative Commons Attribution-Non Commercial-No Derivatives License 4.0 (CCBY-NC-ND), where it is permissible to download and share the work provided it is properly cited. The work cannot be changed in any way or used commercially without permission from the journal.

DOI: 10.1097/GOX.0000000000003221

Disclosure: Dr. Pannucci receives direct research funds (no salary support) from Mentor for an unrelated study in breast implants and chest wall trauma. All the other authors report no financial disclosures.

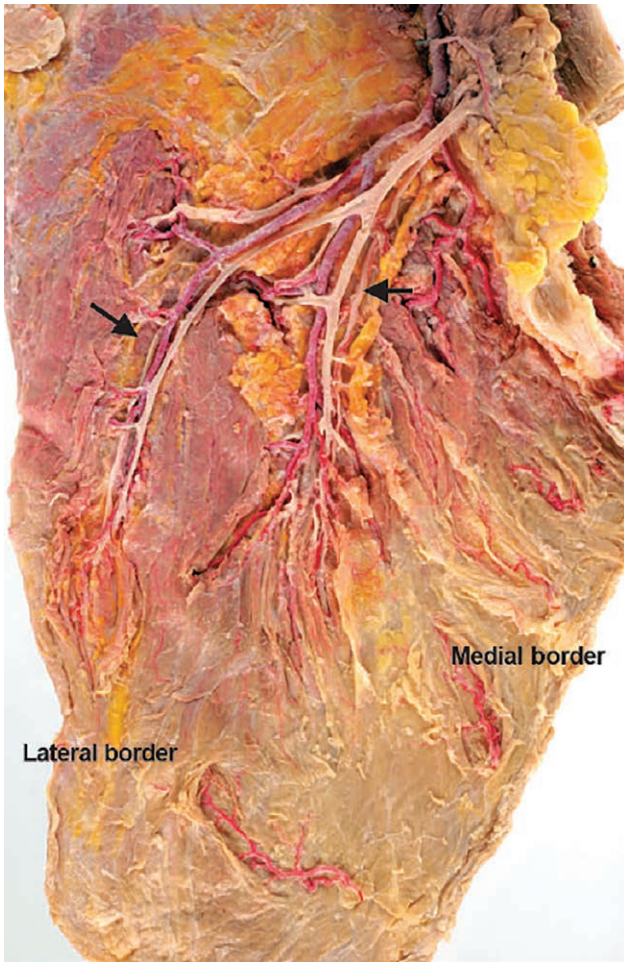


Fig. 1. Cadaveric dissection of lateral and medial portions of the pectoral branch of the thoracoacromial vessels. Reprinted with permission from Wolters Kluwer Health from *Plast Reconstr Surg.* 2005;115:77–83.

DISCUSSION

The first author (CW) has utilized this muscle flap to fill axillary defects in over 50 patients since 2017. The pedicle was present in 100% of patients, allowing reliable muscle flap elevation and transposition. We have also utilized this flap to cover axillary lymphovenous anastomoses after modified radical mastectomy, and believe the flap would be useful as a small, easily accessible muscle flap for free tissue transfer. In patients with established axillary contracture after radiation, a muscle flap out of the radiation field (such as the latissimus) would likely be a better and more reliable option.

The pectoralis major muscle is a Type V Mathes-Nahai (dual-dominant) flap. Similarly, the latissimus muscle (the “pectoralis muscle of the back”) has a consistent branching pattern that allows utilization of the lateral latissimus as a flap. Prior anatomic studies have noted differences in the origin location of the pectoral branch of the thoracoacromial vessels, as well as the submuscular branching course of this vessel.⁴ The medial portion of the muscle is preferentially supplied by internal mammary perforators and the lateral portion is preferentially

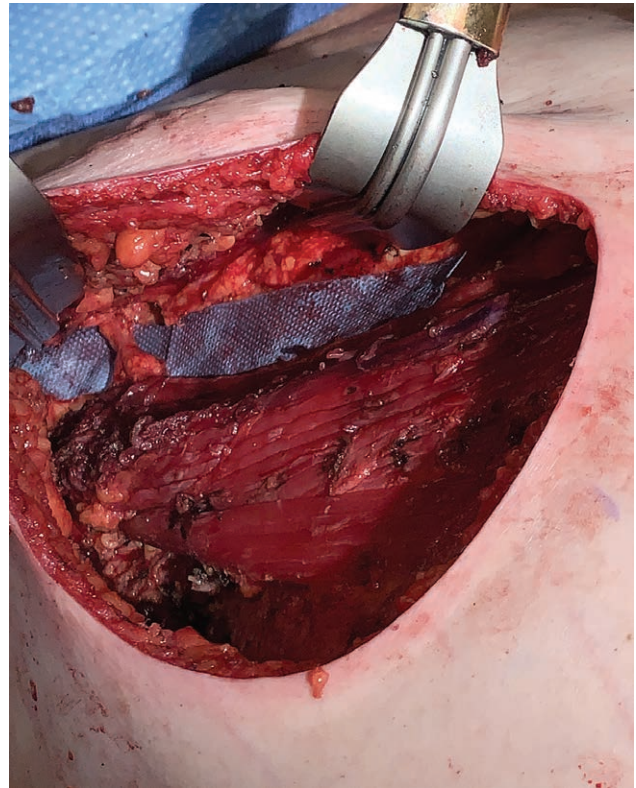


Fig. 2. Intra-operative image of right lateral pectoralis major flap dissection, showing split muscle with pedicle crossing on deep surface.

supplied by the pectoral branch of the thoracoacromial vessels.⁵ The pectoral branch reliably splits into 2 (73%) or 3 (27%) main branches on the deep surface of the pectoralis.³ For 80% of cadaver specimens, the artery branches were >1 mm in size at the level of the third rib.³ The vascular supply supplying the lateral portion of the pectoralis muscle has previously been described in anatomic studies^{4,5} and anatomic evaluations of the thoracoacromial system as microvascular free flap recipient vessels.³

We have utilized the lateral pectoralis major muscle flap to pre-emptively address axillary contour deficits from axillary tissue removal. However, tissue placement within the axilla has other proven benefits besides bulk. For post-mastectomy lymphedema, breast reconstruction has been associated with an overall decrease in the incidence, and a delayed presentation of lymphedema when compared with mastectomy alone.^{6,7} Interestingly, immediate autologous breast reconstruction has decreased rates of lymphedema,^{6–8} suggesting that pre-emptive placement of vascularized tissue in the axilla can be beneficial. The likely mechanism is decreased scar formation. However, some studies have hypothesized that healthy muscle tissue placed into the axilla can act as a “wick” for lymphedema fluid.⁹ Post-free muscle flap lymphoscintigraphy studies have shown that new lymphatic channels reliably drain the transferred muscle into regional proximal lymphatic system within 13–40 days after microsurgical transfer.¹⁰

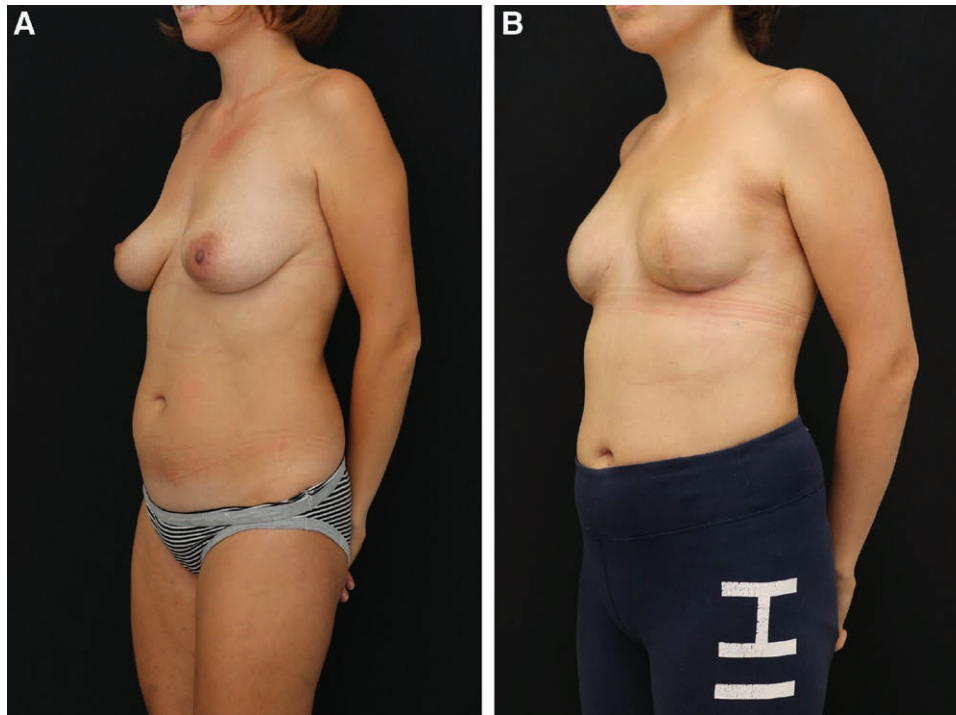


Fig. 3. Preoperative (A) and postoperative (B) photographs of a lateral pectoralis muscle flap patient. Note the absence of left axillary hollowing despite modified radical mastectomy and post-operative radiation.

CONCLUSIONS

The lateral pectoralis major muscle flap reliably allows vascularized tissue to be transposed into the axilla for coverage and bulk, and can be raised through standard mastectomy incisions. The flap is useful for pre-emptive obliteration of axillary dead space after sentinel lymph node removal to prevent contour irregularity, and to cover axillary lymphovenous anastomoses; this flap may similarly have applications for small muscle volume free tissue transfer.

Chad K. Wheeler, MD
 Plastic Surgery Northwest
 530 S. Cowley Street
 Spokane, WA 99201

E-mail: cwheeler@plasticsurgerynorthwest.com

REFERENCES

1. Baxter RA. Subfascial breast augmentation: theme and variations. *Aesthet Surg J.* 2005;25:447–453.
2. Baxter RA. Update on the split-muscle technique for breast augmentation: prevention and correction of animation distortion and double-bubble deformity. *Aesthetic Plast Surg.* 2011;35:426–429.
3. Kompatscher P, Manestar M, Schuster A, et al. The thoracoacromial vessels in microsurgery and supermicrosurgery: an anatomical and sonographic study. *Plast Reconstr Surg.* 2005;115:77–83.
4. Park HD, Min YS, Kwak HH, et al. Anatomical study concerning the origin and course of the pectoral branch of the thoracoacromial trunk for the pectoralis major flap. *Surg Radiol Anat.* 2004;26:428–432.
5. Yang D, Marshall G, Morris SF. Variability in the vascularity of the pectoralis major muscle. *J Otolaryngol.* 2003;32:12–15.
6. Card A, Crosby MA, Liu J, et al. Reduced incidence of breast cancer-related lymphedema following mastectomy and breast reconstruction versus mastectomy alone. *Plast Reconstr Surg.* 2012;130:1169–1178.
7. Lee KT, Bang SI, Pyon JK, et al. Method of breast reconstruction and the development of lymphoedema. *Br J Surg.* 2017;104:230–237.
8. Crosby MA, Card A, Liu J, et al. Immediate breast reconstruction and lymphedema incidence. *Plast Reconstr Surg.* 2012;129:789e–795e.
9. Medgyesi S. A successful operation for lymphoedema using a myocutaneous flap as a “wick”. *Br J Plast Surg.* 1983;36:64–66.
10. Slavin SA, Upton J, Kaplan WD, et al. An investigation of lymphatic function following free-tissue transfer. *Plast Reconstr Surg.* 1997;99:730–741; discussion 742–733.