

# Retinal vascular calibre and response to light exposure and serial imaging

Therese von Hanno,<sup>1,2</sup> Anne Katrin Sjølie<sup>1,3,†</sup> and Ellisiv B. Mathiesen<sup>1,4</sup>

<sup>1</sup>Brain and Circulation Research Group, Department of Clinical Medicine, Faculty of Health Sciences, University of Tromsø, Tromsø, Norway

<sup>2</sup>Department of Ophthalmology, Nordland Hospital, Bodø, Norway

<sup>3</sup>Department of Ophthalmology, Odense University Hospital, Odense, Denmark

<sup>4</sup>Department of Neurology and Neurophysiology, University Hospital of North Norway, Tromsø, Norway

## ABSTRACT.

**Purpose:** To investigate whether retinal vessel calibre measurements on optical retinal photography are affected by light and dark exposure prior to photography and whether the vessel calibre changes during an imaging sequence of several images.

**Methods:** Digital optical retinal photographs were obtained from 32 healthy adults in two separate image sequences of six images during 1 min; one sequence with 10 min of dark exposure and one with 10 min of light exposure prior to imaging. Retinal arteriolar and venular calibres were measured computer-assisted and summarized as central retinal artery and vein equivalents (CRAE and CRVE). Outcome measures were difference in calibres after prior light versus prior dark exposure and difference in calibre during each of the two imaging sequences.

**Results:** CRVE was wider with prior light exposure (2.7%,  $p = 0.0001$ ), comparing the first image in each image sequence. Within each sequence, there was a venular dilatation from first to last image, both with prior light exposure (1.7%,  $p = 0.0003$ ) and prior dark exposure (3.1%,  $p < 0.0001$ ), with the change less pronounced with prior light exposure ( $p = 0.0164$ ). CRAE showed no significant change in either outcome.

**Conclusions:** Retinal venular calibre was wider with light exposure prior to imaging and increased slightly during the imaging sequences, less pronounced after prior light than dark exposure. Measurement error due to these effects will probably be reduced by avoiding dark prior to imaging, and a possible bias effect of endothelial dysfunction may possibly be reduced by measuring calibre on an image taken early in the image sequence.

**Key words:** dark – imaging – light – retinal arterioles – retinal venules – vascular calibre

Acta Ophthalmol. 2014; 92: 444–448

© 2013 The Authors. Acta Ophthalmologica Scandinavica Foundation. Published by John Wiley & Sons Ltd. on behalf of Acta Ophthalmologica Scandinavica.

This is an open access article under the terms of the Creative Commons Attribution-NonCommercial License, which permits use, distribution and reproduction in any medium, provided the original work is properly cited and is not used for commercial purposes.

doi: 10.1111/aos.12213

<sup>†</sup>Deceased.

## Introduction

Dark is known to increase the metabolism in the outer retina (Stefánsson et al. 1983; Linsenmeier & Braun 1992; Wang et al. 1997; Birol et al. 2007). The blood supply for the photoreceptor layer is mainly the choroid but is to a small extent supplied by diffusion from the retinal arteries (Linsenmeier & Braun 1992). The retinal arteries are autoregulated and adapt to changes in systemic blood pressure and metabolic need in the tissue. Although the retinal photoreceptors are more metabolic active in dark than in light, the retinal hemodynamics related to dark and light remains unclear (Pournaras et al. 2008).

Volumetric flow depends on flow velocity and vascular calibre, and there have been conflicting results on how changing light conditions affect the retinal vascular calibre. In two early studies, aimed at flow measurements, dilatation of retinal vessels was found after dark adaptation (Feke et al. 1983; Riva et al. 1983). A later study with use of infrared illumination technique showed a faint retinal venular constriction in dark (Barcsay et al. 2003). Furthermore, flicker light stimulation induces increased venular and arteriolar diameter (Formaz et al. 1997; Nagel & Vilser 2004).

Retinal photography is suitable for clinical and epidemiological studies as the technique of image capturing is non-invasive and cameras are easily accessible and easy to use. The IVAN software measures vascular diameter

on retinal still images with high reproducibility and has been used in several epidemiological studies (Couper et al. 2002; Sherry et al. 2002; Bertelsen et al. 2012).

Light exposure prior to imaging may vary according to artificial and natural room illumination. Furthermore, cameras used for retinal photography commonly use light in the visual spectrum for the imaging technique and include several exposures to capture different fields of the retina. We wanted to investigate whether light exposure imposes an effect on retinal arteriolar and venular calibre with this imaging technique and thereby may be a source of error. Our primary question was whether different light conditions prior to photography were correlated with the diameter of the retinal vessels. Secondly, we wanted to investigate whether the calibres change during an imaging sequence of several images, which may possibly be related to flash illumination on image capturing.

## Methods

Thirty-two healthy persons participated in the study, 18 women and 14 men. Median age was 32.5 years (range 22–54 years). All participants gave written informed consent. The study was approved by the Regional Committee for Medical and Health Research Ethics and adhered to the tenets of the Declaration of Helsinki.

Retinal photographs were captured on one eye by FF450 plus IR Fundus Camera, model 1087-185 (Carl Zeiss Meditec, Jena, Germany), an optical device using light in the visible spectrum and flash illumination at capturing. Flash energy level was set to 32 Ws. Images were disc-centred 50 degrees retinal colour photographs with resolution 2196 × 1958. The pupil was dilated with one drop of Tropicamide 0.5% (Chauvin Pharmaceuticals Ltd. Kingston Upon Thames, Surrey, England). The dosage was repeated after 5 min. Intraocular pressure was measured with an Icare Tonometer (model TA01i; Helsinki, Finland) prior to dilatation. Blood pressure was measured with an automatic sphygmomanometer (ProBP 3400; Welch Allyn, Skaneateles, NY, USA) in sitting position after 10 min of rest.




Fig. 1. Schematic illustration of the study protocol.

The study protocol is presented schematically in Fig. 1. Prior to imaging, the fundus camera was prepared. To facilitate short delay before capturing of the first image after dark exposure, fluorescent markers were placed on chin and forehead for position according to markers on the camera device. An external red lead light for the other eye, placed out of sight of the examined eye, was positioned to have the image disc-centred. The camera was focused according to the user manual. Dark exposure was then achieved with the room darkened, eyes closed and head turned away from two monitors in the room. After 10 min, the head was positioned according to the markers on the face before the eyes were opened and the other eye fixating on the lead light. Camera light control was then turned on faintly allowing for a final adjustment if needed before the first image was captured. Time from light was turned on in the camera until the first image was captured was measured on 12 consecutive participants with the median of 6.3 seconds and range 2.9–10.8 seconds. A total of six images were captured approximately 10 seconds apart. Light exposure was then performed with participants positioned 30 cm in front of a daylight lamp (EnergyLight HF 3319, ultraviolet-free, Philips, Amsterdam, the Netherlands) and looking continuously at the centre, with light intensity adjusted to give 1000 Lux at this distance (DX-200 Digital Luxmeter; INS Enterprise Co., Taipei, Taiwan). After 10 min, six fundus images were captured approximately 10 seconds apart. The pupil size was measured immediately after both imaging sequences with aid of a pupil gauge with circular templates with diameter steps of 1 mm, range 2–9 mm.

Vessel calibre was measured computer-assisted with IVAN, the updated version of Retinal Analysis software (University of Wisconsin, Madison, WI, USA). All vessels with diameter more than 35–40 μm coursing through the area of one-half to one disc diameter from the optic disc margin were measured, and the six largest of each vessel type were summarized as the central retinal artery equivalent (CRAE) and the central retinal vein equivalent (CRVE) (Knudtson et al. 2003). Small vessels not automatically traced by the software were not manually traced. The protocol for grader interaction on the automated measures was in accordance with previously validated protocols (Hubbard et al. 1999) with minor modifications according to the Retinal Vascular Imaging Centre (RetVIC) (Centre for Eye Research Australia, University of Melbourne, Vic., Australia). The first author graded all images. Repeatability of the grading was assessed by regrading 60 random images and showed intraclass correlation coefficient (ICC) of 0.98 for CRAE and 0.99 for CRVE. Mean difference between first and second grading was  $-0.42$  (SD 3.15) μm for CRAE and  $-0.41$  (SD 2.57) μm for CRVE.

Image 1 and image 6 were graded in both sequences, that is, sequence after dark exposure and sequence after light exposure (Fig. 1). The four images from one participant were not graded in a row, and the grader was masked for information on capturing sequence number and light exposure prior to imaging.

To investigate for a possible effect of light conditions prior to imaging, we calculated the difference in calibre on image 1 after light versus dark exposure for each participant. To

investigate for a possible difference in calibre during each image sequence, we calculated the difference in calibre on image 6 versus image 1, with prior dark exposure and with prior light exposure for each participant. The overall arteriolar and venular calibre was calculated as the mean of the measurements on the graded four images of each participant. As we were interested in the change, we report all differences in percentages (%) of the overall arteriolar and venular calibre and not in the absolute value of the differences ( $\mu\text{m}$ ).

We used a sample double-sided *t*-test for the difference, testing against the null hypothesis of zero difference. We used a paired double-sided *t*-test to test whether the change in calibre during an image sequence of six images was different with prior dark exposure versus light exposure. All comparisons used a two-sided significance level of 5%. Shapiro–Wilk was used for test of normal distribution of the test variables. We had no certain

prior estimates of the variances in the response variables, the nearest was the study of Barcsay et al. (2003) with 11 participants and differences in venular calibre in dark versus light with the range of  $-5.4\%$  to  $3.8\%$ , suggesting a standard deviation of  $2.3\%$ , which indicated the need of at least 27 participants with level of significance of 0.05 and power 0.90 to test for a difference of  $1.5\%$  or more (Barcsay et al. 2003).

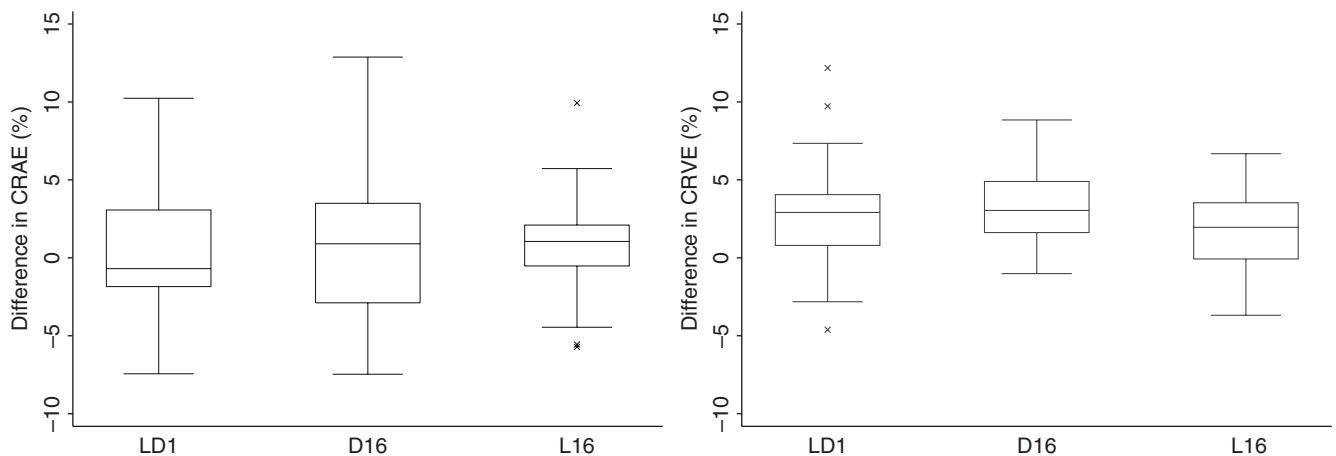
### Results

All participants had normal visual acuity. Mean intraocular pressure was  $16.3$  (SD  $3.1$ ) mmHg. The mean systolic blood pressure was  $118$  (SD  $12$ ) mmHg and mean diastolic blood pressure  $75$  (SD  $6.6$ ) mmHg, with an average mean arterial blood pressure of  $90$  (SD  $8.1$ ) mmHg. The mean retinal perfusion pressure ( $2/3$ \*mean arteriolar blood pressure – intraocular pressure) was  $46.6$  (SD  $6.8$ ) mmHg (Riva et al. 1986). The median pupil size

was  $8$  mm (range  $6$ – $9$  mm) in both imaging sequences. Three participants were present smokers. The mean overall calibre was  $153(14)\mu\text{m}$  for CRAE and  $226(14)\mu\text{m}$  for CRVE.

The distributions of the differences in calibre after light exposure versus dark exposure and during each image capturing sequence are presented in a box-and-whisker plot for CRAE and CRVE (Fig. 2). All differences were normally distributed, thus fulfilling model assumptions of the *t*-test.

The mean CRVE was significantly wider with light versus dark exposure prior to imaging ( $2.7\%$ ), and there was a significant increase in diameter during image capturing both after light exposure ( $1.7\%$ ) and dark exposure ( $3.1\%$ ) (Table 1). The change in calibre during image capturing was stronger with prior dark exposure compared with light exposure ( $p = 0.0164$ , paired *t*-test). There was no significant change in mean CRAE after prior light compared with prior dark exposure or during the image sequences (Table 1).



**Fig. 2.** Mean difference (%) in arterial calibre (CRAE) and venular calibre (CRVE) after light versus dark exposure prior to imaging (LD1) (measured on image 1 in each imaging sequence) and during imaging sequences from first (image 1) to last (image 6) in the after dark exposure (D16) and the after light exposure (L16) sequence. The central box covers the interquartile range, and the line indicates the median. The end of whiskers corresponds to the most extreme observation within  $1.5 \times$  interquartile range of the quartiles. X indicates outliers.

**Table 1.** Difference in retinal vessel calibre after prior dark and light exposure and change in calibre during image capturing (in percentages).

	Difference in calibre after prior light compared with prior dark exposure (LD1)			Difference in calibre during image sequence after prior dark exposure (D16)			Difference in calibre during image sequence after prior light exposure (L16)		
	Mean	SD [95% CI]	p-Value*	Mean	SD [95% CI]	p-Value*	Mean	SD [95% CI]	p-Value*
Arteriolar calibre (CRAE)	0.2	4.1 [–1.2 to 1.7]	0.75	0.8	4.6 [–0.9 to 2.4]	0.36	0.9	3.3 [–0.3 to 2.1]	0.13
Venular calibre (CRVE)	2.7	3.4 [1.5 to 4.0]	0.0001	3.1	2.4 [2.3 to 4.0]	<0.0001	1.7	2.4 [0.9 to 2.6]	0.0003

LD1, D16 and L16 as illustrated in Figure 1; SD, standard deviation; CI, confidence interval.

\* One sample double-sided *t*-test, testing against null hypothesis of zero difference.

## Discussion

Light exposure prior to imaging may vary according to artificial and natural room illumination. Commonly used retinal photography imaging techniques use light in the visual spectrum and involve multiple exposures to capture different fields of the retina.

We found that venular calibre was slightly smaller after dark exposure prior to imaging (2.8%) while there was no difference in arteriolar calibre. Our findings support the results of the only study where retinal vessel calibre was measured during dark adaptation, by use of a near-infrared illumination technique, and where the average venular constriction in dark was 1.5% (Barcsay et al. 2003). Contrary to our results are those from two small studies that measured retinal vascular calibre on fundus photographs; Feke et al. (1983) found an arterial dilatation of 2–3% (assessed in three subjects) and a venous dilatation of 6–8% (assessed in one subject) in dark, and Riva et al. (1983) found a venous dilatation of 5–8% (assessed in three subjects) in dark.

Volumetric flow is a function of flow rates and vascular capacity, where the latter is related to the square of the vascular calibre. We measured the calibre only and may not infer on how retinal volumetric blood flow is affected by light exposure. The inner retina is supplied by the retinal vessels, while the outer retina has a dual supply with diffusion from both the retinal and the choroidal circulation. Although the retinal photoreceptors are more metabolic active in dark than in light, it is not well understood how changing light conditions affect retinal blood flow (Stefánsson et al. 1983; Linzenmeier & Braun 1992; Wang et al. 1997; Birol et al. 2007; Pournaras et al. 2008). The literature is scarce and there have been apparently contradictory findings, which may partly be related to methodology. In such studies, the possibility of rapid changes in blood flow due to changes in light exposures is challenging. Light exposure following dark adaptation seems to induce a rapid transient increase in the retinal blood flow velocity, reaching peak value at 30–60 seconds (Riva et al. 2000). The study of Feke et al. (1983) and Riva et al. (1983) demonstrated increased flow velocity in dark, while Riva et al. (2000) could not reproduce this result

with infrared laser Doppler. As pointed out by the authors, the earlier results could have been affected by the effect of *change* of light as the former technique required light when measuring. Two other studies have demonstrated increased flow velocity in the central retinal artery in dark, using Doppler ultrasound (Havelius et al. 1999; Havelius & Hansen 2005). This technique is well suited for dark measurements, while light measurements were performed on closed eyes after light exposure. Further, the oxygen saturation in the retinal arterioles and venules has been demonstrated to be higher in dark than in light, while the physiological mechanisms behind this finding is not known (Hardarson et al. 2009).

Our study design involved use of an optical photography device that used light in the visible range, which limits our ability to conclude on retinal vascular calibre *during* dark, as our first image was taken after a few seconds of light exposure. But the method allows assessment of differences in calibre after standardized prior dark and prior light exposure. In our study, we put emphasis on shortening the time from full darkness to the first image was captured to avoid the transition described by Riva et al. (2000). We chose our levels of light exposure within clinical relevant ranges. Light intensity of 1000 Lux is easily achieved sitting by a window on an overcast day, while light intensity reaching the eye will be close to zero sitting in a fairly dark room with eyes closed. Our results indicate that changing light exposure prior to imaging may add to the variance in retinal vascular calibre measurements. In studies using a photography device with light in the visible range, we expect that standardizing light conditions prior to imaging, in an equal level as used in the camera to avoid light changes, would decrease the variance in the measurements. To determine this more clearly, there is need of further studies with exposures of several different levels of light prior to image capturing.

Secondly, we found that venular calibre increased during the imaging sequence. The effect was significantly stronger after prior dark exposure (3.0%) but was also present after prior light exposure (1.7%). In epidemiologic studies, smoking, obesity, unfavourable lipid profile and progression of diabetic retinopathy are

associated with increased venular calibre and may be related to endothelial dysfunction (Sun et al. 2009; Ding et al. 2012; von Hanno et al. 2013). We hypothesize that the response we observe, with increased venular calibre during a capturing sequence of six images, is related to background and flash illumination during imaging. This effect may at least in part be related to the phenomenon of increasing retinal vessel calibre during flicker light illumination (Formaz et al. 1997; Nagel & Vilser 2004). Several studies have demonstrated disturbed vascular reactivity in the retinal vessels in smokers and patients with diabetes, with decreased flicker light-induced retinal vasodilatation (Garhöfer et al. 2011; Lott et al. 2012). Further Nguyen et al. (2009) show that flicker-induced vasodilatation was negatively correlated with venular calibre in persons with diabetes while they were not correlated in persons without diabetes. The vascular reactivity may thus be different between groups, and this transition we observe during an imaging sequence may bias retinal vascular calibre measurements and reduce the differences between groups. We expect this bias to be reduced by taking images for retinal vascular calibre early in the capturing sequence, and we would at least advise to report image sequence number as this may add to explain differences in results between studies. To determine this relationship more clearly, there is need of further studies with measurements at different points of the capturing sequence and comparing different groups, for example smokers and persons with overweight, dyslipidaemia and diabetes.

The distribution of the investigated calibre differences was quite wide (Fig. 2). There is a pulse-related variation of arteriolar (3.5–4.3%) and venular (3.1–4.8%) calibre (Chen et al. 1994; Reshef 1999), and this accounts for part of the observed variation. This error is probably randomly distributed due to the cyclicity of the pulse, but the lack of pulse synchronization is a limitation of the study. Even after controlling for pulse cycle, grading of different images of the same subject has been shown to be the factor imposing most variance in calibre measurements, probably related to both biological changes and differences in



camera and eye position (Knutson et al. 2004). We cannot exclude systematic changes in blood pressure during examination as it was measured only once prior to imaging. Change in blood pressure could have affected the correlation between arteriolar calibre and light exposure/image sequence as retinal arteriolar calibre shows vasoconstriction with rising blood pressure (Blum et al. 1999). However, an effect on venular calibre is unlikely as venular blood flow rate and calibre have been found to be stable when acute changes of arteriolar blood pressure occur within the range of mean arteriolar blood pressure < 115 mmHg (Robinson et al. 1986).

An important strength of our study is that the grader was masked for information on light exposure and image sequence number, which is impossible with techniques using real-time measurements. Another strength is the use of computer-assisted grading methods with high reproducibility.

In conclusion, retinal venular calibre was slightly wider with light exposure prior to imaging. Venular calibre increased slightly during an imaging sequence of six images during one minute, both after prior light and dark exposure, although to a lesser degree after prior light exposure. Measurement error due to these effects will probably be reduced by avoiding dark prior to imaging, and a possible bias effect of endothelial dysfunction may possibly be reduced by taking images for retinal vascular calibre measurements early in the capturing sequence.

## Acknowledgements

The North Norway Regional Health Authority and the Norwegian Ophthalmological Society financially supported the study. No conflicting relationship exists for any of the authors.

## References

Barcsay G, Seres A & Németh J (2003): The diameters of the human retinal branch vessels do not change in darkness. *Invest Ophthalmol Vis Sci* **44**: 3115–3118.

Bertelsen G, Erke MG, von Hanno T, Mathiesen EB, Peto T, Sjølie AK & Njølstad I (2012): The Tromsø Eye Study: study design, methodology and results on visual acuity and

refractive errors. *Acta Ophthalmol* [Epub ahead of print].

Biról G, Wang S, Budzynski E, Wangsa-Wirawan ND & Linsenmeier RA (2007): Oxygen distribution and consumption in the macaque retina. *Am J Physiol Heart Circ Physiol* **293**: H1696–H1704.

Blum M, Bachmann K, Wintzer D, Riemer T, Vilser W & Strobel J (1999): Noninvasive measurement of the Bayliss effect in retinal autoregulation. *Graefes Arch Clin Exp Ophthalmol* **237**: 296–300.

Chen HC, Patel V, Wiek J, Rassam SM & Kohner EM (1994): Vessel diameter changes during the cardiac cycle. *Eye* **8**: 97–103.

Couper DJ, Klein R, Hubbard LD, Wong TY, Sorlie PD, Cooper LS, Brothers RJ & Nieto FJ (2002): Reliability of retinal photography in the assessment of retinal microvascular characteristics: the Atherosclerosis Risk in Communities Study. *Am J Ophthalmol* **133**: 78–88.

Ding J, Ikram MK, Cheung CY & Wong TY (2012): Retinal vascular calibre as a predictor of incidence and progression of diabetic retinopathy. *Clin Exp Optom* **95**: 290–296.

Feke GT, Zuckerman R, Green GJ & Weiter JJ (1983): Response of human retinal blood flow to light and dark. *Invest Ophthalmol Vis Sci* **24**: 136–141.

Formaz F, Riva CE & Geiser M (1997): Diffuse luminance flicker increases retinal vessel diameter in humans. *Curr Eye Res* **16**: 1252–1257.

Garhöfer G, Resch H, Sacu S, Weigert G, Schmidl D, Lasta M & Schmetterer L (2011): Effect of regular smoking on flicker induced retinal vasodilatation in healthy subjects. *Microvasc Res* **82**: 351–355.

von Hanno T, Bertelsen G, Sjølie AK & Mathiesen EB (2013): Retinal vascular calibres are significantly associated with cardiovascular risk factors: the Tromsø Eye Study. *Acta Ophthalmol* [Epub ahead of print].

Hardarson SH, Basit S, Jonsdottir TE et al. (2009): Oxygen saturation in human retinal vessels is higher in dark than in light. *Invest Ophthalmol Vis Sci* **50**: 2308–2311.

Havelius U & Hansen F (2005): Ocular vasodynamic changes in light and darkness in smokers. *Invest Ophthalmol Vis Sci* **46**: 1698–1705.

Havelius U, Hansen F, Hindfelt B & Krakau T (1999): Human ocular vasodynamic changes in light and darkness. *Invest Ophthalmol Vis Sci* **40**: 1850–1855.

Hubbard LD, Brothers RJ, King WN et al. (1999): Methods for evaluation of retinal microvascular abnormalities associated with hypertension/sclerosis in the Atherosclerosis Risk in Communities Study. *Ophthalmology* **106**: 2269–2280.

Knutson MD, Lee KE, Hubbard LD, Wong TY, Klein R & Klein BEK (2003): Revised formulas for summarizing retinal vessel diameters. *Curr Eye Res* **27**: 143–149.

Knutson MD, Klein BEK, Klein R, Wong TY, Hubbard LD, Lee KE, Meuer SM & Bulla CP (2004): Variation associated with measurement of retinal vessel diameters at different points in the pulse cycle. *Br J Ophthalmol* **88**: 57–61.

Linsenmeier RA & Braun RD (1992): Oxygen distribution and consumption in the cat retina during normoxia and hypoxemia. *J Gen Physiol* **99**: 177–197.

Lott ME, Slocomb JE, Shivkumar V, Smith B, Gabbay RA, Quillen D, Gardner TW & Bertermann K (2012): Comparison of retinal vasodilator and constrictor responses in type 2 diabetes. *Acta Ophthalmol* **90**: e434–e441.

Nagel E & Vilser W (2004): Flicker observation light induces diameter response in retinal arterioles: a clinical methodological study. *Br J Ophthalmol* **88**: 54–56.

Nguyen TT, Kawasaki R, Kreis AJ, Wang JJ, Shaw J, Vilser W & Wong TY (2009): Correlation of light-flicker-induced retinal vasodilation and retinal vascular caliber measurements in diabetes. *Invest Ophthalmol Vis Sci* **50**: 5609–5613.

Pournaras CJ, Rungger-Brändle E, Riva CE, Hardarson SH & Stefánsson E (2008): Regulation of retinal blood flow in health and disease. *Prog Retin Eye Res* **27**: 284–330.

Reshef DS (1999): Evaluation of generalized arteriolar narrowing expressed as central retinal artery/vein equivalents ratio (craver), using ECG synchronized retinal photography. PhD Thesis, Baltimore, Johns Hopkins University.

Riva CE, Grunwald JE & Petrig BL (1983): Reactivity of the human retinal circulation to darkness: a laser Doppler velocimetry study. *Invest Ophthalmol Vis Sci* **24**: 737–740.

Riva CE, Grunwald JE & Petrig BL (1986): Autoregulation of human retinal blood flow. An investigation with laser Doppler velocimetry. *Invest Ophthalmol Vis Sci* **27**: 1706–1712.

Riva CE, Logean E, Petrig BL & Falsini B (2000): Effet de l'adaptation à l'obscurité sur le flux rétinien. *Klin Monbl Augenheilkd* **216**: 309–310.

Robinson F, Riva CE, Grunwald JE, Petrig BL & Sinclair SH (1986): Retinal blood flow autoregulation in response to an acute increase in blood pressure. *Invest Ophthalmol Vis Sci* **27**: 722–726.

Sherry LM, Wang JJ, Rochtchina E, Wong T, Klein R, Hubbard L & Mitchell P (2002): Reliability of computer-assisted retinal vessel measurement in a population. *Clin Experiment Ophthalmol* **30**: 179–182.

Stefánsson E, Wolbarsht ML & Landers MB (1983): *In vivo* O<sub>2</sub> consumption in rhesus monkeys in light and dark. *Exp Eye Res* **37**: 251–256.

Sun C, Wang JJ, Mackey DA & Wong TY (2009): Retinal vascular caliber: systemic, environmental, and genetic associations. *Surv Ophthalmol* **54**: 74–95.

Wang L, Kondo M & Bill A (1997): Glucose metabolism in cat outer retina. Effects of light and hyperoxia. *Invest Ophthalmol Vis Sci* **38**: 48–55.

Received on October 14th, 2012.  
Accepted on May 14th, 2013.

### Correspondence:

Therese von Hanno, MD  
Department of Ophthalmology  
Nordland Hospital, Pb. 1480  
N-8092 Bodø, Norway  
Tel: + 47 755 78098  
Fax: + 47 755 34745  
Email: therese.von.hanno@uit.no