

Biocompatibility of orthodontic adhesives in rat subcutaneous tissue

Rogério Lacerda dos SANTOS¹, Matheus Melo PITHON¹, Alline Birra Nolasco FERNANDES², Márcia Grillo CABRAL³, Antônio Carlos de Oliveira RUELLAS⁴

1- DDS, MS, Specialist in Orthodontics, PhD student in Orthodontics, Federal University of Rio de Janeiro, Rio de Janeiro, RJ, Brazil.

2- Undergraduate Dental Student, Federal University of Rio de Janeiro, Rio de Janeiro, RJ, Brazil, Brazil.

3- DDS, MS, PhD, Adjunct Professor of Oral Pathology, Federal University of Rio de Janeiro, Rio de Janeiro, RJ, Brazil, Brazil.

4- DDS, MS, PhD, Adjunct Professor, Federal University, Federal University of Rio de Janeiro, Rio de Janeiro, RJ, Brazil, Brazil.

Corresponding address: Rogério Lacerda dos Santos - Rua Ipatinga, 170 - Planalto Divinópolis - MG - Brazil - 35501-191 - e-mail: lacerdaorto@hotmail.com or lacerdaorto@bol.com.br

Received: February 2, 2009 - Modification: September 5, 2009 - Accepted: February 16, 2010

ABSTRACT

Objective: The objective of the present study was to verify the hypothesis that no difference in biocompatibility exists between different orthodontic adhesives. **Material and Methods:** Thirty male Wistar rats were used in this study and divided into five groups (n=6): Group 1 (control, distilled water), Group 2 (Concise), Group 3 (Xeno III), Group 4 (Transbond XT), and Group 5 (Transbond plus Self-Etching Primer). Two cavities were performed in the subcutaneous dorsum of each animal to place a polyvinyl sponge soaked with 2 drops of the respective adhesive in each surgical loci. Two animals of each group were sacrificed after 7, 15, and 30 days, and their tissues were analyzed by using an optical microscope. **Results:** At day 7, Groups 3 (Transbond XT) and 4 (Xeno III) showed intense mono- and polymorphonuclear inflammatory infiltrate with no differences between them, whereas Groups 1 (control) and 2 (Concise) showed moderate mononuclear inflammatory infiltrate. At day 15, severe inflammation was observed in Group 3 (Transbond XT) compared to other groups. At day 30, the same group showed a more expressive mononuclear inflammatory infiltrate compared to other groups. **Conclusion:** Among the orthodontic adhesive analyzed, it may be concluded that Transbond XT exhibited the worst biocompatibility. However, one cannot interpret the specificity of the data generated *in vivo* animal models as a human response.

Key words: Orthodontic adhesives. Biocompatibility testing. Inflammation.

INTRODUCTION

Orthodontic adhesives are used to provide effective union between composite and dental structure. However, the most common substances present in adhesive systems show a well defined cytotoxic effect^{1,6,15}. These adhesives are used in moist media and often on contaminated surfaces without compromising their adhesion, but different compounds can be released during the aqueous phase¹¹, such as non-polymerized free monomers from resin materials⁵. Some authors have demonstrated that these free monomers caused apoptosis in cell culture^{16,26}. *In vivo* studies^{17,19} show that non-polymerized resin compounds released from dental adhesives cause a pulp inflammatory response, which is visible and chronic⁸. Recent studies^{4,5} have shown presence of macrophages together with resin compounds

following restorative procedure⁵, in which a persistent and chronic inflammatory response was observed over a period of 300 days. In general, the adhesives used in orthodontics are chosen based on the research on mechanical assays and effectiveness in sealing the interface between tooth and orthodontic accessory. However, many research studies on the biocompatibility of dental materials are currently being performed^{5,7,8,15,20}. Taken together, all these findings are in accordance with the idea that the close proximity of orthodontic accessories to gingival and oral tissues makes this issue very important when choosing these adhesives. Therefore, the aim of the present work was test the hypothesis that there is no difference in biocompatibility between the adhesives used for attaching orthodontic accessories.

MATERIAL AND METHODS

This study used 30 male adult Wistar rats weighing 250-350 g, which were divided into five groups of 6 animals each: Group 1 (control, distilled water), Group 2 (Concise, 3M Unitek Orthodontic Products, Monrovia, CA, USA), Group 3 (Xeno III, Dentsply/DeTrey, Konstanz, Baden-Württemberg, Germany), Group 4 (Transbond XT, 3M Unitek Orthodontic Products) and Group 5 (Transbond Self-Etching Primer, 3M Unitek Orthodontic Products) (Figure 1). The rats were anesthetized with intraperitoneal injection of sodium thiopental (50 mg/kg) (THIO, Cristália, Itapira, SP, Brazil), and the dorsal region (4x4 cm) of each animal was shaved. Asepsis of the operatory area was done with 4% chlorhexidine digluconate (School of Pharmacy, Federal University of Rio de Janeiro, Rio de Janeiro, RJ, Brazil). Two midline incisions of approximately 8 mm in length were made equidistantly from the tail base to the head of the animal with a #5 scalpel blade mounted onto a scalpel handle. The subcutaneous tissue was laterally separated using a pair of blunt-ended scissors, resulting in two approximately 18-mm-deep surgical loci each. All animals received two PVA sponge implants (4.0 mm long x 2.0 mm diameter). The implants were previously kept in 70% alcohol for 120 min, rinsed with sterile distilled water, autoclaved and then soaked with 2 drops of the respective adhesives. The adhesives in the sponges were photoactivated with a LED source unit (Radii, SDI, Baywater,

Victoria, Australia) according to the application time recommended by the manufacturer. The light intensity of the curing unit (1000 mW/cm²) was checked immediately before each polymerization using a radiometer (Model 100, Demetron Research Corporation, Danbury, CT, USA). The surgical loci were sutured with 4.0 suture (Ethicon, Johnson & Johnson, São José dos Campos, São Paulo, Brazil) and then the animals received an injection of sodium dipyrone (0.3 mL/100 g Novalgina®; Sanofi-Aventis Farmacêutica LTDA, Suzano, SP, Brazil).

The rats were kept in cages and fed balanced food and water. After 7, 15, and 30 days, the animals were anesthetized and submitted to excisional biopsy at the implantation area so that enough surrounding normal tissue could be collected. Each group consisted of 6 rats with two implants, thus resulting in 12 samples per group (Table 1). Next, the animals were sacrificed by cervical dislocation.

After being fixed in 4% formaldehyde (Milony solution) for 24 h, the samples were inserted into paraffin and then 6- μ m-thick histological sections were cut and stained with hematoxylin and eosin. The inflammatory responses induced by the adhesives were examined with a light microscope and classified as mild, moderate, and severe^{17,19}. The biocompatibility of the materials was determined according to the ISO 10993-313 standard.

Groups	Adhesive Primer	Composition	Manufacture
Concise	Concise® Orthodontic Adhesive	Resin A: Bis-glycidyl-methacrylate (Bis-GMA), triethylene-glycol-dimethacrylate (TEGDMA); Resin B: Bis-glycidyl-methacrylate (Bis-GMA), triethylene-glycol-dimethacrylate (TEGDMA) and benzoin peroxide.	3M Unitek, Monrovia, CA, USA
Xeno III	Xeno® III Single Step Self Etching Dental Adhesive	Fluid A: 2-hydroxyethyl methacrylate (HEMA), Purified water, Ethanol, Toluene hydroxybutylate (THB), Amorphous silica. Fluid B: Phosphoric acid modified methacrylate (Piro-EMA), Phosphazene mono-fluoride (PEM-F), Urethane dimethacrylate, Toluene hydroxybutylate (THB), camphoroquinone, Ethyl-4-dimethylaminobenzoate.	Dentsply DeTrey, Konstanz, Baden-Wurttember, Germany
Transbond	Transbond® XT Primer	Bisphenol-a diglycidyl ether dimethacrylate, Triethylene glycol dimethacrylate (TEGDMA).	3M Unitek, Monrovia, CA, USA
TP Sep	Transbond® Adhesive Plus Self Etching Primer (SEP)	Mono and di-HEMA phosphates, camphoroquinone, distilled water, aminobenzoate, potassium hexafluoride titanate, Butylhydroxytoluene, methylparaben, and propylparaben	3M Unitek, Monrovia, CA, USA

Figure 1- Composition of the tested adhesive primers

Table 1- Distribution of the groups according to type of adhesive system and sacrifice day

Days	Control		Concise		Xeno III		Transbond XT		Transbond Plus SEP	
	Rats	Samples	Rats	Samples	Rats	Samples	Rats	Samples	Rats	Samples
7 days	2	4	2	4	2	4	2	4	2	4
15 days	2	4	2	4	2	4	2	4	2	4
30 days	2	4	2	4	2	4	2	4	2	4
Total	6	12	6	12	6	12	6	12	6	12

SEP: Self-Etching Primer

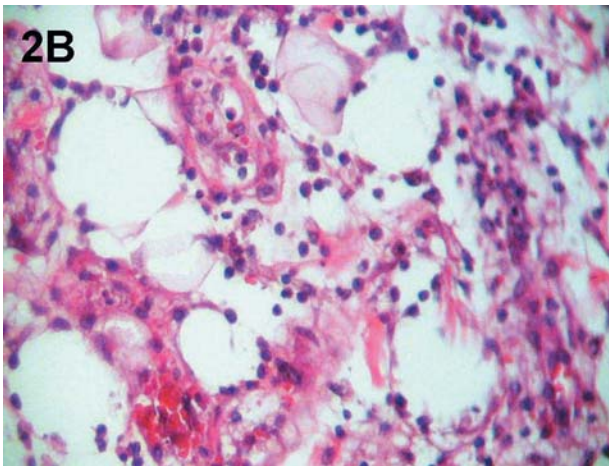
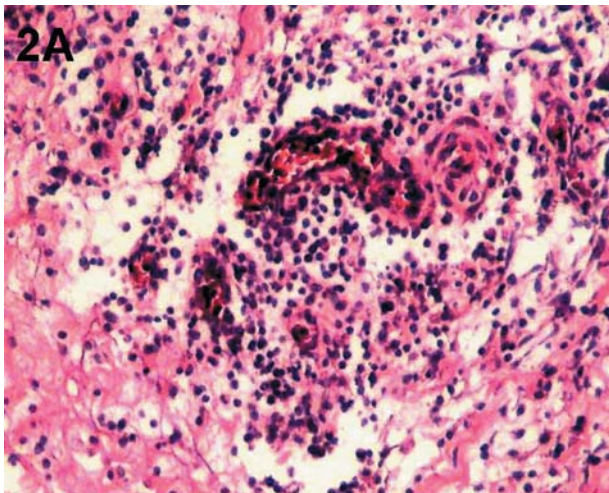


Figure 2- Photomicrographs of histological samples after 7 days of implantation. A: evidence of acute inflammatory infiltrate with predominance of polymorphonuclear cells (1,000x magnification; scale: 100 μ m). B: presence of granulation tissue (1,000x magnification; scale: 100 μ m)

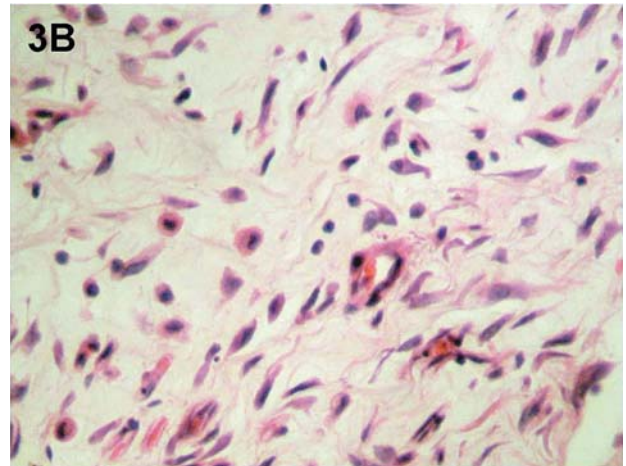
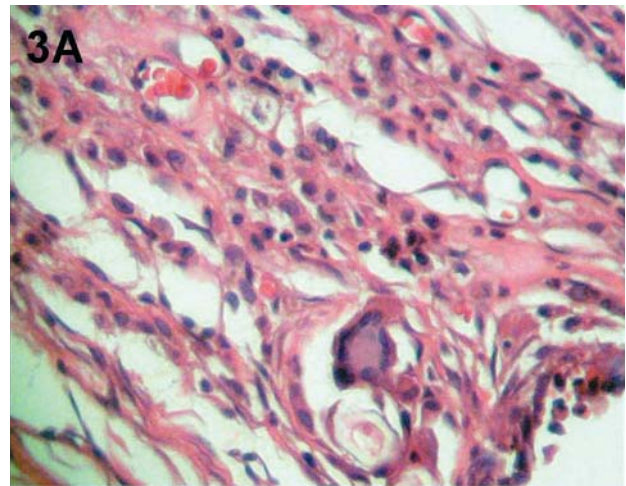


Figure 3- Photomicrographs of histological samples after 15 days of implantation. A: formation of granulomas with multinuclear giant cells (1,000x magnification; scale: 100 μ m). B: areas of intense cell formation and deposition of collagen fibers (1,000x magnification; scale: 100 μ m).

RESULTS

Mono and polymorphonuclear inflammatory infiltrates were observed together with blood vessels and circulatory changes (dilatation and edema) around and within the cavity as a result of the material implantation in all four groups of adhesive systems (Figure 2AB). Groups 3 (Xeno

III) and 4 (Transbond XT) showed the most significant acute inflammatory response. In the control group, a mild inflammatory process was observed due to the presence of sponge. In Group 2 (Concise), there was formation of granuloma and presence of multinuclear giant cells (Figure 2AB),

Table 2- Mean values for the biopsy results regarding the samples studied during the 3 periods of time (7, 15, and 30 days after implantation)

7 days	Leakage PMN	Leakage MN	Edema	Hyperemia Congestion	Granulomas	Granulation Tissue	Fibrosis
Control	+	++	++	++	+	+	-
Concise	+	++	++	++	+	++	-
Xeno III	++	++	++	++	-	+	-
Transbond	++	++	++	++	-	++	-
TP SEP	+	++	+	++	-	++	-
15 days							
Control	+	++	++	++	+	++	+
Concise	+	++	+	++	-	++	+
Xeno III	+	++	++	++	++	++	+
Transbond	+++	++	++	++	-	++	+
TP SEP	+	++	++	++	+	++	+
30 days							
Control	-	-	-	+	-	+	+
Concise	-	+	-	++	-	+	+
Xeno III	-	+	-	+	-	+	+
Transbond	-	++	-	+	-	+	+
TP SEP	-	+	-	+	-	+	+

SEP: Self-Etching Primer

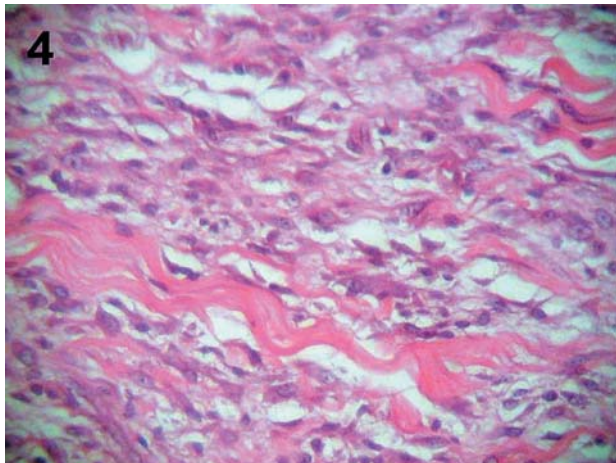


Figure 4- Photomicrographs of histological samples after 30 days of implantation: one can observe deposition of collagen fibers, thus indicating an ongoing repair process (1,000x magnification; scale: 100 µm)

which indicates the beginning of a repair process (Table 2).

At the end of the 15-day period, it was observed a decrease in the inflammatory response intensity for all adhesive systems compared to that at day 7, except for Transbond XT (Figure 3A-B), which showed presence of neutrophils and abscess formation at the region where the material was implanted, thus indicating a very toxic effect on

the tissue. Presence of granuloma and multinuclear giant cells were observed in Groups 3 (Xeno III) and 5 (Transbond SEP) as well as in the Control Group (Figure 3A-B) (Table 2).

After 30 days, the Control Group and all four experimental groups showed chronic inflammatory process characterized by discrete mononuclear infiltrate, discrete vascular alterations, and formation of granuloma with multinuclear giant cells and fibrous tissue formation around the samples (Figure 4). Presence of granulation tissue around the sponges and cell proliferation with deposition of collagen fibers correspond to the repair process and fibrosis, respectively. Therefore, all adhesives were shown to be biocompatible on long-term basis (Table 2).

DISCUSSION

The quality and specificity of the data generated by *in vivo* models is questioned and criticized in literature³⁰, depends of use of a biological system that reproduces as close as possible the metabolic behavior of the target organ for the toxic effect of xenobiotics and of choice of appropriate parameters to evaluate toxic effects. Evaluating the biocompatibility of orthodontic adhesives by means of subcutaneous implants in rats is of great value as the tissue response in rats is similar to that expected when the same material is applied to

the gingival tissue surrounding the area to receive orthodontic accessories.

Several studies have assessed the biocompatibility of dental materials^{5,7,8,15,20}. However, methodological divergence exists. In the present study, polyvinyl sponges saturated with the respective adhesives were inserted into rats subcutaneous tissue and then light cured¹⁷ in an attempt to simulate actual clinical procedures.

Costa, et al.⁶ (1999) have used polyvinyl sponges saturated with adhesives that had not been photoactivated after surgical implantation, allowing the adhesive and their monomers to be in close contact with the subcutaneous connective tissue. Therefore, not only a cytotoxic effect of the dental adhesive was observed but also a persistent inflammatory reaction resulting from the resin compounds. According to the authors, these materials do not seem to be suitable for direct application to connective tissue.

Studies^{15,21,29} have demonstrated the cytotoxicity of the compounds of adhesive systems, which can be explained by the different compositions, mechanisms, and application procedures as well as by methodological variations¹. However, it is clear that the choice for a given adhesive system should be based on its biocompatibility.

The most often studied method for *in vivo* analysis of biocompatibility relies on inflammation¹⁷. Analyzing and rating the inflammation phenomena in different experimental groups makes it possible to establish the best biocompatibility by placing the material in contact with vascularized tissues and observing the different reactions. It is also important to use an innocuous substance in the control group in order to facilitate data interpretation¹⁷.

The inflammatory response begins with a more intense reaction to both surgical procedures and implanted foreign body, and because such a reaction is not specific, the first post-surgical hours are not taken into account. After 7 days, a more organized inflammatory reaction was expected due to the adhesive rather than the surgical procedure.

The decrease in the inflammatory intensity relies on the control of the host defense system, which organizes itself to limit the aggressive action from the compounds existing in the adhesives and to localize the inflammatory reaction. It was possible to differentiate the inflammation intensity between the experimental groups, mainly regarding the higher level of cytotoxic from Xeno III and Transbond XT after 7 days.

Methacrylate monomers such as TEGDMA, Bis-GMA, UDMA, and HEMA, which are largely used in the composition of dentinal adhesives, can cause cell lesion^{10,12}. TEGDMA, Bis-GMA, UDMA are hydrophobic monomers that are often associated with HEMA. Diffusion of these monomers can be facilitated because HEMA increases the hydrophilic characteristic of the material. Under such conditions, the hydrophobic monomers can reach

the cells and damage them^{10,12,23}.

With respect to Xeno III, the presence of HEMA in association with ethanol seems to cause more cell damage. The ethanol in relation with the oral mucosa showed increased mucosal permeability^{13,24} and penetration of potential carcinogens across the mucosal permeability barrier¹³. It has been reported that topical application of ethanol on the oral mucosa affects epithelial cell homeostasis² and alters mucosal structure¹⁸.

In the present study, a mild reaction was observed in the control group whose sponges were saturated with distilled water, whereas a moderate to severe reaction was found in all experimental groups. After 15 and 30 days, the inflammatory reaction was visible, thus allowing the biocompatibility of the materials to be rated in ascending order. In general, small necrotic areas with edema surrounded by cell proliferation, consequent deposition of collagen fibers, chronic inflammation, and decreased number of blood vessels were observed. The presence of multinuclear giant cells suggests the formation of granulomas due to the presence of sponge and/or adhesive material. Therefore, these events are described as a favorable tissue response regarding the biocompatibility of the material.

At the end of the 30-day period, it was possible to observe that all adhesive systems showed good biocompatibility, although Transbond XT was found to be more aggressive compared to other groups as formation of abscess occurred at the implant region. Based on this finding, one can conclude that Transbond XT is the least biocompatible adhesive.

According to in the literature, HEMA is an important toxic component released by most adhesive systems since several *in vitro* studies have demonstrated a defined cytotoxicity of HEMA to the culture of cells^{3,25}. Methacrylate monomers, such as HEMA, are incorporated in the lipid bilayers of cell membranes which are solubilized by the unreacted monomers¹⁰. This mechanism of action of uncured leached monomers on the cell membrane may be regarded as responsible for the high cytotoxicity of Transbond (Transbond XT, 3M Unitek) observed in the present investigation.

Traditionally, persulfate molecules have been used as initiators in redox water-based polymerization systems to decrease the amount of residual monomers after setting¹⁴. The high cytotoxicity of adhesive systems is probably caused by leachable resin components, such as TEGDMA, Bis-GMA and HEMA, which has frequently been added to their chemical composition⁹.

However, it may be speculated that some minor adhesive components released into the connective tissue, such as HEMA, which presents low molecular weight, might be removed by local lymphatic drainage. This hypothesis should explain why the inflammatory reaction decreased with time and the connective tissue healing occurred for

all experimental materials at 30 days following the implantation.

Sohoel, et al.²² (1994), after testing adhesives in pigs, have suggested that orthodontic adhesives can be potentially allergenic for human being, particularly the "no-mix" ones, and lead to adverse reactions in both patients and practitioners. Such cytotoxicity can last two years after polymerisation²⁷.

Thompson, et al.²⁸ (1982) have concluded that even adequately mixed and set, the orthodontic adhesives showed great amounts of material that not had been cured (up to 14% of the material), thus resulting in potential toxicity. Therefore, in addition to adequately preparing and applying these products, the clinician should be careful not to expose skin, mucosa, and gingival to these materials for long periods of time, particularly the subgingival and interproximal areas.

CONCLUSIONS

It is possible (and safer) to evaluate inflammatory and healing phenomena to characterize, and rate the experimental groups by comparing them to a control group. This allows us to state that Xeno III, Transbond SEP, and Concise adhesives had the best biocompatibility, since formation of chronic inflammation with peripheral healing phenomena and multinuclear giant cells around the samples were observed. However, one cannot interpret the specificity of the data generated *in vivo* animal models as a human response. The hypothesis was rejected and one can state that, among the adhesives studied, Transbond XT was found to have the worst biocompatibility.

REFERENCES

- 1- al-Dawood A, Wennberg A. Biocompatibility of dentin bonding agents. *Endod Dent Traumatol*. 1993;9(1):1-7.
- 2- Axford SE, Ogden GR, Stewart AM, Saleh HA, Ross PE, Hopwood D. Fluid phase endocytosis within buccal mucosal cells of alcohol misusers. *Oral Oncol*. 1999;35(1):86-92.
- 3- Bouillaguet S, Wataha JC, Hanks CT, Ciucchi B, Holz J. *In vitro* cytotoxicity and dentin permeability of HEMA. *J Endod*. 1996;22(5):244-8.
- 4- Costa CA, Giro EM, Nascimento AB, Teixeira HM, Hebling J. Short-term evaluation of the pulpo-dentin complex response to a resin-modified glass-ionomer cement and a bonding agent applied in deep cavities. *Dent Mater*. 2003;19(8):739-46.
- 5- Costa CA, Hebling J, Hanks CT. Current status of pulp capping with dentin adhesive systems: a review. *Dent Mater*. 2000;16(3):188-97.
- 6- Costa CA, Teixeira HM, Nascimento AB, Hebling J. Biocompatibility of an adhesive system and 2-hydroxyethylmethacrylate. *ASDC J Dent Child*. 1999;66(5):337-42.
- 7- Cox CF, Kim KM, Stevenson RG 3rd, Hafez AA. Histological evaluation of a self-priming etchant adhesive system. *Compend Contin Educ Dent*. 2003;24(8):17-20.
- 8- Souza Costa CA, Nascimento AB, Teixeira HM. Response of human pulps following acid conditioning and application of a bonding agent in deep cavities. *Dent Mater*. 2002;18(7):543-51.
- 9- Souza Costa CA, Hebling J, Garcia-Godoy F, Hanks CT. *In vitro* cytotoxicity of five glass-ionomer cements. *Biomaterials*. 2003;24(21):3853-8.
- 10- Fujisawa S, Kadoma Y, Komoda Y. ¹H and ¹³C NMR studies of the interaction of eugenol, phenol, and triethyleneglycol dimethacrylate with phospholipid liposomes as a model system for odontoblast membranes. *J Dent Res*. 1988;67(11):1438-41.
- 11- Geurtsen W, Spahl W, Muller K, Leyhausen G. Aqueous extracts from dentin adhesives contain cytotoxic chemicals. *J Biomed Mater Res*. 1999;48(16):772-7.
- 12- Hanks CT, Wataha JC, Sun Z. *In vitro* models of biocompatibility: a review. *Dent Mater*. 1996;12(3):186-93.
- 13- Howie NM, Trigkas TK, Cruchley AT, Wertz PW, Squier CA, Williams DM. Short-term exposure to alcohol increases the permeability of human oral mucosa. *Oral Dis*. 2001;7(6):349-54.
- 14- Kakaboura A, Eliades G, Palaghias G. An FTIR study on the setting mechanism of resin-modified glass ionomer restoratives. *Dent Mater*. 1996;12(3):173-8.
- 15- Kostoryz EL, Eick JD, Glaros AG, Judy BM, Welshons WV, Burmaster S, et al. Biocompatibility of hydroxylated metabolites of BISGMA and BFDGE. *J Dent Res*. 2003;82(5):367-71.
- 16- Lefeuvre M, Amjaad W, Goldberg M, Stanislawski L. TEGDMA induces mitochondrial damage and oxidative stress in human gingival fibroblasts. *Biomaterials*. 2005;26(25):5130-7.
- 17- Machado NP, Moysés MR, Pereira AAC, Pereira LJ, Ribeiro JCR, Dias SC. Study of dentinal adhesives compatibility using histological analysis. *Braz J Oral Sci*. 2007;6(20):1289-94.
- 18- Maier H, Tisch M. Epidemiology of laryngeal cancer: results of the Heidelberg case-control study. *Acta Otolaryngol Suppl*. 1997;527:160-4.
- 19- Moyses MR, Lopes WL, Pereira AAC, Ribeiro JCR, Dias SC, Pereira LJ. Biocompatibility of the Prime & Bond 2.1, Prime & Bond NT and Scotchbond MP Primer adhesive systems. *Braz J Oral Sci*. 2006;5(18):1079-84.
- 20- Mussel RL, Sa Silva E, Costa AM, Mandarim-De-Lacerda CA. Mast cells in tissue response to dentistry materials: an adhesive resin, a calcium hydroxide and a glass ionomer cement. *J Cell Mol Med*. 2003;7(2):171-8.
- 21- Nagem-Filho H, Monteiro CR, Nagem HD, Lage-Marques JL. Effect of dental adhesives on the exudative phase of the inflammatory process in subcutaneous tissue of rats. *Pesqui Odontol Bras*. 2003;17(2):109-12.
- 22- Sohoel H, Gjerdet NR, Hensten-Pettersen A, Ruyter IE. Allergic potential of two orthodontic bonding materials. *Scand J Dent Res*. 1994;102(2):126-9.
- 23- Souza PP, Aranha AM, Hebling J, Giro EM, Costa CA. *In vitro* cytotoxicity and *in vivo* biocompatibility of contemporary resin-modified glass-ionomer cements. *Dent Mater*. 2006;22(9):838-44.
- 24- Squier CA, Cox P, Hall BK. Enhanced penetration of nitrosornicotine across oral mucosa in the presence of ethanol. *J Oral Pathol*. 1986;15(5):276-9.
- 25- Stanislawski L, Daniau X, Lauti A, Goldberg M. Factors responsible for pulp cell cytotoxicity induced by resin-modified glass ionomer cements. *J Biomed Mater Res*. 1999;48(3):277-88.
- 26- Stanislawski L, Lefeuvre M, Bourd K, Soheili-Majd E, Goldberg M, Perianin A. TEGDMA-induced toxicity in human fibroblasts is associated with early and drastic glutathione depletion with subsequent production of oxygen reactive species. *J Biomed Mater Res A*. 2003;66(3):476-82.
- 27- Tell RT, Sydiskis RJ, Isaacs RD, Davidson WM. Long-term cytotoxicity of orthodontic direct-bonding adhesives. *Am J Orthod Dentofacial Orthop*. 1988;93(5):419-22.
- 28- Thompson LR, Miller EG, Bowles WH. Leaching of unpolymerized materials from orthodontic bonding resin. *J Dent Res*. 1982;61(8):989-92.
- 29- Vajrabhaya LO, Pasasuk A, Harnirattaisai C. Cytotoxicity evaluation of single component dentin bonding agents. *Oper Dent*. 2003;28(4):440-4.
- 30- Vande Vannet BM, Hanssens JL. Cytotoxicity of two bonding adhesives assessed by three-dimensional cell culture. *Angle Orthod*. 2007;77(4):716-22.