

Contents lists available at [ScienceDirect](http://www.sciencedirect.com)

## International Journal of Surgery Case Reports

journal homepage: [www.casereports.com](http://www.casereports.com)

# Chondroblastic osteosarcoma of breast in a case of phyllodes tumour with recurrence, a rare case report



Sourav Sarkar (MS), Neeti Kapur (MS)\*, Hareesh M. Mukri (MS),  
Amritanshu Saurabh (MS), Naveen Kumar (MS)

Department of General Surgery, PGIMER & Dr. Ram Manohar Lohia Hospital, New Delhi, India

## ARTICLE INFO

## Article history:

Received 22 July 2016

Received in revised form 20 August 2016

Accepted 23 August 2016

Available online 4 September 2016

## Keywords:

Chondroblastic osteosarcoma of breast

Chondrosarcomatous differentiation

Myocutaneous flap

Adjuvant chemotherapy

Malignant phyllodes

## ABSTRACT

**INTRODUCTION:** Primary extra osseous osteogenic sarcomas have been reported in many tissues of the body but their occurrence in the breast is extremely rare. It can arise as a result of osseous metaplasia in a pre-existing benign or malignant neoplasm of the breast.

**CASE PRESENTATION:** A 24 year-old young lady was diagnosed to have mass in right breast. True cut biopsy showed it was malignant phyllodes tumour. There was no distant metastasis or any axillary lymph nodes palpable. Simple mastectomy was done. The histology report of biopsy showed a malignant phyllodes with chondrosarcomatous differentiation and myxoid changes. She was given 6 cycles of chemotherapy.

There was recurrence after 6 months of surgery. Then radical mastectomy with latissimus dorsi musculocutaneous flap was used to cover the anterior chest wall defect. Sections from the mastectomy specimen confirmed the diagnosis of chondroblastic osteosarcoma. Axillary nodes free of tumour cells.

Now the patient again came with recurrence after 5 months, and disseminate subcutaneous nodules. **CONCLUSION:** A diagnosis of chondroblastic osteosarcoma of the breast was made based on histology report and after excluding any osteogenic sarcoma arising from underlying ribs and sternum. It is a very rare disease with only few case reports in literature.

© 2016 The Authors. Published by Elsevier Ltd on behalf of IJS Publishing Group Ltd. This is an open access article under the CC BY-NC-ND license (<http://creativecommons.org/licenses/by-nc-nd/4.0/>).

## 1. Introduction

Extra skeletal osteosarcomas are uncommon neoplasms representing less than 1% of soft tissue sarcomas. Mammary sarcomas are rarer, accounting for less than 1% of all primary breast malignant tumours. In this group, primary osteosarcomas are one of the least common sarcomas of the breast [1,2]. Most cases have been reported in the literature as case reports except Silver et al. who reported a retrospective analysis of 50 cases [3]. With less than a hundred cases of primary mammary osteosarcoma reported in the literature [4,5].

Extra-skeletal osteosarcoma has been documented in many tissues of the body including the thyroid gland, kidney, bladder, colon, heart, testis, penis, gall bladder and the cerebellum. When it occurs in the breast, it originates either from normal breast tissue *de novo*, or as metaplastic differentiation of a primary benign or malignant breast lesion. Osteogenic sarcomas of the breast either arising primarily in the breast or as secondary deposits from primary bone sarcomas occur in very rare cases [6].

## 2. Case report

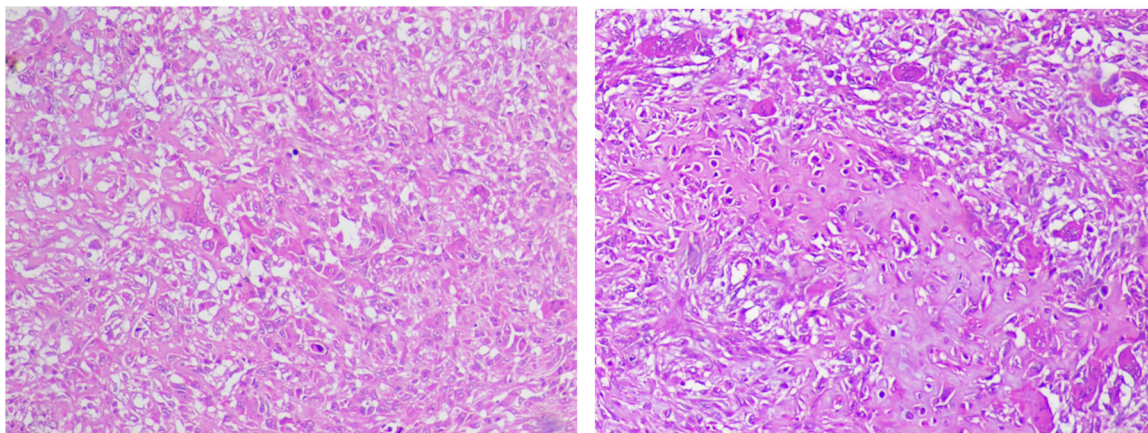
A 24 year-old young lady came to Surgery OPD in PGIMER & Dr. RML Hospital, New Delhi with a 5\*4 cm lump in right breast from 3 months (Figs. 4 and 5). TRU cut biopsy showed it was malignant phyllodes tumour. There was no distant metastasis or any axillary lymph nodes palpable. Simple mastectomy was done and the specimen was sent for histopathological examination.

The histology report of showed a malignant phyllodes with chondrosarcomatous differentiation there were malignant spindle cells and osteoclasts like multi-nucleated tumour giant cells. Cartilaginous differentiation with osteoid production were also seen (Figs. 1–3). Resected margins were tumour free. IHC showed vimentin positive in sarcomatous areas and CD 10 positive in spindle cells. She was given 6 cycles of chemotherapy with Doxorubicin, Ifosfamide and mesna by the oncology department.

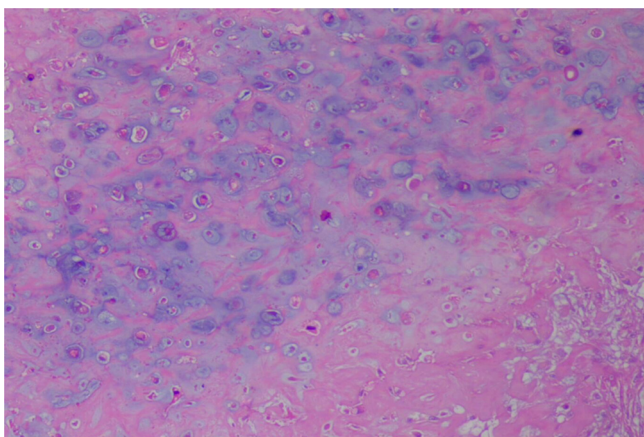
There was recurrence at the site of surgery after 6 months of surgery, while she was on chemotherapy. Then radical mastectomy with latissimus dorsi musculocutaneous flap was used to cover the anterior chest wall defect. Sections from the mastectomy specimen confirmed the diagnosis of chondroblastic osteosarcoma with spindle cells with marked nuclear pleomorphism, many tumour giant cells, osteoid productions and focal chondroblastic differentiation as in (Figs. 1–3). Axillary nodes were free of tumour cells.

\* Corresponding authors at: PGIMER & Dr Ram Manohar Lohia Hospital, New Delhi 110001, India.

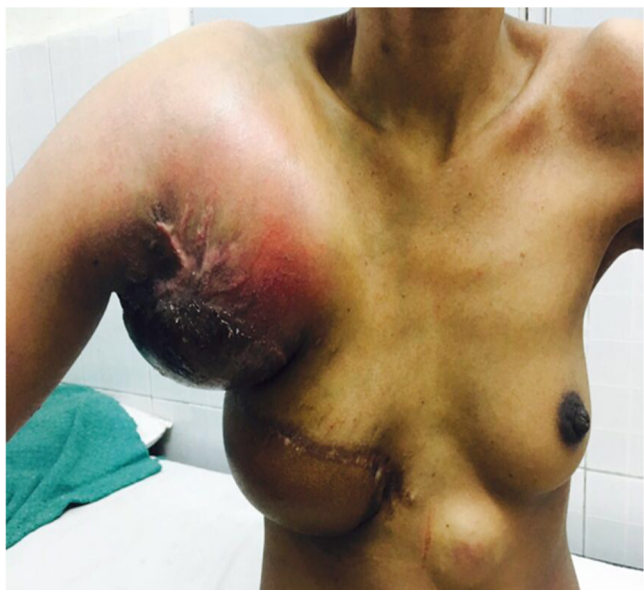E-mail addresses: [2660620ss@gmail.com](mailto:2660620ss@gmail.com) (S. Sarkar), [neetikapur2004@yahoo.co.in](mailto:neetikapur2004@yahoo.co.in) (N. Kapur).



**Figs. 1–2.** Showing malignant spindle cells and osteoclast like multi nucleated tumour giant cells. (20×).



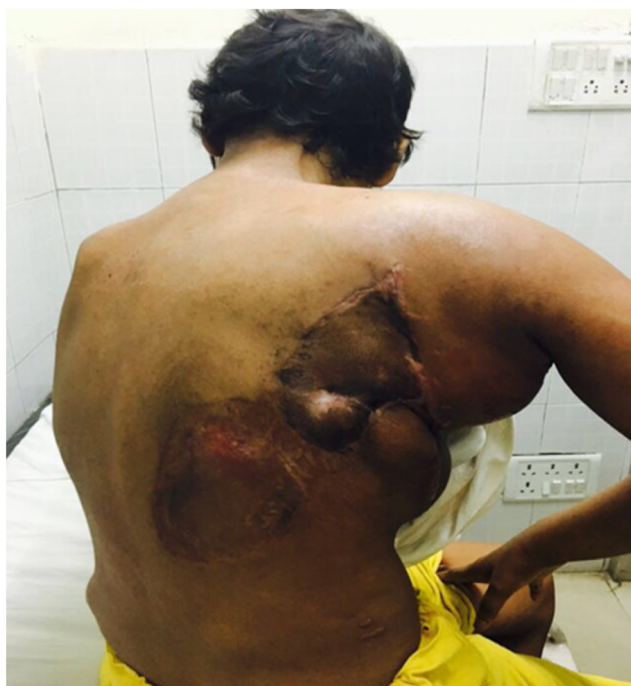**Fig. 3.** Showing cartilaginous differentiation with osteoid production.



**Fig. 4.** An axillary mass, recurrent right breast mass, an epigastric mass.

**3. Follow up**

Now the patient again came with recurrence after 5 months, and disseminate subcutaneous nodules over upper abdomen of size 6\*6 cm, back, scalp, neck and both forearm. There is a hard lump in



**Fig. 5.** Donor site of latissimus dorsi flap with multiple subcutaneous nodules over her back.

her right axilla, with restricted mobility of the right upper limb (Figs. 4 and 5). CECT chest showed left sided mediastinal mass and a necrotic axillary node likely to be malignant. USG abdomen was within normal limits.

**4. Discussion**

Malignant phyllodes tumour is a large, unilateral, painless, rapidly progressing lump with boss-elated surface. Median age of 45 years, axillary lymph nodes present in 20% cases. Risk of malignancy in phyllodes tumour is only 5%. FNAC shows dimorphic stromal and epithelial elements. Core needle shows hyper-cellular stromal components and IHC positive for CD10 and NOS (nitric oxide synthase).

Pure sarcomas of the breast are uncommon, accounting for less than 1% of primary breast malignant tumours [7,8]. More common breast sarcomas include fibrosarcomas, malignant fibrous histiocytoma, angiosarcoma, and liposarcoma [9]. Primary mammary osteosarcoma of the breast represents 12.5% of breast sarcomas [7].

Tumours with the following criteria are considered 'pure osteosarcoma': absence of bone origin, presence of osteoid or bony matrix, absence of an epithelial differentiation, and absence of a benign tumour.

Mammary osteosarcoma predominates in middle-aged and older women. Most often, they arise as de novo conditions without predisposing factors especially after radiation therapy [3]. All cases reported in literature had unilateral disease [7].

Clinical features, mammographic and macroscopic findings are not specific [11]. Mammographically, these tumours are usually dense and well-circumscribed with focal or extensive coarse calcifications [7,12]. Microscopic findings of primary mammary osteosarcoma are similar to skeletal and other extra-skeletal osteosarcomas. Considerable diversity in morphological appearance has been reported with variants like fibroblastic, osteoblastic, osteoclastic, and chondroblastic; a variable amount of osteoid tissue and bone are present in all [7]. Chondrosarcomatous differentiation is unusual as reported in our case [3,11].

In localised forms, the treatment is based on surgical excision with clear margins. Lymph node metastases are exceptional so that lymphadenectomy is not indicated. There is controversy regarding the use of chemotherapy. For some authors, it is not recommended especially in localised and well-resected low-grade tumours. Regarding metastasising tumours, treatment is based mainly on chemotherapy using conventional drugs for osteosarcoma (doxorubicin, ifosfamide, cisplatin, methotrexate) [13,14].

The prognosis is poor and the five-year survival is 38%. Recurrences are less frequent in patients treated with mastectomy than those treated with local excision. Metastases occur mainly in the lung; there is no axillary node involvement in almost all cases [10]. Cases of death occurring a few months after the diagnosis have been reported [1,8].

## 5. Conclusion

Chondroblastic osteosarcoma of breast is a very rare malignancy where a definitive diagnosis is established after a histology pathological examination and immunochemistry staining of the specimen. Surgical excision with clear surgical margins remains the cornerstone of treatment. There is limited literature to support the role of local radiotherapy for control of tumour recurrences in patients with primary breast osteosarcoma is still not established.

## Take away lesson

Chondroblastic Osteosarcoma of breast is a highly aggressive tumor with poor prognosis and even after aggressive surgery and adjuvant chemotherapy.

## Conflict of interest

No conflict of interest.

## Funding source

No funding source.

## Ethical approval

Ethical approval was not taken.

## In author contribution

Sourav Sarkar – Study design data collection, data analysis and writing.

Neeti Kapur – Study design and data analysis.

Stuti Bishen – Histo pathological slides review.

## Guarantor

Sourav Sarkar.

Neeti Kapur.

## References

- [1] C. Adem, C. Reynolds, J.N. Ingle, A.G. Nascimento, Primary breast sarcoma: clinicopathologic series from the Mayo Clinic and review of the literature, *Br. J. Cancer* 91 (2004) 237–241.
- [2] J.L. Young Jr., K.C. Ward, P.A. Wingo, H.L. Howe, The incidence of malignant non-carcinomas of the female breast, *Cancer Causes Control*. 15 (2004) 313–319.
- [3] S.A. Silver, F.A. Tavassoli, Primary osteogenic sarcoma of the breast: a clinicopathologic analysis of 50 cases, *Am. J. Surg. Pathol.* 22 (1998) 925–933.
- [4] M.R. Elochi, et al., Primary chondroblastic osteosarcoma of the breast, *Turk. J. Pathol.* 30 (3) (2014) 225–227.
- [5] A.A. Kallianpur, R. Gupta, D.K. Muduly, A. Kapali, K.C. Subbarao, Osteosarcoma of breast: a rare case of extraskelatal osteosarcoma, *J. Can. Res. Ther.* 9 (2013) 292–294.
- [6] T.O. Ogundiran, et al., Primary osteogenic sarcoma of the breast, *World J. Surg. Oncol.* 4 (2006) 90.
- [7] A. Bahrami, E. Resetkova, J.Y. Ro, J.D. Ibanˆez, A.G. Ayala, Primary osteosarcoma of the breast: report of 2 cases, *Arch. Pathol. Lab. Med.* 131 (2007) 792–795.
- [8] B. Saber, A. Nawal, F. Mohamed, E. Hassan, Primary osteosarcoma of the breast: case report, *Cases J.* 1 (2008) 80–81.
- [9] S. Jacob, D. Japa, Primary osteogenic sarcoma of the breast, *Indian J. Pathol. Microbiol.* 53 (2010) 785–786.
- [10] S. Murakami, H. Isozaki, T. Shou, K. Sakal, Y. Yamamoto, M. Oomori, H. Toyoda, Primary osteosarcoma of the breast, *Pathol. Int.* 59 (2009) 111–115.
- [11] J.T. Sperberg, J.W. Clayton 3rd, G.A. Masters, Primary osteosarcoma of the breast, *Del. Med. J.* 77 (2005) 11–14.
- [12] A. Ribeiro-Silva, L.N. Zambelli Ramalho, S. Zucoloto, Phyllodes tumor with osteosarcomatous differentiation: a comparative immunohistochemical study between epithelial and mesenchymal cells, *Tumori* 92 (2006) 340–346.
- [13] A. Ellmann, Z.M. Jawa, M. Maharaj, Primary osteogenic sarcoma of the breast detected on skeletal scintigraphy, *Clin. Nucl. Med.* 31 (2006) 474–475.
- [14] K. Irshad, B.S. Mann, H. Campbell, Primary osteosarcoma of the breast, *Breast* 12 (2003) 72–74.

## Open Access

This article is published Open Access at [sciencedirect.com](https://www.sciencedirect.com). It is distributed under the [IJSCR Supplemental terms and conditions](#), which permits unrestricted non commercial use, distribution, and reproduction in any medium, provided the original authors and source are credited.