

Pioglitazone-induced congestive heart failure and pulmonary edema in a patient with preserved ejection fraction

Vaneet Jearath, Rajan Vashisht, Vipul Rustagi, Sujeet Raina, Rajesh Sharma

Department of Medicine, Dr. Rajendra Prasad Government Medical College, Tanda, Himachal Pradesh, India

Received: 30-12-2014

Revised: 20-03-2015

Accepted: 08-08-2015

ABSTRACT

Pioglitazone-induced heart failure is known in patients with underlying heart disease, but is not well documented in patients with normal left ventricular function. Pioglitazone has been very popular as it is an insulin sensitizer and insulin resistance is prevalent among Indians. Fluid retention exacerbates pre-existing heart failure or precipitates heart failure in a patient with underlying left ventricular dysfunction. However, pathogenesis of heart failure in a patient with normal left ventricular function is not known. Probably it is due to dose-related effect on pulmonary endothelial permeability, rather than alterations in left ventricular mass or ejection fraction. We report a patient who developed congestive heart failure and pulmonary edema with normal left ventricular function within 1 year of starting pioglitazone therapy. We have to be careful in monitoring all possible side effects during followup when patients are on pioglitazone therapy.

Key words: Diabetes, diabetes mellitus, heart failure, pioglitazone, thiazolidinedione

INTRODUCTION

Pioglitazone is an established insulin sensitizer hugely successful in therapeutic management of type 2 diabetes mellitus. The beneficial effects extend beyond glycemic control and have positive effects on lipid metabolism, blood pressure, endothelial function, adiponectin, and C-reactive protein levels.^[1] Pioglitazone was a safer option for patients till it got involved in a controversy because of the side effects. Due

to the concerns over bladder cancer as an adverse effect, the manufacture, sale, and distribution of the drug was temporarily banned in India. It was subsequently revoked, but with the boxed warning relating to bladder cancer.^[2] The clinical use is further limited by the spectrum of side effects that include weight gain, decrease in hematocrit values, edema, heart failure, fractures, and worsening of diabetic macular edema. Heart failure is well documented in patients with known left ventricular dysfunction. However, in patients with normal left ventricular systolic and diastolic function, it has not been widely reported.^[3] We report a patient who developed congestive heart failure and pulmonary edema with normal

Access this article online	
Quick Response Code:	Website: www.jpharmacol.com
	DOI: 10.4103/0976-500X.179363

Address for correspondence:

Sujeet Raina, C-15, Type-V Quarters, Dr. Rajendra Prasad Government Medical College Campus, Tanda - 176 001, Kangra, Himachal Pradesh, India. E-mail: sujeetrashmishera@yahoo.co.in

This is an open access article distributed under the terms of the Creative Commons Attribution-NonCommercial-ShareAlike 3.0 License, which allows others to remix, tweak, and build upon the work non-commercially, as long as the author is credited and the new creations are licensed under the identical terms.

For reprints contact: reprints@medknow.com

How to cite this article: Jearath V, Vashisht R, Rustagi V, Raina S, Sharma R. Pioglitazone-induced congestive heart failure and pulmonary edema in a patient with preserved ejection fraction. J Pharmacol Pharmacother 2016;7:41-3.

left ventricular function within 1 year of starting pioglitazone therapy.

CASE REPORT

A 65-year-old, non-obese male, a diabetic for the last 10 years on oral hypoglycemic agents (OHA), was admitted in the emergency department with the chief complaint of progressive breathlessness for last 15 days. Patient had history of paroxysmal nocturnal dyspnea and orthopnea for the last 10 days. History of pedal edema was present during that period. There was no history of chest pain, palpitations, syncope, fever, cough, wheeze, and abdominal distension. He was a non-smoker and normotensive. Patient did not report any recent weight gain. Review of other systems was normal. No significant past history was present. No records of previous ECG or echocardiography were available.

In treatment history, patient was taking combination of pioglitazone 30 mg, metformin 1 g, and glimepiride 2 mg for the last 1 year. At the time of admission, pulse was 100/minute and was regular. No special character was noted. Blood pressure was 160/100 mmHg in the right upper limb. Respiratory rate was 24/minute. Jugular venous pressure was raised up to 6 cm above the angle of Louis. Bilateral pedal edema was present. Patient was afebrile. Examination of the cardiovascular system was normal. On chest auscultation, vesicular breath sounds were heard with extensive fine end-inspiratory crackles up to the interscapular area. Palpation of abdomen revealed tender hepatomegaly. Further examination was normal. On investigations, hemoglobin was 11.6 g% and total leukocyte count was 11,200/mm³. Biochemistry revealed the following values: Random blood glucose- 276 mg%, blood urea nitrogen- 20 mg%, serum creatinine- 0.9 mg%, serum aspartate aminotransferase- 58 U/l, serum alanine aminotransferase- 68 U/l, alkaline phosphatase- 215 U/l, and serum albumin 3.6 g%. Serum electrolytes and lipid profile were normal. Cardiac troponins were normal and D-dimer was negative. Urine examination was normal. Serial electrocardiograms were normal. Chest X-ray revealed picture of pulmonary edema with evidence of bilateral pleural effusion [Figure 1a]. A contrast-enhanced computed tomography (CECT) of chest done in a secondary care hospital was brought by the patient, which revealed ground glass opacities, particularly in the perihilar area, thickened interlobular septa, and bilateral pleural effusion [Figure 1b]. With this clinical and investigational profile, possibility of biventricular failure was suspected.

Patient was started on heart failure treatment protocol. Intravenous diuretics and angiotensin converting enzyme inhibitors were added. OHA were stopped and patient was started on premixed insulin (30:70) for control of blood glucose.

On the 2nd day of admission, patient's symptoms improved and 2D echocardiogram was done which documented normal systolic and diastolic functions, normal cardiac chambers, and no regional wall motion abnormality. The measurements on M-mode were: IVSed- 10, IVSes- 13, LVed- 56, LVes- 35, PW (LV) ed- 10, and PW (LV) es- 13. The left ventricular ejection fraction was 65%.

Over the next few days, his symptoms improved gradually. On chest examination, the crackles disappeared, and pedal edema and raised jugular venous pressure resolved. Serial chest X-rays and repeat CECT chest showed radiological clearance [Figure 2a and b]. As no other cause for biventricular failure could be made and patient was on pioglitazone for the last 1 year, possibility of pioglitazone-induced pulmonary edema was suspected. This possibility also gains significance as the patient improved on stopping the drug. Patient was discharged on premixed insulin (30:70) and pioglitazone was not rechallenged. The adverse drug reaction (ADR) was reported to the hospital ADR monitoring center.

DISCUSSION

Diabetes is a non-communicable metabolic disorder associated with microvascular and macrovascular complications. Numerous drugs, either in monotherapy or in combination therapy, are used in the treatment of type 2 diabetes to achieve glycemic goals and subsequently reduce complications.

We diagnosed a diabetic patient with congestive heart failure and pulmonary edema, who had preserved left ventricular ejection function on echocardiogram within 1 year of starting pioglitazone therapy. Pioglitazone is the only thiazolidinedione approved currently for use in type 2 diabetes mellitus after it faced uncertainty due to safety issues. In addition to lowering blood glucose, pioglitazone has a beneficial effect on lipid profile, blood pressure, inflammatory biomarkers, endothelial function, and fibrinolytic status. However, weight gain, decrease in hematocrit values, edema, cardiac failure, fractures, and possible worsening of diabetic macular edema are well-recognized complications of pioglitazone.^[4]

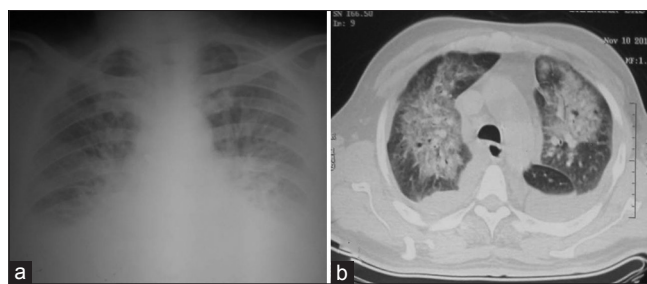


Figure 1: (a) Chest radiograph showing pulmonary edema and bilateral pleural effusion. (b) Computed tomography chest showing ground glass opacities, interlobular septal thickening, and bilateral effusion

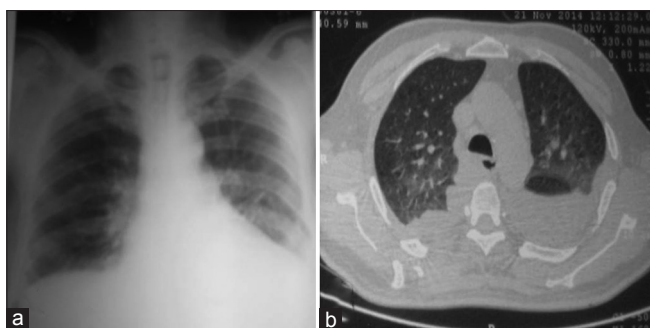


Figure 2: (a) Chest radiograph and (b) computed tomography chest showing resolution of ground glass opacities, interlobular septal thickening, and bilateral effusion

The pathogenesis for fluid retention and peripheral edema is multifactorial. It is due to reduction in renal excretion of sodium and an increase in sodium and free water retention. Increased sympathetic nervous system activity, altered interstitial ion transport, alterations in endothelial permeability, and peroxisome proliferator activated receptor mediated expression of vascular permeability growth factor represent other possible mechanisms for edema.^[5] Fluid retention exacerbates pre-existing heart failure or precipitates heart failure in a patient with underlying left ventricular dysfunction. However, pathogenesis of heart failure in a patient with normal left ventricular function is not known. It is also known that thiazolidinedione therapy does not have significant effects on left ventricular function based on echocardiographic studies.^[6] Studies of rosiglitazone indicate that a dose-related effect on pulmonary endothelial permeability, rather than alterations in left ventricular mass or ejection fraction, is probably responsible for the development of pulmonary edema and, in susceptible patients, cardiac failure.^[7] Rosiglitazone stands banned due to the concerns regarding increased incidence of myocardial infarction.

The Prospective Pioglitazone Clinical Trial in Macrovascular Events (PROactive) study examined the incidence of heart failure in patients taking pioglitazone compared with placebo. Heart failure leading to hospital admission occurred significantly more often in patients taking pioglitazone compared with placebo (5.7% vs 4.1%). However, the mortality rate due to heart failure was proportionately lower with pioglitazone (26.8% vs 34.3%). The reason for the reduced all-cause mortality despite increased risk of heart failure is better glycemic control and lesser myocardial infarction and stroke.^[8] The risk of heart failure associated with the use of non-insulin blood glucose lowering drugs

has been reviewed. Information on the risk of heart failure in glitazone users compared with sulfonylureas users is very scarce, and the risk of heart failure in sulfonylurea users is higher compared with metformin users. In view of this, the probability of occurrence of heart failure due to second generation of sulfonylureas cannot be ruled out. However the findings of the same meta-analysis show that the likelihood of occurrence of heart failure due to pioglitazone is higher as compared to sulfonylureas.^[9]

To summarize, evaluate every patient on pioglitazone, particularly with multiple medications, old age, and chronic renal disease, for all possible side effects by careful monitoring and follow-up.

Financial support and sponsorship

Nil.

Conflicts of interest

There are no conflicts of interest.

REFERENCES

- Shukla R, Kalra S. Pioglitazone: Indian perspective. *Indian J Endocrinol Metab* 2011;15:294-7.
- Mithal A, Kaur P, Bansal B, Mishra SK, Wasir JS, Jevalikar G, *et al.* Usage of pioglitazone at Medanta, the Medicity. *Indian J Endocrinol Metab* 2014;18:111-2.
- Shah M, Kolandaivelu A, Fearon WF. Pioglitazone-induced heart failure despite normal left ventricular function. *Am J Med* 2004;117:973-4.
- Nesto RW, Bell D, Bonow RO, Fonseca V, Grundy SM, Horton ES, *et al.* American Heart Association; American Diabetes Association. Thiazolidinedione use, fluid retention, and congestive heart failure: A consensus statement from the American Heart Association and American Diabetes Association. October 7, 2003. *Circulation* 2003;108:2941-8.
- Scherthaner G, Currie CJ, Scherthaner GH. Do we still need pioglitazone for the treatment of type 2 diabetes? A risk-benefit critique in 2013. *Diabetes Care* 2013;36(Suppl 2):S155-61.
- St. John Sutton M, Rendell M, Dandona P, Dole JF, Murphy K, Patwardhan R, *et al.* A comparison of the effects of rosiglitazone and glyburide on cardiovascular function and glycemic control in patients with type 2 diabetes. *Diabetes Care* 2002;25:2058-64.
- Fernando DJ, Bulughapitiya U, Prior K. Delayed onset of rosiglitazone-induced pulmonary oedema. *Eur J Intern Med* 2006;17:590.
- Dormandy JA, Charbonnel B, Eckland DJ, Erdmann E, Massi-Benedetti M, Moules IK, *et al.* PROactive investigators. Secondary prevention of macrovascular events in patients with type 2 diabetes in the PROactive Study (PROspective pioglitAzone Clinical Trial In macroVascular Events): A randomised controlled trial. *Lancet* 2005;366:1279-89.
- Varas-Lorenzo C, Margulis AV, Pladevall M, Riera-Guardia N, Calingaert B, Hazell L, *et al.* The risk of heart failure associated with the use of noninsulin blood glucose-lowering drugs: Systematic review and meta-analysis of published observational studies. *BMC Cardiovasc Disord* 2014;14:129.