

CASE REPORTS

Case 1

A 14-year-old boy presented in the emergency department with a history of blunt injury to chest (run over by bullock cart) with respiratory insufficiency and episodes of vomiting with frank blood. On examination, child was irritable, tachypneic, with feeble peripheral pulses with features suggestive of left sided pneumothorax. An urgent bed side chest X-ray showed left pneumothorax [Figure 1]. After intercostal drain (ICD) insertion at 5th intercostal space his saturation improved to 95%. Continuous air leak was noticed through ICD tube and computerised tomography (CT) thorax revealed left main bronchus distal portion tear with severe collapse of the left lung ('fallen lung sign'), left subclavian artery complete thrombosis with suspicious injury to left inferior pulmonary vein. Laboratory investigations revealed Bombay O blood group, haemoglobin = 9.3 g/dl, haematocrit = 25.6, other blood and urine investigations were normal. Though CT scan showed subclavian artery thrombosis, clinically there were no signs of ischaemia of limb and also radial and ulnar artery pulsations were felt moderately. Thus, patient was started on heparin 2500 IU empirically.

An immediate diagnostic bronchoscopy and posterolateral thoracotomy was planned. Written informed high-risk consent was taken. In the operating room, pre-operative vitals were heart rate = 112/min, blood pressure = 96/60 mmHg, SpO₂ = 95% with O₂ support. After pre-oxygenation, patient was pre-medicated with intravenous glycopyrrolate 0.2 mg and fentanyl 40 µg. The patient's trachea was intubated with a 6-mm cuffed single lumen endotracheal tube (ETT) after induction with thiopental sodium and succinylcholine. Complete transection of the left main bronchus was confirmed with fibre optic bronchoscopy (FOB) and right endobronchial intubation and one lung ventilation (OLV) was achieved. Anaesthesia was maintained with isoflurane in 100% O₂ and atracurium. Once bronchial transection repaired, ETT was pulled out of right bronchus and placed above the carina, both lungs ventilated saturation of 98-99% ensured. Post-repair, no air leak noticed with positive pressure ventilation and patient was extubated after confirming adequate respiratory efforts. Follow-up chest X-ray showed incomplete expansion of the left lung due to underlying contusion. ICD removed on 11th post-operative day. Child was discharged after 12 days.

Anaesthetic considerations in primary repair of tracheobronchial injury following blunt chest trauma in paediatric age group: Experience of two cases

INTRODUCTION

Tracheobronchial injuries (TBIs) are rare among all age groups and are extremely rare among the paediatric age group. Anaesthetic management for repair of TBI thus is a challenge. Management of TBI is well-described by surgical and medical journals,^[1,2] but there is a paucity of literature regarding anaesthetic implications and considerations. We share our experience of management of primary repair of TBI following blunt chest trauma.

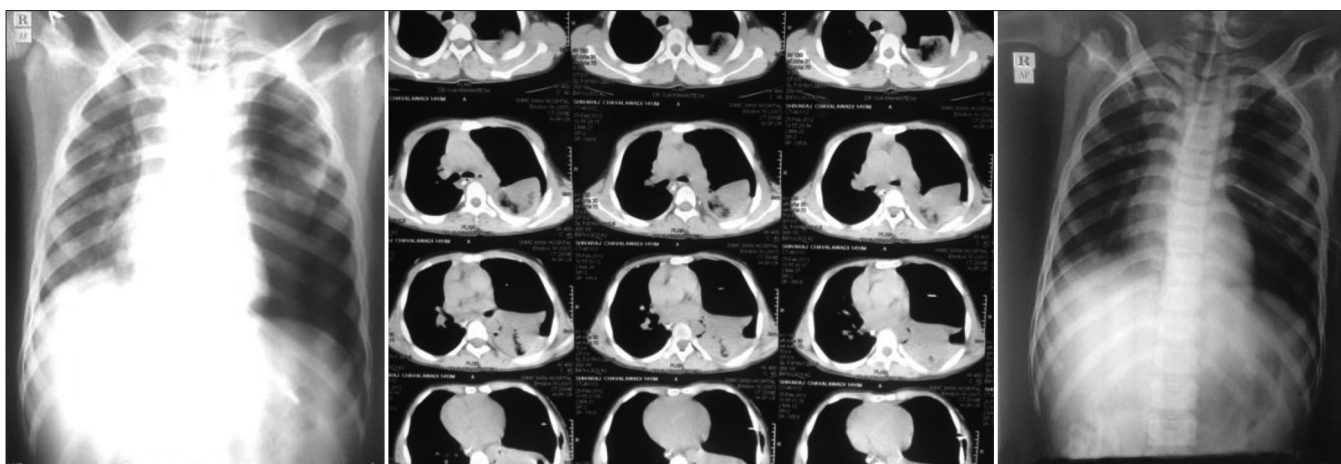


Figure 1: Pre- and post-operative chest X-ray findings with computerized tomography picture showing “fallen lung sign”

Case 2

A 5-year-old male child was admitted as an emergency following a blunt chest trauma. Early clinical examination showed signs of haemorrhagic shock with severe respiratory distress and right sided tension pneumothorax. A wide bore needle was inserted in 2nd intercostal space. Pneumothorax was confirmed by an urgent bed side chest X-ray. After inserting a chest drain and adequate fluid resuscitation, patient's vital parameters improved. Emergency CT scan showed massive pneumothorax with suspicion of right main bronchus injury. Patient's blood investigations were within the normal limits.

After intravenous induction with ketamine 30 mg and succinylcholine 25 mg, patient's trachea was intubated with 5 mm uncuffed ETT. FOB revealed discontinuation of right main bronchus about 2 cm from its origin from carina. Left endobronchial intubation achieved with the help of FOB. After placing the child in left lateral position, a diagnostic thoracoscopy was done, which revealed no associated mediastinal injuries. Rest of the perioperative course was uneventful and was similar to the first case.

DISCUSSION

Incidence of TBI is about 0.7-2.8% according to different investigators.^[1,2] Mortality relating to TBI is very high and many of patients do not reach hospital. Right sided TBI are more frequent than left and left sided injuries had better outcome compared with right TBI.^[3] Lesion locations appear to be constant: 15% are tracheal ruptures, 2.5 cm from the carina; 80% are main bronchial lesions; and 5% are distal bronchial lesions.^[1] A continuing air leak despite chest drainage should alert the clinician to the possibility of

airway injury.^[4] Early bronchoscopy must be carried out when there is doubt about TBI lesion. It is the most reliable means of diagnosing TBI, showing the lesion and its location.^[2] Patients presenting with respiratory distress and persistent air leak will usually go for exploratory surgery. Minimal access surgery can be a safe and effective way to evaluate and manage haemodynamically stable children with both penetrating and blunt traumatic injuries.^[1]

Recommended methods of OLV in children are balloon-tipped bronchial blockers, univent tubes, double lumen tube (DLT) and single lumen ETTs.^[5] Conventional ventilatory management with endotracheal intubation and positive pressure is likely to cause air leakage and produce further deterioration of pulmonary function. Shimazu *et al.* used a double lumen ETT in two cases to facilitate ventilation and allow surgery. Dreyfuss *et al.* recommend high-frequency ventilation for intraoperative and post-operative management of tracheobronchial trauma.^[4] Iwasaki *et al.* successfully managed five patients who required surgery using univent tube.^[6] Naghibi *et al.* used jet ventilation through two intrabronchial catheters in a case of TBI.^[4] A detailed discussion on the problems of OLV and lung isolation is beyond the scope of this paper. In our first case, we could not use DLT due to non-availability of appropriate sized tube. In the second case, age was against using DLT and single lumen tube was used to isolate the lung, with FOB guidance.

After surgery, early extubation is recommended in cases of TBI to avoid additional complications caused by the tube, elevated endotracheal pressure during artificial ventilation or repeated suctioning.^[5]

CONCLUSION

We would like to emphasise on early diagnosis by bronchoscopy and isolation of the lesion by appropriate techniques and on excellent communication and co-ordination between the surgeon, intensivist and the anaesthesiologist to ensure that airway management is well-planned and executed, to protect patient safety.

**Vinod Hosalli, Uday S Ambi, Anilkumar Ganeshnavar,
Shivanand Hulakund, DS Prakashappa**

Department of Anaesthesiology, S Nijalingappa Medical College,
Bagalkot, Karnataka, India

Address for correspondence:

Dr. Uday S Ambi,
Department of Anaesthesiology, S Nijalingappa Medical College,
Bagalkot - 587 102, Karnataka, India.
E-mail: udayambi@ymail.com

REFERENCES

1. Oak S, Sandesh P, Prakash A, Purushotham G, Manjusa S, Rahul P, *et al.* Role of thoracoscopy in blunt thoracic trauma-A case study Paediatric Endosurg and Innovative Techniques 2003;7:315-8.
2. Slimane MA, Becmeur F, Aubert D, Bachy B, Varlet F, Chavrier Y, *et al.* Tracheobronchial ruptures from blunt thoracic trauma in children. J Pediatr Surg 1999;34:1847-50.
3. Singal R, Dalal AK, Dalal U, Attri AK, Gupta S, Sadhu R, *et al.* Complete bronchial transection due to severe blunt trauma and chest; treatment and outcomes: A distinct entity. Indian J Crit Care Med 2012;16:31-3.4.
4. Naghibi K, Hashemi SL, Sajedi P. Anaesthetic management of tracheobronchial rupture following blunt chest trauma. Acta Anaesthesiol Scand 2003;47:901-3.
5. Lahori VU, Aggarwal S, Simick P, Dharmavaram S. Foreign body removal with repair of iatrogenic tracheo-bronchial tear repair: An anesthetic challenge. J Anaesthesiol Clin Pharmacol 2011;27:534-6.
6. Iwasaki M, Kaga K, Ogawa J, Inoue H, Shohtsu A. Bronchoscopy findings and early treatment of patients with blunt tracheo-bronchial trauma. J Cardiovasc Surg (Torino) 1994;35:269-71.

| Access this article online | |
|---|--|
| Quick response code | Website: www.ijaweb.org |
|  | DOI: 10.4103/0019-5049.118541 |